OBSTETRIC UNIT

UNIVERSITY COLLEGE HOSPITAL

NOT TO BE TAKEN AWAY

SHL
WITHDRAWN

Library of
University College
Obstetric Hospital
from
Herbert R. Spencer

OBSTETRICAL TRANSACTIONS.

VOL. XLIX.

Digitized by the Internet Archive
in 2026

https://archive.org/details/transactions-of-the-obstetrical-society-of-london_1907_49_1

TRANSACTIONS

OF THE

OBSTETRICAL SOCIETY

OF

LONDON.

VOL XLIX.

FOR THE YEAR 1907.

WITH A LIST OF OFFICERS, FELLOWS, ETC.,
AND GENERAL INDEX TO VOLS. I—XLIX.

EDITED BY
HERBERT R. SPENCER, M.D.,
AND
ROBERT BOXALL, M.D., Senior Secretary.

LONDON:
LONGMANS, GREEN, AND CO.
1908.

PRINTED BY ADLARD AND SON, LONDON AND DORKING.

OBSTETRICAL SOCIETY OF LONDON.

OFFICERS FOR 1907.

PRESIDENT.
SPENCER, HERBERT R., M.D.

VICE-PRESIDENTS.
BUTLER-SMYTHE, ALBERT C.
HANDFIELD-JONES, MONTAGU, M.D.
PHILLIPS, JOHN, M.D.
SINCLAIR, Sir WILLIAM JAPP, M.D. (Manchester).

TREASURER.
HERMAN, GEORGE ERNEST, M.B.

EDITOR OF 'TRANSACTIONS.'
SPENCER, HERBERT R., M.D.

HONORARY SECRETARIES.
BOXALL, ROBERT, M.D.
LEWERS, ARTHUR H. N., M.D.

HONORARY LIBRARIAN.
GOW, WILLIAM JOHN, M.D.

EX-OFFICIO MEMBERS OF COUNCIL.
WILLIAMS, Sir JOHN, Bart., M.D. (*Trustee and Past President*).
BLACK, J. WATT, M.D. (*Trustee and Past President*).
CHAMPNEYS, FRANCIS HENRY, M.D. (*Trustee*).
GERVIS, HENRY, M.D. (*Past President*).
GALABIN, ALFRED LEWIS, M.D. (*Past President*).
HERMAN, G. E., M.B. (*Past President*).
DAKIN, W. R., M.D. (*Ex-President*).

OTHER MEMBERS OF COUNCIL.
ANDREWS, HENRY RUSSELL, M.D.
BRIGGS, HENRY, M.B., F.R.C.S. (Liverpool).
BROOK, WILLIAM H. B., M.D. (Lincoln).
CULLINGWORTH, CHARLES JAMES, M.D.
EASTES, GEORGE, M.B., F.R.C.S.
EDEN, THOMAS W., M.D.
FAIRBAIRN, JOHN SHIELDS, M.B., B.Ch.
HELLIER, JOHN BENJAMIN, M.D. (Leeds).
HICKS, HENRY THOMAS, F.R.C.S.
HURRY, JAMIESON BOYD, M.D. (Reading).
KERR, JOHN MARTIN MUNRO, M.B., C.M. (Glasgow).
LOCKYER, CUTHBERT, M.D.
ROBERTS, CHARLES HUBERT, M.D.
ROUTH, AMAND, M.D.
SCHARLIEB, MARY ANN DACOMB, M.D.
TARGETT, JAMES HENRY, M.S., F.R.C.S.
WILLIAMSON, HERBERT, M.B.
WILSON, THOMAS, M.D. (Birmingham).

STANDING COMMITTEES.

LIBRARY COMMITTEE.

DORAN, ALBAN, F.R.C.S.
ROBINSON, GEORGE H. DRUMMOND, M.D.
LOCKYER, CUTHBERT, M.D.
ANDREWS, H. RUSSELL, M.D.
BLACKER, G. F., M.D.

EX-OFFICIO.
- SPENCER, H. R., M.D., *President.*
- HERMAN, G. E., M.B., *Treasurer.*
- BOXALL, ROBERT, M.D., } *Hon. Secs.*
- LEWERS, ARTHUR H. N., M.D., } *Hon. Secs.*
- GOW, WILLIAM JOHN, M.D., *Hon. Lib.*

PUBLICATION COMMITTEE.

PHILLIPS, JOHN, M.D.
BLACKER, GEORGE FRANCIS, M.D.
CULLINGWORTH, CHARLES JAMES, M.D.
ROUTH, AMAND, M.D.
GOW, WILLIAM JOHN, M.D.
FAIRBAIRN, JOHN SHIELDS, M.B.

EX-OFFICIO.
- SPENCER, HERBERT R., M.D., *President and Editor.*
- BOXALL, ROBERT, M.D., } *Hon. Secs.*
- LEWERS, ARTHUR H. N., M.D., } *Hon. Secs.*

FINANCE COMMITTEE.

BOULTON, PERCY, M.D.
CULLINGWORTH, CHARLES JAMES, M.D.
WILLIAMS, Sir JOHN, Bart., K.C.V.O., M.D.
BLACK, J. WATT, M.D.
CHAMPNEYS, F. H., M.D.
ROUTH, AMAND, M.D.

EX-OFFICIO.
SPENCER, H. R., M.D., *President.*
HERMAN, G. E., M.B., *Treasurer.*
BOXALL, ROBERT, M.D., } *Hon. Secs.*
LEWERS, ARTHUR H. N., M.D., }

PATHOLOGY COMMITTEE.

GRIFFITH, W. S. A., M.D., *Chairman.*
ANDREWS, HENRY RUSSELL, M.D.
BLACKER, GEORGE FRANCIS, M.D.
DORAN, ALBAN, F.R.C.S.,
EDEN, THOMAS WATTS, M.D.
FAIRBAIRN, JOHN SHIELDS, M.D.
HICKS, HENRY THOMAS, F.R.C.S.
KEEP, ARTHUR CORRIE, M.D., *Secretary.*
LOCKYER, CUTHBERT, M.D.
LONGRIDGE, CHARLES JOHN NEPEAN, M.D.
MAXWELL, R. DRUMMOND, M.D.
ROBERTS, CHARLES HUBERT, M.D.
SMITH, ARTHUR LIONEL H.
SMITH, G. F. DARWALL, F.R.C.S.
SMITH, GUY BELLINGHAM, F.R.C.S.
SPENCER, HERBERT R., M.D.
STEVENS, THOMAS GEORGE, M.D.
TARGETT, JAMES HENRY, M.S.
WILLETT, JOHN ABERNETHY, M.B.
WILLIAMSON, HERBERT, M.B.

EX-OFFICIO.
SPENCER, H. R., M.D., *President.*
BOXALL, ROBERT, M.D., } *Hon. Secs.*
LEWERS, ARTHUR H. N., M.D., }

LIST OF PRESIDENTS OF THE SOCIETY.

1859 EDWARD RIGBY, M.D.
1861 WILLIAM TYLER SMITH, M.D.
1863 HENRY OLDHAM, M.D.
1865 ROBERT BARNES, M.D.
1867 JOHN HALL DAVIS, M.D.
1869 GRAILY HEWITT, M.D.
1871 JOHN BRAXTON HICKS, M.D., F.R.S.
1873 EDWARD JOHN TILT, M.D.
1875 WILLIAM OVEREND PRIESTLEY, M.D.
1877 CHARLES WEST, M.D.
1879 WILLIAM S. PLAYFAIR, M.D.
1881 J. MATTHEWS DUNCAN, M.D., F.R.S.
1883 HENRY GERVIS, M.D.
1885 JOHN BAPTISTE POTTER, M.D.
1887 JOHN WILLIAMS, M.D.
1889 ALFRED LEWIS GALABIN, M.D.
1891 JAMES WATT BLACK, M.D.
1893 G. ERNEST HERMAN, M.B.
1895 F. H. CHAMPNEYS, M.A., M.D.
1897 CHARLES JAMES CULLINGWORTH, M.D.
1899 ALBAN DORAN, F.R.C.S.
1901 PETER HORROCKS, M.D.
1903 EDWARD MALINS, M.D.
1905 WILLIAM R. DAKIN, M.D.
1907 HERBERT R. SPENCER, M.D.

REFEREES OF PAPERS FOR THE YEAR 1907

Appointed by the Council.

BLACK, JAMES WATT, M.D.
BLACKER, GEORGE FRANCIS, M.D.
BLAND-SUTTON, JOHN, F.R.C.S.
CHAMPNEYS, F. H., M.A., M.D.
CULLINGWORTH, CHARLES JAMES, M.D.
DAKIN, WILLIAM RADFORD, M.D.
DORAN, ALBAN, F.R.C.S.
GALABIN, ALFRED LEWIS, M.A., M.D.
GOW, WILLIAM JOHN, M.D.
HANDFIELD-JONES, M., M.D.
HERMAN, G. ERNEST, M.B.
MEREDITH, WILLIAM A., M.B., C.M.
PHILLIPS, JOHN, M.A., M.D.
ROUTH, AMAND, M.D.
SPENCER, HERBERT R., M.D.

OBSTETRICAL SOCIETY OF LONDON.

TRUSTEES OF THE SOCIETY'S PROPERTY.

Sir John Williams, Bart., K.C.V.O., M.D.
J. Watt Black, M.D.
F. H. Champneys, M.A., M.D.

HONORARY FELLOWS.

BRITISH.

Elected

1899 Hutchinson, Jonathan, F.R.C.S., F.R.S., LL.D., 15, Cavendish square, W.

1892 Lister, The Right Honorable Lord, M.B., F.R.C.S., F.R.S., LL.D., 12, Park crescent, Portland place, W.

1892 Turner, Sir William, M.B., F.R.C.S., F.R.S., Principal of the University of Edinburgh; 6, Eton terrace, Edinburgh.

1904 Williams, Sir John, Bart., K.C.V.O., M.D., F.R.C.P., Plâs Llanstephan, Carmarthenshire. *Council*, 1875-6, 1892, 1894. *Hon. Sec.* 1877-9. *Vice-Pres.* 1880-2. *Board Exam. Midwives*, 1881-2; *Chairman*, 1884-6. *Pres.* 1887-8. *Trans.* 12. *Trustee.*

FOREIGN.

Elected

1899 MARTIN, A. E., M.D., Professor of Obstetrics and Gynæcology, Greifswald. *Trans.* 1.

1899 OLSHAUSEN, R. M., Professor, N. Artilleriestrasse 19, Berlin.

1899 PINARD, A., Professor, 10, Rue Cambacérés, Paris.

1904 POZZI, SAMUEL, M.D., 47, Avenue d'Iéna, Paris.

1895 VON WINCKEL, Professor, Sonnenstrasse 16A, Munich.

ORDINARY FELLOWS

1906

Those marked thus (*) have paid the Composition Fee in lieu of further annual subscriptions.

Those marked thus (†) reside beyond the London Postal District.

The letters O.F. are prefixed to the names of the "Original Fellows" of the Society.

Elected

1898 Aarons, S. Jervois, M.D.Edin., 14, Stratford place, W.

1900 Abbott, Horatio White, L.R.C.P.Lond., 66, Jackson road, Holloway, N.

1890† Ackerley, Richard, M.B., B.S.Oxon., Croft House, The Hill, Surbiton.

1891 Adams, Charles Edmund, M.R.C.S., 227, Gipsy road, West Norwood, S.E. *Council*, 1901.

1906† Adams, Evelyn Lancelot, M.B., B.S.Lond., 171, St. James's road, East Croydon.

1890 Addinsell, Augustus W., M.B., C.M.Edin., M.R.C.P., 10, Curzon street, W. *Council*, 1898-1900. *Trans.* 2.

1903 Aldrich-Blake, Louisa Brandrath, M.D., M.S.Lond., Surgeon to the New Hospital for Women, 17, Nottingham place, W.

1883*†Allan, Robert John, L.R.C.P.Ed., The Bungalow, Dulwich hill, Sydney, New South Wales.

1906† Allan, Thomas Sprot, L.R.C.P.&S.Edin., 67, Pitfield street, N.

Elected

1887 Ambrose, Robert, B.A., L.R.C.P. & S.Ed., The Mount, Shoot-up hill, Brondesbury, N.W.

1901† Amsden, Walter, L.R.C.P.Lond., Seaford, Sussex.

1905† Anderson, Daniel E., M.B.Lond., M.D.Paris, 121, Avenue des Champs Élysées, Paris.

1875* Anderson, John Ford, M.D., C.M., 41, Belsize park, N.W. *Council*, 1882, 1898-9.

1903 Anderson, Louisa Garrett, M.D., B.S.Lond., Assistant Surgeon to the New Hospital for Women, 114A, Harley street, W.

1899 Andrews, E. Collingwood, M.A., M.D.Cantab., 110, Finchley road, South Hampstead, N.W.

1899 Andrews, Henry Russell, M.D., M.R.C.P.Lond., Assistant Physician to the London Hospital, 7, Wimpole street, W. *Council*, 1905–7. *Trans.* 2.

1906 †Anklesaria, H. N., L.R.C.P., F.R.C.S.Edin., 12, Colaba Causeway, Bombay, India.

1870*†Appleton, Robert Carlisle, M.R.C.S., The Bar House, Beverley.

1884 Appleton, Thomas A., M.R.C.S., 46, Britannia road, Fulham, S.W.

1883† Archibald, John, M.D., Hazelden, Wimborne road, Bournemouth.

1871 Argles, Frank, L.R.C.P.Ed., Hermon Lodge, Wanstead, Essex, N.E. *Council*, 1886-7.

1906 †Aubrey, George Ernest, M.B., B.S.Lond., Alexandra Buildings, Hong Kong, China.

1887 Bailey, Henry Frederick, M.R.C.S., The Hollies, Lee terrace, Lee, S.E.

1869* Bantock, George Granville, M.D., Consulting Surgeon to the Samaritan Free Hospital; 14, Upper Hamilton terrace, N.W. *Council*, 1874-6. *Trans.* 2.

1886*†Barbour, A. H. Freeland, M.D.Edin., Lecturer on Midwifery and Diseases of Women, Edinburgh Medical School, 4, Charlotte square, Edinburgh. *Council*, 1898-1901. *Vice-Pres.* 1903–5.

1884† Barraclough, Robert W. S., M.D., Primrose Club, 4, Park place, St. James's, S.W.

Elected

1896† Barrett, Sidney Edward, M.B., B.C.Cantab., The Limes, Tillingham, Southminster, Essex.

1886† Barrington, Fourness, M.B.Edin., F.R.C.S.Eng., 213, Macquarie street, Sydney, New South Wales.

1891 Barton, Edwin Alfred, L.R.C.P.Lond., 56, Kensington Court, W.

1906 †Battle, Charles J., L.R.C.P., Kearsney, Stanger, Natal South Africa.

1892 Beauchamp, Sydney, M.B., B.C.Cantab., 8, William street, Lowndes square, S.W. *Council*, 1904.

1896† Belben, Frank, M.B., F.R.C.S., Redlands, Knyveton road, Bournemouth.

1866*†Belcher, Henry, M.D., 28, Cromwell road, West Brighton.

1871 *Bell, Robert, M.D.Glasg., 15, Half Moon street, Mayfair, W.

1906 †Bell, William Blair, M.D., B.S., Assistant Gynæcological Surgeon to the Royal Infirmary, Liverpool, 7, Rodney street, Liverpool.

1889† Benson, Matthew, M.D.Brux., Wyndholme, Wigan.

1894 Berkeley, Comyns, B.A., M.B., B.C.Cantab., Physician to Out-patients to Chelsea Hospital for Women; 53, Wimpole street, W. *Council*, 1902-3.

1883† Bertolacci, J. Hewetson, L.S.A., Elstead, Godalming, Surrey.

1889† Best, William James, M.R.C.S., 1, Cambridge terrace, Dover.

1893*†Betenson, William Betenson, L.R.C.P.Lond., Sussex Lodge, Newhaven.

1894* Betenson, Woodley Daniel, L.R.C.P.Lond., 58, Lansdowne road, Notting hill, W.

1891† Beville, Frederick Wells, L.R.C.P.Lond.

1887*†Biden, Charles Walter, L.R.C.P.Lond., Laxfield, Framlingham.

Elected

1879* Biggs, J. M., M.R.C.S., L.R.C.P.Lond., Hillside, Child's hill, N.W. *Council*, 1903–4.

1889† Bisshopp, Francis Robert Bryant, M.A., M.B., B.C.Cantab., Parham House, Tunbridge Wells.

1890† Black, George, M.B., B.S.Lond., The Willows, Hailsham, Sussex.

1868* Black, James Watt, M.A., M.D., F.R.C.P., Obstetric Physician to the Charing Cross Hospital; 15, Clarges street, Piccadilly, W. *Council*, 1872-4. *Vice-Pres.* 1885-6. *Chairman, Board Exam. Midwives*, 1887-90. *Pres.* 1891-2. *Treas.* 1898-1901. *Trustee.*

1893 Blacker, George Francis, M.D., B.S.Lond., F.R.C.S., Obstetric Physician to University College Hospital; 45, Wimpole street, W. *Council*, 1898-1901. *Board Exam. Midwives*, 1900-1. *Trans.* 2.

1901 Blair, G. MacLellan, M.B., B.S., 93, Maida Vale, W.

1861*† Blake, Thomas William, M.D.St.And., Hurstbourne, Bournemouth, Hants.

1888* Bland-Sutton, John, F.R.C.S., Surgeon to the Middlesex Hospital; 47, Brook street, W. *Council*, 1894-5. *Trans.* 5.

1902† Boardman, Edith, M.D.Brux., Hyderabad Deccan India.

1894† Bodilly, Reginald Thomas H., L.R.C.P.Lond., Woodbury, High road, South Woodford.

1902† Bonnar, Kathleen, L.R.C.P. and S.Edin., Dufferin Hospital, Allahabad, India.

1883 Bonney, William Augustus, M.D., 100, Elm park gardens Chelsea, S.W.

1900 Bonney, William Francis Victor, M.S., M.D.Lond., F.R.C.S.Eng., Lecturer on Practical Midwifery at Middlesex Hospital; Surgeon to Out-patients, Chelsea Hospital for Women; 10, Devonshire street, Portland place, W. *Trans.* 2.

Elected

1894† Borcherds, Walter Meent, M.R.C.S., L.R.C.P., Ficksburg, Orange River Colony, South Africa.

1903 Bott, Percival George A., L.R.C.P.Lond., 45, Cambridge terrace, Hyde park, W.

1866* Boulton, Percy, M.D., Physician to the Samaritan Free Hospital; 15, Seymour street, Portman square, W. *Council*, 1878-80, 1885, 1896. *Hon. Lib.* 1886. *Hon Sec.* 1886-9. *Vice-Pres.* 1890-2. *Board Exam. Midwives*, 1890-1. *Chairman*, 1897-1900. *Editor*, 1894-1900. *Trans.* 4.

1886† Boustead, Robinson, M.D., B.C. Cantab., Lieutenant-Colonel, Indian Medical Service; c/o Messrs. H. S. King and Co., 45, Pall Mall, S.W.

1899 Bowie, Albert W., M.B., C.M.Edin., 38, Bruce Grove, Tottenham, N.

1899† Bowring, Walter Andrew, F.R.C.S.Eng., The Pines Furze Hill, Brighton.

1884* Boxall, Robert, M.D.Cantab., Physician and Lecturer to the York Road (General Lying-in) Hospital; 40, Portland place, W. *Council*, 1888-90, 1894-5, 1899-1901. *Board Exam. Midwives*, 1891-3. *Hon. Lib.* 1902–3. *Hon. Sec.*, 1904-7. *Trans.* 13.

1902 Boyd, Florence Nightingale, M.D.Brux., L.R.C.P. and S.I., Senior Surgeon New Hospital for Women, Lecturer on Gynæcology, London (Royal Free Hospital) School of Medicine for Women; 134, Harley street, W. *Trans.* 1.

1897 Boyd, John Stewart, L.R.C.P.Lond., Victoria House, Custom House, E.

1884† Boys, Arthur Henry, L.R.C.P.Ed., Chequer Lawn, St. Albans.

1880 Branfoot, Arthur Mudge, M.B., c/o Messrs. Woodhead and Co., 44, Charing cross, S.W.

1887 Bridger, Adolphus Edward, M.D.Ed., 18, Portland place, W.

Elected

1888*†Briggs, Henry, M.B., F.R.C.S., Surgeon to the Hospital for Women, and Professor of Midwifery and Gynæcology, University College (Victoria University), Liverpool; 3, Rodney street, Liverpool. *Council*, 1901–3, 1907.

1894 Brinton, Roland Danvers, B.A., M.D.Cantab., 8, Queen's Gate terrace, S.W.

1892 Brodie, William Haig, M.D., C.M.Edin., F.R.C.S.Eng., 6, St. Stephen's road west, West Ealing, W.

1902† Brook, William Henry Breffit, M.D., B.S., F.R.C.S., 8, Eastgate, Lincoln. *Council*, 1907.

1868† Brown, Andrew, M.D. St. And., Mayfield, Royston park, Pinner. *Council*, 1893-4. *Trans.* 1.

1865* Brown, D. Dyce, M.D., 29, Seymour street, Portman square, W.

1898† Brown, Haydn, L.R.C.P.Edin., Caterham, Surrey.

1889* Brown, William Carnegie, M.D.Aber., 32, Harley street, W.

1902 Browne, Ada Margaret, L.S.A., 64, Belsize park, N.W.

1904 Brydone, James Marr, M.B., B.C.Cantab., 16, South Audley street, Grosvenor square, W.

1885*†Bunny, J. Brice, L.R.C.P.Ed., Bishop's Lydeard, Taunton.

1877† Burd, Edward, M.D., M.C., Senior Physician to the Salop Infirmary; Newport House, Shrewsbury. *Council*, 1886-7.

1894 Burt, Robert Francis, M.B., C.M.Edin., 76, Stapleton Hall road, Stroud Green, N.

1878 Butler-Smythe, Albert Charles, F.R.C.S.Ed., Surgeon to Out-patients, Samaritan Free Hospital; 76, Brook street, Grosvenor square, W. *Council*, 1889-91, 1904. *Vice-Pres.* 1905–7.

1887* Buxton, Dudley W., M.D.Lond., 82, Mortimer street, Cavendish square, W.

Elected

1886† Byers, Sir John W., Kt., M.A., M.D., M.A.O. (Hon. Causâ), Professor of Midwifery and Diseases of Women and Children at Queen's College, and Physician for Diseases of Women to the Royal Hospital, Belfast; Dreenagh House, Lower crescent, Belfast. *Vice-Pres.* 1899-1902.

1891† Calthrop, Lionel C. Everard, M.B.Durh., Queen street, Droitwich, Worcestershire.

1887† Cameron, James Chalmers, M.D., Professor of Midwifery and Diseases of Infancy, McGill University; 605, Dorchester street, Montreal.

1887† Cameron, Murdoch, M.D.Glas., Regius Professor of Midwifery in the University of Glasgow, 7, Newton terrace, Charing Cross, Glasgow. *Council*, 1903–5.

1903† Cameron, Samuel James Murdoch, M.B., Ch.B.Glasg., 13, Sandyford place, Glasgow, W.

1902 Campbell, Janet, M.B., B.S.Lond., 86, Campden Hill Court, Kensington.

1894† Campbell, John, M.A., M.D.Dubl., F.R.C.S., Crescent House, University road, Belfast.

1888*†Campbell, William Macfie, M.D. Edin., The Old House, Grassendale, Liverpool.

1903 Chadburn, Maud Mary, M.D.Lond., Surgeon to the Outpatient Department, New Hospital for Women; 16, Harley street, W.

1876* Champneys, Francis Henry, M.A., M.D. Oxon., F.R.C.P., Physician-Accoucheur to, and Lecturer on Midwifery at, St. Bartholomew's Hospital; 42, Upper Brook street, W. *Council*, 1880-1, 1900-1. *Hon. Lib.* 1882-3. *Hon. Sec.* 1884-7. *Vice-Pres.* 1888-90. *Board Exam. Midwives*, 1883, 1888-90; *Chairman*, 1891-5. *Editor*, 1888-93. *Pres.* 1895-6. *Treas.* 1902. *Trans.* 16. *Trustee.*

1874*†Charlesworth, James, M.D., Physician to the North Staffordshire Infirmary; 25, Birch terrace, Hanley, Staffordshire.

Elected

1897† Chinery, Edward Fluder, F.R.C.S.Edin., Monmouth House, Lymington, Hants.

1863*†Chisholm, Edwin, M.D., 44, Roslyn gardens, Sydney, New South Wales.

1893 Clarke, W. Bruce, F.R.C.S., Assistant Surgeon to St. Bartholomew's Hospital, 51, Harley street, W.

1899 Clayton, Charles Hollingsworth, L.R.C.P., 10, College terrace, Belsize park, N.W.

1903† Clayton, John Hazelwood, M.B.Lond., 16, Hagley road, Edgbaston, Birmingham.

1906† Clifford, Harold, M.B.Lond., F.R.C.S.Edin., 15, St. John street, Manchester.

1906 Clutterbuck, Lewis Augustus, M.D.Durh., 43, Welbeck street, W.

1865*†Coates, Charles, M.D., Physician to the Bath General and Royal United Hospitals; 10, Circus, Bath.

1875* Coffin, Richard Jas. Maitland, F.R.C.P.Ed., 94 Sinclair road, W.

1905† Cohen, Rachel, M.B.Calc., F.R.C.S.I., 24, Chowringhi, Calcutta, India.

1905† Collins, Victor Evelyn, M.D.Lond., Simonstown, Cape Colony.

1888 Cooper, Peter, L.R.C.P.Lond., Stainton Lodge, 35, Shooter's Hill road, Blackheath, S.E.

1875*†Cordes, Aug., M.D., M.R.C.P., Consulting Accoucheur to the "Miséricorde;" Privat Docent for Midwifery at the University of Geneva; 12, Rue Bellot, Geneva. *Trans.* 1.

1883 *Corner, Cursham, L.S.A., 113, Mile End road, E.

1903 Corthorn, Alice Mary, M.B., B.S.Lond., 30, St. Mary Abbot's terrace, Kensington.

1893 Cripps, William Harrison, F.R.C.S., Surgeon to St. Bartholomew's Hospital; 2, Stratford place, W. *Trans.* 2.

1889† Croft, Edward Octavius, M.D.Durh., Hon. Surgeon to the Hospital for Women and Children; Hon. Demonstrator of Obstetrics to the Yorkshire College, Leeds; 33, Park square, Leeds. *Trans.* 1.

Elected

1881*†Cronk, Herbert George, M.B.Cantab., Repton, near Burton-on-Trent.

1893 Crosby, Herbert Thomas, M.A., M.B., B.C.Cantab., 19, Gordon square, W.C.

1895 Cross, Ernest W., L.R.C.P.Lond., The Limes, Wallwood park, Leytonstone.

1886*†Cross, William Joseph, M.B., Horsham, Victoria, Australia.

1898† Cullen, Thomas, M.D.Toronto, Johns Hopkins Hospital, Baltimore, U S.A.

1875* Cullingworth, Charles James, M.D., D.C.L., LL.D., F.R.C.P., Consulting Obstetric Physician to St. Thomas's Hospital; 14, Manchester square, W. *Council*, 1883-5, 1891-3, 1904-7. *Vice-Pres.* 1886-8. *Board Exam. Midwives*, 1889-91. *Chairman*, 1895-6. *Pres.* 1897-8. *Trans.* 14.

1905 Currie, George Burnett, M.D.Aber., St. James's avenue, Ealing, W.

1889*†Cursetji, Jehángir J., M.D. Brux., 77A, Gowalia Junk road, Bombay.

1894 Cutler, Lennard, L.R.C.P.Lond., 1, Kensington Gate, Kensington, W. *Trans.* 1.

1885 Dakin, William Radford, M.D., B.S., F.R.C.P., Obstetric Physician to, and Lecturer on Midwifery at, St. George's Hospital; 8, Grosvenor street, W., *Council*, 1889-91. *Hon. Lib.* 1892-3. *Hon. Sec.* 1894-7. *Vice-Pres.* 1898-1901. *Chairman*, 1901–4. *Trans.* 3. *Pres.* 1905–6.

1868 Daly, Frederick Henry, M.D., 185, Amhurst road, Hackney Downs, N.E. *Council*, 1877-9. *Vice-Pres.* 1883-5. *Trans.* 2.

1901 Daly, Frederick James Purcell, L.R.C.P.Lond., 188, Upper Clapton road, N.E.

1904† Das, Kedarnath, L.M.S., M.B.Cal., M.D.Madras, Campbell Hospital, Calcutta.

Elected

1893 Dauber, John Henry, M.A.Oxon., M.B., B.Ch., Physician to the Hospital for Women, Soho square; 39, Hertford street, Mayfair, W.

1906† Davidson, H. Stevenson, M.B., Ch.B.Edin., 4, Dundas street, Edinburgh.

1892† Davis, Robert, M.R.C.S., Darrickwood, Orpington, Kent.

1891 Dawson, Ernest Rumley, L.R.C.P.Lond., 4, Grange Park road, Leyton, E. *Council*, 1904-6. *Trans.* 1.

1889 Des Vœux, Harold A., M.D.Brux., 214, Buckingham gate, S.W. *Council*, 1896-8.

1894 Dickinson, Thomas Vincent, M.D.Lond., M.R.C.P., Physician to the Italian Hospital, Queen square; 33, Sloane street, S.W. *Council*, 1900-2.

1894 Dickson, John William, B.A., M.B., B.C.Cantab., 42, Hertford street, Mayfair, W.

1907 Dodd, Stanley, M.B., B.C.Cantab., 11, Wimpole street, W.

1886† Donald, Archibald, M.D.Edin., M.R.C.P., Obstetric Physician to the Royal Infirmary, Manchester; Honorary Surgeon to St. Mary's Hospital for Women, Manchester; Sunnyside, Victoria park, Manchester. *Council*, 1893-5. *Trans.* 3.

1879* Doran, Alban H. G., F.R.C.S., Surgeon to the Samaritan Free Hospital; 9, Granville place, Portman square, W. *Council*, 1883-5. *Hon. Lib.* 1886-7. *Hon. Sec.* 1888-91. *Vice-Pres.* 1892-4. *Pres.* 1899-1900. *Trans.* 24.

1890† Douty, Edward Henry, M.D., M.C.Cantab., F.R.C.S. Eng., Surgeon to the Queen Victoria Hospital, La Madeleine, Cannes; (*Summer*, 7, rue St. Roch., Paris).

1887 Dovaston, Milward Edmund, M.R.C.S., Hatchcroft house, Hendon, N.W.

1899† Down, Elgar, L.R.C.P.Lond., Wingfield House, Stoke, Devonport.

1896 Downes, J. Lockhart, M.B., C.M.Edin., 269, Romford road, E.

Elected

1884† Doyle, E. A. Gaynes, L.R.C.P., The Shrubbery, San Fernando, Trinidad, West Indies.

1906 Drew, Douglas, B.S., F.R.C.S.Eng., 6, Wimpole street, W.

1894† Drew, Henry William, F.R.C.S., Eastgate, East Croydon.

1883 Duncan, Alexander George, M.B., Calton House, Amhurst park, Stamford hill, N.

1871* Eastes, George, M.B., F.R.C.S., 35, Gloucester terrace, Hyde park, W. *Council*, 1878-80, 1906-7.

1883† Eccles, F. Richard, M.D., Professor of Gynæcology, Western University; 1, Ellwood place, Queen's avenue, London, Ontario, Canada.

1893* Eden, Thomas Watts, M.D.Edin., M.R.C.P.Lond., Assistant Obstetric Physician to, and Lecturer on Practical Midwifery at, Charing Cross Hospital, 26, Queen Anne street, W. *Council*, 1897-9, 1905-7. *Board Exam. Midwives*, 1903–5. *Trans.* 5.

1903† Edge, Frederick, M.D.Lond., F.R.C.S.Eng., 54, Darlington street, Wolverhampton.

1873*†Engelmann, George Julius, A.M., M.D., 336, Beacon street, Boston, Mass., U.S.A.

1907 Engineer, Sorab Kaikhoshru, M.R.C.P.Ed., L.M.&S. Bombay, 39, Marine Lines, Fort, Bombay.

1905 English, Thomas Crisp, M.B.Lond., F.R.C.S., 47, Upper Brook street, W.

1897 Evans, Evan Laming, M.B., B.C.Cantab., F.R.C.S., 36, Bryanston street, Great Cumberland place, W.

1875† Ewart, John Henry, M.R.C.S., L.R.C.P., Eastney, Devonshire place, Eastbourne. *Council*, 1904-6.

1899 Fairbairn, John Shields, M.B., B.Ch.Oxon., Assistant Obstetric Physician to St. Thomas's Hospital, 42, Wimpole street, W. *Council*, 1904-7. *Board Exam. Midwives*, 1904-5. *Trans.* 1.

1894 Fairweather, David, M.A., M.D., C.M.Edin., Alderman's hill, Palmer's green, N.

Elected

1876† Farncombe, Richard, M.D.Brux., 183, Belgrave road, Balsall heath, Birmingham.

1903† Farncombe, William Turberville, M.D., Harborne, Birmingham.

1869* Farquhar, William, M.D., Deputy Surgeon-General, 40, Westbourne gardens, Bayswater, W.

1882† Farrar, Joseph, M.D., Gainsborough. *Trans.* 1.

1894† Fazan, Charles Herbert, L.R.C.P.Lond., Belmont, Wadhurst, Sussex.

1868* Fegan, Richard, M.D., Westcombe park, Blackheath, S.E.

1883 Fenton, Hugh, M.D., Physician, Chelsea Hospital for Women; 27 George street, Hanover square, W.

1893† Finley, Harry, M.D.Lond., West Malvern, Worcestershire,

1877*†Fonmartin, Henry de, M.D., 26, Newberry terrace, Lower Bullar street, Nichols Town, Southampton.

1897† Fothergill, W. E., M.B., C.M.Edin., Lecturer on Midwifery and Diseases of Women, Victoria University; Assistant Physician Northern Hospital for Women and Children, Manchester; 13, St John Street, Manchester.

1884 Fouracre, Robert Perriman, M.R.C.S., 89, Tollington park, N.

1886† Fowler, Charles Owen, M.D., Cotford House, Thornton heath. *Council*, 1901–3.

1898† Frampton, Trevethan, M.R.C.S., F.R.C.P., 15, Brunswick square, Brighton.

1875*†Fraser, Angus, M.D., Physician and Lecturer on Clinical Medicine to the Aberdeen Royal Infirmary; 232, Union street, Aberdeen. *Council*, 1897-1900.

1888† Fraser, James Alexander, L.R.C.P.Lond., Western Lodge, Romford.

1902† Freeland, Arthur Raymond Stilwell, L.R.C.P., M.R.C.S., The Green Hall, Ashbourne, Derbyshier.

Elected

1905 Fuller, Arthur W., M.D.Edin., 32, Old Burlington street, W.

1883* Fuller, Henry Roxburgh, M.D.Cantab., 45, Curzon street, Mayfair, W. *Council*, 1893. *Trans.* 1.

1905 Fuller, J. Reginald, M.D.Durh., 6, Crescent road, Crouch End, N.

1886† Furner, Willoughby, F.R.C.S., 13, Brunswick square, Brighton. *Council*, 1894-6.

1874* Galabin, Alfred Lewis, M.A., M.D., F.R.C.P., Obstetric Physician to, and Lecturer on Midwifery at, Guy's Hospital; 49, Wimpole street, Cavendish square, W. *Council*, 1876-8. *Hon. Lib.* 1879. *Hon. Sec.* 1880-3. *Vice-Pres.* 1884. *Treas.* 1885-8. *Pres.* 1889-90. *Trans.* 12.

1888† Galloway, Arthur Wilton, L.R.C.P.Lond., Malverns, Epping.

1863* Galton, John H., M.D., Chunam, Sylvan road, Upper Norwood, S.E. *Council*, 1874-6, 1891-2. *Vice-Pres.* 1895-8.

1881 Gandy, William, M.R.C.S., Hill Top, Central hill, Norwood, S.E. *Council*, 1897-8.

1886*†Garde, Henry Croker, F.R.C.S.Edin., Maryborough, Queensland.

1887 Gardiner, Bruce H. J., M.D., Gloucester House, Barry road, East Dulwich, S.E.

1879 Gardner, John Twiname, 5, Embankment gardens, Chelsea, S.W.

1872*†Gardner, William, M.A., M.D., Professor of Gynæcology. McGill University; Gynæcologist to the Royal Victoria Hospital; 109, Union avenue, Montreal, Canada.

1873*†Garton, William, M.D., F.R.C.S., Inglewood, Aughton, near Ormskirk.

1901 Gayer, Reginald Courtenay, L.R.C.P., 33, Stanhope gardens, South Kensington, S.W.

Elected

1889* Gell, Henry Willingham, M.A., M.B.Oxon., 24, Palace court, W.

1898*†Gemmell, John Edward, M.B., C.M.Edin., Hon. Surgeon to the Hospital for Women, Liverpool; 12, Rodney street, Liverpool.

1859*†Gervis, Henry, M.D., F.R.C.P., Consulting Obstetric Physician to St. Thomas's Hospital; 15, Royal Cresent, Bath. *Council*, 1864-6, 1889-91, 1893. *Hon. Sec.* 1867-70. *Vice-Pres.* 1871-3. *Treas.* 1878-81. *Pres.* 1883-4. *Trans.* 8.

1866* Gervis, Frederick Heudebourck, M.D.Brux., 1, Fellows road, Haverstock hill, N.W. *Council*, 1877-9. *Vice-Pres.* 1892. *Trans.* 1.

1899† Gervis, Henry, M.A., M.B., B.C.Cantab., 74, Dyke road, Brighton.

1883* Gibbons, Robert Alexander, M.D., Physician to the Grosvenor Hospital for Women and Children; 29, Cadogan place, S.W. *Council*, 1889-90. *Trans.* 1.

1894 Gibson, Henry Wilkes, L.R.C.P.Lond., 6, College terrace, Fitzjohn's avenue, N.W.

1892 Giles, Arthur Edward, M.D.Lond., M.R.C.P., Physician to Out-patients, Chelsea Hospital for Women; 10, Upper Wimpole street, W. *Council*, 1898-1900. *Trans.* 7.

1891† Gimblett, William Henry, M.D.Durh., 64, Sutherland avenue, W.

1899† Glover, Thomas Anderson, M.D., C.M.Edin., 24, Hallgate, Doncaster.

1894† Goddard, Charles Ernest, M.D., Wembley, Harrow.

1871 *Godson, Clement, M.D., C.M.; 82, Brook street, W. *Council*, 1876-7. *Hon. Sec.* 1878-81. *Vice-Pres.* 1882-4. *Board Exam. Midwives*, 1877, 1882-86. *Trans.* 5.

1893† Gordon, Frederick William, L.R.C.P.Lond., Manukau road, Auckland, New Zealand.

Elected

1883 GORDON, JOHN, M.D., 49, Newgate street, E.C.

1869† GOSS, TREGENNA BIDDULPH, M.R.C.S., 1, The Circus, Bath. *Hon. Loc. Sec.*

1891† GOSTLING, WILLIAM AYTON, M.D., B.S.Lond., Barningham, West Worthing.

1889 GOULLET, CHARLES ARTHUR, L.R.C.P.Lond., 2, Finchley road, N.W. *Council* 1902–5.

1890 GOW, WILLIAM JOHN, M.D.Lond., Physician-Accoucheur in charge of Out-patients, St. Mary's Hospital; 27, Weymouth street, W. *Council*, 1893-5-1901. *Board Exam. Midwives*, 1898-1900-1. *Hon. Lib.*, 1906-7. *Trans.* 2.

1893† GOWAN, BOWIE CAMPBELL, L.R.C.P.Lond., Raven Dene, Great Stanmore.

1907 GRAHAM, LEWIS, B.S.Lond., M.R.C.S., L.R.C.P., Hospital for Women, Soho square, W.

1893 GRANT, LEONARD, M.D.Edin., Hillside, New Southgate, N.

1907 GRAY, ARCHIBALD MONTAGUE HENRY, M.D., B,S.Lond., University College Hospital, W.C.

1902† GRECH, SALVATORE, M.D.Malta, Professor of Obstetrics in the University of Malta; Accoucheur and Gynæcologist and Teacher of Practical Midwifery at the Central Civil Hospital; 31, Strada Mezzodi, Valetta, Malta.

1894† GREEN, CHARLES ROBERT MORTIMER, M.D., F.R.C.S.Eng. Lieut.-Colonel, Indian Medical Service, c/o Thomas Cook and Sons, Ludgate Circus, E.C.

1863 *GRIFFITH, G. DE GORREQUER, M.R.C.S., L.R.C.P., 34, St. George's square, S.W. *Trans.* 2.

1879* GRIFFITH, WALTER SPENCER ANDERSON, M.D.Cantab., F.R.C.S., F.R.C.P., Assistant Physician-Accoucheur to St. Bartholomew's Hospital; 96, Harley street, W. *Council*, 1886-8, 1893-5, 1901–3. *Hon. Lib.* 1896-7. *Board Exam. Midwives*, 1887-9. *Trans.* 11.

Elected

1888*†Grimsdale, Thomas Babington, B.A., M.B.Cantab., Gynæcological Surgeon to the Royal Infirmary, Liverpool, 29, Rodney street, Liverpool.

1880 Grogono, Walter Atkins, M.R.C.S., L.R.C.P., Witham Lodge, 171, Romford road, Stratford, E.

1896† Groves, Ernest W. Hey, M.B., B.Sc., 16, Richmond Hill, Clifton. *Trans.* 1.

1894 Hamilton, Bruce, L.R.C.P.Lond., Glenbrook, 5, Crediton road, West Hampstead, N.W.

1887† Hamilton, John, F.R.C.S.Ed., Beechhurst House, Swadlincote, Burton-on-Trent.

1906 Hamilton, William Gavin, Capt. I.M.S., M.R.C.S.& L.R.C.P.Lond., c/o Messrs. Grindlay, Groom and Co., Bombay.

1883* Handfield-Jones, Montagu, M.D.Lond., F.R.C.P., Physician-Accoucheur to, and Lecturer on Midwifery and Diseases of Women at, St. Mary's Hospital; 35, Cavendish square, W. *Council*, 1887-9, 1896-7. *Board Exam. Midwives*, 1894-6. *Hon. Lib.* 1900-3. *Hon. Sec.* 1902–5. *Vice.-Pres.* 1906-7. *Trans.* 1.

1901 Handley, William Sampson, M.S., M.D.Lond., F.R.C.S.Eng., 77, Wimpole street, W. *Council*, 1905–6. *Trans.* 2.

1906† Harke, Sydney L., L.R.C.P., 17, Park hill road, Croydon.

1892 Harold, John, M.B., B.Ch., B.A.O., 91, Harley street, W.

1877 Harper, Gerald S., M.B.Aber., 40, Curzon street, Mayfair, W. *Council*, 1894-5.

1898† Harper, John Robinson, L.R.C.P., Bear street, Barnstaple, Devon.

1878† Harries, Thomas Davies, F.R.C.S., Grosvenor House, Aberystwith, Cardiganshire.

1867*†Harris, William H., M.D., Deputy Surgeon-General, Shirley, Parklands, Surbiton.

Elected

1880* Harrison, Richard Charlton, M.R.C.S., L.R.C.P., 33, Uxbridge road, Ealing, W.

1890† Hart, David Berry, M.D.Edin., Assistant Gynæcologist, Royal Infirmary, Edinburgh; 13, Charlotte square, Edinburgh. *Council* 1902–5.

1886† Hartley, Horace, L.R.C.P.Ed., Stone, Staffordshire.

1893 Harvey, John Jordan, L.R.C.P. & S.Edin., The Aviary, Canning Town, E.

1880 Harvey, John Stephenson Selwyn, M.D.Durh., M.R.C.P., 1, Astwood road, Cromwell road, S.W.

1907 Hastings, Somerville, M.B., B.S., 35, Welbeck street, Cavendish square, W.

1905† Haultain, Francis William Nicol, M.D., F.R.C.P.Edin., 12, Charlotte square, Edinburgh.

1899† Hawes, Godfrey Charles Browne, L.R.C.P., The Red House, West road, Guildford.

1899*†Hawkes, Claude Somerville, L.R.C.P., F.R.C.S.E., Glencairn, Wickham Terrace, Brisbane, Queensland.

1893† Haydon, Thomas Horatio, M.B., B.C. Cantab., 22, High street, Marlborough.

1900† Hayford, Ernest James, M.D., c/o The Agent, Claude's Ashanti Goldfields, Ltd., Cape Coast Castle, Gold Coast, West Africa.

1901† Haynes, Edward James Ambrose, F.R.C.S.I., Weetalabah, Hay street west, Perth, Western Australia.

1907 Hedley, John Prescott, M.B., B.C.Cantab., 11, John street, Berkeley square, W.

1903† Heilborn, William Ernest, M.B., B.Ch.Cantab., 6, Walmer place, Bradford, Yorks.

1892† Hellier, John Benjamin, M.D.Lond., Lecturer on Diseases of Women and Children, Yorkshire College; Hon. Obstetric Physician to Leeds Infirmary; 27, Park square, Leeds. *Council*, 1906-7.

Elected

1890† Helme, T. Arthur, M.D.Edin., M.R.C.P., Hon. Surgeon for Women to the Northern Hospital for Women and Children, Manchester, 3, St. Peter's square, Manchester.

1867† Hembrough, John William, M.D., St. Nicholas Chambers, Newcastle-on-Tyne.

1906† Henchley, Albert Richard, M.D.Brux., L.R.C.P.&S. Edin., 1, London road, Canterbury.

1876* Herman, George Ernest, M.B., F.R.C.P., Consulting Obstetric Physician to the London Hospital; 20, Harley street, Cavendish square, W. *Council*, 1878-9, 1898-1901. *Hon. Lib.* 1880-1. *Hon. Sec.* 1882-5. *Vice-Pres.* 1886-7. *Board Exam. Midwives*, 1886-8. *Treas.* 1889-92, 1903-7. *Pres.* 1893-4. *Trans.* 35.

1903 Hicks, Henry Thomas, F.R.C.S.Eng., 15, Portman street, W. *Council* 1907.

1901† Hilliard, Francis Porteus Tyrrell, M.A., M.B.Oxon., St. Giles' Hill, Winchester.

1886† Holberton, Henry Nelson, L.R.C.P.Lond., East Molesey.

1906 Holland, Eardley L., M.B., B.S.Lond., F.R.C.S.Eng., Hospital for Women, Soho.

1891† Holman, Robert Colgate, M.R.C.S., Whithorne House, Midhurst, Sussex.

1864* Hood, Wharton Peter, M.D., 11, Seymour street, Portman square, W.

1906 Hope, George, D.P.H., L.R.C.P., M.R.C.S.Lond., Beaconsfield House, 47, Uxbridge road, Hanwell, W.

1896† Hopkins, George Herbert, F.R.C.S., 3, North Quay, Brisbane, Queensland.

1905† Hopkins, Lionel Gordon, M.D.Lond., "The Leas," Westcliffe-on-Sea, Essex.

Elected

1883* Horrocks, Peter, M.D., F.R.C.P.Lond., Obstetric Physician to Guy's Hospital; 42, Brook street, W. *Council*, 1886-7. *Hon. Lib.* 1888-9. *Hon. Sec.* 1890-3. *Vice-Pres.* 1894-6. *Pres.* 1901–2. *Trans.* 2.

1876 Horsman, Godfrey Charles, L.S.A., 22, King street, Portman square, W.

1883 Hoskin, Theophilus, L.R.C.P.Lond., 1, Amhurst park, N.

1879† Hubbard, Thomas Wells, L.R.C.P., L.R.C.S., Barming place, Maidstone.

1901 Humphreys, Francis Rowland, L.R.C.P.Lond., 2, Chalcot gardens, England lane, South Hampstead, N.W.

1884*†Hurry, Jamieson Boyd, M.D.Cantab., 43, Castle street, Reading. *Council*, 1887-9, 1907. *Vice.-Pres.* 1897-1900. *Trans.* 2.

1878*†Husband, Walter Edward, M.R.C.S., L.R.C.P., Grove Lea, Lansdown, Bath.

1895 Huxley, Henry, L.R.C.P.Lond., 39, Leinster gardens, Hyde park, W.

1904† Illington, Edmund Moritz, Capt. I.M.S., L.R.C.P., c/o Surgeon-General, with the Government of Madras, Madras.

1894† Ilott, Herbert James, M.D.Aber., 57, High street, Bromley, Kent.

1901† Inglis, Arthur Stephen, M.D.Aber., 2, East ascent, St. Leonards-on-sea.

1902† Inglis, John, M.D., 14, Eversfield place, St. Leonards-on-Sea.

1907 Ingram, Percy Cecil Parker, M.B., B.S.Lond., St. George's Infirmary, Fulham road, S.W.

1902† Ionides, Theodore Henry, M.B., B.S.Lond., 25, First avenue, Brighton.

Elected

1903 IRONSIDE, ROBERT ADRIAN, M.D., C.M.Aber., Campbell House, Fitzjohn's avenue, N.W.

1884*†IRWIN, JOHN ARTHUR, M.A., M.D., 14, West Twenty-ninth street, New York.

1904 IVENS, MARY H. FRANCES, M.B., M.S.Lond., Honorary Medical Officer for the Diseases of Women, Stanley Hospital, Liverpool, 1A, Rodney Street, Liverpool.

1897 JÄGER, HAROLD, M.B.Lond., 172, Holland park avenue, W.

1890† JAMES, CHARLES HENRY, L.R.C.P.Lond., Major, Indian Medical Service; Patiala, Punjab, India.

1883*†JENKINS, EDWARD JOHNSTONE, M.D.Oxon., 213, Macquarie street, Sydney.

1882*†JENNINGS, CHARLES EGERTON, M.D.Durh., F.R.C.S.Eng., Assistant Surgeon to the North-West London Hospital; The Red House, Great Somerford, Wilts.

1901*†JOHNSON, EDWARD ANGUS, M.B., B.S.Melb., L.R.C.P. Lond., "St. Catharine's" Prospect, South Australia.

1868† JONES, EVAN, M.R.C.S., Ty-Mawr, Aberdare, Glamorganshire. *Council*, 1886-8. *Vice.-Pres.* 1890-1.

1894 JONES, EVAN, L.R.C.P.Lond., 89, Goswell road, E.C

1902† JONES, EVAN JAMES TREVOR, M.D.Brux., Ty-Mawr, Aberdare, Glamorganshire.

1895† JONES, GEORGE HORATIO, M.R.C.S., Deddington, Oxon.

1894† JONES, JOHN ARNALLT, M.D.Durh., Heathmont, Aberavon, Port Talbot, Glamorganshire.

1886† JONES, WILLIAM OWEN, M.R.C.S., The Downs, Bowdon, Cheshire.

1903† JORDAN, JOHN FURNEAUX, M.B., F.R.C.S., Surgeon to the Birmingham Hospital for Women, 9, Newhall street, Birmingham.

1883† KEELING, JAMES HURD, M.D., 267, Glossop road, Sheffield.

Elected

1896 KEEP, ARTHUR CORRIE, M.D., C.M.Edin., Surgeon to Out-patients to the Samaritan Free Hospital; 14, Gloucester place, Portman square, W. *Council*, 1902-4.

1894 KELLETT, ALFRED FEATHERSTONE, M.B., B.C.Cantab., 39, Granville park, Blackheath, S.E.

1886 KENNEDY, ALFRED EDMUND, L.R.C.P.Ed., Chesterton House, Plaistow, E.

1879 KER, HUGH RICHARD, L.R.C.P.Ed., Tintern, 2, Balham hill, S.W.

1895† KERR, JOHN MARTIN MUNRO, M.B., C.M.Glasg.; Obstetric Physician to the Glasgow Maternity Hospital; 28. Berkeley terrace, Glasgow. *Council*, 1906-7. *Trans.* 2.

1907 KERRAWALLA, MANECXJI PIROSHAW, M.D.Brux., L.M.&S. Bombay, 22, Oxford street, W.

1877*†KERSWILL, JOHN BEDFORD, M.R.C.P.Ed., Fairfield, St. German's, Cornwall.

O.F.* KIALLMARK, HENRY WALTER, M.R.C.S., 5, Pembridge gardens, Bayswater. *Council*, 1879-80.

1872* KISCH, ALBERT, M.R.C.S., 61, Portsdown road, W. *Council*, 1896-7.

1876*†KNOTT, CHARLES, M.R.C.P.Ed., Liz Ville, Elm grove, Southsea.

1889 LAKE, GEORGE ROBERT, M.R.C.S., 177, Gloucester terrace, Hyde park, W.

1867* LANGFORD, CHARLES P., M.R.C.S., Sunnyside, Hornsey lane, N.

1894† LEA, ARNOLD W. W., M.D., B.S.Lond., F.R.C.S., Lecturer on Midwifery and Diseases of Women, Owens College, 274, Oxford road, Manchester. *Council*, 1903-6. *Trans.* 2.

1901 LEAHY-LYNCH, TIMOTHY, L.R.C.P., L.M.Edin., 2, Finsbury park road, N.

1905 LEAKEY, ALEXANDER B., M.B., B.Ch.Edin., 84, Pine road, Cricklewood, N.W.

Elected

1884*†Lediard, Henry Ambrose, M.D., 26, Lowther street, Carlisle. *Council*, 1890-2. *Trans.* 1.

1903† Leicester, John Cyril Holdich, M.D., B.S., F.R.C.S. Eng., Captain, Indian Medical Service, c/o Messrs. Grindlay & Co., Calcutta. *Trans.* 1.

1902† Lendon, Alfred Austin, M.D.Lond., Lecturer on Obstetrics in the University of Adelaide, North terrace, Adelaide, South Australia.

1897 Leslie, William Murray, M.D.Edin., 74, Cadogan place, Belgrave square, S.W.

1900*†Levison, Hugo Adolf, M.D.(Columbia Univ.), L.R.C.P. Lond., 44, West 35th street, New York.

1885* Lewers, Arthur H. N., M.D.Lond., F.R.C.P., Obstetric Physician to, and Lecturer on Midwifery at the London Hospital; 43, Upper Brook street, W. *Council*, 1887-9, 1893, 1901-3. *Board Exam. Midwives*, 1895-7. *Hon. Lib.* 1904–5. *Hon. Sec.* 1906-7. *Trans.* 13.

1902 Lewis, Ernest Wool, L.R.C.P., M.R.C.S., The Hermitage, Fulham Palace road, S.W.

1901† Littlewood, Harry, F.R.C.S., 25, Park square, Leeds. *Trans.* 1.

1894 Livermore, William Leppingwell, L.R.C.P.Lond., 52, Stapleton Hall road, Stroud Green, N.

1899 Lockyer, Cuthbert, M.D., B.S.Lond., F.R.C.S., 117A, Harley street, W. *Council*, 1904–7. *Board Exam. Midwives*, 1905. *Trans.* 6.

1905† Longridge, Charles John Nepean, M.D.Vict., F.R.C.S. Eng., 30, Wimpole street, W.

1893† Lowe, Walter George, M.D.Lond., F.R.C.S., Burton-on-Trent.

1878*†Lycett, John Allan, M.D., Consulting Gynæcologist to the Wolverhampton and District Hospital for Women; "Gatcombe," Clifton road, Tettenhall, near Wolverhampton.

Elected

1905*†Lyle, Robert Patton Ranken, M.D.Dubl., 11, Ellison place, Newcastle-on-Tyne.

1902† Lynn, Edward, M.R.C.S., 638, Woolwich road, New Charlton, Kent.

1890 McCann, Frederick John, M.D., C.M.Edin., F.R.C.S. Eng., M.R.C.P., Physician to In-patients at the Samaritan Hospital; 5, Curzon street, Mayfair, W. *Council*, 1897-8. *Board Exam. Midwives*, 1904–5. *Trans.* 3.

1894† McCausland, Albert Stanley, M.D.Brux., Churchill House, Swanage.

1894† McDonnell, Æneas John, M.D., Ch.M.Sydney, Rathdonnell, Toowoomba, Queensland.

1906† McIlroy, Louise, M.D., Gynæcologist to the Glasgow Victoria Infirmary; 26, Sandyford place, Glasgow. *Trans.* 1.

1892† McKay, W. J. Stewart, M.B., M.Ch.Sydney, Australian Club, Macquarie street, Sydney, N.S.W.

1897† McKerron, Robert Gordon, M.B.Aberd., 1, Albyn place, Aberdeen. *Trans.* 2.

1900† Macan, Jameson John, M.A., M.D.Cantab., Crossgates, Cheam, Surrey.

1893† Maclean, Ewen John, M.D., F.R.S.Edin., M.R.C.P.Lond., Senior Gynæcologist to Cardiff Infirmary; 12, Park place, Cardiff. *Council*, 1900.

1899 Macleod, William Aitken, M.B., C.M.Edin., 9, Pembridge villas, Bayswater, W.

1878*†Macnaughton-Jones, H., M.D., M.A.O. (Hon. Causâ), F.R.C.S.I. & Edin., 131, Harley street, Cavendish square, W. *Trans.* 1.

1894† McOscar, John, L.R.C.P.Lond., Bridge House, Spring gardens, Buxton.

1905 McQueen, Robert Martin, L.R.C.P.Lond., M.R.C.S., 89, Eaton terrace, S.W.

Elected

1899† MAGUIRE, GEORGE J., M.B., B.Ch., "Fulwood," Kew gardens, S W. *Trans.* 1.

1895† MAIDLOW, WILLIAM HARVEY, M.D.Durh., F.R.C.S.Eng. Ilminster, Somerset.

1884* MALCOLM, JOHN D., M.B., C.M., Surgeon to the Samaritan Free Hospital; 13, Portman street, W. *Council*, 1894-6. *Trans.* 3.

1871†*MALINS, EDWARD, M.D., Consulting Obstetric Physician to the General Hospital, Professor of Midwifery in the University, Birmingham; 50, Newhall street, Birmingham. *Council*, 1881-3. *Vice-Pres.* 1884-6, 1901-2. *Pres.* 1903–4.

1903† MALINS, Herbert, B.A.Oxon., M.B.Edin., 64, Sutherland avenue, W.

1868*†MARCH, HENRY COLLEY, M.D., Portisham, Dorchester. *Council*, 1890-2.

1887 MARK, LEONARD P., M.D.Durh., 49, Oxford terrace, Hyde park, W.

1887† MARSH, O. E. BULWER, L.R.C.P.Ed., Parkdale, Clytha park, Newport, Monmouthshire.

1905† MARTEN, ROBERT HUMPHREY, M.B., B.C.Cantab., Adelaide.

1890† MARTIN, CHRISTOPHER, M.B., C.M.Edin., F.R.C.S.Eng., Surgeon to the Birmingham and Midland Hospital for Women; 35, George road, Edgbaston, Birmingham. *Trans.* 1.

1905† MASTERS, ALFRED THOMAS, L.S.A., Northridge, Northiam, Sussex.

1899† MAXWELL, JOHN PRESTON, M.B.Lond., F.R.C.S., E.P. Mission, Engchhun, Amoy, China. *Trans.* 1.

1904 MAXWELL, R. DRUMMOND, M.D.Lond., 102, Oxford gardens, North Kensington, W.

1890 MAY, CHICHESTER GOULD, M.A., M.D.Cantab., Assistant Physician to the Grosvenor Hospital for Women and Children; 59, Cadogan place, S.W.

Elected

1884† Maynard, Edward Charles, L.R.C.P.Ed., 39, Wynnstay gardens, Kensington.

1886 Mennell, Zebulon, M.R.C.S., 1, Royal crescent, Notting hill, W.

1898 Menzies, Henry, M.B.Cantab., 4, Ashley gardens, S.W.

1882 Meredith, William Appleton, M.B., C.M., F.R.C.S.Eng., Surgeon to the Samaritan Free Hospital for Women and Children; 21, Manchester square, W. *Council*, 1886-8. *Vice-Pres.* 1891-3. *Trans.* 3.

1893† Michie, Harry, M.B.Aber., 27, Regent street, Nottingham.

1875*† Miles, Abijah J., M.D., Professor of Diseases of Women and Children in the Cincinnati College of Medicine, Cincinnati, Ohio, U.S.

1902 Milligan, Wyndham Anstruther, M.A., M.D.Aber., F.R.C.S.Edin., 68, Park street, Grosvenor square, W.

1876*† Millman, Thomas, M.D., 490, Huron street, Toronto, Ontario, Canada.

1880*† Mills, Robert James, M.B., M.C., 35, Surrey street, Norwich.

1892† Milton, Herbert M. Nelson, M.R.C.S., Kasr-el-Aini Hospital, Cairo, Egypt.

1869*† Minns, Pembroke R. J. B., M.D., Thetford, Norfolk.

1903† Moore-Ede, William Edward, M.B., B.C.Cantab., 64, Jesmond road, Newcastle-on-Tyne.

1859† Moorhead, John, M.D., Surgeon to the Weymouth Infirmary and Dispensary, Royal Bath Hotel, Bournemouth.

1895† Morison, Henry Bannermann, M.B.Durh., Okehurst, Cranleigh, Surrey.

1890 Morris, Charles Arthur, C.V.O., M.A., M.B., M.C. Cantab., F.R.C.S., Surgeon to the Grosvenor Hospital for Women and Children, 28, Chester square, S.W.

1883* Morris, Clarke Kelly, M.R.C.S., Gordon Lodge, Charlton road, Blackheath, S.E.

Elected

1893† Morse, Thomas Herbert, F.R.C.S., All Saints' green, Norwich. *Trans.* 1.

1896 Mugford, Sidney Arthur, L.R.C.P., 135, Kennington park road, S.E.

1893 Muir, Robert Douglas, M.D., The Limes, New Cross road, S.E.

1885 Murray, Charles Stormont, L.R.C.S. and L.M.Ed., 85, Gloucester place, Portman square, W.

1896† Nariman, R. T., M.D.Brux., Parsi Lying-in Hospital, Bombay.

1902† Nariman, Temulfi Bhicafi, L.M.&F.Bombay, Bombay, India.

1892† Nash, W. Gifford, F.R.C.S., Senior Surgeon to the Bedford County Hospital, Clavering House, De Parys avenue, Bedford.

1902† Newland, H. Simpson, M.B.Adel., F.R.C.S.Eng., 12, North terrace, Adelaide, South Australia.

1889† Newnham, William Harry Christopher, M.A., M.B.Cantab., Physician-Accoucheur to the Bristol General Hospital; Chandos Villa, Queen's road, Clifton, Bristol.

1893† Nichol, Frank Edward, M.A., M.B., B.C.Cantab., 1, Ethelbert crescent, Margate.

1873† Nicholson, Arthur, M.B.Lond., 30, Brunswick square, Brighton. *Council*, 1897-9.

1904† Nicholson, Harry Oliphant, M.D.Edin., 20, Manor place, Edinburgh.

1876* Nix, Edward James, M.D., 11, Weymouth street, W. *Council*, 1889-90.

1903 Nolan, William, L.R.C.P. & S.I., L.M.Dubl., 20, Talbot road, Bayswater, W.

1903† Nott, Arthur Holbrook, M.B.Durh., Major, Indian Medical Service, c/o Messrs. Grindlay & Co., 54, Parliament street, S.W.

Elected

1904† Odgers, Norman Blake, M.B., B.Ch.Oxon, F.R.C.S.Eng., 16, Castilian street, S. Giles street, Northampton.

1905 Orr, William Robert, M.D., Coolard lodge, East Finchley, N.

1899† Osborn, Francis Arthur, L.R.C.P.Lond., Ennismore House, Dover.

1877† Osterloh, Paul Rudolph, M.D. Leipzic, Physician for Diseases of Women, Diaconissen Hospital; Wienerstrasse 8, Dresden.

1902 Oxley, Alfred James Rice, M.D.Dubl., 7, Courtfield road, S.W.

1889* Page, Harry Marmaduke, M.D.Brux., F.R.C.S., 14, Grenville place, S.W.

1877* Paramore, Richard, M.D., 2, Gordon square, W.C.

1867*†Parks, John, M.R.C.S., Bank House, Manchester road, Bury, Lancashire.

1887 Parsons, John Inglis, M.D.Durh., M.R.C.P., Physician to the Chelsea Hospital for Women, 3, Queen street, Mayfair, W. *Trans.* 2.

1904 Paterson, Herbert John, M.A., M.B., B.C.Cantab., F.R.C.S.Eng., 9, Upper Wimpole street, W.

1899 Paul, J. E., M.D., c/o Messrs. Parry and Co., 70, Gracechurch Street, E.C.

1902† Payne, Edward Marten, M.B., C.M., St. John's, Richmond terrace, Blackburn.

1882*†Peacey, William, M.D., Rydal Mount, St. John's road, Eastbourne.

1894 Peake, Solomon, M.R.C.S., 228, Goldhawk road, Shepherd's Bush, W.

1899† Peck, Francis Samuel, M.R.C.S.Eng., Major, Indian Medical Service; 6, Harington street, Calcutta.

1871* Pedler, George Henry, M.R.C.S., L.R.C.P., 6, Trevor terrace, Rutland gate, S.W. *Council*, 1897-8.

1880*†Pedley, Thomas Franklin, M.D., Rangoon, India. *Trans.* 1.

Elected

1898† PENNY, ALFRED GERVASE, M.A., M.B., B.C.Cantab. Rahere house, Clayfield, Brisbane, Queensland.

1881† PERIGAL, ARTHUR, M.D., New Barnet, Herts. *Council*, 1892–3.

1879*†PESIKAKA, HORMASJI DOSABHAI, 23, Hornby row, Bombay.

1894 PETTY, DAVID, M.B., C.M.Edin., 148, Stamford hill, N.

1903† PHILBRICK, JOHN HAROLD, M.B., B.Ch.Cantab. c/o Messrs. Grindlay & Co., Calcutta.

1879 PHILLIPS, GEORGE RICHARD TURNER, M.R.C.S., 33, Beaufort gardens, S.W. *Council*, 1891.

1882 PHILLIPS, JOHN, M.A., M.D.Cantab., F.R.C.P., Professor of Obstetric Medicine in King's College, and Obstetric Physician to King's College Hospital; 68, Brook street, W. *Council*, 1887-9, 1893. 1906. *Hon. Lib.* 1894-5. *Hon. Sec.* 1896-9. *Board Exam. Midwives*, 1892-4. *Vice-Pres.* 1900-3, 1907. *Chairman* 1905. *Trans.* 11.

1878* PHILPOT, JOSEPH HENRY, M.D., 61, Chester square, S.W. *Council*, 1891.

1889† PINHORN, RICHARD, L.R.C.P.Lond., 5, Cambridge terrace, Dover. *Council*, 1897-9.

1893 PLAYFAIR, HUGH JAMES MOON, M.D.Lond., Assistant Physician, Hospital for Women and Children, Waterloo road; 7, Upper Brook street, Grosvenor square, W. *Council*, 1900.

1891* POLLOCK, WILLIAM RIVERS, M.D., F.R.C.P., Obstetric Physician to the Westminster Hospital, 56, Park street, Grosvenor square, W. *Council*, 1895-7, 1902-4. *Board Exam. Midwives*, 1898-9. *Trans.* 1.

1891† POPE, HENRY SHARLAND, M.B., B.C.Cantab., Castle Bailey, Bridgwater.

1888* POPHAM, ROBERT BROOKS, F.R.C.P.Edin., L.R.C.P.Lond., "Endyon," 130, Argyle road, West Ealing, W

1903† POTTS, WILLIAM ALEXANDER, B.A.Cantab., M.D.Edin., 118, Hagley road, Birmingham.

Elected

1901 Powell, Llewellyn, M.B., B.C.Cantab., 58, New Cavendish street, W.

1886* Prangley, Henry John, L.R.C.P.Lond., Tudor House, 197, Anerley road, Anerley, S.E.

1880* Prickett, Marmaduke, M.A.Cantab., M.D., Physician to the Samaritan Hospital; 27, Oxford square, W. *Council*, 1892.

1895 Priestley, R. C., M.A., M.B.Cantab., 81, Linden gardens, Bayswater, W.

1905 Provis, Francis Lionel, F.R.C.S.Lond., 11, Brook street, Hanover square, W.

1898† Purslow, Charles Edwin, M.D., M.R.C.P.Lond., Honorary Obstetric Officer, Queen's Hospital, Birmingham; 192, Broad street, Birmingham.

1876*†Quirke, Joseph, M.R.C.P.Ed., The Oaklands, Hunter's road, Handsworth, Birmingham.

1878† Rawlings, John Adams, M.R.C.P.Ed., 14, Northampton place, Swansea.

1897† Rawlings, J. D., M.B.Lond., Rose Hill House, Dorking.

1870* Ray, Edward Reynolds, M.R.C.S., 15A, Upper Brook street, W. *Council*, 1902-4.

1894† Rayner, Herbert Edward, F.R.C.S., Diamond hill, Camberley, Surrey.

1899† Rayner, David Charles, F.R.C.S.Eng., 9, Lansdowne place, Victoria square, Clifton, Bristol.

1860* Rayner, John, M.D., Swaledale House, Highbury quadrant, N.

1879 Read, Thomas Laurence, M.R.C.S., 11, Petersham terrace, Queen's gate, S.W. *Council*, 1892.

1905† Rees, Rhys Basil, L.S.A.Lond., Priory house, Queen's crescent, N.W.

1879† Reid, William Loudon, M.D., Professor of Midwifery and Diseases of Women and Children, Anderson's College; Physician to the Glasgow Maternity Hospital; 7, Royal crescent, Glasgow. *Council*, 1899-1901-2.

Elected

1893† Renshaw, Israel James Edward, F.R.C.S.Edin., 26, Sefton road, Sale, Cheshire.

1875*†Rey, Eugenio, M.D., 39, Via Cavour, Turin.

1890 Reynolds, John, M.D.Brux., 11, Brixton hill, S.W.

1905† Rice, George, M.D.Durh., 46, Friar gate, Derby.

1905 Richardson, Martin James, M.B., C.M.Edin., 47, Gloucester place, Portman square, W.

1872*†Richardson, William L., M.D., A.M., Professor of Obstetrics in Harvard University; Physician to the Boston Lying-in Hospital; 225, Commonwealth avenue, Boston, Massachusetts, U.S.

1889† Richmond, Thomas, L.R.C.P.Ed., 4, Burnbank gardens, Glasgow.

1871* Rigden, Walter, M.D. St. And., 16, Thurloe place, S.W. *Council*, 1882-3. *Trans.* 1.

1892 Roberts, Charles Hubert, M.D.Lond., F.R.C.S.Eng., M.R.C.P., Physician to Out-patients to Queen Charlotte's Hospital; Physician to Samaritan Free Hospital for Women; 21, Welbeck street, Cavendish square. *Council*, 1897-9, 1905-7. *Board Exam. Midwives*, 1901. *Trans.* 4.

O.F.*† Roberts, David Lloyd, M.D., F.R.C.P., F.R.S.Edin., Consulting Obstetric Physician to the Manchester Royal Infirmary; and Lecturer on Clinical Midwifery and the Diseases of Women in Owens College; 11, St. John street, Deansgate, Manchester. *Council*, 1868-70, 1880-2. *Vice-Pres.* 1871-2. *Board Exam. Midwives*, 1900-4. *Trans.* 5.

1867* Roberts, David W., M.D., 56, Manchester street, Manchester square, W. *Council*, 1905.

1890† Roberts, Hugh Jones, M.R.C.S., Llywenarth, Penygroes, R.S.O., N. Wales.

1874* Robertson, William Borwick, M.D., St. Anne's, Thurlow park road, West Dulwich, S.E.

Elected

1892 Robinson, George H. Drummond, M.D., B.S.Lond., Assistant Obstetric Physician, West London Hospital; 17, Seymour street, Portman square, W. *Council*, 1899-1900. *Board Exam. Midwives*, 1898-1900. *Trans.* 2.

1887 Robinson, Hugh Shapter, L.R.C.P.Ed., Talfourd House, 78, Peckham road, Camberwell, S.E.

1876†*Roe, John Withington, M.D., Ellesmere, Salop.

1874*†Roots, William Henry, M.R.C.S., Canbury House, Kingston-on-Thames.

1903† Rose, Alexander Macgregor, M.B., Ch.B., The Mess, Prospect, Bermuda.

1904 Rose, Thomas, L.R.C.P., 60, Bloomsbury street, W.C.

1893† Rosenau, Albert, M.D., Haus Rosenau (am Kurgarten), Kissingen, Bavaria. (*Winter*, Winter Palace, Monte Carlo.)

1884† Rossiter, George Frederick, M.B., Surgeon to the Weston-super-Mare Hospital; Cairo Lodge, Weston-super-Mare.

1884† Roughton, Walter, F.R.C.S., Cranborne House, New Barnet.

1882* Routh, Amand, M.D., B.S., F.R.C.P., Obstetric Physician and Lecturer on Midwifery at Charing Cross Hospital; 14a, Manchester square, W. *Council*, 1886-8, 1896-7, 1907. *Board Exam. Midwives*, 1893-5. *Hon. Lib.* 1898-9. *Hon. Sec.* 1900-3. *Vice-Pres.* 1904–6. *Trans.* 5.

O.F.* Routh, Charles Henry Félix, M.D., Consulting Physician to the Samaritan Free Hospital for Women and Children; 52, Montagu square, W. *Council*, 1859-61. *Vice-Pres.* 1874-6. *Trans.* 13.

1887*†Rowe, Arthur Walton, M.D.Dur., 1, Cecil street, Margate.

1886 Rushworth, Frank, M.D.Lond., 153, Finchley road, South Hampstead, N.W. *Council*, 1905.

1886† Rutherfoord, Henry Trotter, M.A., M.D.Cantab., Salisbury House, Taunton. *Council*, 1892-3. *Trans.* 1.

Elected

1866*†Saboia, Baron V. de, M.D., Director of the School of Medicine, Rio de Janeiro; 7, Rua dom Affonso, Petropolis, Rio Janeiro. *Trans.* 2.

1906 St.Johnston, Thomas Reginald, L.R.C.P., Lewisham Infirmary, S.E.

1864*†Salter, John H., M.R.C.S., D'Arcy House, Tolleshunt d'Arcy, Kelvedon, Essex. *Council,* 1894-6.

1868* Sams, John Sutton, M.R.C.S., St. Peter's Lodge, Eltham road, Lee, S.E. *Council,* 1892.

1886*†Sanderson, Robert, M.B.Oxon., 56, Brunswick square, Brighton.

1872 Sangster, Charles, M.R.C.S., 148, Lambeth road, S.E.

1903† Savage, Smallwood, M.B.Oxon., F.R.C.S.Eng., 133, Edmund street, Birmingham.

1890 Schacht, Frank Frederick, B.A., M.D.Cantab., 153, Cromwell road, S.W.

1902 Scharlieb, Mary Ann Dacomb, M.D.Lond., M.S., B.S., Obstetric Physician to the Royal Free Hospital, and Lecturer on Midwifery to the London School of Medicine for Women; 149, Harley street, W. *Council,* 1905–7.

1882 Serjeant, David Maurice, M.D., 27, Peckham road, S.E.

1905 Serjeant, Edith, L.R.C.S.&P.Edin., 27, Peckham road, Camberwell, S.E.

1905† Serjeant, Helen Mary, L.R.C.S.&P.Edin., Babies' Castle, Hawkhurst, Kent.

1875 Seton, David Elphinstone, M.D., 1, Emperor's gate, S.W. *Council,* 1884.

1896† Sharman, Mark, M.B., C.M.Glas., Rickmansworth.

1891 Shaw-Mackenzie, John Alexander, M.D.Lond., 50, Green street, Park lane, W.

1906† Shaw, William Fletcher, M.D.Vict., St. Mary's Hospital, Manchester.

Elected

1900† Shepherd, Thomas William, L.R.C.S.Edin., Castle Hill House, Launceston.

1906 Shields, Ida Russell, M.B., B.S.Lond., Clapham Maternity Hospital, Clapham.

1902 Sikes, Alfred Walter, M.D., B.Sc.Lond., 57, Wimpole street, W.

1902 Simson, Henry J. F., M.B., F.R.C.S.Ed., 36, Grosvenor street, W.

1888† Sinclair, Sir William Japp, M.D.Aber., Honorary Physician to the Southern Hospital for Women and Children and Maternity Hospital, Manchester; and Professor of Obstetrics and Gynæcology, Owens College, Manchester; Garvock House, Dudley road, Whalley Range, Manchester. *Council*, 1899-1902. *Vice-Pres.*, 1903-7. *Trans.* 1.

1881† Sloan, Archibald, M.B., 21, Elmbank street, Glasgow.

1876† Sloan, Samuel, M.D., C.M., 5, Somerset place, Sauchiehall street west, Glasgow.

1890† Sloman, Frederick, M.R.C.S., 18, Montpellier road, Brighton.

1903 Smith, Arthur Lionel Hall, L.R.C.P., M.R.C.S.Lond., 16, New Cavendish street, W.

1905* Smith, George Frederick Darwall, M.B.Cantab., B.Ch.Oxon., F.R.C.S.Eng., 30, Wimpole street, W.

1901 Smith, Guy Bellingham, M.B., B.S.Lond., F.R.C.S., 24, St. Thomas's street, S.E. *Trans.* 1.

1867* Smith, Heywood, M.D., 25, Welbeck street, Cavendish square, W. *Council*, 1872-5. *Board Exam. Midwives*, 1874-6. *Trans.* 6.

1875 Smith, Richard Thomas, M.D., Physician to the Hospital for Women, Soho square; 33, Wimpole street, W.

1886† Smith, Samuel Parsons, L.K.Q.C.P.I., Park Hyrst, Addiscombe road, Croydon.

1899*† Smyly, Sir William Josiah, M.D., F.R.C.P.I., 58, Merrion square, Dublin.

Elected

1868* SPAULL, BARNARD E., M.R.C.S., L.R.C.P., 1, Stanwick road, West Kensington, W.

1907 SPEERS, WILLIAM GORDON, M.R.C.S., L.R.C.P.Lond., 18, Largo dos Guayanazes, São Paulo, Brazil.

1888* SPENCER, HERBERT R., M.D., B.S.Lond., F.R.C.P., Professor of Obstetric Medicine in University College Hospital Medical School, Obstetric Physician to University College Hospital; 104, Harley street, W. *Council*, 1890-92. *Board Exam. Midwives*, 1896-7. *Hon. Sec.* 1898-1901. *Vice-Pres.*, 1902–4. *Editor*, 1903-7. *Pres.*, 1907. *Trans.* 11.

1882* SPOONER, FREDERICK HENRY, M.D., Shameen, 33, Pembury road, Lower Clapton, N.E.

1897 STABB, ARTHUR FRANCIS, M.B., B.C.Cantab., Assistant Obstetric Physician to St. George's Hospital, and Lecturer in Midwifery in the University of Cambridge; 132, Harley street, W. *Council*, 1899-1901. *Board Exam. Midwives*, 1903-5.

1907 STEDMAN, HERMAN, M.D.Cinc., F.R.C.S.Edin., 145, East India road, E.

1877† STEPHENSON, WILLIAM, M.D., Professor of Midwifery, University of Aberdeen; 3, Rubislaw terrace, Aberdeen. *Council*, 1881-3. *Vice-Pres.*, 1887-9. *Trans.* 2.

1894 STEVENS, THOMAS GEORGE, M.D., B.S.Lond., 8, Weymouth street, W. *Council*, 1902-3. *Board Exam. Midwives*, 1904-5. *Trans.* 2.

1884† STEVENSON, EDMOND SINCLAIR, Knt., F.R.C.S.Ed., Strathallan House, Rondebosch, Cape of Good Hope. *Trans.* 2.

1875*†STEWART, WILLIAM, F.R.C.P.Ed., 26, Lethbridge road, Southport.

1884 STIVENS, BERTRAM H. LYNE, M.D.Brux., 107, Park street, Grosvenor square, W.

1883 STOCKS, FREDERICK, M.R.C.S., 421, Wandsworth road, S.W.

1894† STOTT, WILLIAM ATKINSON, M.B., Ch.B.Vict., L.R.C.P. Lond., 2, Hillary place, Woodhouse lane, Leeds.

Elected

1898† Sturmer, Arthur James, M.R.C.S., L.R.C.P., Lieut.-Col., c/o Messrs. Henry S. King & Co., 9, Pall Mall, S.W. *Trans.* 1.

1884 Sunderland, Septimus, M.D., M.R.C.P., Physician to the Royal Hospital for Children and Women; 11, Cavendish place, Cavendish square, W.

1904 Swaffield, Walter H., M.D., F.R.C.S.Ed., 39, Weymouth street, Portland place, W.

1896 Swan, Charles Atkin, M.B., B.Ch.Oxon., 3, Chester place, Hyde Park square, W.

1901 Swanton, James Hutchinson, M.D., M.Ch., 40, Harley street, W.

1893 Swayne, Francis Griffiths, M.A., M.B., B.C.Cantab., 140, Church road, Norwood, S.E.

1892† Swayne, Walter Carless, M.D.Lond., Obstetric Physician, Bristol Royal Infirmary; Professor of Midwifery in University College, Bristol; Mathon house, 56, St. Paul's road, Clifton. *Council*, 1903-6.

1905† Swete-Evans, William B., M.A., M.B., B.C., Malvern lodge, Southport.

1888* Sworn, Henry George, L.K.Q.C.P. & L.M., 5, Highbury crescent, N.

1883 Tait, Edward Sabine, M.D., 48, Highbury park, N. *Council*, 1892-4. *Trans.* 1.

1880*†Takaki, Kanaheiro, F.R.C.S., 10, Nishi-Konyachō, Kiōbashika, Tokio, Japan.

1891 Targett, James Henry, M.B., M.S.Lond., F.R.C.S., Obstetric Surgeon and Joint Lecturer on Midwifery to Guy's Hospital, 19, Upper Wimpole street, W. *Council*, 1895. 1906. *Board Exam. Midwives*, 1900-2.

1892* Tate, Walter William Hunt, M.D.Lond., Obstetric Physician to, and Lecturer on Midwifery and the Diseases of Women at, St. Thomas's Hospital; 32, Queen Anne street, Cavendish square, W. *Council*, 1895-7. *Board Exam. Midwives*, 1898-9. *Trans.* 2.

Elected

1900 Taylor, Frank Edward, M.A., M.D., F.R.C.S., Pathologist to Chelsea Hospital for Women; Physician for Diseases of Women to North-west London Hospital; 11, Bentinck street, Cavendish square, W.

1890*†Taylor, John William, F.R.C.S., Surgeon to the Birmingham and Midland Hospital for Women; Professor of Gynæcology, Birmingham University; 22, Newhall street, Birmingham. *Council*, 1900-2. *Trans.* 4.

1892 Taylor, William Bramley, M.R.C.S., 145, Denmark hill, S.E.

1894† Tench, Montague, M.D.Brux., L.R.C.P.Lond., Great Dunmow, Essex.

1890† Thomas, Benjamin Wilfred, L.R.C.P.Lond., Welwyn.

1887† Thomas, William Edmund, L.R.C.P.Ed., Ashfield, Bridgend, Glamorganshire.

1901 Thompson, Charles Herbert, M.D.Dubl., 133, Harley street, W.

1867*†Thompson, Joseph, L.R.C.P.Lond., Surgeon to the General Hospital and Hospital for Women, Nottingham; 1, Oxford street, Nottingham. *Council*, 1896-8. *Trans.* 1.

1905 Thomson, William B., M.D., B.Ch.Glasg., Holborn Infirmary, Archway road, Highgate, N.,

1902 Thorne, Mary, M.D., 148, Harley street, W.

1873*†Ticehurst, Charles Sage, M.R.C.P.Edin., Petersfield, Hants.

1895† Tinley, William Edwin Falkingridge, M.B., B.S.Durh., Hildegard House, Whitby.

1879† Tivy, William James, F.R.C.S.Ed., 5, Victoria square Clifton, Bristol.

1886† Tuckett, Walter Reginald, M.R.C.S., Woodhouse Eaves, near Loughborough.

1865* Turner, John Sidney, M.R.C.S., Stanton House, 81, Anerley road, Upper Norwood, S.E. *Council*, 1893-4.

Elected

1891† Turner, Philip Dymock, M.D.Lond., Sudbury villa, Ryde, Isle of Wight. *Trans.* 1.

1897 Twynam, George Edward, L.R.C.P.Lond., 2, Wetherby place, Hereford square, South Kensington.

1890 Tyrrell, Walter, L.R.C.P.Lond., 104, Cromwell road, S.W.

1904† Van Buren, Asa Claude, M.B., B.S.Lond., Wray Lodge, Chelston square, Torquay.

1903 Vaughan, Ethel May, M.D., B.S.Lond., Physician for Diseases of Women to Out-patients, Royal Free Hospital, and Demonstrator of Gynæcology, London School of Medicine for Women; 21, Upper Wimpole street, W.

1874* Venn, Albert John, M.D., 3, Hanover court, Hanover square, W.

1903† Vincent, George Fourquemin, F.R.C.S.Edin., Rozelle, Maybury road, Woking.

1900* Vincent, Ralph Henry, M.D., B.S.Durh., 1, Harley street, W.

1898† Walker, Alfred, M.D., B.C., M.A.Cantab., Port Isaac, North Cornwall.

1866*†Walker, Thomas James, M.D., Surgeon to the General Infirmary, Peterborough; 33, Westgate, Peterborough, *Council*, 1878-80.

1901† Wallace, Arthur John, M.D.Edin., Surgeon to the Hospital for Women, Liverpool; 1, Gambier terrace, Liverpool.

1870 Wallace, Frederick, M.R.C.S., L.R.C.P., Foulden Lodge, Upper Clapton, N.E. *Council*, 1880-2.

1893† Walls, Willlam Kay, M.B.Lond., 14, St. John street, Manchester.

1879*†Walter, William, M.A., M.D., Surgeon to St. Mary's Hospital, Manchester; 20, St. John street, Manchester.

Elected

1867*†Walters, James Hopkins, M.R.C.S., Surgeon to the Royal Berkshire Hospital; 15, Friar street, Reading, Berks. *Council*, 1884-6. *Trans.* 1.

1898*†Ward, Charles, F.R.C.S.I., M.R.C.S.Eng., Pietermaritzburg, Natal, S. Africa.

1898† Watson, C. R., M.D.Brux., 5, Mount Ephraim road, Tunbridge Wells.

1894 Webb, John Curtis, M.A., M.B., B.C.Cantab., 6, Bina gardens, S.W.

1905† Webster, Charles George, Capt. I.M.S., L.R.C.P.&S.Ed., Madras.

1901 Weekes, Henry Holman, M.D.Brux., L.R.C.P.Lond., Crowborough, Sussex.

1891† Wellesley-Garrett, Arthur Edward, L.R.C.S. & L.M.Ed., 6, Grosvenor hill, Wimbledon.

1888*†Weston, Joseph Theophilus, M.D.Brux., care of Messrs. Grindlay and Co., 54, Parliament street, S.W.

1890* Wheaton, Samuel W., M.D.Lond., Physician to the Royal Hospital for Children and Women; 10, Rastell avenue, Streatham hill, S.W.

1902† White, Clement, M.B., B.C.Cantab., Star hill, Rochester.

1907 White, Clifford, M.D., B.S.Lond., Queen Charlotte's Hospital, N.W.

1903† Whitehouse, William H., M.D.Durh., Keston House, Aston road, Birmingham.

1902† Whitelocke, Richard Henry A., M.B., C.M.Edin., 6, Banbury road, Oxford.

1882† Wholey, Thomas, M.B. Durh., The Lodge, Hankham, Pevensey.

1901† Wigg, Henry Higham, M.D.Brux., L.R.C.P., F.R.C.S. Edin., 8, North terrace, Adelaide.

1902 Willett, John Abernethy, M.B.Oxon., 26, Upper Wimpole street, W.

Elected

1903 Willey, Florence Elizabeth, M.D., M.S., B.Sc.Lond., 1A, Devonshire street, Portland place, W.

1904† Williams, Edward Colston, M.D., B.S.Lond., 7, Park road, Wigan.

1899 Williamson, Herbert, M.A., M.B., M.R.C.P., Assistant Obstetric Physician, Royal Hospital for Women and Children; 84, Wimpole street, W. *Council*, 1907. *Trans.* 3.

1898† Wilson, Claude, M.D.Edin., Belmont, Church road, Tunbridge Wells.

1892† Wilson, Thomas, M.D., B.S.Lond., F.R.C.S., Assistant Obstetric Physician at the General Hospital, Birmingham; 87, Cornwall street, Newhall street, Birmingham. *Council*, 1906-7. *Trans.* 3.

1901† Wilson, Thomas George, M.B., Ch.M.Sydney, F.R.C.S. Edin.; 296, Ward street, North Adelaide, South Australia.

1900† Wingate, William Warburton, M.B., B.C.Cantab., 60, St. Andrew's street, Cambridge.

1886† Winterbottom, Arthur Thomas, L.R.C.P.Ed., c/o H. R. D. Pearson, Esq., King Island, Tasmania.

1877*†Wintle, Henry, M.B., 33, Strawberry High road, Twickenham.

1893 Wise, Robert, M.D.Edin., 290, Ivydale road, Nunhead, S.E.

1906† Withers, Frederick Ernest, L.R.C.P., The Manor House, Horncastle.

1887† Withers, Robert, M.R.C.S., Stenteford Lodge, Spencer terrace, Lipson road, Plymouth.

1890 Wornum, George Porter, M.R.C.S., 58, Belsize park, Hampstead, N.W.

1904† Worthington, Richard, M.B., B.C.Cantab., Gordon road, Lowestoft.

1876† Worts, Edwin, M.R.C.S., L.R.C.P., 6, Trinity street, Colchester.

Elected

1887† WRIGHT, CHARLES JAMES, M.R.C.S., Senior Surgeon to the Hospital for Women and Children, Leeds; Professor of Midwifery to the Yorkshire College; Lynton Villa, Virginia road, Leeds. *Council*, 1903-5.

1907 WYATT, JAMES MONTAGUE, M.R.C.S., L.R.C.P.Lond., 15, Routh road, Wandsworth Common, S.W.

1888*†WYATT-SMITH, FRANK, M.B., B.C.Cantab., British Hospital, Buenos Ayres.

1882*†YOUNG, CHARLES GROVE, M.D., Berbice, Upper Sea road, Bexhill, Sussex.

1906† YOUNG, ERNEST ERIC, M.S.Lond., North Staffordshire Infirmary, Hartshill, Stoke-on-Trent. *Trans.* 1.

Number of Fellows 573

CONTENTS.

	PAGE
List of Officers for 1907	v
Standing Committees	vii
List of Past Presidents	ix
List of Referees of Papers for 1907	x
Trustees of the Society's Property	xi
List of Honorary Fellows	xi
List of Ordinary Fellows	xiii
Contents	liii
List of Plates	lviii
List of Illustrations	lix
Advertisement	lx

January 7th, 1907—

Fibroid of Uterus with a Sarcomatous Nodule in the centre, shown by Dr. AMAND ROUTH . . 1

CHRONIC SEPTIC INFECTION OF THE UTERUS AND ITS APPENDAGES, by Dr. ARCHIBALD DONALD . 6

THE PATHOLOGY OF CHRONIC METRITIS, by Dr. WILLIAM FLETCHER SHAW . . . 19

February 6th, 1907—

Report of the Pathology Committee on Dr. Amand Routh's Specimen of a Fibro-myoma of the Uterus, with a Sarcomatous Nodule in the Centre . 45

A Villous Tumour of the Body of the Uterus in a woman aged 84; Vaginal Hysterectomy; Recovery; shown by Mr. J. BLAND-SUTTON . . 46

Pregnancy in the Right Cornu of a Fibroid Uterus, shown by Mrs. BOYD 49

Adeno-carcinoma of the Ovary, shown by Mrs. BOYD 50

PAGE

Co-existing Tubal and Uterine Pregnancy; Abdominal Section; subsequent delivery at term, shown by Dr. WALTER TATE 51

Suppuration in Fibro-myoma Uteri following Premature Delivery; treated by Abdominal Hysterectomy; shown by Dr. WALTER TATE . . 54

Chorio-endothelioma of Uterus; Intra-peritoneal Hæmorrhage; Hysterectomy; Death; shown by Mr. ALBAN DORAN for the late Dr. G. BAGOT FERGUSON 57

Annual Meeting: the Audited *Report* of the Treasurer (Dr. G. E. HERMAN) 62

Report of the Honorary Librarian (Dr. W. J. GOW) . 64

Annual Address of the President (Dr. W. R. DAKIN). 66

March 6th, 1907—

Report of the Pathology Committee on Mr. BLAND-SUTTON'S Specimen of a Villous Tumour of Uterus from a patient aged 84 (see p. 46) . . 93

After-history of the Case of Fibroid of Broad Ligament associated with an Ovarian Cyst, reported in the Forty-third Volume of the Society's 'Transactions,' by Mr. ALBAN DORAN 94

A Case of Perithelioma of the Uterus, shown by Dr. G. F. DARWALL SMITH . . . 97

A Suppurating Fibroid Tumour of the Uterus, shown by Dr. G. F. BLACKER . . . 100

A Case of Chorion-epithelioma of the Uterus: Lutein Cysts in both Ovaries; shown by Dr. G. F. BLACKER (Plates VII—IX) 104

A Case of Supposed Recurrence after Vaginal Hysterectomy for Cancer of the Cervix, shown by Dr. C. HUBERT ROBERTS (Plate X) . . 114

INAUGURAL ADDRESS—President (Dr. H. R. SPENCER) 117

April 3rd, 1907—

Report of the Council 135

Report of the Pathology Committee on Mr. G. F. Darwall Smith's Specimen of Perithelioma of the Uterus (see p. 97) 136

PAGE

Supposed Sarcoma of the Cervix, shown by Dr. H. R. Andrews 137

Fibro-myomatous Uterus with a Calcified Fibroid lying free in its cavity, shown by Dr. J. H. Dauber 139

Bilateral Primary Tuberculous Salpingitis with Secondary Infection of the Perivascular Lymphatics of the Uterine Wall, shown by Dr. Cuthbert Lockyer (Plates XI and XII) . . . 141

Placentæ from a case of Twins, shown by Dr. Robert Wise 147

On the advisability of Removing the Cervix in performing Hysterectomy for Fibro-myomatous Uterine Tumours, by Mr. J. D. Malcolm 148

May 1st, 1907—

Report of the Pathology Committee on Dr. H. R. Andrews' Specimen of Supposed Sarcoma of Cervix 169

A Case of Intra-peritoneal Rupture of the Bladder occurring during Labour, by Mr. C. R. Porter (introduced by Dr. H. R. Andrews) . . 170

A Uterus four years after Cæsarean Section, shown by Mr. J. Bland-Sutton . . . 174

Two Specimens from Cases of Cancer of the Cervix, the Patients remaining free from Recurrence twenty and eleven years respectively after Operation, shown by Dr. Lewers 179

Uterus showing Villous Malignant Tumour and a Fibroid which has undergone Sarcomatous Change, shown by Dr. May Thorne (Plate XIII) . . 181

Malignant Vaginal Polypus secondary to an Adrenal Tumour of the Kidney, by Mr. Alban Doran (Plates XIV—XVIII) . . . 182

June 5th, 1907—

Report of the Pathology Committee on Dr. May Thorne's Specimen of Uterus showing Malignant Villous Tumour and a Fibroid undergoing Sarcomatous Change (see p. 181) . . . 207

Report of the Pathology Committee on Mr. Alban Doran's Specimen of a Malignant Vaginal Polypus secondary to an Adrenal Tumour (see p. 182) . 208

PAGE

Two Cases of Pregnancy in a Rudimentary Uterine Horn, by Dr. Henry Russell Andrews . 209
Rupture of the Heart in a Still-born Infant, shown by Dr. C. Nepean Longridge . . . 214
Dilated Ureters in Still-born Infants, shown by Dr. C. Nepean Longridge . . . 215
The Pelvic Organs of a Case where Inoperable Papilloma of the Left Ovary had been found Seven Years Previously, shown by Dr. Amand Routh . 216
Myomatous Uterus Weighing over Seven Pounds removed from a Woman aged 22, shown by Dr. Herbert Spencer (Plate XIX) . . 219
Ovarian Pregnancy (?), shown by Dr. Briggs . 222
Early Tubal Mole, shown by Dr. Briggs . . 223
Fibroid Tissue formed around a Needle and removed from the Left Labium Majus, shown by Dr. Briggs 223
Primary Embolic Chorion-Epithelioma of the Vagina, by Henry Thomas Hicks (Plates XX—XXII) 224
A Case of Chorion-epithelioma complicated by Hæmato-metra, by W. S. A. Griffith and Herbert Williamson (Plate XXIII) . . 242

July 3rd, 1907—

Report of the Pathology Committee on Dr. H. Briggs' Specimen of Ovarian Pregnancy (?) (see p. 222) . 256
Report of the Pathology Committee on Dr. Dauber's Specimen of Fibro-myomatous Uterus containing a Calcified Fibroid lying free in the Uterine Cavity (see p. 139) 257
Report of the Pathology Committee upon Mr. H. T. Hicks's Specimen of Primary Vaginal Embolic Chorion-epithelioma (see p. 224). . . 257
Suppuration in an Ovarian Cyst caused by the *Bacillus typhosus*, by Dr. Frank E. Taylor . 257
Two Uteri with "Fundal Ligament" after Hysteropexy, shown by Dr. Frank E. Taylor . . 266
Hæmorrhage in Uterine Fibroid, shown by Mr. J. H. Targett 269
Malignant Disease of Cervix in One-horned Uterus, shown by Miss Aldrich-Blake . . 270

PAGE

Skeleton of Extra-Uterine Fœtus, shown by Miss Aldrich-Blake 270

Two Specimens of Fibroid associated with Bleeding after the Menopause, shown by Dr. Lewers . 271

Calcified Uterine Fibro-myoma removed Piecemeal for Hæmorrhage fourteen years after Oöphorectomy, shown by Dr. Herbert R. Spencer . 272

A Specimen of Diaphragmatic Hernia in a New-born Baby, shown by Dr. C. Nepean Longridge . 273

Mammary Gland of New-born Infant, shown by Dr. C. Nepean Longridge . . . 274

Myxomatous Fibroid, shown by Mrs. Scharlieb . 274

Pension to the Secretary and Librarian, Miss Hannam, in lieu of honorarium 277

Abstract of Receipts and Payments from January—June, 1907 278

Index 279

Additions to Library 291

General Index to Transactions, vols. i—xlix . . 295

PLATES.

PLATE		PAGE
I–III.	—The Pathology of Chronic Metritis (Dr. W. Fletcher Shaw) . . .	22
IV–VI.	—The Pathology of Chronic Mastitis (Dr. W. Fletcher Shaw) . . .	24
VII and VIII.	—A Case of Chorion-epithelioma of the Uterus; Lutein Cysts in both Ovaries (Dr. G. F. Blacker) . . .	106
IX.	—A Case of Chorion-epithelioma of the Uterus; Lutein Cysts in both Ovaries (Dr. G. F. Blacker)	110
X.	—A Case of Supposed Recurrence after Vaginal Hysterectomy for Cancer of the Cervix. (Dr. C. Hubert Roberts) . .	114
XI and XII.	—Bilateral Primary Tuberculous Salpingitis with Secondary Infection of the Perivascular Lymphatics of the Uterine Wall (Dr. Cuthbert Lockyer) . .	142
XIII.	—Uterus showing Malignant Villous Tumour and a Fibroid which has undergone Sarcomatous Change (Dr. May Thorne)	180
XIV.	—Malignant Vaginal Polypus secondary to an Adrenal Tumour of the Kidney (Mr. Alban Doran) . . .	184
XV–XVII.	—Malignant Vaginal Polypus secondary to an Adrenal Tumour of the Kidney (Mr. Alban Doran) . . .	188
XVIII.	—Malignant Vaginal Polypus secondary to an Adrenal Tumour of the Kidney (Mr. Alban Doran) . . .	190
XIX.	—Myomatous Uterus weighing over Seven Pounds, removed from a Woman, aged 22 (Dr. Herbert R. Spencer) . .	221
XX–XXII.	—Primary Embolic Chorion-epithelioma of the Vagina (Mr. H. T. Hicks) . .	225
XXIII.	—A Case of Chorion-epithelioma complicated by Hæmatometra (Dr. W. S. A. Griffith and Dr. H. Williamson) . .	246

ILLUSTRATIONS.

PAGE

A Uterus in Sagittal Section. The cavity is dilated and occupied by a villous tumour growing from the posterior wall (Mr. J. BLAND-SUTTON) 47

A Uterus in Sagittal Section which had been subjected to Cæsarean Section four years previously (Mr. J. BLAND-SUTTON) 175

ADVERTISEMENT.

The Society is not as a body responsible for the facts and opinions which are advanced in the following papers and communications read, nor for those contained in the abstracts of the discussions which have occurred at the meetings during the Session.

AGNES HANNAM,

Secretary and Librarian.

20, Hanover Square, W.

JANUARY 7TH, 1907.

W. R. DAKIN, M.D., President, in the Chair.

Present—26 Fellows and 2 visitors.

Books were presented by Dr. Herman, and the Staff of Guy's Hospital.

Thomas Reginald St.Johnston, M.R.C.S., L.R.C.P., and William Fletcher Shaw, M.D.Vict., were admitted Fellows of the Society.

H. N. Anklesaria, L.R.C.P., F.R.C.S.Ed. (Bombay), and Harold Clifford, M.B.Lond. (Manchester), were declared admitted.

The following gentlemen were elected Fellows of the Society: Percy Cecil Parker Ingram, M.B., B.S.Lond. (Newport, Mon.); and Herman Stedman, M.D.Cincinnati, F.R.C.S.Ed.

The following gentleman was proposed for election: Lewis Graham, B.S.Lond., M.R.C.S., L.R.C.P.

FIBROID OF UTERUS WITH A SARCOMATOUS NODULE IN THE CENTRE.

By Dr. AMAND ROUTH.

THE specimen was removed on December 4th last, from a lady, aged 52, who had had two children, the last

sixteen years previously. Her September period was of normal date and duration—five days. On October 3rd hypogastric pain began, "like labour pains," but almost continuous, starting at 6 p.m. and lasting for two hours. These recurred every evening at the same time and lasted for some hours. Twice during the month slight hæmorrhage occurred during the paroxysm of pain.

The October period lasted four days (October 16th to 20th), and was followed by increased pain, which still recurred with absolute punctuality at 6 p.m., but lasted three or four, or even six hours, and was uncontrolled by drugs. She also began to lose large quantities of blood from the uterus, large clots being passed. Her temperature never rose above 99° F.

I saw her at Newbury with Dr. Wyllie on November 1st, and found she had a fibroid uterus reaching two inches above the pubes, and that there was much tenderness over the tumour on its left upper corner. Thinking it probable that there was a submucous fibroid or a fibroid polypus present, I dilated up rapidly to admit my finger but found nothing *in utero*. The fibroid was intra-mural, and was mainly in the left side of the uterus.

All pain and hæmorrhage ceased for four days after the dilatation, but then the pain gradually returned. It was found that morphia had no effect upon the severity of the pain unless given hypodermically within the first few minutes of the onset, which was invariably sudden, and it was also noticed that the pains were now not so punctual, but were postponed two or three hours beyond the twenty-four, as if it took a longer time for the nervous energy to accumulate.

The patient's friends were anxious to avoid hysterectomy, so it was not till November 26th that Dr. Wyllie was able to persuade the patient to come to a nursing home in London. Then, curiously enough, the pains ceased for a few days, and after a consultation with Dr. Cullingworth it was decided to wait a week before operating. As, however, the pains began again on the evening of the consultation,

and as the patient was being worn out by the pain and the dread of its daily appearance, operation was agreed upon, and supra-vaginal hysterectomy was performed on December 4th.

On incising the fibroid after the operation, a nodule of a soft, myeloid, homogeneous character was found in the centre of the fibromyoma, clearly defined, apparently not springing from the fibroid itself, but separately. Dr. Cuthbert Lockyer, who assisted me at the operation, has given me the following report on the specimen.

Dr. Cuthbert Lockyer's Report on Dr. Amand Routh's Specimen of Fibromyoma Uteri, showing Invasion by a Mixed-celled Sarcoma in which Multinucleated Giant-cells predominate.

The specimen consists of the body of the uterus and the normal right appendages. The amputation of the corpus uteri was made half an inch below the level of the internal os. The organ measures four inches from above down, and twelve inches in transverse circumference. The increase in circumferential measurement is due to the presence of an interstitial growth situated in the left half of the uterine body. On incising the capsule of uterine muscle which surrounded this growth, the former retracted, and on cutting into the latter its surface became convex after the manner of an ordinary fibroid. On its cut surface, however, the growth showed two or three circular areas of tissue totally devoid of the whorled character of a fibroid. These areas presented a smooth, homogeneous, glistening surface of greyish pink colour, which appeared microscopically to be quite distinct from the fibroid growth in which they lay embedded. Histologically, however, the demarcation is by no means definite. The areas in question have all the characteristics of a mixed-celled sarcoma, in which the most striking feature is the presence of a large number of multinuclear cells, some of

which are round or oval in shape. These cells and other malignant mesoblastic cells of smaller size and various shapes trespass amongst, and produce hyaline degeneration of the fibro-muscular bundles, and are also seen to lie amongst the fully formed and thick-walled blood vessels of the fibroid tumour. There is no attempt at encapsulation of the malignant areas such as is sometimes seen when an originally benign fibroid is invaded by a sarcoma of later date.

There is no other growth in the wall of the uterus nor on the mucosa, but the musculature of the organ is considerably hypertrophied, the walls of the cavity being uniformly one inch in thickness. The cavity itself is abnormally capacious, but shows no sign of encroachment by the tumour above described as situated in the left wall of the uterus.

(*Signed*) CUTHBERT LOCKYER.

The specimen is of considerable interest as regards the question of sarcoma developing in the substance of a fibroid, but the case is also of interest from the remarkable periodicity of the pain. Can the combined symptoms of rhythmic pain and hæmorrhage be at all diagnostic of a malignant change occurring in a uterine fibromyoma?

Dr. CULLINGWORTH said that the questions raised by Dr. Routh's specimen were of such importance that if Dr. Routh and Dr. Cuthbert Lockyer were willing he would suggest that the specimen and sections be referred to the Pathology Committee for consideration and report. The periodicity of the uterine pain was remarkable; personally, he had not met with a similar experience.

Dr. CUTHBERT LOCKYER welcomed Dr. Cullingworth's proposal that the growth of the uterus shown by Dr. Routh should be submitted to the Pathology Committee. This was the more necessary from the fact that Dr. Lockyer admitted that his own report left the important question quite unanswered as to how much of the tumour is sarcomatous, and how far the original fibroid is still benign. As already stated, on macroscopical investigation of the growth, at the time of operation, there seemed to be no doubt that the sarcoma areas were definitely

limited and circumscribed, whilst examination of a single paraffin section, prepared so as to include what was taken to be the edge of a sarcomatous patch, proved that the adjacent fibro-myomatous tissue was extensively invaded in a way undiscoverable by unaided vision. Dr. Lockyer therefore undertook to cut further sections from various parts of the fibroid, for the purpose of deciding the important question whether or not the whole original fibroid had become the seat of secondary sarcomatous change. That the initial tumour was a benign fibro-myomatous growth seemed, in Dr. Lockyer's opinion, conclusively proved, not only by its macroscopical characters—definite encapsulation and convex section—but also by the presence of definite fibro-muscular tissue and fully-formed, thick-walled blood-vessels seen in the microscopical section.

The specimen was referred to the Pathology Committee (*see p.* 45).

CHRONIC SEPTIC INFECTION OF THE UTERUS AND ITS APPENDAGES.

By Archibald Donald, M.A., M.D., C.M.,

GYNÆCOLOGICAL SURGEON TO THE MANCHESTER ROYAL INFIRMARY; SURGEON TO ST. MARY'S HOSPITAL, MANCHESTER.

(Received November 8th, 1906.)

(*Abstract.*)

The writer deals briefly with septic infection which involves the uterine appendages as well as the uterus.

The cases in which the uterus is only involved are discussed more fully. The clinical history and symptoms of these cases are considered, and special attention is drawn to the discomfort or pain which is felt in the hypogastrium or iliac regions, and which is so characteristic of a heavy uterus.

In dealing with the pathology of chronic metritis, the great divergencies of opinion as to the microscopic anatomy are noted. The three main theories as to the cause of chronic metritis are discussed, namely (1) passive congestion, (2) inflammatory change, and (3) muscular hypertrophy.

Reasons are given why the mere alteration in position of a healthy uterus is not likely to cause passive congestion and chronic metritis, but it is pointed out that the treatment by pessaries and suspension operations is founded on the assumption that a displacement does cause these changes.

The parts played by connective tissue increase, and muscular hypertrophy in the enlargement of the uterus are not as yet definitely established and further investigations are desired. The importance of considering the clinical history along with the microscopic anatomy is insisted on. Four clinical types are mentioned. The careful examination of the endometrium in every case is also of the greatest importance.

The treatment of chronic metritis is briefly considered.

A few introductory words to indicate the object and scope of this paper will perhaps not be out of place.

In what follows I have tried to give a comprehensive, though necessarily incomplete account of the progress and results of certain inflammatory processes as they affect the uterus, tubes, and ovaries. The subject is a large one, but it seems best in the first instance to deal with it in all its aspects, in order to avoid the purely regional point of view. The changes produced in the uterus will be considered more in detail.

There is no great difference of opinion as to the clinical history of chronic septic inflammation of the genital tract, but the symptoms of the disease, especially in its later stages, require more careful study. Good work has been done on the pathology of chronic inflammation of the tubes and ovaries; but there are only a few scientific observations on chronic inflammation of the uterus, and we are bound to admit that many pathological points are not yet definitely settled. Further, the failure of many to grasp the important part that chronic uterine inflammation plays in gynæcological practice is responsible for much in the way of treatment that is illogical and pernicious.

In dealing with the various kinds of cases, it will be most convenient if we reverse the order in which the infective process develops and take the more serious cases first.

Cases in which the Inflammation Involves the Uterine Appendages.

The large majority of these cases begin with an acute or subacute infection, but occasionally they are chronic from the first. The illness generally dates from a confinement or an abortion, but in rare cases it may follow some minor operation on the uterus, such as the use of the sound. In acute infections, death may supervene before pathological changes in the organs affected are well marked. In the less acute infections, inflammation

is set up which spreads along the mucous surfaces and penetrates into the tissues of the organs, and changes are produced, which remain more or less permanent. The process starts with an endometritis, then the mucous membrane of the tube is affected, and this leads to a localised peritonitis. The tubes and ovaries are thickened, and may contain pus. But in the class of cases under consideration there is merely obliteration of the abdominal ostium of the tube, and adhesion of the tube to the ovary. The inflammation of the pelvic peritoneum results in adhesions; the ovaries and tubes may be bound together, and there may be more or less intimate matting of these organs with intestines, omentum and peritoneum.

The physical signs in the later stages generally consist of a thickening, more or less definite, at the sides of the uterus or in the pouch of Douglas. Sometimes the uterus is bound down by adhesions, and in this way a displacement is produced. The kind of displacement depends on the part of the uterus involved. Adherent retroversion is produced when the fundus is bound down posteriorly; pathological anteversion when the lower portion of the uterus is pulled back; and anteflexion is caused by the contraction of adhesions which draw the middle portion of the uterus backwards while the fundus and cervix are free.

The symptoms in cases of this sort, when they have passed into the chronic stage, are mainly caused by the condition of the tubes and ovaries. As a rule the general health is much affected. The patient is easily tired, backache is common and also dysmenorrhœa, and there is sterility. In the earlier stages, there may be menorrhagia or irregular and frequent menstruation, but, later on, the periods may become scanty. There is often a marked change in the shape of the abdomen. The patient complains of having lost her figure, and the abdomen feels and looks distended, and the muscles are rigid.

Cases in which the Uterus is chiefly involved—Chronic Metritis and Endometritis.

The affection may, in the first instance, be acute or sub-acute, and gradually become chronic. The uterus may be involved in an inflammation which spreads to the tubes and ovaries, and the inflammation in the appendages may clear up, leaving the uterus alone obviously affected. But in the majority of the cases the infection does not travel as far as the tubes, whilst it affects (directly or indirectly) the whole of the uterine tissue. The mischief is mainly uterine from the first and there is never any acute stage. It is to this class of case that I wish particularly to direct attention.

Clinical history and symptoms.—The trouble nearly always dates from a confinement or miscarriage, and the history is generally as follows:

After the miscarriage or confinement the patient makes a recovery, which may be classified as good, if careful observations of temperature and pulse are not made. But, if the chart is kept strictly, variations from the normal, both in pulse and temperature, will show that convalescence has not run an ideal course. Whether these deviations from the normal are due to the same organisms which cause the more acute cases, but in smaller dosage, or whether they are due to some less noxious germs, is doubtful; but it is certain that cases of what may be called "slight" or "less severe" sepsis are not uncommon.

As long as the patient is in bed she feels fairly well. It is only when she begins to move about that the symptoms show themselves. She then finds that she is easily tired, and she generally complains of pain, or it may be only of dragging or discomfort in the hypogastrium, or in one or both iliac regions. There is generally some leucorrhœa in the earlier stages, and when the periods are established they are apt to be profuse or long-continued. The lower part of the abdomen is sometimes distended. If the patient should become pregnant

again there is liability to miscarriage, and if this happens the diseased condition is almost certain to be aggravated. In the later stages the pain or dragging sensation in the iliac regions is common, and is aggravated by standing or walking. Leucorrhœa may persist for a long period, but this is exceptional. Sometimes hæmorrhage becomes a prominent symptom, and this is especially the case in women over forty years of age. The hæmorrhage may be so profuse as to seriously affect the patient's general health and even endanger her life.

There is one symptom to which I should like to draw special attention, namely, the pain in the iliac region.

Pain or dragging in the iliac region is one of the commonest symptoms in gynæcological practice, and in my opinion is, in the large majority of cases, caused by a heavy uterus. It is usually, but I think erroneously, classified as ovarian. If the bulk of the uterus is greatly increased the uterine body will fall, either forwards or backwards, to a lower level in the pelvis than normal. This is bound to cause a pull or strain on the broad and round ligaments, and this pull or strain will be communicated to the side and front of the pelvis. Those who practise Alexander's operation rely on the round ligaments to pull the uterus up and keep it in a position of anteversion. It is reasonable to suppose that a heavy fundus, whether anteverted or retroverted, will pull on the round ligaments at their insertion in the abdominal wall. In cases of pelvic peritonitis—where the ovaries are involved in the inflammation—the most characteristic pain is in the back and not in front. But although in very pronounced retroversion or retroflexion the patient may complain of a feeling of pressure on the rectum or perineum, the iliac pain is much more common. It is customary, however, to refer pain in the iliac region in women to ovarian troubles, except in cases in which the appendix is thought to be at fault. In the discussion on this pain, which took place at the meeting of the British Medical Association in 1904, the uterus was hardly mentioned and the con-

clusion is justified that the part played by the uterus in the production of this pain has been, to a great extent, overlooked. And yet it is the most constant symptom of a heavy uterus, whether that organ is retroverted or anteverted, as anyone may easily satisfy himself by the systematic interrogation of patients. It is aggravated or brought on by standing, and is generally most marked just before or at the onset of menstruation.

Physical signs.—The one thing common to all these cases is enlargement of the body of the uterus. In some cases the cervix is lacerated and hypertrophied, or is thickened without obvious laceration, or shows an erosion. On bimanual examination the body of the uterus is found distinctly and symmetrically enlarged, and is tender to pressure. There is either retroversion or exaggerated anteversion, or if the isthmus of the uterus is unduly pliant, anteflexion or retroflexion is found. The appendages may be dragged down by the heavy fundus and are then easily felt, but are not thickened or adherent.

Pathological appearances and etiology.—Within recent years the operation of vaginal hysterectomy has been occasionally performed in cases of chronic metritis, and a study of the uteri thus obtained has widened our knowledge of the subject. In its naked-eye appearances the chronic metritic uterus differs widely from a normal uterus. In well-marked specimens the uterus weighs about three times as much as the normal uterus, its walls are about twice as thick, and there is great increase in all the dimensions. When divided the cut surface of uterine tissue bulges as if it had been under strain. In nearly every case the endometrium is considerably increased in thickness. There is no difference of opinion on these points amongst those who have been working on the subject, except as to the endometrium. Theilhaber believes that thickening of the endometrium is exceptional in chronic metritis—but Shaw, who carefully examined a much larger number of specimens, found definite thickening of the mucosa in nearly every case.

When we come to microscopic changes, the divergence of opinion in more marked. Some writers state that the most characteristic changes in chronic metritis are to be found in the blood-vessels; others think that the connective tissue is most affected; while others regard the condition as primarily due to an increase in the muscular element. The fullest account of the microscopic changes in chronic metritis, and the one which is based on the most copious material and careful investigation, is to be found in the paper by Dr. W. F. Shaw, to which I would refer the members of this Society. I may, however, mention briefly a few of Dr. Shaw's conclusions.

He attributes the increased thickness of the uterine walls to overgrowth of both muscle and cellular tissue—which, in his view, are increased almost equally, but with a very slight excess of connective tissue. He finds no constant changes in the vessels. The endometrium was definitely thickened in every one of twenty-five cases in which it could be measured, with two exceptions, both of which are easily explained.

There are three main theories as to the causation of chronic metritis. It has been regarded as due to (1) passive congestion; (2) inflammatory change; and (3) muscular hypertrophy.

The theory of *passive congestion* as a cause of chronic metritis may be stated thus: Under certain circumstances the venous circulation in the uterus is obstructed, and this obstruction leads to dilatation of capillaries and blood-vessels, and possibly to certain changes in the walls of these blood-vessels. An infiltration of small cells occurs in the neighbourhood of the vessels, and this passes into cellular tissue so that a permanent enlargement of the uterus is thus produced.

When we come to inquire into the conditions which are supposed to lead to this passive congestion, we find that we are practically limited to backward displacement of the uterus. Other conditions, such as pelvic tumours,

may, theoretically, cause chronic congestion of the uterus, but the uterine condition is then only of secondary importance. In certain cases of chronic metritis we find the uterus in a position of retroversion or retroflexion, and it is believed by some that these positions cause passive congestion, which, in turn, leads to permanent changes in the tissues of the uterus. Even if this were true it would not account for the larger number of cases of chronic metritis in which the uterus is anteverted, as this, the normal position, even when exaggerated, cannot cause obstruction to the free blood return from the uterus. But there are reasons for believing that a mere alteration in the position of a healthy uterus does not cause passive congestion. The arrangement of the circulation of the uterus, as was pointed out by Sir John Williams* many years ago, make it exceedingly improbable that this should occur. Then, the uterus is not always enlarged in cases even of very marked displacement; there may be very pronounced and long-standing prolapse of a uterus which is normal in size, if we except the tensile elongation of the supra-vaginal cervix, and yet this is the case of all others in which we would expect the blood return to be hampered owing to the stretching of the vessels. We find also, now and again, a uterus which has been for a long time in a position of retroversion and which is yet not enlarged. Finally, if passive congestion is the cause of chronic metritis, we should expect to find some well-marked and characteristic changes in the blood-vessels of uteri which had long been retroverted and were enlarged. No such changes, however, have been proved to exist. On the other hand, Dr. Shaw's sections show that the changes in the vessels are variable, and do not support any such hypothesis. The results of treatment give us another argument against the passive congestion theory, but this will be referred to when the treatment of chronic metritis is discussed.

In spite of all this the theory of passive congestion has

* 'Obstet. Soc. Trans.' London, vol. xxvii for 1885, pp. 112–117.

been widely, but for the most part tacitly, adopted, and forms the basis of most of the treatment by pessaries and fixation operations.

There are writers who believe that the changes found in some cases of chronic metritis are to be found chiefly in the blood-vessels, apart from passive congestion, but as I have stated, this cannot be accepted as a constant, or even as a common change.

When we come to consider the remaining theories—the theory of *connective-tissue inflammation*, and the theory of *muscular hypertrophy*—we have to admit that at present the position is not absolutely clear. Both theories are *à priori* possible, and each has been supported by observation. According to the one, the change is to be regarded as purely inflammatory; according to the other it is, in part at least, in the nature of a true hypertrophy. This "working hypertrophy" may be produced by an increase in thickness of the uterine mucosa or by an increase in the amount of connective tissue between the muscle bundles. I believe that most cases of chronic metritis, if carefully examined, will show both hypertrophy of muscular tissue and increase of connective tissue.

It seems difficult to explain the divergent views of those who have written on the pathology of chronic metritis, as, at first sight, it seems that the question ought to be definitely settled by the careful study of microscopic sections. It may be that the cases from which specimens have been obtained differ widely in their clinical history; and that those who hold exclusively to the connective-tissue theory have only examined specimens which have been obtained from uteri which have at some time been the seat of a very acute inflammation, or in which senile change is advanced. At the present time the microscopic anatomy must be regarded as "sub judice." I would suggest that in further investigations the clinical history of each case should be carefully considered. The neglect of this can only lead to confusion. The term "metritis" may be a misnomer for some of the cases

which are grouped under this title. An investigation into the pathology of the usual form of chronic metritis—that is, the type in which the uterus is enlarged and the symptoms have never been acute—is not made easier by including cases in which there has been acute inflammation after labour, or with cases which have had a high temperature and a sharp illness after curetting, or with cases of so-called climacteric hæmorrhage. Further, it is highly important that the whole thickness of the body of the uterus should be most carefully examined, and not merely one portion. Four types of case may be distinguished clinically at present: 1 and 2. The two types dealt with in this paper—*i. e.* those which date from a confinement or abortion, and are either simple or complicated by inflammation of the appendages. 3. The uterus which bleeds profusely at the climacteric (this may ultimately prove to belong to one of the former categories). 4. Uniform enlargement of the virginal uterus, in which the usual sources of infection can be excluded.

Another point that calls for careful investigation in these cases of chronic metritis is the condition of the endometrium. At present we are rather in the dark as to the relative importance of the changes in the endometrium and those in the mesometrium in the production of symptoms. This is especially so in cases of profuse and intractable hæmorrhage. The theory which is involved in the word "fibrosis," and which assumes that the muscular tissue of the uterus is replaced by a fibrous tissue, and that the hæmorrhage is due to want of muscular control, is an attractive hypothesis, but it has yet to be proved.

The *diagnosis* of chronic metritis is arrived at through the clinical history and the physical signs. The one point which I wish to emphasise here is that chronic metritis in different stages and in varying degree is probably the most common of all the minor gynæcological ailments.

Treatment.—If the opinions which I have expressed as to the pathology of chronic metritis are correct, it

follows that all attempts to cure the condition by a mere alteration of the position of the uterus are quite illogical. The use of pessaries and the slinging up of the uterus by means of operation in cases of backward displacement of a mobile uterus is a tacit acceptance of the passive congestion theory. Some who use pessaries for such cases admit that they do not hope in this way to cure the patient, but merely to palliate her troubles. My own view on this point is that even where relief appears to follow it is merely a kind of faith-healing, and that the use of pessaries for backward displacement eventually causes more discomfort than relief.

Others believe, however, that the maintenance of the uterus in what they call the "proper" position brings about a cure. The mere hanging up of the uterus by a round ligament or fixation operation can never cause a reduction in its size, even if it succeeds in diminishing or altering the dragging symptoms.

The backward displacement of an otherwise healthy and normal uterus produces no symptoms of any consequence, and neither pessaries nor operations are required. When the uterus is enlarged by chronic metritis the result to be aimed at in the treatment is the reduction of the weight of the uterus, and the cure of the tenderness—hæmorrhage, leucorrhœa, and dysmenorrhœa, if these are present.

The means at our disposal are comparatively few. Something can be done in the early stages by palliative treatment; rest in bed, frequent vaginal douching with hot water, tonics—such as iron and strychnine—and careful attention to the bowels. The only time at which these measures are likely to be of lasting benefit is soon after the trouble has begun. It must, however, be remembered that in many cases the departure from the normal is comparatively slight, and that no further treatment is advisable beyond the occasional employment of palliative measures.

In cases where we find marked enlargement of the

uterus, with typical symptoms, curetting should be done. The statement that is often seen in books, that curetting is followed by a decrease in size of the uterus in cases of chronic metritis, is by no means a flight of imagination. I have accurately noted it in my own cases, and Dr. Shaw's investigations have definitely proved that it occurs in a large percentage. Accurate measurement is possible only with the cavity, but careful bimanual estimation leaves no doubt in my mind that the whole uterus is generally diminished. The result of this reduction in size is often to allow the retroverted uterus to return to the normal position, but even when this does not happen the tenderness and dragging are removed.

It is important that the operation should be carried out with the most rigid asepsis. My own practice is to dilate, under an anæsthetic, with finely graduated metal dilators, to use a flushing curette, and to pack the uterine cavity with sterilised gauze for twenty-four hours. If there is cervical hypertrophy a wedge should be removed from each lip of the cervix, and if there is a tendency to prolapse of the vaginal walls a plastic operation on the posterior wall adds afterwards to the patient's comfort.

It sometimes happens that a single curetting is not sufficient, and that the operation has to be repeated before a good result is obtained. In rare cases repeated curettings fail to relieve the symptoms. Whether this is due to a further production of diseased endometrium from the remains of the old, or whether it is to be explained by the condition of the mesometrium, is uncertain. My experience leads me to favour the former view, and the fact that these failures after curetting are comparatively rare points to its being the correct explanation.

For really bad cases, in which there is prolonged hæmorrhage, which repeated curettings have failed to cure, there is general agreement that vaginal hysterectomy is justifiable.

For my part I think the operation ought to be extended to some cases in which hæmorrhage is not a very impor-

tant feature. There are a good many women whose lives are rendered miserable by chronic metritis at a time when they ought to be most active. If, in a case of this sort, the uterus is found to be much enlarged and very hard, and everything points to its being functionally useless, and no improvement is brought about by repeated curetting, it ought to be removed. Owing to improvements in technique the operation involves very little risk, immediate or remote.

Dr. CULLINGWORTH suggested that Dr. Shaw's paper should be read, and that the discussion on Dr. Donald's paper should be postponed until the two communications, which were on closely related subjects, could be considered together.

THE PATHOLOGY OF CHRONIC METRITIS.

By William Fletcher Shaw, M.D., Ch.B.,
HOUSE SURGEON AND RESIDENT OBSTETRICAL ASSISTANT SURGEON
ST. MARY'S HOSPITAL, MANCHESTER.

(Received November 9th, 1906.)

(*Abstract.*)

The conclusions arrived at in this paper are the result of the examination of forty-five uteri extirpated for chronic metritis, thirty-eight being uncomplicated cases, while seven occurred with some concurrent pathological condition. For the purpose of comparison twenty-three normal uteri were also examined.

Chronic metritis is a simple hypertrophy of the mesometrium and is not a connective-tissue hyperplasia.

The percentage of connective tissue varies considerably in the different specimens of chronic metritis, but many normal multiparous uteri possess an equal or even greater proportion of connective tissue; the average amount in the specimens of chronic metritis was only 0·8 per cent. higher than the average amount in the normal parous uteri.

The vessel changes are variable, and, as similar affections are as frequently found in normal uteri, they cannot be considered as the cause of the symptoms.

Except two cases, which could be easily explained, every specimen of uncomplicated chronic metritis also suffered from chronic endometritis.

There is no evidence of active inflammation, as shown by small-celled infiltration or cicatricial tissue.

Chronic metritis is a slowly progressing affection of the uterus. It is never a primary affection, being usual secondary to chronic endometritis, but may be associated with any pelvic

or uterine disease leading to increased uterine contraction or vascularity, viz. fibroids, tubo-ovarian disease, etc.

Chronic metritis occurs at a much earlier age than the menopause, and thus proves that the climacterium is not the causal factor.

In the early stage chronic metritis is indistinguishable clinically from chronic endometritis. At a later period the great increase in size of the uterus may produce symptoms, *i. e.* sacralgia and aching pain in the hypogastrium and iliac regions, due to traction on the broad ligament.

The diagnosis of chronic metritis is largely dependent on the result of treatment. In the early stage of the affection all the symptoms disappear after dilatation and curettage of the uterus, thus demonstrating that the endometritis is the primary cause.

In chronic metritis and chronic endometritis local treatment of the endometrium may fail to relieve the symptoms. This is probably due to re-inauguration of the endometritis.

So-called "chronic metritis" is a subject which has been clinically recognised, and of which much has been written from early times, but it is only comparatively recently that its pathology has been discussed on anything like a scientific basis. However, in the vast amount of literature on this subject there are hardly two authors who agree as to its causation and its pathology. The reason for these various views probably lies in the fact that only in very recent years have uteri been extirpated for chronic metritis, as the older writers argued from *post-mortem* uteri, which had the same characteristics as those clinically diagnosed as chronic metritis, viz. enlargement and increased hardness, but which had often, probably, never given rise to any symptoms during life. Even since these uteri were extirpated the views of modern gynæcologists seem as much at variance as those of the older writers, the most likely explanation being that all the writers, except Lorentz and Theilhaber, were recording the results of only a very small number of such uteri.

In this paper I give the results of the microscopical examination of thirty-eight uteri extirpated for chronic metritis alone, and also seven extirpated for chronic metritis along with some other concurrent disease; three had carcinoma of the cervix, two had intra-mural fibroids, one had a tubo-ovarian abscess and one double ovarian disease. For comparison with these I also examined twenty-three normal uteri of various ages and the endometrium removed by curettage in fifty cases of endometritis, the chief object of the latter being a comparison of their clinical histories with those of the chronic metritic uteri.

For the use of specimens I have to thank Dr. Lloyd Roberts, Sir William Japp Sinclair, Dr. Walter, Dr. Donald, Dr. Walls, and Dr. Arnold Lea. In the following paragraphs dealing with changes in the blood-vessels, endometrium, and connective tissue, the figures are derived solely from the thirty-eight cases of uncomplicated chronic metritis.

Pieces were taken from several portions of each uterus and sections cut in paraffin, so that each one included the whole thickness of the uterine wall from peritoneum to mucous membrane. These sections were stained with "Van Gieson" as being the best differential stain for muscular and connective tissue, the connective tissue being bright red and the muscular tissue deep yellow.

Although differing on many minor points, most authors consider the pathology of chronic metritis to fall into one of two groups:

(1) Changes in the vessels;

(2) Increase of connective tissue.

(1) Changes in the Blood-vessels.

Several of the older writers considered the bleeding of chronic metritis to be due to changes in the vessel-walls, which they described as atheroma. Reinecke, in 1896, and Findley, in 1905, each published four cases in which

they considered the hæmorrhage to be due to arterio-sclerosis, the thickening being chiefly in the tunica media.

Theilhaber found the vessels markedly increased in all his specimens and the walls generally thickened, but he does not attach much importance to this.

I have investigated the condition of the blood-vessels in the thirty-eight cases of chronic metritis, and compared their appearance with those of normal uteri at various ages, with the following results :

Vessels not altered	15
A few vessels enlarged but walls not thickened	2
Vessels decreased in number . . .	6
Vessels increased in number . . .	4
A few vessels with thick tunica media containing fibrous tissue . . .	6
A few vessels undergoing hyaline or colloid degeneration	4
A combination of the last two . .	1
	38

In twenty-one—that is, 55 per cent., the vessels were not increased in number, nor were any changes observed in the vessel walls, but in the histories of these twenty-one hæmorrhage was of quite as frequent occurrence as in the other seventeen. In six instances some of the larger arteries showed great increase in thickness of the tunica media, the result of fibrous deposit. This is the pathological condition to which Reinecke, Findley, etc., ascribe the hæmorrhage of chronic metritis. In this I cannot agree, as I only found it occurring in a few vessels in six specimens out of thirty-eight examined. Moreover, of these six specimens, three (Nos. 4, 10, and 18) had no excessive hæmorrhage (see Pl. II, fig. 4), and I also found this change in the vessels of many multiparous normal uteri (see Pl. III, fig. 5). In five instances the arteries showed a homogeneous degeneration affecting the media and adventitia. This area stained bright red with eosin,

DESCRIPTION OF PLATE I,

Illustrating Dr. Wm. Fletcher Shaw's paper on the Pathology of Chronic Metritis.

Fig. 1.—Group of vessels from virgin uterus (Case No. 37). Stained with van Gieson.

These vessels have large lumina and narrow walls, and are surrounded by a fair amount of connective tissue (shown black in the figure). Outside the vessels are seen muscle bundles, with strands of connective tissue running around the bundles and also around the individual muscle-fibres.

This uterus was obtained from a virgin, aged 18, who died as the result of an accident.

Fig. 2.—From Case No. 6. Stained with van Gieson.

This is the type of vessel which made some authors ascribe the bleeding of chronic metritis to vessel-changes. The lumen is narrow and the walls greatly thickened, this great increase in thickness occurring chiefly in the tunica media and being due to a deposit of fibrous tissue, which shows black in the photograph and gives this coat its speckled appearance. If looked at carefully a faint line of demarcation can be seen between the narrow tunica intima and the thick tunica media. In the section of this uterus only two vessels were thickened like this figure, all the remainder being fairly normal, as represented in Fig. 3.

Fig. 1.

Fig. 2.

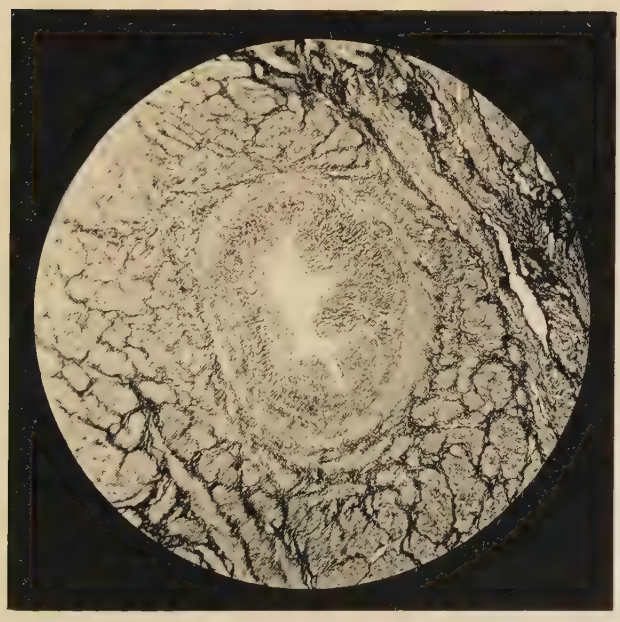

Illustrating Dr. Wm. Fletcher Shaw's paper on the Pathology of Chronic Metritis.

Adlard & Son, Impr.

DESCRIPTION OF PLATE II,

Illustrating Dr. Wm. Fletcher Shaw's paper on the Pathology of Chronic Metritis.

Fig. 3.—Group of normal vessels from the same section as Fig. 2 (Case No. 6). Stained with van Gieson.

These vessels are fairly normal and correspond closely with the vessels from a virgin uterus (Fig. 1).

Fig. 4.—Vessel showing thick tunica media due to deposit of fibrous tissue. From Case No. 18; a uterus which had *no abnormal bleeding*. Stained with hæmatoxylin and eosin.

Fig. 3.

Fig. 4.

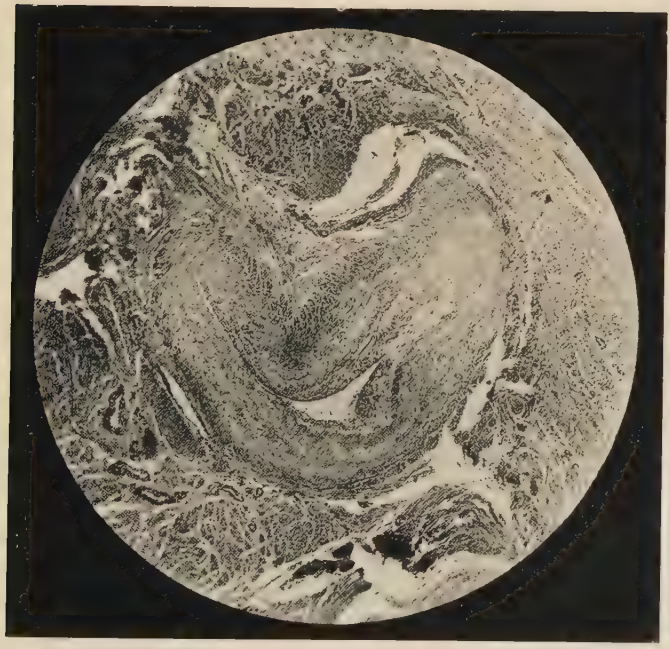

Illustrating Dr. Wm. Fletcher Shaw's paper on the Pathology of Chronic Metritis.

Adlard & Son, Impr.

DESCRIPTION OF PLATE III,

Illustrating Dr. Wm. Fletcher Shaw's paper on the Pathology of Chronic Metritis.

Fig. 5.—Vessels showing thick tunica media due to deposit of fibrous tissue. From a normal multiparous uterus of a woman, aged 26, with no uterine symptoms. Stained with van Gieson.

Fig. 6.—A vessel from Case No. 7, which shows hyaline or colloid degeneration. Stained with van Gieson.

The lumen of the vessel is narrow and is surrounded by a narrow zone of dark, normal tissue; the remainder of the wall is replaced by a pale, homogeneous material. Outside the vessel wall normal, deeply-stained mesometrium can be seen.

Fig. 5.

Fig. 6.



Illustrating Dr. Wm. Fletcher Shaw's paper on the Pathology of Chronic Metritis.

Adlard & Son, Impr.

and pale yellow with "Van Gieson." The exact nature of this change is not clear, but is either a hyaline or colloid degeneration—probably colloid, as it stains a pale yellow with "Van Gieson" (see Pl. III, fig. 6). I cannot, however, ascribe the abnormal bleeding of chronic metritis to this change, as three (Nos. 14, 15, and 18) of these five specimens had no abnormal bleeding.

Anspach and Macgregor are the only authors I can find who mention this change. Anspach described it as a peri-arterial degeneration, which commences in the adventitia, and finally leads to complete obliteration of the vessel. He does not name this degeneration, but states that it is a "hyaline coloured material" when stained with eosin, and bright yellow when stained with "Van Gieson." Macgregor finds it in the vessels of the endometrium in uteri which show this degeneration in the vessels of the mesometrium. In none of my five specimens could I find a trace of it in the vessels of the endometrium.

From these results it seems clear that the hæmorrhage of chronic metritis does not depend upon changes in the vessel-walls of the mesometrium.

The seven uteri extirpated for chronic metritis with some concurrent disease also showed little vessel change; in five of them the vessels were not altered, in one the number of vessels was increased but there were no other changes, while only one possessed vessels with thickened tunica media due to deposit of fibrous tissue.

(2) Changes in the Relative Amounts of Connective Tissue and Muscular Tissue.

The most generally accepted view of the pathology of chronic metritis is that a great increase of connective tissue has taken place. Theilhaber considers that, not only has the amount of connective tissue greatly increased, but the amount of muscular tissue has actually decreased; this he believes to occur normally as the menopause is

reached, and the excessive bleeding then commences owing to the loss of muscular control over the vessels unless these have proportionately contracted.

The method of estimating the amounts of connective and muscular tissues was as follows, and was similar to that employed by Meier, although I had been using it some time before I read his original paper.

The slide was put on a mechanical stage, under the "high power" of a microscope, and consecutive fields estimated through the whole length of the section, from peritoneum to endometrium. As these uteri were so thick this generally meant forty to fifty calculations for each section. The mean of these estimates was taken as a fairly average estimation of that section. Each section was calculated two to three times, and the mean of these calculations taken as the final estimate for that section. Finally, if more than one piece had been cut from a uterus, the average of the results of the various sections was taken as the estimation for the uterus. In the later cases I only examined one piece, as I found very little difference in the several areas from the same uterus. Many of these calculations were made at intervals of several months, but, with few exceptions, the estimates for each section showed less than 5 per cent. of difference, and very often less than 1 per cent. difference. In estimating a section I carefully avoided seeing the former results of that section, otherwise it would have been almost impossible not to have been influenced by the previous figures. The measurements of the thicknesses of the uterine wall were made by means of a mechanical stage on a microscope.

Forty-five uteri with chronic metritis were examined in this way, and also, for the sake of comparison, twenty-three uteri obtained *post mortem* from women of various ages, who had not complained of any uterine symptoms during life. Amongst these I was fortunate enough to obtain the uterus of a virgin, aged 18, who had died rapidly from the result of an injury to the head.

DESCRIPTION OF PLATE IV,

Illustrating Dr. Wm. Fletcher Shaw's paper on the Pathology of Chronic Metritis.

Fig. 7.—The connective tissue seen as dense, darkly-staining strands between the muscle bundles; very little between the muscle fibres.

Fig. 8.—The connective tissue occurs as dense, darkly-staining strands between the muscle bundles, and also as finer strands between the muscle fibres.

Fig. 7.

Fig. 8.

Illustrating Dr. Wm. Fletcher Shaw's paper on the Pathology of Chronic Metritis.

Adlard & Son, Impr.

DESCRIPTION OF PLATE V,

Illustrating Dr. Wm. Fletcher Shaw's paper on the Pathology of Chronic Metritis.

Fig. 9.—The connective tissue is a loose meshwork between the muscle bundles; there is little connective tissue between the muscle fibres.

Fig. 10.—The connective tissue occurs as a loose meshwork between both the muscle bundles and the muscle fibres.

Fig. 9.

Fig. 10.

Illustrating Dr. Wm. Fletcher Shaw's paper on the Pathology of Chronic Metritis.

Adlard & Son, Imp.

DESCRIPTION OF PLATE VI,

Illustrating Dr. Wm. Fletcher Shaw's paper on the Pathology of Chronic Metritis.

Fig. 11.—Section of endometrium from Case No. 33. The glands are enlarged and increased in number, the total thickness of the endometrium being much increased (compare with Fig. 12).

Fig. 12.—This shows the endometrium and part of the mesometrium from a normal primiparous uterus, aged 32. This photograph is taken with the same magnification as Fig. 11, and shows how much the endometrium is thickened in cases of chronic metritis.

Fig. 11.

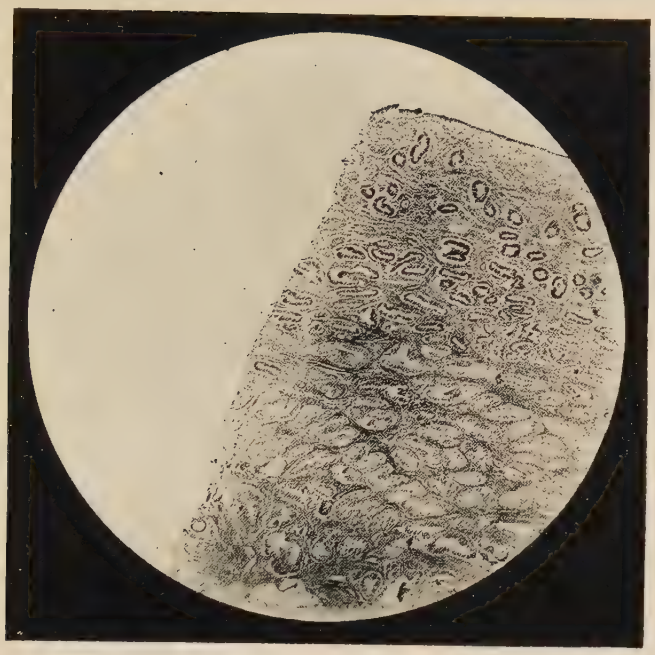

Fig. 12.



Illustrating Dr. Wm. Fletcher Shaw's paper on the Pathology of Chronic Metritis.

Adlard & Son, Impr.

Meier has thoroughly worked out the musculature of the normal uterus in a series of sixty-one uteri, taken at various ages, and has arranged them in a series of curves, showing the percentage of connective and muscular tissues at various ages. His first curve, containing all his uteri, shows anything but a regular gradation; his last, after eliminating those which are least likely to be normal, *i. e.* puerperal uteri, and those of women who have suffered from wasting diseases, shows a regular increase of muscular tissue from childhood to about twenty years of age. For the next ten years the proportion of muscular tissue to connective tissue remains constant. After thirty years of age the muscular tissue progressively decreases in quantity until old age is reached.

I have not been able to obtain sufficient adult normal uteri to arrange in a curve, but our results for corresponding uteri are sufficiently close to show that our methods of calculating give very nearly the true proportion of muscular and connective tissue.

Meier divides his specimens into eight types, according to the arrangement of the connective tissue and muscle fibres. These groups can all be recognised in my sections if carefully looked for, but for practical purposes I believe that a division into four well-defined groups is all that is requisite:

(1) The connective tissue occurs as *dense, darkly-staining strands* between the muscle bundles; there is very little between the muscle fibres (see Pl. IV, fig. 7).

(2) The connective tissue occurs as dense, *darkly-staining strands* between the muscle bundles, but, unlike Group 1, it also occurs in finer strands between the muscle fibres (see Pl. IV, fig. 8).

(3) The connective tissue is a *loose meshwork* between the muscle bundles, little connective tissue being present between the muscle fibres (see Pl. V, fig. 9).

(4) The connective tissue occurs as a *loose meshwork* between both the muscle bundles and the muscle fibres (see Pl. V, fig. 10).

The connective tissue is never equally distributed through the uterine wall; hence a section of one part must not be taken as indicating the proportion existing throughout the uterus. Thus, the inner third of the uterine wall almost invariably shows a relatively small proportion of connective tissue to muscle.

Lorentz has thoroughly examined nine uteri, extirpated on account of excessive hæmorrhage and with the diagnosis of chronic endometritis or chronic metritis. He describes the chief pathological changes as (1) a general increase in the size of the uterus; (2) increase in density of the uterus; (3) great increase of connective tissue; (4) thickening of the vessel walls. He usually finds no changes in the endometrium.

In the forty-five uteri examined by me I found the uterus showed general enlargement, the result of hypertrophy of both muscular and connective-tissue elements in the uterine wall. In a few cases only did the vessels show marked changes. In every instance endometritis, as shown by increased thickness of endometrium, was present in the thirty-eight specimens of uncomplicated chronic metritis.

Theilhaber has maintained that the characteristic changes of chronic metritis are—a great increase of connective tissue and diminished amount of muscular tissue. He bases this opinion on the results of observations by Meier for normal uteri, and Lorentz for uteri with chronic metritis. My observations do not confirm this view. The increase in size is due to a general hypertrophy of both elements, and there is certainly no diminution in the amount of muscular tissue.

Lorentz, in chronic metritis, places the proportion of connective tissue at 45 per cent. to 60 per cent., average at 50·5 per cent. My results in similar specimens varied from 32·5 per cent. to 50 per cent., average 40·4 per cent.

In the normal uteri of parous women, Meier places the proportion of connective tissue at 46·5 per cent., and my own observations show a ratio of 39·4 per cent.

It is thus clear that the difference between the proportion of connective tissue in normal uteri and in chronic metritis is too slight, amounting only to 4 per cent. in Meier and Lorentz's cases and 0·8 in mine, to account for the great increase in thickness of the uterine wall.

Increase in size and thickness of the uterine wall is a constant feature of chronic metritis. The dimensions of a normal uterus may be stated as follows (Quain): length 7·5 cm., breadth 5 cm., thickness 2·5 cm.

All my chronic metritic uteri had much thickened walls, the least being 12 mm., the greatest 26 mm., and the average 18·1 mm.; while the average thickness of the walls of the normal uteri was only 8·7 mm. These figures were obtained after the sections were mounted, and are therefore below the correct measurement, owing to the shrinking of the tissues in preparation; but as most of the uteri were prepared in the same way the difference between the average thicknesses of their walls will be about correct, or will err on the side of being too small. Now the chronic metritic uteri only show, on the average, an increase of 0·8 per cent. (in Meier's case 4 per cent.) of connective tissue above the normal uteri, but their walls are, on the average, more than 100 per cent. thicker than those of the normal uteri. To say that this great increase in bulk is due entirely to increase of connective tissue, and that the musculature is actually lessened in amount, would be obviously incorrect. What has really taken place is a general hypertrophy of the whole uterine wall, the connective tissue having increased, in some specimens, rather more than the muscular tissue.

Anspach, in his recent paper, also disagrees with these results of Theilhaber, his specimens of "metrorrhagia myopathica" showing no greater increase of connective tissue than multiparous uteri with an equal number of pregnancies.

Several authors consider this "fibrosis" to be due to inflammatory changes commencing in the endometrium and extending to the mesometrium.

If this really was the cause then we should have to form two entirely separate groups—chronic metritis occurring in virgins, and chronic metritis occurring after pregnancy, as it is only in the latter that direct infection, to cause the inflammation, could occur. In only three to four of the uteri which I examined was there any trace of small cell-infiltration of the connective tissue, and in none was there anything to make us consider this the cause of the changes.

Condition of Mucous Membrane.

Theilhaber states that thickening of the mucous membrane is rarely found in chronic metritis, and when present is simply an œdema due to venous stasis. Lorentz found the glands increased in size or number in five out of nine specimens. In my thirty-eight specimens I found it possible to accurately measure the thickness of the mucosa in only thirty-one, since some of them had been badly preserved, or else only a small portion of the specimen was given to me which did not include the whole of the mucous membrane. However, in four others, sufficient mucosa was left to show its characteristics, thus making thirty-five in all from which definite conclusions could be drawn. Of these thirty-five specimens, thirty-three showed definite thickening of the mucosa; in two the mucosa was of normal or diminished depth. Of these two, one (No. 15) had passed the menopause three years previously, and had had no discharge of blood since, only profuse leucorrhœa; the other (No. 24) had been curetted three times previously, and each time the mucosa had been found greatly thickened, but unfortunately I was not able to obtain sections from the previous curettings. The thirty-three specimens had endometrium varying from 1·5 mm. to 5 mm. in thickness; but besides this increased thickness they all showed changes in the glands which distinguished them from the normal endometrium.

Unfortunately, almost every text-book gives a different

classification of endometritis. Until the pathology of endometritis is thoroughly worked out and a standard classification adopted it is only possible to classify the various specimens according to their most prominent characteristics. I have divided the endometrium found in my specimens into six classes:

(1) The glands smaller than normal 4 specimens.
(2) The glands enlarged . . 5 „
(3) The glands increased in number 10 „
(4) A combination of 2 and 3 . 10 „
(5) The stroma increased . . 3 „
(6) A combination of 4 and 5 . 3 „

This allows the specimens to be classified according to their most prominent features. To do it more than roughly is impossible, as the various classes merge into each other; so much so is this that two sections hardly ever show exactly the same features. The density of the stroma varies very much, even in the same specimen, often being dense in the deeper portion of the section and loose in the superficial. In only eight specimens did I find the stroma less dense than normal, and in many it was denser; but even if the stroma were œdematous in every specimen, venous stasis would not explain the hyperplasia of glands found in so many instances.

These changes in the endometrium, along with the simple hypertrophy of the mesometrium, I find to be the only constant changes in uteri extirpated with the diagnosis "chronic metritis."

For the sake of comparison with these cases of chronic metritis I tabulated the symptoms (objective and subjective), and the result, after curetting of fifty cases, diagnosed as chronic endometritis. Both classes of cases complain of abnormal menstruation, intermenstrual pain, dysmenorrhœa, and intermenstrual discharge; in both we find increase in the size of the uterus, flexions, and tenderness. These symptoms certainly occur in varying proportions in the two classes of cases, but generally the difference is too slight to enable a definite diagnosis to

No.	Age.	Social state.	Name.	Address.	Date of operation and length of cavity.	Date of 2nd measurem't and length of cavity.	Difference.	Result to patient.
					1905	1905		
52	27	M	C. W.	Lancaster	Feb. 8, 3½ in.	Dec. 20, 2½ in.	−1 in.	Almost cured.
59	25	M	L. W.	Tyldesley	April 15, 3 in.	Dec. 14, 2½ in.	−½ in.	Almost cured.
77	25	S	N. E.	Bury	May 27, 3¼ in.	Nov. 22, 3¾ in.	+½ in.	No improvement.
96	26	S	M. B.	Altrincham	Aug. 2, 3 in.	Dec. 17, 2½ in.	−½ in.	Much better.
92	32	M	K. G.	Stockport	July 29, 3½ in.	Dec. 14, 3¼ in.	−¼ in.	Greatly improved.
89	35	M	S. N.	Golborne	July 26, 3¼ in.	Dec. 14, 2½ in.	−¾ in.	Greatly improved.
88	23	S	M. L.	Blackburn	July 19, 2¾ in.	Dec. 18, 2½ in.	−¼ in.	No improvement.
93	29	S	A. L.	Blackburn	July 29, 3½ in.	Dec. 30, 3¼ in.	−¼ in.	Cured.
94	23	S	E. C.	Cheadle	Aug. 2, 3¼ in.	Dec. 19, 3 in.	−¼ in.	Great difficulty in passing sound; int. os almost occluded; patient improved.
—	38	S	J. A.	Buxton	July 22, 2¾ in.	Jan. 4, 2½ in.	−¼ in.	Better.
—	40	S	M. Y.	Patricroft	Mar. 16, 3¼ in.	Dec. 13, 2¾ in.	−½ in.	Much better.
98	29	M	F. W.	Irlam-o'th'-Heights	July 31, 3½ in.	Dec. 14, 3 in.	−½ in.	Much better.
—	29	M	E. C.	Middleton	Sept. 28, 3½ in.	Dec. 16, 3 in.	−½ in.	Feels a new woman.
55	24	M	K. J.	Hulme	Mar. 24, 3¼ in.	Nov. 10, 3 in.	−¼ in.	Better.
—	39	M	E. T.	Harpurhey	Mar. 14, 3½ in.	Dec. 15, 4 in.	+½ in.	No better; int. os seems occluded; great difficulty in passing a sound.
62	24	M	A. B.	Manchester	April 28, 3½ in.	Nov. 10, 3 in.	−½ in.	Much better.
71	35	M	E. M.	Hyde	May 19, 3 in.	Dec. 11, 2½ in.	−½ in.	Almost cured.
73	49	M	L. W.	Blackburn	May 23, 3¼ in.	Dec. 5, 2½ in.	−¾ in.	Improved.
—	28	M	E. H.	Whalley	May 23, 3 in.	Dec. 5, 2½ in.	−½ in.	Not improved.
66	30	M	H. F.	Hightown	May 12, 3¼ in.	Nov. 27, 2¾ in.	−½ in.	Better.
90	30	M	E. F.	Knutsford	July 28, 3½ in.	Dec. 15, 3 in.	−½ in.	Better.
91	22	S	C. B.	Heaton Chapel	July 28, 3½ in.	Dec. 16, 2½ in.	−1 in.	Improved.
100	31	M	E. R.	Bolton	July 17, 2¾ in.	Dec. 14, 3½ in.	+¾ in.	No better; great difficulty in passing sound through internal os.
					1903			
—	28	S	M. S.	—	Dec. 6, 3¼ in.	Feb. 5, 2¾ in.	−½ in.	—
					1904			
—	30	M	M.	—	Mar. 3, 3½ in.	March, 2¾ in.	−¾ in.	—

be made. For practical purposes I find a patient is diagnosed as suffering from chronic endometritis if her symptoms are recent and the uterus is not very much enlarged; if the symptoms are of long duration, if the uterus is much enlarged and hard, if hæmorrhage is the chief symptom, and especially if she has been curetted without relief, the diagnosis is chronic metritis. Chronic endometritis thus appears to be a precursor of chronic metritis.

That these symptoms are due to disease of the endometrium is proved by the excellent results of curetting, thirty-nine (78 per cent.) of these fifty patients reporting at the end of six months that they were improved, and only eleven (22 per cent.) did not feel any better. Taking the individual symptoms separately—irregular menstruation, intermenstrual discharge, pain, and tenderness—the results were about the same, the effect on tenderness being the most marked. Of the very large number of these patients examined a few days after curetting, very few complained of tenderness, although this was one of the most marked features of the examination previous to operation. At the end of six months only 8 per cent. of this series had any tenderness.

The statement is often made that the cavity of the uterus, in cases of chronic endometritis, is lessened after curetting, but I do not know of any statistics on this subject. On the suggestion of Dr. Donald, I measured the uteri of twenty-three women six months after they were curetted for chronic endometritis, and Dr. Donald has kindly given me two of his own private cases to bring the number up to twenty-five. The cases were not picked in any way. I tried to re-measure every uterus whose measurement I had noted at the time of operation, but could not get more than twenty-three to come back again for examination; either they had moved to another address or were living too far away, or else "had not time to come."

In this list of twenty-five, twenty-two (88 per cent.) showed diminution in length of cavity, and only three (12

per cent.) increase. The diminution varied from 1 in. to $\frac{1}{4}$ in., the average being $\frac{1}{2}$ in. That this diminution has some definite bearing on the result is shown by the fact that the symptoms of the three which showed increase were not improved by the operation, while twenty-one of the twenty-two which showed diminution of the cavity were improved. Two of the uteri, which were increased in size, were very difficult to examine on account of the internal os being almost occluded, although the external os was patulous.

If the endometrium is hypertrophied from any cause, the probability is that the uterus will endeavour to expel it, just as it does all foreign bodies; this would especially occur during menstruation, when the mucous membrane becomes more swollen, and would account for the severe pain which most of these patients complain of at that time. Any muscular body with increased work in course of time hypertrophies. This occurs in the heart, stomach, bladder, etc., and it is only reasonable to expect it in a uterus which, for some time, has been endeavouring to expel a hypertrophied mucous membrane. I have found this to be the case in all the specimens examined by me; certainly most of them showed a slightly increased percentage of connective tissue, but this was very small compared with the great total increase in size of the uterus—an increase which is largely made up of new muscular tissue.

Theilhaber considers that the mesometrium is the starting-point in so-called chronic metritis, and that the changes, if any, in the endometrium are only secondary. This, I consider, he deduces from insufficient data. He divides his patients with chronic metritis into six groups: (1) girls at puberty, (2) weak, anæmic girls, (3) women at menopause, (4) women with diseased tubes or ovaries, (5) women with myomata, and (6) women with subinvoluted uteri. He states that in these patients he finds atrophy of muscle and increase of connective tissue (although Lorentz's figures for chronic metritic uteri are not very different from Meier's for normal uteri, if averages are

taken), and also increased size of the vessels. The uteri which he has examined microscopically and on which he bases his arguments are those of Lorentz. Of these nine specimens seven had been pregnant from three to thirteen times, and the other two were from married nulliparous women, aged 32 and 38 years respectively. None of these can be taken as examples of his first two groups, viz. girls at puberty or weak, anæmic girls. His third class, which includes women suffering from excessive hæmorrhage about the menopause, also occurred in my series of cases; but I can find no evidence to make me suppose that the symptoms are connected with the time of life, and are not the result of a primary endometritis, just as in all the other specimens.

Amongst the uteri which I examined, fourteen were from women of forty years old or more; of these, eight definitely dated the commencement of their symptoms from a confinement or a miscarriage; one had passed the menopause, and had had no hæmorrhage since; one had had the hæmorrhage for nine years, commencing when she was thirty-eight years old; and in another I could not obtain the date of onset of symptoms. This only leaves three (No. 2, No. 20, and No. 33) which might possibly be due to primary changes in the mesometrium at the menopause, but, microscopically, I find appearances similar to those occurring in the other examples of chronic metritis; they show no specially high percentage of connective tissue, nor are the vessels enlarged or thick-walled, but both have a much thickened endometrium. Nor do Lorentz's specimens, except his first, appear to bear out this statement, the other two, of more than forty years of age, having a pregnancy about the time of, or after, the commencement of the symptoms.

Out of twenty-three patients from whom I obtained a definite history, fourteen dated the commencement of their symptoms to a confinement or a miscarriage, three had symptoms previous to the last pregnancy, and only six had symptoms commencing at a considerable interval after

the last delivery. This class, in which the symptoms date from a confinement or miscarriage (Theilhaber's Group, No. 6), is the one in which I find most of these patients fall; I also find this borne out in the histories of large numbers of chronic endometritic patients. It is easy to imagine an endometritis being set up after a confinement or miscarriage, either through a slight degree of sepsis or from the retention of a small piece of membrane or placenta. This is sufficient to explain the symptoms (menorrhagia, metrorrhagia, and leucorrhœa) of these patients; the dysmenorrhœa is explained by the uterus contracting and making an effort to expel the swollen endometrium during menstruation. In process of time the contractions lead to hypertrophy of the uterus, and so account for the enlarged, hard uteri, and also for the constant aching pain found in these chronic metritic patients, due to the large, heavy uterus dragging on the broad ligaments. That the endometrium is primarily at fault is proved by the results of curetting (see pp. 31, 32). In the great majority of cases, in a few days tenderness has disappeared and the uterus is smaller; at a later period the uterus is found to remain diminished in size and the symptoms have disappeared or are improved. A certain number do not benefit from curetting, and require a repetition of the operation; a very small proportion are not improved with repeated curetting, and in these hysterectomy may be necessary. Failure of curettage does not, however, prove that the endometrium was not primarily at fault, since a certain amount of endometrium must always remain behind, and may be the starting point of a fresh endometritis. In virgins, in whom endometritis develops without any obvious reason, the causal element has possibly not been removed, and consequently may again develop endometritis. The specimens which I have been able to obtain, extirpated for chronic metritis, really represent the few failures in a very large number of patients on whom curettage was performed.

Chronic metritis may be associated with other pelvic or uterine diseases, such as tubo-ovarian inflammation, myo-

mata, and malignant disease of the cervix. I have examined seven examples of this: two in which it occurred along with small intra-mural fibroids, three with carcinoma of the cervix, one with a pyosalpinx, and one with double ovarian disease.

In each instance the uterus was much enlarged, globular in shape, increased in density, and the percentage of connective tissue was slightly increased; in fact, the appearances, macroscopically, were identical with those of chronic metritis; microscopically, however, the endometrium was not increased in thickness. These facts may be summarised as follows:

Conclusions.

(1) Chronic metritis is a simple hypertrophy of the mesometrium, and is not a connective-tissue hyperplasia.

(*a*) The uterus in chronic metritis is much enlarged, the increase being in all diameters: average length of uterus, 10·03 cm.; average length of cavity, 8·06 cm.; average width, 6·04 cm.; average thickness of wall, 2·48 cm.; average weight, 106·38 grm. The dimensions of a normal uterus are (Quain): length, 7·5 cm.; length of cavity, 6·39 cm.; width, 5 cm.; the thickness of wall, 1·25 cm.; weight, 33·41 grm.

(*b*) The percentage of connective tissue varies considerably in the different specimens of chronic metritis, but many normal multiparous uteri possess an equal, or even greater, proportion of connective tissue: the average amount in the specimens of chronic metritis was only 0·8 per cent. higher than in the normal parous uteri.

(*c*) The vessel changes are variable, and similar affections are found in normal uteri.

(*d*) There is no evidence of active inflammation, as shown by small-celled infiltration or cicatricial tissue.

(2) Chronic metritis is a slowly progressing affection of the uterus. In the early stage the uterus is simply enlarged, due to hypertrophy of the mesometrium; at a

later stage it tends to become denser and harder, but this is not due to increase of connective tissue or inflammatory changes.

(3) Chronic metritis is never a primary affection. It is usually secondary to chronic endometritis, but may be associated with any pelvic or uterine disease leading to increased uterine contraction or vascularity, viz. fibroids, tubo-ovarian inflammation, carcinoma, prolapsus, etc.

The age of patients with chronic metritis varied from twenty-three to fifty-four years, the average being 38·3. This is well below the average age at which the menopause occurs, and thus proves that the climacterium is not the causal factor in the complaint.

(5) The symptoms are mainly those of the primary disease. In the early stage chronic metritis is indistinguishable from chronic endometritis. At a later period the great increase in size of the uterus may produce symptoms—*i. e.* sacralgia and aching pain in hypogastrium and iliac regions due to traction on the broad ligaments.

(6) The diagnosis of chronic metritis is largely dependent on the result of treatment. In the early stage of the affection all the symptoms disappear after dilatation and curettage of the uterus, thus demonstrating that the endometritis is the primary cause.

(7) In chronic metritis and chronic endometritis local treatment of the endometrium may fail to relieve the symptoms. This is probably due to re-inauguration of the endometritis.

(8) *Treatment.*—A few patients are relieved by general treatment—*i. e.* living a simple hygienic life, with no very heavy work or too long standing, but with some occupation to prevent the patient from dwelling on her symptoms. The bowels must act freely ; douching, also, seems to have a beneficial effect. The great majority of the cases require curetting, and are much improved by it (see p. 31). In a few instances the symptoms are not relieved even by repeated curettings; in these cases nothing short of hysterectomy is of any avail. This drastic measure is,

however, only necessary in a small percentage of these patients. At St. Mary's Hospital, in 1905, 171 patients were curetted for chronic metritis or chronic endometritis, while, in the same year, only five hysterectomies were performed for these ailments.

Since writing the above paper a very important article has appeared, by Drs. Gardner and Goodall (Brit. Med. Journ.,' November 3rd, 1906) on "Chronic Metritis and Arterio-sclerotic Uterus," based upon the examination of nine uteri extirpated for chronic metritis.

It is satisfactory to find that the description of the microscopic appearances which is given by the authors is substantially the same as that which I have recorded, although they arrive at very different conclusions. They found hypertrophy or hyperplasia of both muscular and fibrous tissues in seven out of these nine cases. Further, they note the similarity of sections of chronic metritic uteri, fibro-myomatous uteri, and uteri with disease of the uterine adnexa. It will be remembered that in these last two kinds of cases I found similar changes in the uterine tissue, which I classified as "chronic metritis with some concurrent disease." So far, therefore, we are in agreement.

In the remaining two specimens the authors found changes which, as they themselves admit, are not characteristic of simple chronic metritis, but which they regard as secondary to a general arterio-sclerosis. These changes I have not found in any of my specimens.

As regards their conclusions, they believe that the intractable hæmorrhage, which is so frequent a symptom, is due to muscular insufficiency of the uterine tissue and the vessel walls. They have arrived at this conclusion because the fibrous tissue of the uterus is slightly increased in comparison with the muscular tissue, and because they found the adventitia of the vessels increased by a deposit of fibrous tissue in seven cases and in some of the cases the media of the vessels was similarly affected. But, after most careful comparison of my sections, I have

been able to establish no definite connection between these altered vessels and excessive hæmorrhage. Many of the specimens in which these vessel-changes are well-marked are normal uteri, while in other cases, in which the hæmorrhage was most pronounced and long continued, the vessels showed none of these changes.

In discussing the changes found in the endometrium, the authors state that they believe this affection to be primary and due to sepsis, when it is found in what we may call the usual type of case, but secondary to arterial changes when it is found in their second, or arterio-sclerotic type. How they differentiate between primary and secondary endometritis they do not state, nor is any difference obvious from their description of the microscopical appearances of their specimens. In my specimens of uncomplicated chronic metritis the endometrium was found thickened in all, with the exception of two, which were easily explained, but in every case of uncomplicated chronic metritis the endometrium was of normal thickness or thinner. But if changes in the endometrium were at any time secondary to changes in the mesometrium they ought to be found in the majority, at least, of cases of complicated chronic metritis. Further, the explanation of all cases of endometritis associated with chronic metritis as being due to either sepsis or secondary to arterial changes takes no account of the thickening of the endometrium associated with enlargement of the body of the uterus which is sometimes found in virgins (see Donald, 'Journ. of Obstet. and Gyn. of the Brit. Empire,' 1904). Some of the specimens which I have examined were virginal uteri, with changes which could not be differentiated from those found in parous uteri.

Under treatment they only consider hysterectomy after preliminary curettage if the diagnosis is uncertain, thus evidently drawing a hard and fast line between chronic metritis and chronic endometritis.

They also believe that ovarian function has some power over uterine hæmorrhage, and, in support of this, quote

one case in which menorrhagia continued for some time after curettage, but underwent spontaneous cure in the course of a few months. In our experience this is what very often occurs after curettage, the patient generally receiving more benefit from the operation after a lapse of a few months than immediately subsequent to it.

Note.—The tables of cases are published in the 'Journ. of Obstet. and Gyn. of the Brit. Emp.,' vol. xi, February, 1907, pp. 140–150.

Bibliography.

Addinsell.—Chronic Infective Metritis, Journ. of Obstet. and Gyn. of the Brit. Emp., vol. x, 1906, p. 6.

Anspach.—Metrorrhagia Myopathica, Amer. Journ. of Obstetrics and Diseases of Women and Children, January, 1906.

Barbour.—Allbutt and Playfair's System of Gynæcology, 1896.

Becquerel.—Traité clin. des maladies de l'utérus.

Bennet.—A Practical Treatise on Inflammation of the Uterus and its Appendages, 1849.

Cullen.—Cancer of the Uterus and Pathology of Diseases of the Endometrium, 1906.

Cholmogoroff.—Monats. für Geburts. und Gynäkol., Bd. 11, 1900, p. 692.

De Sinéty.—Manual de Gynécologie, 1879.

Doléris.—Métrite et fausses Métrites, 1902.

Donald.—Chronic Endometritis and Chronic Metritis in Virgins, Journ. of Obstet. and Gyn. of the Brit. Emp., April, 1904.

Fordyce.—Chronic Metritis and Endometritis, Encyclopædia Medica.

Fothergill.—Some Recent Work on So-called Chronic Metritis and Endometritis, and their Relation to the Life-history of the Uterine Muscle, Practitioner, March, 1904.

Findley.—Diagnosis of Diseases of Women, 1905.

Findley (Palmer).—Arterio-sclerosis of the Uterus as a Causal Factor in Uterine Hæmorrhage, Amer. Journ. of Obstet., July, 1905.

Finn.—Centralbl. für med. Wissensch., 1868, S. 564.

Fritsch.—Diseases of Women, 1883, pp. 151–168.

Foerster.—Spec. Path. Anatomie, p. 314.

Galabin.—Diseases of Women, 1903.

Walker Hall and Herxheimer.—Methods of Morbid Histology and Clinical Pathology, 1905.

Herman.—Diseases of Women.

Hart and Barbour.—Diseases of Women.

Hektoen and Riesman.—Text-book of Pathology.

Huguier.—Gaz. des Hôp., 1849, p. 127.

Jellett.—A Short Practice of Gynæcology, 1903.

Klebs.—Handbuch der patholog. Anatomie.

Lorentz.—Archiv für Gynäkol., Bd. lxx, 1903, p. 309.

Leith.—The Menopause and its Disorders, 1897.

Meier.—Archiv für Gynäkol., Bd. lxvi, 1902, p. 15.

Macgregor (Jessie).—A Contribution to the Pathology of the Endometrium, 1905.

McReynolds.—The Use and Abuse of the Curette, Amer. Journ. of Obstet., June, 1905.

Nonat et Linas.—Traité pratique des maladies de l'utérus, de ses annexes et des organes génitaux externes, 1874, p. 213.

Pichevin et Petit.—Gaz. Méd. de Paris, 1895.

Quain's Anatomy, vol. iii, part 4, p. 260.

Robertson.—Endometritis: Its Pathology and Treatment, Amer. Journ. of Surgery, January, 1905.

Reinecke.—Die Sklerose der Uterinarterien und klimakterischen Blutungen, Archiv für Gynakol., Bd. liii, 1897, p. 340.

Schroeder.—Ziemssen's Cyclopædia of the Practice of Medicine, 1875, vol. x, pp. 101—139.

Scanzoni.—Die chronische Metritis, 1863.

Simpson (Sir J. Y.)—Diseases of Women, 1872.

Thomas.—Diseases of Women, 1869, p. 254.

Theilhaber.—The So-called Chronic Metritis, its Causes

and its Symptoms, Archiv für Gynäkol., Bd. lxx, 1903, p. 411.

Theilhaber.—Die Variationem im Bau des Mesometrium und deren Einfluss auf die Entstehung von Menorrhagien und von Fluor, Archiv für Gynäkol., Bd. lxvi, 1902, p. 1.

Theilhaber.—Schlussfolgerungen aus den von andern Autoren am Mesometrium blutender Frauen erhobenen Befunden und aus unseren Untersuchungen, Archiv für Gynäkol., Bd. lxvi, 1902, p. 40.

The President thanked Dr. Shaw for his valuable paper. It was an important step towards putting the study of so-called "metritis" on a scientific basis. Dr. Shaw had carefully controlled his observations on the diseased uteri by examining the uteri of normal subjects, and his resulting opinion was, in consequence, a safe foundation. The President used the term "so-called metritis" because, as far as he could see, there was nothing indicating inflammation in any of Dr. Shaw's sections or descriptions. In fact, both "metritis" and "endometritis" as used at present by many did not necessarily mean anything connected with inflammation. These terms, however, led students and others astray, and ought to be reserved for inflammatory processes. He would appeal to both Dr. Donald and Dr. Shaw, as among the pioneers in this research, not to countenance such misuse of terms.

Dr. Cullingworth said that he knew Dr. Donald's paper to be the outcome of much careful clinical observation, of prolonged thought, and of strong conviction. The subject was one that had engaged the author's attention, to his (the speaker's) knowledge, for many years. With reference to Dr. Shaw's paper, he thought the Fellows would be interested to know that it was based upon a thesis which had been presented to the Victoria University of Manchester for the M.D. degree, and to which the authorities of that University had awarded the distinction of a gold medal. The paper represented three years' hard work. The two authors, though both were Manchester men, had not worked in collaboration, but approaching the subject independently, the one from a clinical, the other from a pathological standpoint, they had gradually become aware of each other's work, and of the fact that the conclusions at which they had arrived were practically the same.

Dr. Amand Routh said no subject in minor gynæcology was more perplexing than that of chronic metritis. Some patients, with large, hard uteri, would suffer from menorrhagia and no local pain, whilst others, with, apparently, a similar uterus,

would have no hæmorrhage, but considerable pelvic discomfort. Curetting frequently relieves such patients, even when the scrapings are insignificant in quantity, when, in fact, an atrophic "endometritis" has succeeded to the hypertrophic "endometritis" which the authors appear to have mainly dealt with. Did the authors consider all their cases to be "septic" in origin? Were not some of them really of the type usually known as arterio-fibrosis of the uterus?

Dr. Russell Andrews said that he thought that Dr. Fletcher Shaw deserved the thanks of the meeting for his clear demonstration of the fact that there were no characteristic histological changes in "chronic metritis." One reason why some gynæcologists were loth to accept chronic metritis as a clinical entity was that the slides and microphotographs used to illustrate some papers on this subject showed changes in the muscle, connective tissue, and vessel-walls, which were said to be pathognomonic of chronic metritis, though they differed in no way from what was seen in normal, multiparous uteri. He thought that this was one of the most interesting points in a very interesting demonstration.

Dr. Cuthbert Lockyer expressed his hearty appreciation of Dr. Fletcher Shaw's admirable and painstaking work upon the much vexed question of the pathology of so-called chronic metritis. He thought this Society owed a debt of gratitude to Dr. Shaw for his paper and demonstration, which constituted the first really scientific attempt at evolving order out of chaos (as far as this subject was concerned) which had been presented for discussion at the Obstetrical Society of London. It was true that the Society's attention had previously been drawn to certain histological features in uteri said to be in a state of "chronic metritis," but such conditions as were noted could all be found in parous uteri devoid of such clinical symptoms as hæmorrhage and subinvolution. Dr. Shaw's demonstration was convincing from the fact that he was careful to demonstrate the histology of the normal side by side with that of the abnormal uterus, and, again, his systematic three years' work embraced a mass of material which, from its very bulk, added valuable weight to his conclusions. It was interesting to note the uniform finding of concomitant mucosal hypertrophy, with similar changes in the mesometrium. In cases the speaker had examined hysterectomy had frequently followed a comparatively recent curettage, and for this reason, probably, the specimens showed no excess of thickness in the lining membrane of the cavum uteri. Dr. Lockyer was, however, quite familiar with changes in endometrial scrapings, which were analogous in all the details of hypertrophy and hyperplasia (including early fibroblastic invasion and new vessel formation), which are to be found in the fibromuscular walls of uteri removed for hæmorrhage and increased

weight. Dr. Lockyer particularly noted that Dr. Shaw's series of cases did not include one type of uterus in which he himself was especially interested, and to which attention had been drawn by Dr. Goodall at the meeting of the British Medical Association at Toronto, in August, 1906, viz. the arterio-sclerotic uterus. The speaker, from his own clinical and pathological experience, agreed with Dr. Goodall that there was a type of uterine disease which affected, primarily, the vessels of that organ—a disease characterised by great thickening and hyaline degeneration of the middle coats of the vessels, together with irregular thickening of the intima. These changes lead to actual occlusion of some of the vessels, to compensate for which new vessels can be found in the process of formation. Now, such uteri are found to be associated with general cardio-vascular changes, such as are seen in Bright's disease, and clinically give rise to intractable hæmorrhage. If the latter be treated by curettage the scrapings are *not* abundant, and are principally characterised by a fibroblastic invasion, starting in the deeper layers of the mucosa and working outwards. This leads to fibrous tissue formation, destruction of gland-tubes, and atrophy of the mucosa itself. Attention has been drawn to this condition, not only by Dr. Goodall, but by Dr. Freeland Barbour, in a paper entitled "Climacteric Hæmorrhage due to Sclerosis of the Uterine Vessels" ('Scottish Medical and Surgical Journal,' June, 1905), and, as this author states, the only remedy for the hæmorrhage is removal of the uterus. Dr. Lockyer cited a similar case from his own practice, at St. Mary's Hospital, Plaistow, and it was surprising to him that in such an extensive research Dr. Shaw had not met with this condition. Dr. Lockyer would, therefore, like to hear from Dr. Shaw whether he regarded every case of so-called chronic metritis as of infective origin, or if he would admit the entity of a primarily arterio-sclerotic uterus occurring independently of any source of infection from without.

Dr. Frank E. Taylor said that he had been much impressed by two points during the routine pathological examination of a considerable number of uteri, similar in character to those described by Dr. Donald and Dr. Shaw, which had been removed on account of excessive and intractable hæmorrhage. The first point was the extreme variability of the histological findings presented by the various specimens examined, some uteri presenting histological features which differred very slightly from those of normal uteri, whilst others presented most striking changes, especially as regards the thickness of the vessel-walls in the myometrium. All intermediate stages were likewise observed. The second point was the lack of a normal standard with which to compare the conditions found in chronic metritis—as to what amount of thickening of the vessel-walls in the myometrium could be considered pathological, and as to the significance of the relative proportion of fibrous to muscular tissues present, along

with the difficulty of definitely ascertaining this proportion. He (Dr. Taylor) agreed with Mr. Targett that, *à priori*, one would expect to find more marked changes in the endometrium than in the myometrium in uteri causing such excessive and persistent hæmorrhage, but in the majority of the cases examined by him the changes in the endometrium, beyond, possibly, some hyperplasia, were usually not very marked, whilst the myometrium showed more definite changes, which changes usually consisted in great thickening of the vessel-walls. It was, he considered, an extremely difficult matter to explain the uterine hæmorrhages on the ground of these histological findings. Both Dr. Donald and Dr. Shaw had laid great stress on the importance of infection as a causative factor in the etiology of chronic metritis, and had mentioned the frequency with which the symptoms dated from a confinement or miscarriage—presumably septic. Now, gonococcal infection was probably as frequent as puerperal infection of the pelvic viscera. Hence, it might have been expected, if infection were really an important factor, that a history of gonococcal infection would have been present in a certain proportion of the cases, but of such a possible origin neither Dr. Donald nor Dr. Shaw made any mention.

FEBRUARY 6TH, 1907.

W. R. DAKIN, M.D., President, in the Chair.

Present—40 Fellows and 3 visitors.

A book was presented by Mr. J. Bland-Sutton.

George Hope, D.P.H., L.R.C.P., M.R.C.S.Lond., was admitted a Fellow.

F. Ernest Withers, M.R.C.S., L.R.C.P. (Horncastle), was declared admitted.

The following gentlemen were proposed for election :— Archibald Montague Henry Gray, M.D., B.S.Lond.; Clifford White, M.D., B.S.Lond.; and James Montague Wyatt, M.R.C.S., L.R.C.P.Lond.

The following gentleman was elected a Fellow of the Society :—Lewis Graham, B.S.Lond., M.R.C.S., L.R.C.P.

Report of the Pathology Committee on Dr. Amand Routh's Specimen of a Fibromyoma of the Uterus with a Sarcomatous Nodule in the Centre (*see p.* 1).

WE have examined this specimen and the microscopic sections taken from it, and agree that the nodule is a true giant-celled sarcoma, invading the co-existing fibromyoma. We find no evidence of sarcomatous degeneration of the fibromyoma. The invasion of this tumour by the sarcoma is of quite limited extent.

(*Signed*) JOHN S. FAIRBAIRN,
CUTHBERT LOCKYER,
C. HUBERT ROBERTS,
CORRIE KEEP,
G. BLACKER, *Chairman*.

A VILLOUS TUMOUR OF THE BODY OF THE UTERUS IN A WOMAN, AGED 84; VAGINAL HYSTERECTOMY; RECOVERY.

By J. Bland-Sutton.

A villous tumour of the uterus is, I think, very rare, and the interest of this report is increased from the fact that the patient is a multipara, aged 84. Except for a blood-stained vaginal discharge this old lady seemed in perfect health, but the character of the discharge made those in charge of the patient suspect that she was the victim of cancer of the body of the uterus. In order to establish a diagnosis the uterus was curetted, and a microscopic examination of the scrapings caused the pathologist to pronounce the disease to be cancerous; but it was thought that the patient's advanced age contra-indicated a radical operation.

Dr. W. A. Milligan asked me to see the patient with a view to operation, for, notwithstanding her advanced age, she seemed to be thoroughly capable of bearing an operation, and especially as the uterus did not appear to be greatly enlarged. After careful consideration I performed vaginal hysterectomy in September, 1906, and the operation was followed by an excellent and quick convalescence.

The uterus was hardened in a solution of formalin and bisected (see Fig. 1) in its sagittal axis. The uterine cavity is filled with a soft, yellowish mass, which grows from the endometrium covering the posterior surface. Thin sections were successfully cut in such a way as to involve the walls of the uterus and the growth. On microscopic examination we found that the free portion of the tumour consists of compound villous processes covered with columnar epithelium. Its resemblance to a villous tumour of the bladder is complete in every particular, except that the investing epithelium is identical with that covering the normal endometrium.

We critically examined the base of the tumour and find it consists of the peculiar cells which compose the reticulum of the normal endometrium, and it does not infiltrate the subjacent muscular wall of the uterus. From

FIG. 1.—A uterus in sagittal section. The cavity is dilated and occupied by a villous tumour growing from the posterior wall. From a multipara, aged 84.

the histologic standpoint it is clearly a non-malignant tumour.

Although I have devoted much attention to the histology of uterine tumours I have only seen one other example of a villous tumour of the corporeal endometrium. This occurred in a multipara, aged 56, and I removed the uterus under the impression that it was cancerous, but in the laboratory Dr. Foulerton and myself have,

after repeated examinations of the section, been unable to make up our minds on the question of malignancy. This operation was performed six years ago, and, as the woman remains in good health, it is therefore a fair assumption that a typical villous tumour of the uterus is not malign. Moreover, in this case the villi were long, slender, and simple.

I believe that a typical villous tumour of the corporeal endometrium with compound villi is a rare condition.

Dr. Amand Routh alluded to a case of malignant papilloma which he had shown in this Society in January, 1897 ('Obstet. Soc. Trans.,' vol. xxxix, p. 5). The patient was aged 57, and had metrorrhagia. Her uterus was dilated and a soft growth curetted away in June, 1894. This was repeated in March, 1895, and in April, 1896. On the two previous occasions Dr. W. H. Tate described the scrapings as benign papilloma. On the last occasion Mr. Targett reported that the growth was a delicate papilloma, essentially resembling the common fimbriated variety of the urinary bladder. He added that the specimen could not be described as malignant. Six months aftewards, as hæmorrhage recurred, Dr. Routh removed the uterus *per vaginam*. Mr. Targett then reported that there was distinct evidence that the papilloma had invaded the muscle-walls, but still retained its papillomatous type, thus differing from the columnar carcinoma of the uterine body. Dr. Routh believed that any new growth occurring in the uterus, after the menopause, was apt to take on a malignant development, and should be treated accordingly. He was surprised, therefore, to hear that the base of the growth in Mr. Bland-Sutton's case was not involved.

Dr. Milligan said that the clinical history of the case extended from July, 1905, at which time the patient began to suffer from a discharge, which ultimately became blood-stained. There was never, as Mr. Bland-Sutton had said, a copious loss of blood, the discharge all the way through being nothing more than what could be called a blood-stained discharge. In addition to this there was a certain amount of abdominal pain and backache. Examination of the pelvis revealed a freely movable uterus. The patient made an excellent recovery ofter the operation, and at the present time is remarkably well. The examination of the curettings certainly pointed to the case as being one of columnar-celled carcinoma of the body of the uterus. He had had an opportunity of examining Mr. Bland-Sutton's section through the growth, and certainly he could not detect any infiltration of the muscular wall of the uterus. It is noteworthy if the

case be one of an ordinary villous tumour, that the hæmorrhage was not more severe than it was.

Dr. Cuthbert Lockyer: In reference to the total absence of invasion of uterine muscle by the complicated villous adenoma of the endometrium Dr. Cuthbert Lockyer asked Mr. Bland-Sutton what, in his opinion, would have happened had the growth been thoroughly curetted? Would there have been a recurrence?

The specimen was referred to the Pathology Committee.

PREGNANCY IN THE RIGHT CORNU OF A FIBROID UTERUS.

By Mrs. Boyd.

The specimen showed a diffuse fibromyoma of the uterus occupying the whole of the supra-vaginal portion of the cervix and the greater part of the body, partially intra-ligamentous and subperitoneal in its development, and complicated by pregnancy in the right cornu of three to four months' duration. The specimen was removed by abdominal pan-hysterectomy, after enucleation of the lower intra-ligamentous portion, from a patient, aged 42, married two and a half years, without family.

On admission there was a history of four months' amenorrhœa, the periods being replaced by slight vaginal, blood-stained discharge, and two months' severe pain in the abdomen, coming on in definite attacks, with frequency of micturition, and increasing constipation.

Examination on admission showed slight hæmorrhage to be going on. A hard, ovoid tumour occupied the centre of the abdomen, extending to a point half way between the umbilicus and the xiphisternum. At the right upper pole was a definitely cystic portion. *Per vaginam* the cervix, much softened, was displaced to the right by the lower pole of the hard, abdominal tumour, which filled the pelvis. A diagnosis was made of pregnancy complicating fibroid with impending miscarriage, and operation was undertaken the following day.

Mrs. Boyd drew attention to the extreme thinning of

the uterine wall in the region of the right cornu, where the ovum was developing, and compared it with a similar specimen exhibited by her in March, 1904, where marked thinning of the stretched uterine wall was also well seen. In the present instance the placenta was implanted on the area where the greatest thinning had occurred, the uterine wall being here little more than one eighth of an inch in thickness. She remarked on the similarity between the risks of these cases and those of interstitial cornual pregnancy, and suggested that the danger of rupture of the distended and thinned-out uterine cornu made early operation, apart from the question of impending miscarriage which determined operation in this case, advisable where the lower portion of the uterus was blocked by fibroids, and only a small portion of the upper part of the cavity was left available for gestation. She thought that rupture through the placental site, with its attendant enormous danger, might well have occurred had this case been allowed to proceed in the hope of delivering a viable child by Cæsarian section.

Dr. Amand Routh agreed that Mrs. Boyd's treatment had, in this case, been the correct one, but could not agree with her general statement that, owing to the risk of rupture of the uterus from thinning of the uterine walls in these cases of pregnancy and fibroids, hysterectomy, in the early months, was called for. He knew of no such risk, and thought that, as a general rule, with very few exceptions, no operation should be done till fœtal viability, and that usually it was best to wait till nearly full term.

Dr. Herman asked if rupture of the uterus during pregnancy was not an extremely rare event? When investigating the subject some years ago he had only been able to find one indubitable case of rupture of the uterus during pregnancy (apart from labour and rupture of interstitial gestation sacs).

ADENO-CARCINOMA OF THE OVARY.

Shown by Mrs. Boyd.

Mrs. Boyd showed a specimen of papilliferous cystic adeno-carcinoma of the left ovary removed from a patient

aged 54. The interest lay in the facts of the case rather than in the specimen itself. The patient had been operated on ten years previously in St. Bartholomew's Hospital, where the uterus was removed by vaginal hysterectomy for typical squamous carcinoma of the cervix. She was admitted to the New Hospital for Women in November, 1906, with the abdomen enormously distended by ascites. She had noticed the distension for two months, and was otherwise in excellent health. After withdrawal of fifteen pints of ascitic fluid by tapping, a nodular growth could be felt adherent to the left side of the vaginal scar. Fluid rapidly re-accumulated and the abdomen was opened, and a cystic papilliferous tumour, of the size of an orange, was removed; it had to be dissected out of the vaginal scar, in which it was firmly embedded. It proved to be a cystic adeno-carcinoma.

Mrs. Boyd congratulated Dr. Griffith, under whose care the patient had been ten years previously, on the success of the vaginal hysterectomy—a cure so complete as to allow the patient to develop ten years later a second independent focus of malignant disease of a different type. Unfortunately, no section of the early growth of the cervix could be obtained for comparison with the ovarian growth recently removed.

CO-EXISTING TUBAL AND UTERINE PREGNANCY; ABDOMINAL SECTION; SUBSEQUENT DELIVERY AT TERM.

By Walter Tate, M.D., F.R.C.P.

Mrs. S—, aged 37, had her first and only child ten years ago. From that time she enjoyed good health, and had normal menstruation till February 21st, 1906, when the last period occurred. In March she saw nothing. During the second week in April she began to feel ill, suffering from some pain, sickness, and diarrhœa. On April 20th the patient had two attacks of severe pain

over the lower part of the abdomen. She also had a slight hæmorrhagic discharge, with some pain, on one or two occasions between April 20th and 30th, when the patient was first seen by the writer. On examination the uterus was found to be enlarged and lying behind the pubes. On the left side there was a firm swelling, about as big as a duck's egg, in the situation of the left appendages. The condition was thought to be one of tubal mole, but the patient was very anxious to avoid operation unless it was immediately necessary.

In a case like this, when the patient had the severe attack of pain ten days before being seen, and where, on examination, a firm mass is found in the situation of the appendages of one side, it may fairly be assumed that the ovum is dead, and we have to deal with a tubal mole. Even if further hæmorrhage does occur in such a case, it is unlikely to be of the very severe type of intra-peritoneal bleeding if the patient is kept absolutely at rest in bed. It was, therefore, decided that the patient should be kept at rest in bed, and in the event of further pain, indicating recurrence of the hæmorrhage occurring, abdominal section was to be performed. The patient was kept in bed for three weeks, and during this time had no more pain, and her general condition improved. A few days after beginning to get about a little she had a return of the pain, and a week later had another bad attack. There had been no irregular hæmorrhagic discharge. On June 6th, 1906—that is, five weeks and two days after my previous visit—I again saw the patient. There was nothing to note specially about the general appearance and condition of the patient, which were quite satisfactory. The abdominal condition, however, had altered, for there was now a well-defined, elastic and tender swelling in the lower abdomen on the left side, extending out to the iliac fossa. *Per vaginam*, it was noticed that the uterus was much larger than is usually found in cases of tubal pregnancy, and to the left of, and continuous with it, was a swelling as large as the closed fist in the situation of the left appendages.

As it was evident that the return of the pain and the increased size of the pelvic swelling were caused by further hæmorrhage, the patient was advised to submit to operative treatment, and on the following day laparotomy was performed. When the abdomen was opened a little dark blood was seen about the coils of intestine, contiguous to the appendages on the left side, and an ounce or two of dark blood was removed from the pelvis. The uterus was very soft and elastic, and enlarged to the size of a three months' pregnancy. The enlarged left appendages were covered by adherent blood-clot, and were roofed over by adherent omentum and some coils of bowel. The adhesions were readily separated, and the appendages of the left side removed. The right appendages were normal. The pelvis was swabbed out with a little normal saline solution, and the abdomen afterwards closed.

The parts removed consisted of the Fallopian tube, containing a tubal mole, which had probably advanced to the eighth or ninth week. The mass was about as big as an orange. The uterine end of the tube had a normal appearance. The fimbriated end was contracted to the size of a cedar pencil, and the umbilical cord was seen issuing from this. At one part of the gestation-sac the chorionic villi had penetrated the wall of the Fallopian tube, and were clearly evident on the surface. On laying open the sac by a longitudinal cut along the tube the wall was seen to be thickened, varying from a quarter to half an inch in thickness, owing to hæmorrhage. The amniotic sac was about two inches in diameter, and the origin of the umbilical cord, with one and a half inches of this structure, was seen springing from the inner surface of the sac near the fimbriated end. There was naturally some anxiety after the operation, lest a miscarriage of the uterine pregnancy should occur. Fortunately this complication was avoided, and the patient made an uninterrupted recovery.

Three weeks after the operation the uterus was found to reach halfway between the pubes and umbilicus.

The patient was discharged at the end of a month, and returned home. She had no trouble whatever during the remaining months of pregnancy, and a living, healthy child was born on November 30th, 1906. The confinement was normal and only lasted four hours. The child, which was a female, weighed 6½ lb.

CASE OF SUPPURATION IN FIBROMYOMA UTERI FOLLOWING PREMATURE DELIVERY, TREATED BY ABDOMINAL HYSTERECTOMY.

By Walter Tate, M.D., F.R.C.P.

Mrs. K—, aged 37, was married four years ago. Nine weeks after marriage she had a miscarriage at the second month of pregnancy, but had no complications after this. Before her marriage a fibroid tumour of the uterus as large as an orange had been discovered by her medical attendant in the course of an examination for some minor ailment. It was not causing any special symptoms. In September, 1905, the patient again became pregnant, and was delivered in the middle of March, 1906, of a dead fœtus at about the sixth month. Two days later she had rigors and high fever, and apparently a parametric abscess developed, which is said to have burst *per vaginam*. She had a long, tedious convalescence, being in bed many weeks, and in June she was sent away to Weymouth. On returning home again in July a sinus could still be felt in the left vaginal fornix, and the uterine fibroid was half as large again as it was after the confinement. The patient was better on the whole, but, as she was much troubled with hæmorrhoids, an operation was performed for the removal of these. Soon after this operation the temperature began to go up at night, and the tumour began to increase more rapidly.

At the beginning of September, when the patient again

consulted her medical attendant, she had been having irregular temperature for some weeks, and was suffering from a profuse offensive discharge from the vagina. It was evident that the fibroid had begun to grow much more rapidly, and on palpation the tumour was very tender. The patient had also lost a good deal of flesh and looked ill. She was kept in bed for a time and hot vaginal douching administered, but as the tumour continued to increase and the patient was steadily losing ground, she was sent up to town with a view to operation.

On October 2nd, 1906, the patient was seen by Dr. Tate, and looked exceedingly ill and emaciated. The expression was anxious, and the skin had an earthy hue. The abdomen was occupied by a tumour as large as a seven months' gestation. It was very tender and elastic, and fairly mobile. On vaginal examination the cervix was felt high up, and a portion of the tumour bulged down the anterior fornix. Nothing could be felt of the discharging sinus which had been observed by the medical attendant early in August.

The appearance of the patient was very suggestive of a malignant growth, but in view of the hectic fever which had persisted for some weeks, and also the history of septic trouble with abscess in the pelvis which developed during the puerperium, it seemed more than probable that the case would prove to be one of suppuration in a fibroid.

The patient was kept at rest in bed for a few days to recover from the fatigue of the journey to town, and during this time the irregular fever, varying between 99° F. and 102° F., persisted.

On October 7th abdominal hysterectomy was performed. The uterus was completely removed. There was no difficulty in the operation, and not a single adhesion in the pelvis. This fact proves that the abscess, which discharged *per vaginam* after the confinement, was parametric and not intra-peritoneal.

The uterine tumour removed was spherical in shape,

and the surface of the tumour had a yellowish-white appearance, which was quite different from what is usually seen. The uterine canal passed upwards along the posterior and left aspect of the mass. The tumour had burrowed somewhat into the right broad ligament, but it grew chiefly from the anterior wall of the uterus. On carefully incising the anterior wall of the mass a large cavity was opened up, from which was let out $3\frac{1}{2}$ pints of the most offensive pus, having a greenish-yellow colour. Remains of fibroid growth formed a very irregular wall to this cavity, and in the centre of the cavity was a sloughing mass of fibroid tumour about as large as the palm of the hand, which was quite free in the cavity. The whole inner surface of the cavity was very ragged, and the uterine wall adjacent was œdematous.

A cover-smear preparation was made from some of the fluid in the interstices of the fibroid, and numerous Gram's positive bacilli and a few streptococci were seen. All the culture media, both aërobic and anaërobic, remained sterile at the end of the fourth day. The cultures were inoculated at the bedside.

The following is the report of the microscopical examination of the wall of the cavity :

"The longitudinal fasciculi (which form the investiture of this growth) are teased asunder by an œdematous process, which is not an unusual feature in the capsules of interstitial growths of any size. The fibroid itself has an area of so-called myxomatous degeneration, represented histologically by a granular, fibrinous network, displacing the fibromuscular bundles. The bulk of the section shows the structure of normal looking fibromyomatous tissue. The tumour shows no sign of pyogenic inflammation."

Both these reports were supplied by the Laboratories of Pathology and Public Health.

The patient's temperature steadily fell after the operation, and by the third day it was normal. She continued to gain strength and improved remarkably in appearance

during the first fortnight. At the end of this time she began to have pain in the pelvis and some return of fever, and six days later a tender, fluctuating swelling was found slightly depressing the posterior vaginal wall. The swelling was incised and a collection of pus evacuated. After this the patient made an uninterrupted recovery.

CHORIO-ENDOTHELIOMA OF UTERUS; INTRA-PERITONEAL HÆMORRHAGE; HYSTERECTOMY; DEATH.

By the late Dr. G. Bagot Ferguson.

[The Society cannot fail to admit how painful are the circumstances under which this specimen is exhibited. On September 14th, 1906, my friend and old fellow-student, Dr. G. Bagot Ferguson, of Cheltenham, a Fellow of this Society, sent me the specimen which I bring forward this evening, and expressed a desire that I should exhibit it for him at one of our meetings. Some correspondence followed the receipt of the specimen, as I considered that full particulars of the case were necessary, and the last letter which I received from Dr. Ferguson reached me only nine days before his terribly sudden decease, on November 27th, when performing an operation. I am much indebted to Dr. Robert Kirkland, Physician to the Cheltenham General Hospital, for kindly supplying me with full notes of the case, which was originally under his care in that institution, and to Mr. Shattock and Dr. Cuthbert Lockyer for their opinion of the pathological characters of the tumour. *Alban Doran.*]

Dr. Kirkland's Report.

L. G—, married, aged 20, admitted into the Cheltenham General Hospital on September 4th, 1906, under Dr. Kirkland.

Family history unimportant.

Personal history.—The patient had always enjoyed good health. She had been married one year. About three months before admission she felt poorly, and consulted a doctor, who informed her that she was suffering from anæmia. Menstruation had ceased for three months, but about three weeks ago she noticed a "dirty-water discharge tinged with blood." She stated that her abdomen had been increasing in size for about a month. On September 4th she was suddenly seized with severe pain over the lower part of the abdomen, with sickness, and her doctor advised her to seek admission into the hospital. She was admitted under Dr. Kirkland, who saw her on September 5th. He found her sitting up in bed with severe dyspnœa, and pallor was very marked. Temperature 100·4° F., respiration 48, pulse 114, soft and slapping. She complained of pain in the lower abdomen, where a fulness could be seen extending nearly to the umbilicus. The abdominal wall was somewhat rigid and exceedingly tender. A large, round, and regular swelling could be felt extending from the pelvic brim to the umbilicus, and, laterally, more towards the right than the left. At the right side its margin seemed well defined, and the fingers could be insinuated between it and the iliac fossa, whilst it was not so well defined on the left side. The percussion note was dull over the swelling, but resonant all round. Dulness did not change when the patient was placed on her side. The tumour seemed movable laterally to a slight extent. On vaginal examination the cervix felt soft and short, the uterus was enlarged, and continuous with the swelling on the right side. The os did not admit the finger. There was no hæmorrhage, nor any other kind of discharge, nor any offensive odour. The pouch of Douglas did not feel full nor boggy. A hæmic murmur could be heard over the pulmonary area. At the base of the left lung, from beneath the heart to the spine, there was impaired resonance with crepitation and faint breath-sounds. There was neither expectoration nor hæmoptysis. The liver dulness was normal, the spleen not palpable.

The diagnosis was pregnancy in the third or fourth month complicated by an ovarian cyst with twisted pedicle and intra-cystic hæmorrhage. As operative interference might be required at any moment, Dr. G. B. Ferguson was asked to see her. He suggested the possibility of ectopic gestation. Deciduoma or chorion-epithelioma was considered improbable. As there was no definite history of abortion, and as the diagnosis was very uncertain, it was agreed that operation should be postponed.

On September 6th the patient had less pain and distress. On the 7th the sclerotics were noticed to be slightly tinged, and the integuments had a generally diffused icteric tint. On the 8th the pain again became severe, and the vomiting recurred. It was found that the tumour had suddenly increased in size, extending to an inch above the umbilicus. There was, as throughout the patient's illness, no hæmorrhage from the vagina. At a point midway between the umbilicus and right iliac spine the maternal pulsations could be heard distinctly simulating fœtal pulsations. Operation was again postponed.

For a week after this examination the patient's condition remained but little changed. The temperature, which had fallen, never rose again to 100° F., but seldom fell below 99° F. at night. The pulse, however, remained high—between 120 and 130.

On September 14th the patient became, if possible, more pale, and grew extremely weak and restless, the pulse rising to 138. As she was evidently dying it was decided to open the abdomen at once.

Dr. G. B. Ferguson's Report.

I was asked this afternoon, September 14th, 1906, to operate upon a young woman, aged 20, one year married, who had symptoms of pregnancy and abdominal hæmorrhage. I found a rough, red tumour which had originated within the uterus, but had perforated it above and was fungating and bleeding. The peritoneal cavity contained

much blood. I could find no fœtus. Both ovaries were cystic. Some omentum adhered firmly to the uterus, but was separated and removed later. One of my colleagues injected all the time during the operation, which lasted half-an-hour, saline solution with 1 in 100,000 adrenalin into the basilic vein, and warm saline was lavishly poured into the abdominal cavity, wetting me to the skin. Soon after I had cleared all away and sewed up the abdominal wound the patient died.

The tumour had all the characters of a deciduoma.

Dr. Lockyer's Report of the Specimen.

The uterus is expanded and much distorted by a large, solid, corporeal growth, which has eaten its way through the fundus, where it presents as a red, fungating mass. Shreds of omentum adhere to the mass. The specimen measures 8 in. across and 6 in. from above downwards. As I received it the uterus was divided by an anterior sagittal incision, exposing its cavity, which is filled as far as the os internum by a soft, red growth. The cervix appears to be quite free from invasion. Above, the growth has completely eroded the fundus, and extends for a considerable distance above its limits. Posteriorly the peritoneal surface of the uterus is much altered by the proximity of the tumour. In the upper half of the corpus uteri the tumour presents posteriorly as dark-blue bosses, covered only by peritoneum; in the lower half the peritoneum and muscle of the uterine wall are normal in appearance. Sections taken through the entire length of the cervix and lower pole of the growth show that the tumour invades the body of the uterus as far as the internal os, whilst the cervix remains healthy.

Microscopic appearances.—The tumour consists of a combination of syncytium and its derivatives, with columns and masses of Langhans's cells. The syncytium can be

seen invading vessels and taking the place of the endothelium of their walls.

The *ovaries* are converted into cystic bodies, the larger measuring 11 in. and the smaller 8 in. in circumference. It is not clear which is the right and which the left ovary. Two malignant nodules are attached to the larger ovary; one is of the size of a small Tangerine orange, and occupies its lower pole, whilst the other nodule consists of two lobes of the size of filberts, and lies higher up. Both ovaries contain a number of thin-walled cysts, appearing on the surface as semitransparent bullæ and dark-purple, grape-like bodies. On cutting into the substance of the larger ovary the malignant growth was found, as may be seen on inspecting the specimen, to penetrate one of the cysts. Both ovaries are cystic throughout; their solid, central core is reduced to a minimum. The largest cysts lie towards the periphery, the smallest towards the centre.

Microscopic appearances.—The cysts in both ovaries are lined with an abundance of lutein cells of the type observed in early pregnancy. Some of the cysts have a fibrinous investment internal to the lutein lamina; others have no such investment. The malignant growth is composed of Langhans's cells packed into alveoli, the walls of which are formed of syncytium.

[In conclusion, I may observe that intra-peritoneal hæmorrhage from a large uterine tumour is a rare, though grave complication. The tumour is usually a fibroid. The subject has been discussed by Drs. Lewers, Herbert Spencer, and others before this Society, and more recently by Mr. Bruce Clarke in the 'Lancet.'* This case, however, for which we are indebted to our deceased colleague, comes under a different category, as Dr. Lockyer's careful report clearly demonstrates.—*A.D.*]

* "Intra-peritoneal Bleeding from a Uterine Fibroid with Acute Distension of the Abdomen; Abdominal Section; Removal of the Fibroid; Recovery," 'Lancet,' January 5th, 1907, p. 8; with references to earlier cases.

Dr. Cuthbert Lockyer had practically nothing to add to his detailed report of this growth. He had investigated nine other growths of similar nature, but this was the first specimen in which an ovary was invaded by the tumour. Ovarian metastases were present in 5 per cent. of the recorded cases, and the same frequency obtained for the intestines. The parametric connective tissues were found to be the seat of new growth in 16 per cent. of cases. In many instances, however, the uterus was found to be ruptured by the primary growth, and it was just possible that the cellular tissues became involved by direct extension in some of these cases, just as is commonly the case with carcinoma of the cervix. It was noteworthy that in this instance the cervix, as is usual, escaped invasion. The ovaries were particularly interesting, not only from the fact that in one there was a secondary deposit, but mainly because these organs had been transformed into compound lutein cystomata, and therefore provided one more example of lutein excess accompanying malignant overgrowth of fœtal trophoblast. It would be remembered that the speaker had already published four similar examples, and he knew of one other, but he (Dr. Lockyer) would again draw attention to the fact that the lutein excess does not always assume the form of a congerie of cysts, but may be present amidst the stroma of normal-looking ovaries. As to the mode of transference of the malignant growth to the ovary, Dr. Lockyer drew attention to the fact that the growth was situated on the pole of the ovary most remote from the hilum, and thought that, as the omentum was adherent to the pelvic organs and was also the seat of a large chorio-epitheliomatous mass, that possibly the ovarian deposits sprang from cells carried from uterus to ovary *viâ* the omentum rather than by the anatomical blood-vessels, which enter the hilum of the gland.

Annual Meeting.

The audited Report of the Treasurer (Dr. G. E. Herman) was read.

On the motion of Dr. Amand Routh, seconded by Dr. J. S. Fairbairn, the Report of the Treasurer (Dr. G. E. Herman) was received and adopted.

OBSTETRICAL SOCIETY OF LONDON.

Abstract of Receipts and Payments for the Year ending December 31st, 1906.

RECEIPTS.

1906.	£	s.	d.	£	s.	d.
To balance from 1905				125	16	10
Amount withdrawn from Deposit				150	0	0
				275	16	10
„ (1) Annual Subscriptions				425	5	6
„ (2) Composition Fee				5	5	0
„ (3) Sale of 'Transactions' (Longmans)	55	2	3			
Do. do. (Society)	2	11	9			
1 Certificate replaced	0	5	0			
Sale of Book	0	5	0			
Do. Midwives' Questions	0	2	0			
				58	6	0
„ (4) Bonus on Fire Policy				29	9	9
„ (5) Interest on Debentures	80	13	11			
Ditto on Consols	14	5	0			
Ditto on L.C.C. 3% Stock	23	0	4			
Ditto on Victoria Government Stock	16	18	0			
Ditto on Deposit	3	2	8			
				137	19	11
				£932	3	0

PAYMENTS.

1906.	£	s.	d.	£	s.	d.
By (1) 'Transactions'				300	14	3
„ (2) Library:						
Books purchased	43	7	4			
Binding	9	7	3			
				52	14	7
„ (3) Museum and Library:						
Rent	200	0	0			
Librarian's Salary	180	0	0			
Repairs, Cleaning, etc.	46	14	9½			
				426	14	9½
„ (4) Expenses of Meetings				31	1	2
„ (5) Stationery, Stamps, and Printing				35	12	6½
„ (6) Extraordinary Expenses				13	1	6
„ (7) Banking Expenses				0	15	8
„ (8) Balance at Bank				71	8	6
				£932	3	0

Audited and approved.

NEWSON-SMITH, LORD & MUNDY,
Chartered Accountants.

January 28th, 1907.

G. E. HERMAN, *Treasurer.*

Report of the Honorary Librarian.

The work of the Library has been carried on as usual during the past year.

The total number of volumes in the Library amounts to 6272, of which 62 are periodicals. Of these 20 are publications bound in two volumes annually, and the remaining 22 in one volume annually.

During the year 39 volumes have been added, 28 of which have been presented and 11 purchased. In addition 240 German Inaugural Dissertations have been purchased.

The number of Fellows visiting the library and the number of books taken out remain about the same as last year. WILLIAM J. GOW.

The Report of the Hon. Librarian, Dr. W. J. Gow, was received, and its adoption was moved by Mr. ALBAN DORAN, seconded by Dr. T. W. EDEN, and carried.

The following Fellows were declared elected to serve on the Council of the Society for the Session 1907 :

President.—Herbert R. Spencer, M.D.

Vice-Presidents.—Albert C. Butler-Smythe ; Montague Handfield-Jones, M.D. ; John Phillips, M.D. ; William Japp Sinclair, Knt., M.D. (Manchester).

Treasurer.—George Ernest Herman, M.B.

Editor of 'Transactions.'—Herbert R. Spencer, M.D.

Honorary Secretaries.—Robert Boxall, M.D. ; Arthur H. N. Lewers, M.D.

Honorary Librarian.—William John Gow, M.D.

Other Members of Council.—Henry Russell Andrews, M.D. ; Henry Briggs, M.B., F.R.C.S. (Liverpool) ; William H. B. Brook, M.D. (Lincoln) ; Charles James Cullingworth, M.D. ; George Eastes, M.B., F.R.C.S. ; Thomas W. Eden, M.D. ; John Shields Fairbairn, M.D., B.Ch. ; John Benjamin Hellier, M.D. (Leeds) ; Henry

Thomas Hicks, F.R.C.S.; Jamieson Boyd Hurry, M.D. (Reading); John Martin Munro Kerr, M.B., C.M. (Glasgow); Cuthbert Lockyer, M.D., B.S.; Charles Hubert Roberts, M.D.; Amand Routh, M.D.; Mary Ann Dacomb Scharlieb, M.D.; James Henry Targett, M.S., F.R.C.S.; Herbert Williamson, M.B.; Thomas Wilson, M.D. (Birmingham).

Mrs. Scharlieb moved, and Mr. Butler-Symthe seconded, a vote of thanks to the retiring Vice-President, Dr. Amand Routh, and to the other retiring members of Council, Dr. E. Rumley Dawson, Dr. Ewart, Mr. Handley, Dr. Lea, Dr. John Phillips, and Dr. Swayne.

The President then delivered the Annual Address.

PRESIDENT'S ANNUAL ADDRESS, 1907.

Ladies and Gentlemen,—It becomes my duty once more to occupy your time in the recital of the progress of our Society during a past year, both as a scientific and as a corporate body. Looking at the subject in the latter aspect there are great changes in prospect, and I shall allude to this again; but in the former we shall find, I believe, that there is no change, for there has been no departure from the steady determination to seek for truth in Nature which is characteristic of this Society.

I have first to make a statement as to the number of Fellows on our roll. We have lost by death thirteen Fellows, of whom one, Professor Gusserow, was an Honorary Fellow; by resignation and erasure, I am sorry to say, twenty-six—in all thirty-nine. We have elected twenty-one new Fellows. Our numbers are therefore smaller than they were last year, for then we had 595 Ordinary Fellows, whereas this year there are 577.

The Fellows we have lost by death since my last address number among them some exceptionally distinguished men. Of these, the best known to the world is Gusserow; the best known to us personally is Dr. Hamilton Bell. To these names I deeply regret to add, at the last moment, that of Dr. Budin.

Thomas Rutherford Adams, M.P., J.P., was born in Ireland, and came to London to enter as a student at the Westminster Hospital. He became House-Surgeon there, having qualified in 1860. He took the degree of M.D. Brussels, in 1865, after he had been in practice at Croydon for two years. He became a Fellow of this Society in 1884, and was on the Council from 1894 to 1897. Dr. Adams was one of the founders of the Croydon General

Hospital, which was about to be organised when he arrived at Croydon, and he was one of the first members of the medical staff. He was made public vaccinator for the district of Croydon in 1869. Dr. Rutherford Adams was a person of many interests outside the profession. Among other things he was a member of the Croydon Literary and Scientific Society, and an active Freemason. He seemed to have been loved by both poor and rich. He was a well-known member of the British Medical Association. He died in the last week of 1905.

Harry Campbell Pope, M.D., B.S., F.R.C.S.—Dr. Pope was the son of a medical man, and was born at Tring in 1849. He was at school at Haileybury, and then went to Liverpool for his medical education. He remained there for four years, and came up to University College Hospital. He graduated as M.D. in 1878, having taken the Fellowship of the College of Surgeons in 1876. Before settling into practice he was House-Surgeon at the Seamen's Hospital, Greenwich, and Medical Tutor and Demonstrator of Anatomy at the Queen's College, Birmingham. He began private practice in Shepherd's Bush, and remained there till his death on January 2nd, 1906. Dr. Pope took great interest in public medical matters. He became a Fellow of our Society in 1876, and was on the Council from 1902 to 1904. He was also a Fellow of the Medical Society, and of the Gynæcological Society. He helped to found the West London Medico-Chirurgical Society, and was first Vice-President, and then President, of that Society. He edited its 'Proceedings' in 1895 and 1896. His contributions to medical literature included papers on diphtheria, inguinal colotomy, diseases of the pancreas, and the feeding of infants. He was a very active member of the Medical Defence Union, being Honorary Secretary for a time, and on the Council till his death. The high esteem in which he was held by the medical men around him is shown by the fact that he was chosen to be the first Chairman when the Kensington Division of the British Medical Association was instituted

in 1903. He filled the post with much success, and it is no doubt greatly owing to his wise governing that this Section is in so prosperous a condition as that in which it now finds itself. Dr. Pope was Medical Officer to the Fire Brigade, and was Physician to the Jewish Rescue Home. He was at work up to the end, and was present at a meeting of the Council of the Medical Defence Union on December 22nd, and seemed then in his usual health. He died quite suddenly on January 2nd, aged 56.

Geheimrath Professor Dr. Adolph Gusserow, who had been one of our Honorary Fellows since 1895, was the well-known Professor of Obstetrics and Gynæcology at the University of Berlin. Professor Gusserow was the son of a distinguished physician of that city, and was born there in 1836. He studied in the University, and afterwards at Wurtzburg and Prague. After passing the State examination he acted as Assistant in the University Frauenklinik to Edward Martin. Later on he studied in this country under Sir James Simpson, who appears to have exercised a great influence on his career and development, and to have remained always one of his sincerest friends. This friendship and esteem were evident in the address in memory of Simpson delivered when Gusserow was Rector of Zurich University.

On his return to Germany he was soon appointed Professor of Obstetrics at Utrecht, and almost immediately afterwards was promoted to succeed Breslau at Zurich. He effected great improvements in the Maternity Hospital, which was constructed on anything but modern lines; and under his direction a new building was planned. It was not, however, until he had left Zurich and was succeeded by Frankenhäuser that the Clinic was finished and brought into use. He was made Rector of Zurich University in 1870—an appointment of some difficulty and delicacy at that time, since the feeling of the University in the war then raging was German, while that of the townspeople was decidedly French.

Gusserow stayed at Zurich for five years. From thence,

in 1872, he went to Strasburg—an University newly founded after the war. He was accompanied here by Zweifel, at that time his assistant. He left behind him at Strasburg, as elsewhere, evidence of his energy in a new woman's hospital with lying-in wards.

Being now called to Berlin to take charge of the recently instituted Charité, his great experience in organisation enabled him to bring the Obstetrical and Gynæcological Departments of the University, and the Clinic attached thereto, into the leading position they hold at present. He held the Professorship till within two years of his death, and resigned it only on account of his failing health. Soon after his return to Berlin he had made a most happy marriage, and became the father of three daughters.

Wyder, of Zurich, writing of him in the 'Monats. f. Geb. u. Gyn.' of April, 1906, speaks of his personal character in the highest terms. He says: "No one will accuse me of exaggeration when I assert that Gusserow was an accomplished gentleman, with splendid endowment of head and heart." Gusserow had the highest possible sense of duty, and won the love of his patients, of his colleagues, and even of candidates at examinations.

He was not a brilliant operator, and this could not be expected in a man who did not begin to perform major operations till he was forty-five years of age. But as clinical teacher he excelled all others.

He wrote very little, his principal contributions being the section on "Die Neubildungen des Uterus," in Billroth's 'Handbuch,' and his "Researches on the Interchange of Gases in the Fœtus." He edited, at first in conjunction with Crédé and later on with Leopold, the 'Archiv f. Gynäkologie,' and he was engaged in this duty till shortly before his death, which occurred on February 6th of last year.

Thomas Edmonston Charles, M.D., F.R.C.P., Deputy Surgeon-General in the Indian Medical Service, Hon. Physician to the King, was born in Calcutta in 1834.

He was educated at Edinburgh, and became M.D. in 1855. He then went to India as a member of the Bengal Medical Service. Being attached to the Bengal Fusiliers he took part in the famous march from Dogshai to Umballa in the 1857–1858 campaign. He served through the siege of Delhi, and after some more fighting he accompanied Lord Clyde and his army in the second advance on Lucknow. Here he was in the storming party of the Bengal Fusiliers, who took the enemy's first position. He was afterwards in Oudh with Sir Hope Grant, and was mentioned in despatches. He received the Indian medal and clasps for Lucknow and Delhi.

In 1859 he was appointed Garrison Assistant-Surgeon at Allahabad, and soon after this Professor of Midwifery at the Bengal Medical College, a post which he filled in the most efficient manner, and greatly advanced the cause of medical education in India. He founded the Eden Hospital in Calcutta, and took the greatest share in the organising and establishing of this institution.

His health obliged him to come to Europe in 1880, and he settled at Cannes, practising there with great popularity and success. After six years he went to Rome, and was attracted to the study of archæology, becoming somewhat of an authority in this subject.

He was now again obliged by failing health to seek a milder and more equable climate, and Falmouth was chosen. Here he took some part in public matters, and became Chairman of the Truro Division of the British Medical Association. He was prevented by ill-health alone from accepting the position of President-Elect of the South-Eastern Branch. He died on March 2nd, aged 72.

Dr. Charles joined our Society in 1867, and was on the Council from 1882 to 1884. Sir Joseph Fayrer, who knew him well, says of him: "Dr. Charles was a many-sided man. In addition to his study of archæology he was much interested in microscopical research, and revised the New Sydenham Society's translation of Marchiafava's and Bignani's work on malarial fever.

He was, so far as his physical energy would permit, an enthusiastic mountaineer. . . . He was a fisherman in early life and took great interest in sport of all kinds. . . . His great professional ability, the strenuous and energetic manner in which he performed all his duties, his high sense of honour, his amiable character, and his earnest desire to be of use to everyone, not only enhanced his value as a public servant, but endeared him to all with whom he was associated, and especially to those who, like the present writer, had known him throughout his career and appreciated the sterling qualities of his character."

Michael McWilliams Bradley, M.D., was elected a Fellow of this Society in 1877. He was educated at Glasgow University, and went to practise at Jarrow-on-Tyne in 1872. He held several public appointments, and was on the Commission of the Peace for twenty years. He was a Nationalist in politics, and was President of the Wolfe Tone branch of the United Irish League. He was on more than one occasion considered as a candidate for a constituency in the North of Ireland. He was greatly loved and esteemed for his genuine kindliness by all who knew him. He contributed a paper to the 'Obstetrical Journal' (vol. vi) on "Post-partum Hæmorrhage, with Notes of Three Cases successfully Treated by Compression of the Abdominal Aorta"; and another to vol. vii of the same journal entitled "A Contribution to Midwifery Statistics." He died on May 2nd of last year.

Franklin Hewitt Oliver was elected a Fellow in 1888. He was born in 1859, and died last September at the early age of 47. He practised in Bethnal Green, and was one of the best-known and most popular men in the district. He was educated at Charing Cross Hospital, where he afterwards held the post of Resident Obstetric Officer. Dr. Oliver held many public appointments, being for several years Chief Surgeon to the Royal Maternity Charity. He was at the time of his death Surgeon-Accoucheur to the City of London Lying-in Hospital.

His last two years were however, spent on a sick-bed, and after a life of unstinting devotion to a practice among the poor he died, worn out with pain, which he had borne with courage and patience.

Robert Hamilton Bell, M.A., M.B., B.C., F.R.C.S., died in October. It is sad enough to have to record the death of those Fellows of our Society with whom we have had but little acquaintance, and some of whom we knew by name only; but in the case of Dr. Bell each of us must feel that he has sustained a personal loss. It is a still greater sorrow to remember that he was taken from us, not after he had seen the fruition of a life's work and had lived to a good old age—for these conditions to some extent mitigate the shock of his death to a man's friends—but when he was yet almost on the threshold of his career. His career was certain to have been a brilliant one—his earnestness, his energy, and his ability all assure us of that. But there was much more than even these qualities in him. He was a man without, I believe, a single enemy, and that, not because of a colourless and insignificant character, but because he was transparently honest, because he took a broad view of life, was of a kind and generous nature, and was free from all meanness and petty jealousy.

Dr. Bell was born in 1871, and was educated at Cambridge and at St. Thomas's Hospital, entering as a student there in 1895. He was House-Physician and Obstetric House-Physician there, having taken the degree of M.B. in 1898. He began practice in Kensington in 1899, but, having a strong desire to work at obstetrics, he applied for, and was appointed to, the post of Physician to Out-patients at the Samaritan Free Hospital. He now took the Membership of the College of Physicians and also the Fellowship of the College of Surgeons. The following year found him Obstetric Tutor at his old Hospital. In 1905 he obtained the post of Assistant Obstetric Physician to the Great Northern Hospital, and, the year after, the Assistant-Physiciancy to the British

Lying-in Hospital. He had become a Fellow of this Society in 1901.

Dr. Bell's death was very sudden. He was at work at St. Thomas's on October 26th, and was dead of pneumonia on the 29th. He was, at his death, 35 years of age, and had, as we have seen, devoted himself to the study of obstetrics purely for only about five years. When we consider the amount of work he accomplished, not only in pathological research and in the publication of valuable papers, but in the numerous hospital appointments which he had obtained in such rapid succession, we see that he had expended more and better-directed energy in these few years than most men are able to display in a life-time. He had learned

> "To scorn delights and live laborious days:
> But the fair guerdon when we hope to find,
> And think to burst out into sudden blaze,
> Comes the blind Fury with the abhorred shears
> And slits the thin-spun life."

He had distinguished himself in both literary and clinical fields. There is no need for me to remind the Fellows of our Society of his contributions to its 'Transactions.' These, as we consider them in the order of their production, showed an increasing acuteness of vision and power of generalisation; and his last paper, on a very important question—that of the diagnosis and treatment of early ectopic gestation—on which he was engaged at the time of his death, illustrates his judicial faculty in a remarkable manner. This paper shows also that he was a master of good English and of clear exposition.

A writer in the 'British Medical Journal,' one of his colleagues at the Samaritan Free Hospital, speaks of the deep impression made on the staff of that hospital (than whom there are none better qualified to decide) by his judgment and clinical knowledge, and says they were all of one accord concerning his ability as an operator.* The power of

* A brass tablet to Dr. Bell's memory has been fixed in the Samaritan Free Hospital by his medical and surgical colleagues.

teaching—a rare power—was in him highly developed. At St. Thomas's his pupils found his interest in their work never failing and always discriminating. His kindness and consideration towards his patients have been remarked on by many who have written of him; and I well remember being struck with this on one occasion, in a very sad case, while he was still in general practice in Kensington. It was the first time I had met him, and I could not help at once recognising in him a man so kind and so self-sacrificing that it was a privilege to know him. I can imagine no worthier ambition for any man than that of so living as to be cherished in the memory of his friends, as Bell is, and ever will be.

George Bagot Ferguson, M.D., M.Ch., F.R.C.S., was admitted a Fellow in 1901. He died suddenly in November last while performing an abdominal operation in the Cheltenham Hospital.

Dr. Ferguson was educated first at Cheltenham College, then at Oxford, and finally at St. Bartholomew's Hospital. He became House Surgeon there, and then went into practice at Cheltenham. He was appointed very shortly after his arrival to a post on the honorary staff of the Hospital, and at the time of his death was Senior Surgeon. He had been hurriedly sent for to operate on a case of strangulated hernia; and while he was resecting a piece of gangrenous intestine he suddenly fell down, and he died very soon after. He had not been strong for some years, and shortly before his death had suffered from angina and other heart symptoms.

In 1901 Dr. Ferguson was President of the British Medical Association, and delivered an address on scientific research. He was a man of marked influence in Cheltenham, and always exercised this in promoting the welfare of the town and its inhabitants. It is to a great extent by his exertions that the mineral waters of Cheltenham have become known to the profession. He was much valued as a consulting and operating surgeon in the town and surrounding district. He contributed

numerous articles on surgical subjects to the medical papers and to hospital reports.

A few weeks only before his death he sent the specimen which we have seen this evening to Mr. Doran, who introduced it in feeling terms; it was the first contribution he had made to our proceedings.

William Travers, M.D., F.R.C.S.—Dr. Travers was a well-known practitioner in Kensington, where he was deservedly popular and successful. He was born in 1838. He became a student at Charing Cross Hospital, and afterwards performed the duties of Resident Medical Officer to that Institution for six years before beginning private work. In 1883 he was elected Physician to the Chelsea Hospital for Women, and held this appointment till 1894. He was some time President of the West London Medico-Chirurgical Society, and would have been President of the Gynæcological Society if his failing health had not obliged him to decline the office. Dr. Travers suffered from increasing loss of sight towards the close of his life, but he persevered in work till almost the end. He died on December 17th after an attack of pneumonia following influenza.

Dr. Travers was a man of general and widespread interests, and his loss is severely felt by those who were his patients and his friends. He had been a Fellow since 1884.

Alexander Waugh, M.B., C.M., was admitted a Fellow also in 1884. He died on December 9th, aged 66. Mr. Waugh was educated at Bristol and St. Bartholomew's Hospital, and qualified in 1863. He then went to practise at Midsomer Norton, near Bath. He took a great share in building the Cottage Hospital there, and was in every way a benefactor to the neighbourhood. There was little belonging to the occupations and amusements of the country in which he was not able to take a part, and he was loved and respected by all the country side. He was President of the Bath and Bristol branch of the British Medical Association in 1880.

We have also lost by death *Dr. Lyons,* of Thames

Ditton; *Dr. Mitchell*, of St. Leonard's; *Mr. William Gill*, of Russell Square; and *Dr. Verley*; but, unfortunately, all attempts to obtain any special accounts of the lives of these gentlemen have proved unsuccessful.

It is with the greatest regret that I add to this list the name of *Professor Budin*. He died on January 22nd from an attack of pneumonia. The time was too short for me to prepare an adequate account of his life and most valuable services to obstetric medicine, and I must leave this to be done by my successor. Dr. Budin was one of our Honorary Fellows, and was elected in 1899.

Work of the Society.

The record of the Society's work during the past year is a very satisfactory one, as we shall see in the brief account of it, which it is my duty to put before you.

I will group the material into: (1) papers on obstetric subjects; (2) papers on gynæcological subjects; (3) short communications on obstetrics; (4) the same in gynæcology; (5) specimens.

Papers on Obstetrics.

Dr. Herman read a paper in June entitled "A Case showing (*a*) Uterine Contractions without Retraction; (*b*) Prolonged High Temperature of Nervous Origin."

The author recorded a case which was interesting from two points of view. One was the condition of the uterus for a time during labour, in which it contracted regularly without advance of the child, although the child was premature and thus small, and there was no obstruction. The other phenomenon was an event of the lying-in period. This was unduly prolonged by raised temperature. The woman's state was made alarming by repeated rigors, during each of which the fever reached the neighbourhood of 105° F.

The author considered the long standstill, in spite of uterine contractions, to have been due to the absence of

retraction of the uterus. Retraction, however, did take place at last. The incompleteness of the third stage seems to be accounted for by abnormal adhesions over a small area. After manual removal of the placenta on account of excessive bleeding the patient was very prostrate, with a small and quick pulse, and two pints of warm water were injected into the rectum.

Before labour had begun, and soon after the introduction of a bougie, she had a shivering fit, and her temperature rose to 106·4° F. It came down in five hours after this to 100° F., but rose again on the day following delivery to 103° F. She had fever till the twenty-fifth day after delivery, with rigors on the seventh, ninth, tenth, fifteenth, eighteenth, and nineteenth days of the puerperium. In spite of these severe symptoms the patient looked placid and happy. Every possible source of fever seems to have been considered and investigated according to our present lights, but no cause could be found. The blood was sterile on the ninth day, but the skin sloughed at the site of puncture. She was treated with polyvalent antistreptococcic serum on the eleventh day, but no appreciable effect was produced. The injection was repeated on the nineteenth day after the rigor, and the temperature had fallen next morning to 98° F.

Dr. Herman remarked on the unusual character of the case, and pointed out how it illustrated the difference between contraction and retraction of the uterus, taking the view that for more than twenty-four hours contractions were present without any retraction, as evidenced by the non-advance of the child. He considered that the prolonged high temperature with rigors was of nervous, not hysterical, origin, and related another case which occurred in his experience. In this there was a high temperature for some weeks after the removal of a fibroid polypus, without any physical sign, except a mild cystitis, to be found. This woman was in very good condition in spite of the pyrexia. He instanced other cases of high temperature in patients of nervous and of hysterical types,

and pointed out that in all these instances, in some of which the pyrexia lasted for weeks, there was no emaciation nor enfeeblement.

The paper was well and critically discussed, and both the points dwelt on by the author were handled very freely. Each of the speakers who touched on the retraction question had his own view as to how retraction should be defined, and mistrusted all others, even including the definitions in the English text-books. There seemed to be no vital difference between the conceptions respectively advanced by the various authorities who spoke nor between their methods of teaching them to students. It was agreed generally that retraction does not occur without contraction, but on the question whether contraction may occur without retraction—the main point of this part of the paper—Dr. Williamson said he believed that contraction and retraction go hand in hand in labour (presumably normal labour), but did not say whether he thought they might be dissociated in abnormal conditions; and Dr. Horrocks, who has fully dealt with this subject in an article in the 'Journal of Obstetrics and Gynæcology,' January, 1902, believes that retraction—meaning, according to his own definition, "contraction followed by relaxation (that is, the passing off of the uterine contraction) but not by extension"—must have occurred in this case, for there was no force present which would have extended the uterine muscle after the contraction was over. He believed, in fact, that each of the contractions described by the author must have been followed by retraction.

In reference to the high temperature, Dr. Lewers suggested uterine phlebitis as a cause, but Dr. Herman would not agree to this for the reasons excluding sepsis which he had stated in the paper.

In November Dr. Rivers Pollock read a paper on "External Version, its Present Position in Obstetrics, with a Suggestion of a New Method of Performing it." Dr. Pollock described the present position of external version in the civilised world, and discussed the question

of the proper time to perform it. He considered also the difficulties of the operation and how to overcome them. He believed that most important assistance was obtained when the patient was suspended by her feet and her trunk was rendered vertical, or as nearly so as practicable, so as to induce disengagement of the breech, in podalic cases, from the pelvic brim of the mother. After the disengagement had been thus accomplished the breech could be prevented from again descending into the brim by pressure of the hand on the abdomen of the woman below the child's breech. The patient could then be placed on her back and the remainder of the version performed in the usual way.

The result of inversion of the patient as affecting the angle made by the uterus with the horizon was discussed, and Dr. Champneys pointed out that, to put the uterus upside down, the best posture was the genu-pectoral. Dr. Pollock said he had tried that, and the breech did not move out of the pelvis.

Gynæcological Papers.

In January Dr. Griffith and Dr. Williamson read an interesting and important paper on "A Case of Fibro-myoma of the Uterus Undergoing Sarcomatous Change." It occurred in a patient, aged 56, who suffered from abdominal pain. She was known to have uterine fibroids, and had been examined six years before on this account. Nearly two months before admission into the hospital she had begun to have the pain, with cough and night-sweats, and she now had diarrhœa and a temperature of 101° F. The diarrhœa soon subsided, but the temperature remained high, and she was obviously ill. She was examined three weeks after her admission, and there yet seemed nothing to connect the uterine tumour with her illness. But she steadily got worse, and had rigors and pain in her chest. Peptonuria had been discovered soon after her admission, and this had suggested some necrotic change, probably in

the fibroid. A month after the examination referred to she began to lose blood from the vagina in fairly large quantity, and she was urged, in view of her condition, to submit to an exploratory operation, but she refused. In a few days she got much worse; her pulse was 120 and her respirations 40. There were now some signs in the right lung, and malignant growth with secondary deposits was suspected. Soon after this she died.

At the *post-mortem* examination sarcoma was found in the lungs, and in the uterus many fibromyomata. One of these latter showed two varieties of growth—(*a*) dense, white, fibrous-looking tissue, the continuity of which was broken by the presence of (*b*) masses of friable material of a deep red or brown colour. The white part was fibromyoma and the brown part was sarcoma. Microscopically the former was at one place invaded by an elongated strand of sarcomatous cells, resembling exactly those of the red part, and being of various sizes and shapes. Most of them were round, some were spindle-shaped, some were large, and contained six or eight nuclei. The authors discussed the relations of sarcoma and fibromyoma, and discarded the term "malignant degeneration" as inaccurate and confusing. They pointed out four possible conditions, each of which had been described as "malignant degeneration." They were of opinion that this case ought to be assigned to the group in which a sarcoma arises *de novo* in a pre-existing fibromyoma, or possibly to that in which the cells of the original fibromyoma assume malignant characters. They further thought it probable that the sarcoma may, in part at least, have originated in muscle-cells. We owe the authors a good deal for their excellent description of this case, and it is to be hoped that more evidence as to the proneness of fibroids to undergo malignant change may be forthcoming, and be presented in such a form that it may be criticised.

At the meeting in March, Mr. Malcolm read a paper on "Peritonitis and the *Staphylococcus albus*." The object of the essay was to show that the micro-organism in

question was not responsible, as had been alleged, for certain cases of peritonitis, since it was found in many peritoneal cavities where there was no evidence of its presence except that of the microscope or of culture investigations. Mr. Malcolm is well known to hold the view that inflammation, including, of course, peritonitis, may be an aseptic process. He considered that the evidence of Messrs. Dudgeon and Sargent as enunciated in their work on the "Bacteriology of Peritonitis," that, "febrile disturbances frequently found after effusion of blood into the peritoneal cavity are due to the presence of this organism," is unconvincing. He argued that a staphylococcus which is present invariably in intra-peritoneal blood-clot, and may exist there without pus-formation for three months, is a different coccus from that which produces suppuration. On this Mr. Percy Sargent remarked that Mr. Dudgeon and he had been at pains to demonstrate that the white staphylococcus, the subject of this paper, was not the same as the *Staphylococcus pyogenes albus*, and had never suggested that it caused the suppuration which sometimes follows on an old pelvic hæmatocele. In regard to the question of the absence of micro-organisms in suppuration, Mr. Sargent drew a careful distinction between the terms "aseptic" and "sterile," as applied to wounds, the former meaning only the absence of any clinical signs of inflammatory reaction, and the latter meaning absence of micro-organisms. He was evidently of opinion that all cases of inflammation of the peritoneum would eventually turn out to be due to micro-organisms.

Mr. Malcolm's paper is full of interesting matter and original ideas, and an attempt to condense it for an occasion of this kind would not do it bare justice. I have, therefore, limited myself to giving the main points.

Dr. Addinsell read a paper in April with the title of "Chronic Infective Metritis." He dealt with the nature and treatment of certain cases of uterine hæmorrhage, severe and intractable, in which there was no gross lesion

to be found. The paper was illustrated with a large number of lantern slides of microscopic sections taken from uteri removed by him in consequence of this intractability. Dr. Addinsell described three stages as evidenced by the microscope in the development of the complaint, beginning with the usual signs of inflammation round the blood-vessels and invading the intermuscular connective tissue, then surrounding those mucous glands which lie deepest in the muscular wall. After this, sclerotic changes in the tissues, thickening of the arterial walls, chiefly in the middle coat, and dilatation of the capillaries. The author considered that the age of the patient had little to do with the incidence of the disease, and that his cases differed from those of hæmorrhage of the climacteric period discussed by Barbour, and also from those of arteriosclerosis described by Palmer Findley. The Fellows who spoke on this paper all agreed that it concerned a most important clinical group of cases, which offered great difficulty in treatment. It was doubted whether, on the evidence adduced, the cases could be fairly ascribed to infection, for the changes found were not in the submucous layer principally, as would be expected on that assumption, but in the parts where the changes due to child-bearing and presenility are found. Dr. Blacker alluded to the success he had had in such cases as the author described by treating them with steam at 120° C.

At the July meeting Miss Louise McIlroy, M.D., read a paper on "Primary Cancer of the Ovary." As the result of examining fifteen cases of undoubted cancer of the ovary she had come to the conclusions given below, which she divided into two groups :

(1) *Those arrived at from the clinical standpoint.*— That primary cancer of the ovary occurs in women about the time of the menopause or after, but is found in young patients, causing, in the latter, cessation of menstruation. That previous child-bearing has no influence, that pain is not marked, that ascites is present usually, that meta-

stasis depends on the duration of the disease and the integrity of the tumour-capsule, that the probability of recurrence is great, and that malignancy is rarely suspected before operation.

(2) *Those from pathological investigations.*—That both ovaries are frequently affected, one being more advanced than the other; that in the early stage the capsule is firm, but later on breaks down, and that the tumour-tissue proliferates through it; that germinal epithelium is absent as a rule, and no Graafian follicles or corpora lutea are found; that previous benign change in the ovary is constant; that the most common forms are the glandular cystic form and the alveolar form, with connective tissue increase; that it begins near the surface and arises from the follicles and from cells which have been derived from the germ-epithelium.

The paper was highly appreciated, and Miss McIlroy is to be congratulated on her work. In answer to a question she said she considered that the naked-eye appearance of cystic growths of the ovary was of little aid toward determining their innocence or malignity in the majority of specimens. It would, therefore, appear that we ought to remove all adenomatous ovarian tumours whole, without tapping, however large they may be.

In October Mr. Eric Young described a case of that rare disease, primary tubercle of the cervix uteri. A woman with no family history of tubercle began to suffer from menorrhagia and a thick, yellow discharge, with constant aching pains in the sacral and hypogastric regions. There was no intermenstrual bleeding.

On examination she was slightly tender in the hypogastrium and left iliac regions; the cervix was indurated and greatly enlarged, its surface uneven and ulcerated in places, and in places nodular and papillary; friable nowhere. There was no sign of tubercle in the lungs.

On account of the suspicious nature of the cervix vaginal hysterectomy was performed.

The cervix was reported on by two independent

observers. One of them stated that there was no miliary tubercle, but that the specimen consisted of inflammatory material, with here and there a giant-cell. He thought the lesion might be of inflammatory origin. The other reported that the area of ulceration extended, in addition to that already described, as far up as the internal os. He found, on microscopic examination, that many typical tubercles were present; in the centre were giant-cells, some of which presented as many as fifteen or twenty nuclei arranged round the periphery. He had no doubt that the specimen was an example of tuberculosis of the cervix.

The author then proceeded to discuss the literature of the subject and the difficulties of a clinical diagnosis.

This was a valuable paper on account of the careful record it contained of a case of rare occurrence, of the similarity of the disease in some respects to carcinoma, and of the satisfactory results of treatment.

Dr. Victor Bonney read a paper in December on the "Treatment of Ovarian Prolapse by Shortening the Ovarian Ligament."

He considered the cases of ovarian prolapse in three groups:

(1) *Primary uncomplicated ovarian prolapse.*—In this group he considered that the operation was indicated where there was dyspareunia and chronic ovarian pain.

(2) *Ovarian prolapse secondary to, or coincident with, retroversion of the uterus.*—In these cases, where a cure could not be obtained by pessaries, shortening of the ligament, combined with ventrofixation or suspension of the uterus, was the best course.

(3) Ovarian prolapse caused by, or complicated with, disease of the ovary or tube, with or without fixed retroversion of the uterus. Here the author advised salpingectomy, combined with ventrofixation and shortening of the ovarian ligament.

Dr. Bonney described his method of performing the operation, which consists in pleating the ovarian ligament

by a "gathering" stitch so as to bring the ovary up under the cornu.

This paper was discussed by several Fellows, most of whom were not in favour of operating in such cases as the author described in the way he recommended except under rare circumstances.

Short Communications on Obstetric Subjects.

At the January meeting Mr. Anstruther Milligan read a short paper on "A Case of Pyelonephritis of Pregnancy." He related the history of a patient, who, six weeks before her confinement, began to have symptoms of trouble in her left loin. Her labour was normal, but three weeks after she was admitted into the Soho Hospital, and a large amount of pus was evacuated from the pelvis and ureter of the left kidney. No stone or caseating matter was found. She recovered, and had another child about fifteen months afterwards with no return of the trouble. Mr. Milligan then proceeded to discuss the possibility of the pyelitis being directly due to the pregnancy, and concluded that this was beyond question. He ascribed the connection to some injury done to the ureter by compression, but was unable to state exactly how this occurred.

In February Dr. Spencer gave an account of "A Second Case of Abdominal Ovariotomy during Labour." The operation was complicated by extensive adhesions due to a tapping which had been performed three weeks previously. He delivered the woman with the forceps at the conclusion of the ovariotomy. He remarked on the undesirablity of tapping ovarian cysts, unless under very exceptional circumstances, and then proceeded to consider what courses were possible in the case of labour complicated by a large ovarian tumour which did not obstruct the pelvis. There were three alternatives, one of which must be promptly adopted on account of the danger of rupture of the tumour, namely:

(1) To deliver by the natural passages, dilating the canal if necessary, and then to perform ovariotomy.

(2) To perform ovariotomy, and leave the delivery to nature.

(3) To perform ovariotomy at the end of the first stage of labour, and immediately afterwards to deliver by the forceps while the patient is under the anæsthetic.

Of these three courses he believed that the last described was, on the whole, the best.

In April Dr. Ewen Maclean read a short note on "A Case of Abdominal Pregnancy, Spurious Labour at Term, Fœtus and Placenta Removed Six Months later." He related the history of the woman's pregnancy, and described her condition when she came into hospital, and the operation that was performed. A decomposing fœtus was found with a degenerated placenta. This could not be made out to be adherent to the sac wall, but it had probably been attached at the inferior and anterior surfaces of the lower pole of the sac. There was a pinhole communication between the sac-cavity and a coil of intestine. No attempt was made to remove the sac, as the peritoneal cavity was not opened at any time during the operation, but it was drained. It was impossible to be certain of the exact mode of development of the case; but it could be assumed, ovarian pregnancy being excluded, that dislocation of a tubal pregnancy had occurred in one of the two accepted ways at the second month, for the history and the conditions found at the operation did not favour the theory of intra-ligamentous development.

Dr. H. H. B. Brook recorded, in June, "Three Cases of Glycosuria occurring in Pregnancy." By a curious coincidence he had had these three examples of an uncommon disorder under his care at about the same time. They were all nearly of the same degree of severity, as gauged by the quantity of glucose present, viz. 10 to 12 grains to the ounce. They were appropriately dieted, and the sugar diminished; but it never quite disappeared in one of the cases, and was absent only occasionally in the others.

Dr. Brook, rightly considering that such cases are doubtful as to their termination, paid much attention to them at the time, and afterwards recorded them fully.

Dr. Nepean Longridge read a note on "Sixty-four Cases of Contracted Pelvis," which had been delivered in Queen Charlotte's Hospital. This was an interesting and valuable analytical record of their treatment and its results. It will certainly be of use to obstetricians in considering the question of the management of contracted pelvis. The paper is very condensed as it stands, and it would be impossible for me to give an adequate abstract of it for this address. The author concludes that the treatment of this abnormality appears to be narrowing down to two methods of election—namely, the induction of labour and Cæsarian section; and, speaking generally, it seems that the former method is most satisfactory with a conjugate of over 3½ inches, and the latter when it is under that measurement. The author said he did not approve of de Ribes' bag in induction, and Dr. Rivers Pollock and Mr. Targett spoke in its defence.

Short Gynæcological Papers.

In May Dr. Lewers read the notes of three cases of epithelioma of the vulva, and remarked how, as illustrated by the first case, local recurrence after operations on epithelioma in this part is not necessarily of fatal significance, for the patient, after having had three operations performed on recurrent patches, had passed five years since the last operation without any sign of return. He considered Paquelin's cautery a better instrument for removal of the growth than the knife or scissors.

In July Dr. Williamson described a rare tumour of the labium—namely adenoma. His specimen had the naked-eye appearance of an epithelioma, but, microscopically, it proved to be an adenoma—a diagnosis which had been justified by no reappearance having taken place after

three years. The author alluded to the only three cases as yet described, and discussed the origin of these growths.

In October Dr. Eden and Mr. Lionel Provis recorded the removal of a very large intra-ligamentous fibrocystic tumour of the uterus. It weighed 30 lb., and was removed by enucleation and sub-total hysterectomy. Its growth had been very rapid, and the clinical symptoms resembled those of an ovarian cyst. It was attached by a distinct pedicle to the uterus.

In November Mr. Doran read a short account of a case of myomectomy during pregnancy, followed by labour at term, with notes of similar cases. The operation was performed in the fourth month of the patient's first pregnancy. Her age was thirty-five. The operation did not seem to unfavourably affect the pregnancy nor to increase the perils of labour; and it was as well borne by elderly primigravidæ as by younger ones.

After-Histories.

Two after-histories of cases previously shown were noted: one by Dr. Boxall, of a case of cystic fibroid with carcinoma of the left ovary and right Fallopian tube, which he had brought before the Society five years ago. Dr. Boxall had recently heard from the patient that she was perfectly well. The other was mentioned by Dr. Hamilton Bell, and was a case, the specimen from which was shown by Dr. Tate six months before as an example of sarcoma of the ovary. The Pathology Committee had found no evidence of sarcomatous change in the ovary. The woman had recently died with secondary sarcomatous growths in various organs.

It is very obvious that the practice of recording the after-histories of cases of which the Society has already heard, is of the utmost value, and should be adhered to on every possible occasion.

Specimens.

It is impossible for me to even refer to the long series of specimens shown at meetings during the year. I cannot, however, refrain from mentioning the specimens shown by Dr. Cuthbert Lockyer and Dr. Blacker respectively, of the imperfectly developed generative organs removed from two epileptic subjects; and that of fibroids of the uterus complicated with carcinoma of the corporeal endometrium, shown by Mr. Bland-Sutton.

Sir William Sinclair discussed the subject of sea-tangle tents and their use, and an interesting debate followed on the question of how far they were really useful in gynæcological work.

It will be seen from the above short account of the work done by the Society that there is no falling off from the standard of previous years. Most of the important subjects in obstetrics and gynæcology have received a share of attention. I should like to point out that some of the short communications—and this is true also of some of the accounts of specimens shown—dealt with points of great importance, and involved in their preparation a considerable amount of work, and added much to our knowledge of the various subjects concerned.

The discussions on papers and specimens have been as original and independent as ever, and as free as ever from platitudes and mere self-advertisement.

Two years ago, when casting around for a subject for the Inaugural Address with which it is the privilege of each President to make his appearance, I arrived at the determination that some good might come of airing a conviction I had as to the urgent need for reform in the present method of teaching practical midwifery in this country. I, therefore, discussed the matter at some length. I was very glad to find that I had the support of, I believe, practically all the teachers of midwifery of London and elsewhere. In fact, I was not by any means

the first to publicly express the necessity for improvement. Whether what I ventured to say was the spark that fired the train (as I hoped it might be) I know not, but the Fellows are, no doubt, aware that the matter is now under consideration by both the General Medical Council and by the Royal Colleges of Physicians and Surgeons, and some practical result will very soon, I hope, follow.

The agitating question of the amalgamation of our Society with the other London medical societies into a general academy of medicine has, as you know, been finally settled; and this year, almost certainly, the Obstetrical Society of London will cease to exist. In the name of the Society I must heartily thank Dr. Champneys, who has acted as our representative on the Amalgamation Committee, for the generous devotion he has shown to our interests, and for the sacrifice of valuable time he has made for us, both at the meetings of the Committee and in the intervals.

I am sure that none of us, in his anxiety to do the best by amalgamation for the advancement of obstetric medicine, can help feeling the sentiment of regret that a distinguished society like ours, which has accomplished so much in its half-century of existence, should come to the end of its independent life, lose its honoured name, and become merely a section of a general association of medicine. It was, however, necessary, under the present conditions, that this should happen, but we know that the inspiring traditions which we have inherited will not die, and that in the dissolution of our Society we shall show that "even in our ashes live their wonted fires," and that the ancient spirit will animate our meetings and ourselves.

We shall found another Salamis in the new country, with Dr. Spencer as our leader. For if, by a slight alteration, we read "Spencer" for "Teucer," then—

> "Nil desperandum Teucro duce et auspice Teucro;
> Certus enim promisit Apollo
> Ambiguam tellure nova Salamina futuram."

But I must remember that it is not yet time to "cast a longing, ling'ring look behind," nor is it in my province to compose an elegy. When the time does come for the last words to be said in this Society I am most happy to think they will be uttered by my distinguished successor.

In last year's address I had to record, with some regrets, the end of the Board for the Examination of Midwives, of which I was the last working Chairman. I stand now, as it seems at present, the last President of the Obstetrical Society who will complete the full term of office under that title. I only trust that if, in any remote future, the casual reader of our archives discover this, it will not convey to him the idea that the manner in which the duties had been performed by the last incumbent of these two honourable offices was such as to demand their immediate abolition. To have held the position of President of the leading Society devoted to the study of his own particular branch of medicine is one of the greatest honours, if not the greatest honour, which can befal a man, even though he may remind himself that conspicuous ability is not always the reason for its bestowal.

I must thank the Society for having bestowed it on me; I must thank the Fellows for their forbearance and support while I have enjoyed it; and I must thank our Senior Secretary (Dr. Boxall) for the energy he has shown, which has greatly enabled me to sustain it.

On the motion of Dr. Cullingworth, seconded by Dr. Herbert R. Spencer, a vote of thanks to the President for his address was passed by acclamation.

MARCH 6TH, 1907.

HERBERT R. SPENCER, M.D., President, in the Chair.

Present—52 Fellows and 4 visitors.

Books were presented by the Medical Society, St. Bartholomew's Hospital Staff, and the Radcliffe Librarian.

Eardley L. Holland, M.B., B.S.Lond., F.R.C.S.Eng.; Percy Cecil Parker Ingram, M.B., B.S.Lond.; and Lewis Graham, B.S.Lond., were admitted Fellows of the Society.

Charles J. Battle, M.R.C.S., L.R.C.P. (Kearsney, Natal), was declared admitted.

The following gentlemen were elected Fellows of the Society: Archibald Montague Henry Gray, M.D., B.S.Lond.; Clifford White, M.D., B.S.Lond.; James Montague Wyatt, M.R.C.S., L.R.C.P.Lond.

Report of the Pathology Committee on Mr. Bland-Sutton's Specimen of a Villous Tumour of Uterus from a patient aged 84 (*see p.* 46).

WE have examined this specimen and the microscopic sections taken from it, and agree with the exhibitor that

the growth is a villous tumour with no evidence of malignancy.

(*Signed*) Henry Russell Andrews.
G. Blacker.
T. W. Eden.
J. Bland-Sutton.
Herbert R. Spencer.
Corrie Keep.
W. S. A. Griffith, *Chairman.*

AFTER-HISTORY OF THE CASE OF FIBROID OF BROAD LIGAMENT ASSOCIATED WITH AN OVARIAN CYST, REPORTED IN THE FORTY-THIRD VOLUME* OF THE SOCIETY'S 'TRANSACTIONS.'

By Alban Doran, F.R.C.S.

Four and a half years after the operation which I reported in 1901 I removed a large cystic tumour of the opposite ovary, which had shown no sign of disease when inspected on the previous occasion. The second ovariotomy gave me an opportunity of examining the effects of the extensive enucleation necessitated by the connections of the two tumours already removed.

At the first operation, performed on July 18th, 1901, I removed a thin-walled cyst of the left ovary, containing ten pints of chocolate-coloured fluid; it was multilocular, and beneath and behind it lay a fibroma of the left mesometrium, invading the mesosalpinx. The base of the ovarian tumour also burrowed into the mesometrium, dragging upwards the uterus, which bore two small spherical fibroids posteriorly near the fundus, and also the

* P. 260 and Pl. XIV.

right appendages. I noted that "the right ovary and tube were quite normal."

After clamping the ovarian pedicle I cut into the left broad ligament, enucleated the fibroma, which weighed two and a half pounds, and then ligatured the ovarian pedicle. Much of the capsule was trimmed away; its anterior and posterior layers were sewn over the stump of the ovarian pedicle with a continuous No. 2 China-twist suture. The uterus and right appendages now fell back into the pelvis. I observed that "the sigmoid flexure lay very close to the cut edge of the capsule, but was not kinked."

At the end of December, 1905, the patient was sent to me by Mr. Meredith Townsend, of Kensington, on account of recent abdominal distension. The patient, aged 49, did not look cachectic. A somewhat flaccid cyst occupied the lower part of the abdomen, reaching three inches above the umbilicus and downwards to the brim of the pelvis. The uterus lay behind it and was movable.

I operated on January 9th, 1906, removing a multilocular cyst weighing 4 lb. 7 oz., and containing several pints of glairy ovarian fluid. The pedicle was broad and long. The base of the cyst, however, did not burrow into the broad ligament. Sections prepared from the tumour showed glandular growth, without any trace of malignancy.

I inspected the uterus and observed that the two little sub-serous fibroids on its posterior aspect, near the fundus, had become much smaller. The left uterine cornu ran on to the sigmoid flexure, which was not kinked nor otherwise obstructed. Some lobules of fat grew close up to the left cornu, probably derived from the sigmoid mesocolon. I could not detect the least trace of a ligature.

I searched the abdominal and pelvic cavities and could not find any detached glandular growths or subperitoneal fibromata. The parietal peritoneum was thickened and highly vascular. A long piece of omentum adhered to the uterus, but there were no other adhesions of any kind,

which was remarkable when the severity of the first operation is taken into account.

The patient was in very good health on April 1st, 1906, four months after the operation.

Observations.—Thus a cystic adenoma developed in the right ovary, which was apparently free from any kind of disease when I removed the left ovary subject to the same form of new growth. The development of an ovarian tumour of this kind within four years is, however, a pathological phenomenon by no means unfamiliar to us. Nor is it surprising that the fibroma of the broad ligament did not recur; had I found another, I might reasonably be accused of having overlooked it during the first operation. For a broad ligament fibroma, like the example in question, is not so probably a detached uterine tumour as an independent new growth akin to mesenteric fibroma, probably congenital, and nearly always of slow growth.*

When examining the parts around the uterus, as I removed the right ovary their condition showed the advantages of the practice of sewing broad ligament over the stump of the ovarian pedicle; for I found no adhesions between the broad ligament and the adjacent pelvic structures, so that the second operation proved remarkably easy. We know how often it is far otherwise when the ovarian pedicle formed at the first operation has been left bare, protruding into the peritoneal cavity.

The PRESIDENT said he agreed that it was desirable, when possible, to bury pedicles in the broad ligament, but that was not always practicable. The rate of disappearance of silk varied much in different cases. He had seen the silk completely disappear from ovarian pedicles in three months, leaving the stump at the cornu of the uterus smooth and quite free from adhesions. On the other hand, he had found silk present after seven years.

Dr. LEWERS said he had performed abdominal section a second

* I have discussed this question in "Fibroid of the Broad Ligament weighing 44½ lbs." in the forty-first volume of the Society's 'Transactions,' p. 173; and also in "Fibro-myoma of the Mesentery, 30 lbs., with Notes on the Surgery of Retro-peritoneal Tumours," 'Brit. Med. Journ.,' vol. ii, 1904, p. 1075.

time in the same patient in a considerable number of cases. It was certainly not the case that the pedicle left, after removing an ovarian tumour treated in the ordinary way, invariably contracted adhesions. He had several times seen it quite free from such adhesions.

Dr. Peter Horrocks said he had several times seen cases where there were no adhesions over the stump after an operation performed a considerable time previously. He mentioned a recent case where the ovaries had been removed nine years before, on account of a fibroid tumour. The latter, however, began to grow and give trouble, and so was removed a week ago by panhysterectomy. No adhesions were found over the stumps of the old operation. He remembered other cases illustrating the same fact, and he was inclined to think that the greater the degree of asepsis the less likelihood of adhesions forming over the stump. He also thought that if the distal end was strangulated by the ligature being very tight adhesions were apt to form.

Mr. Alban Doran maintained that the usual practice of leaving a ligatured pedicle bare in the peritoneum often led to extensive, if not dangerous, adhesions. Such was his experience of second ovariotomies on the same patients. Twenty years ago, when thick silks were applied to thick pedicles, and the peritoneum irritated by sponges, this complication was far more common than it was at the present day. Dr. Horrocks had referred to a different subject—removal of the ovaries for the "cure" of uterine fibroids. The pedicles projecting from a big fibroid uterus were in a position highly favourable to the development of adhesions. Mr. Doran observed that in 1901 he noted that two small, subperitoneal myomas projected from the fundus. In 1906 he found that they had undergone no increase or diminution in size.

A CASE OF PERITHELIOMA OF THE UTERUS.

By G. F. Darwall Smith, M.B., F.R.C.S.

A single woman, aged 38, a parlourmaid, was admitted into St. George's Hospital, under Dr. Dakin, on July 5th, 1906, complaining of pain in the left side, and of more or less constant bleeding from the vagina since the preceding March. In March, 1904, she had also been under Dr. Dakin's care, when double ovariotomy had been per-

formed for two ovarian cysts, one of which was suppurating. The cysts had been reported on by Dr. Rolleston as being cysto-adenomatous in character. Convalescence after this operation had been uneventful, and the patient was discharged from hospital in April, 1904, apparently well.

After this operation menstruation had ceased, and there had been no discharge of any kind noticed until the bleeding started in March, 1906. When re-admitted to hospital, in July, 1906, the cervix uteri was found to be small and of normal consistence. The uterus was freely movable, and felt somewhat unusually light. Douglas' pouch was empty, and there was no abnormal swelling in the pelvis.

On July 20th the uterus was curetted. The tissue removed was declared by Dr. Rolleston to be perithelio-matous, and is shown in one of the slides under the microscope. Nearly the whole of this tissue is seen to be composed of the cells of the growth. They are slightly elongated in shape, and can be seen quite clearly to be budding off from the periphery of the smaller vessels in very many parts of the section. Some parts of the growth are quite necrotic. In one or two parts of the growth, which probably are the older parts of it, the cells are almost glandular in type, but are seen to be arranged closely about the periphery of small vessels. Very few endometrial glands can be found in the sections. The few that are present show some evidence of proliferation of the cells lining them.

On July 31st total hysterectomy was performed by the abdominal route.

The uterus so removed is only slightly enlarged. After hardening, it measured 3 in. in length externally and $2\frac{1}{2}$ in. internally. The external appearances were normal. On slitting up the anterior wall of the uterus the cervix appeared normal to the naked eye, but at the fundus, and projecting downwards into the uterine cavity, was a soft, friable growth, which was distinctly paler than the surrounding mucous membrane. Under the microscope,

sections taken from the site of the growth show the origin of the growth less clearly than does the tissue removed by the curette, but still its peritheliomatous origin can be distinctly made out in one or two places. Almost the entire growth is made up of cells of approximately the same character as the majority of those seen in the curetted tissue. Scattered about here and there are a few capillaries, but they are by no means plentiful. Strands of elongated cells can be seen at intervals running into the growth from the region of the uterine muscle. These seem for the most part either to be, or to contain, small blood-vessels. No endometrial glands have been seen in any of the sections cut from the site of the growth. The growth can be seen to be infiltrating the uterine muscle at its base, and fairly numerous small round cells are visible scattered among the muscle-fibres for some distance towards the peritoneal surface of the uterus. There is much less necrotic tissue to be seen in these sections than in those from the curetting. Sections taken from the cervix show nothing abnormal.

If it be agreed that a perithelioma is a malignant growth arising from the adventitia of vessels, and distinguished by the long axes of the cells being arranged radially to the lumen of the vessels, it is submitted that in this growth the origin and arrangement are of that nature. The argument that ordinary sarcoma may show this arrangement as the growth extends, and, hence, that this growth may be an ordinary sarcoma, is met by the fact that the oldest parts of the growth show the peritheliomatous arrangement best. The oldest parts of the growth are distinguished by (1) necrosis, (2) a less embryonic type of cell.

I have searched through the literature of perithelioma, but I have been unable to find any record of a case of perithelioma of the uterus, though I believe one was shown to the Royal Academy of Medicine in Ireland by Dr. Hastings Tweedy in November last. Doubtless, however, the condition has often been seen before.

My best thanks are due to Dr. Dakin for so kindly allowing me to report the case.

The specimen was referred to the Pathology Committee (*see p.* 136).

Mr. Targett agreed that the sections exhibited a malignant growth infiltrating the wall of the uterus. But he regarded it as a sarcoma probably originating from the cellular stroma of the endometrium; whether it had begun in the sheaths or walls of the capillary vessels did not affect the general characters of the growth. When a sarcoma invaded a dense tissue like uterine muscle it extended between the planes of fibres and thus simulated the mode of infiltration of a carcinoma. A further investigation of the specimen was desirable.

Dr. Darwall Smith, in reply, said that he had no doubt that the specimen shown was merely a variety of sarcoma, but that, unlike some sarcomata which had been described as coming to have a perivascular arrangement as the growth extended, the most clearly perivascular part of this growth was apparently the oldest part of the growth. He believed it was Borrmann who had described malignant perivascular growths as being of two varieties: one, the true perithelioma arising from the adventitia, in which the long axes of the cells were arranged radially to the lumen of the vessel, and this arrangement was well marked in the present case; and the other, which he called periendothelioma, arising from the endothelium of the perivascular lymphatics, in which the long axes of the cells were parallel to the lumen of the vessel. He was much interested to hear of the other cases of perithelioma of the uterus which had been mentioned.

A SUPPURATING FIBROID TUMOUR OF THE UTERUS.

Shown by Dr. George Blacker.

A. R—, aged 40, was admitted into the Great Northern Hospital on April 24th, 1906, four weeks after her confinement. She had had five children and no miscarriages. After the confinement, in which version had to be per-

formed on account of a shoulder presentation, she was very ill with inflammation round the uterus. On admission the temperature was 101·4° F., the pulse rate 120; there was considerable abdominal tenderness and a blood-stained offensive discharge coming from the vagina. A tender fluctuating swelling was found in the lower part of the abdomen, reaching half-way up to the umbilicus. The tumour was quite superficial, the skin over it was reddened and œdematous, and it was situated in front of the enlarged uterus, the fundus of which reached to its upper limit. An abscess in the cellular tissue in front of the uterus was diagnosed, and an incision was made into the most prominent part of the tumour just above the symphysis pubis, rather more than a pint of pus being evacuated. The patient made an uninterrupted recovery, and was discharged from the hospital on May 28th. At this time the uterus was still considerably enlarged, but this was thought to be due either to subinvolution, or to the presence of a fibroid tumour in the uterine wall.

The patient remained well until December of the same year, when she had what was considered to be an attack of influenza. On January 1st, 1907, pain commenced in the lower part of the abdomen. As the pain continued, Dr. Rostant was called in, who informed the patient that she had a pelvic abscess, and sent her into the hospital. On admission the woman complained of considerable abdominal pain, but the temperature was normal. Some blood-stained discharge was present, the last period, which had come on a week early, being just over. On examination of the abdomen an elastic, tender, rounded, movable tumour was found, reaching up four inches above the pubes. The uterus, closely connected with the tumour, was in front of and to the left of it, and the sound passed 11 cm.

The enlarged right ovary could be felt above and separate from the main swelling. The tumour was thought to be a suppurating cyst in the broad ligament, and as it definitely increased in size under observation,

and the temperature rose to 103° F., it was decided to remove it by abdominal section. An incision was made to one side of the old scar, and on opening the abdomen a careful examination failed to show any sign of thickening or induration of the cellular tissue in front of the uterus.

The tumour was found to consist of the uterus and what was evidently an intra-ligamentary fibroid, and the whole was removed by total hysterectomy together with the right tube and ovary. As there was a good deal of oozing from the raw surface from which the tumour was enucleated an iodoform gauze drain was introduced into the vagina, the peritoneum sewn together over it, and the abdomen closed. The gauze was removed on the fifth day after the operation; the temperature fell to normal almost immediately, and the patient made a good recovery.

The specimen consists of the uterus with a fibroid tumour and the right ovary and Fallopian tube. The tumour, measuring 10 cm. by 9 cm., is growing from the right anterior wall of the uterus and is invading the broad ligament, but is surrounded by a thin layer of muscular tissue derived from the uterine wall.

The cavity of the uterus is healthy and measures 13·5 cm. On making an incision into the tumour through the right wall of the uterus about ten ounces of pus escaped, and the abscess cavity was found to contain a large mass of yellow necrotic tissue. On transverse section the cavity measures 9 cm. in length by 4 cm. across at its widest part. Its walls are irregular and covered by an adherent yellow slough.

Microscopic examination shows the lining of the abscess cavity to be composed of typical granulation tissue.

The right Fallopian tube is slightly thickened and its abdominal ostium nearly closed. The right ovary is converted into a dermoid cyst measuring 4·5 by 4 cm. in diameter, and containing in its outer wall a small plate of bone to which is attached a rudimentary incisor tooth.

Suppuration in a fibroid tumour is not a common form

of degeneration, and therefore this specimen is of some interest on that account, and also as an example of a case of anterior pelvic cellulitis. It seems probable that the attack of pelvic cellulitis which occurred in April, 1906, may have been the starting-point of the suppurative process in the fibroid tumour, which no doubt was present at that time. Unfortunately it was not possible to take a cultivation from the pus so that the species of organism present remains undetermined.

The PRESIDENT thought that these cases of true suppuration were rare. He had only seen two cases. In one the suppuration was due to the presence of cancer of the cervix complicating the fibroid; in the other it was due to the presence of a gangrenous polypus in the cavity, from which a large fibroid growing in the broad ligament was infected. The uterus weighed over 14 lbs. and was removed by total abdominal hysterectomy. In view of the fact that suppuration of fibroids was likely to arise from infection of the cervix he thought the whole of the uterus should be removed. Infection of fibroids without suppuration he had frequently observed, usually after labour or abortion.

Dr. HERMAN had seen one case in which an abundant discharge of pus was pouring from the uterus, and there was a fibroid with an irregular cavity in its interior from which pus flowed into the uterine cavity. The patient was insane. The uterus was removed by Sir F. Treves and placed in the Museum of the Royal College of Surgeons.

Dr. PETER HORROCKS said he brought a large suppurating fibroid to show at the Society last year, but owing to lack of time it was postponed. It was a large subperitoneal fibroid which suppurated after parturition at full term, and he was inclined to think that the diminution of the supply of blood to the tumour during the involuting period following parturition had something to do with the causation of the abscess. The centre or most ill-nourished part died, and so suppuration took place. He mentioned another case where a lady had a large fibroid tumour for many years. She was encouraged to wait until the change of life and not to have an operation. After the climacteric had been reached she began to lose flesh steadily, and the doctor found the tumour practically cystic, having a fluctuating feel and giving a distinct thrill. An operation was performed and the uterus was removed by supravaginal hysterectomy. It was a large uterine fibroid in the walls of the uterus, and it was full of pus. He mentioned a similar case

operated on nearly a month ago. He wished to point out that the last two cases followed upon the diminished blood-supply due to the atrophic changes of the climacteric period. All the patients did well, and he would like to call attention to the danger of using a corkscrew to draw out the fibroid when an abscess was suspected.

Mr. Malcolm said he had shown two cases * of necrobiosis, and had urged that the diminished blood-supply during involution was a chief cause of the change. When suppuration occurred there must, he thought, be a further cause of mischief.

Dr. Blacker, in reply, did not think that in his case the process of involution had had anything to do with the occurrence of the suppuration, as the uterus had involuted badly. He thought, without doubt, the fibroid had become infected from the suppurative cellulitis which had occurred eight months previously. Unfortunately it had not been possible to take a cultivation from the pus, so that the species of organism present had not been ascertained.

A CASE OF CHORION-EPITHELIOMA OF THE UTERUS; LUTEIN CYSTS IN BOTH OVARIES.

(With Plates VII—IX.)

By Dr. G. F. Blacker.

Mrs. A. B—, aged 46, was admitted into University College Hospital on January 28th, 1907. She had had five children and two miscarriages, the youngest child being seven years old. Twelve months ago she had a period of two months' amenorrhœa, followed by hæmorrhage lasting for three weeks and accompanied by the passage of some clots. This bleeding was assumed, by the medical man she called in, to be due to the onset of the menopause, but in view of the further history of the case no doubt she had an early miscarriage. After the bleeding ceased the periods returned and were regular until five weeks before her admission to the hospital. For this length of time there had been a slightly offensive

* 'Obstet. Trans.,' 1894, p. 200, and 1904, p. 15—the term "sloughing," and not "necrobiosis," was used in publishing these cases.

blood-stained discharge from the vagina. For the past two weeks there had been some throbbing pain in the vagina, and she said she had been losing flesh for a month or so past. Her bowels were moved regularly without pain, micturition was attended with some difficulty, but her general health had been good until the onset of the present illness. She had, however, suffered from a chronic winter cough for some years, and this was associated from time to time with the expectoration of a little blood. There was nothing of note in the family history. On admission the patient presented a sallow and somewhat cachectic appearance. In the lower part of the abdomen could be felt a smooth, rounded, not tender tumour, which was taken to be the fundus uteri. On vaginal examination the anterior and left vaginal walls were seen to be occupied by a rounded swelling infiltrating the tissues round the urethra and extending on to the lateral wall. This latter portion of the tumour presented a friable and sloughing surface. The intact mucous membrane over the anterior part of the tumour was considerably congested, and pressure on this area caused a good deal of pain. The urethral orifice was displaced somewhat to the left of the middle line, but a No. 6 gum elastic catheter was readily passed. A similar smaller tumour occupied the right wall of the vagina, lying in the mucous membrane and extending up into the right lateral fornix. The uterus was enlarged and there was a rounded swelling in the position of either ovary. A few days after admission the patient coughed up a small quantity of blood. An examination of the chest revealed slight impairment of movement on the right side, weak breath sounds, and some coarse rhonchi. On February 6th the vaginal growths were excised very freely, together with the lower 2·75 cm. of the urethra and practically the whole of the two lateral vaginal walls, the lower two-thirds of the anterior wall and a part of the posterior wall. Beside the two main tumours already described three smaller nodules of growth were removed from the lateral and posterior vaginal walls.

The raw surfaces left were closed as far as possible by stitching the remains of the posterior wall to the anterior, and the stump of the urethra was brought out through a button-hole opening in a flap drawn over it from the anterior wall, which in its turn was stitched to the cut edge of the mucous membrane below the clitoris. Considerable difficulty was experienced in getting beyond the limits of the growth in the right wall of the vagina, as it extended high up into the right lateral fornix, and the raw surface left in this position could not be closed, but was plugged with iodoform gauze. The patient made a good recovery from the operation, and was able for the first week to retain her urine and to empty the bladder spontaneously.

On examination under an anæsthetic the body of the uterus was found to be soft in consistence and considerably enlarged; the cervix was healthy; both ovaries were cystic.

Microscopic examination of the growths removed from the vagina showed them to be a chorion-epithelioma, and a week later, therefore, on February 13th, the uterus and appendages were removed by total abdominal hysterectomy. There were slight adhesions about the ovaries, and some little difficulty was experienced in freeing the bladder from the uterus, owing to the presence of a small nodule of growth projecting from the anterior surface of the uterus and adherent to the bladder. The latter organ had to be dissected free, but this was done without any injury to its walls. An iodoform gauze plug was inserted between the cut edges of the vagina, the peritoneum sewn together over this, and the abdomen closed without drainage. No secondary growths were found at the time of the operation in the abdomen.

Sixteen hours after the operation the patient had a sudden attack of abdominal pain, her pulse became small and feeble, she became markedly blanched, and developed some dyspnœa.

An examination of the vagina revealed the fact that a good deal of hæmorrhage was taking place from the

DESCRIPTION OF PLATE VII,

Illustrating Dr. G. F. Blacker's case of Chorion-epithelioma of the Uterus; Lutein Cysts in both Ovaries.

Fig. 1.—The uterus and ovaries. The anterior wall of the uterus has been removed, showing the growth almost filling the cavity. Both ovaries are enlarged and cystic.

Fig. 2.—The right ovary laid open, showing the lutein cysts in its interior, with hæmorrhages into the interior of the cysts, into their walls, and into the stroma of the ovary.

Fig. 1.

Fig. 2.

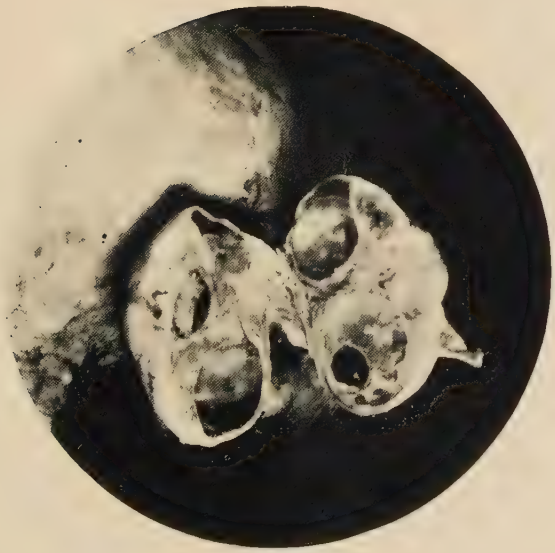

Illustrating Dr. G. F. Blacker's case of Chorion-epithelioma of the Uterus; Lutein Cysts in both Ovaries.

Adlard & Son, Impr.

DESCRIPTION OF PLATE VIII,

Illustrating Dr. G. F. Blacker's case of Chorion-epithelioma of the Uterus; Lutein Cysts in both Ovaries.

Fig. 3.—Section of the tumour in the uterus, showing columns of polyhedral cells with an alveolar arrangement, with a number of large cells containing several nuclei in various parts of the section. No large syncytial masses are to be seen.

Fig. 4.—The growth in the vagina, showing masses of protoplasm with numerous nuclei and vacuolar spaces, together with collections of cells derived from Langhans's layer.

Fig. 3.

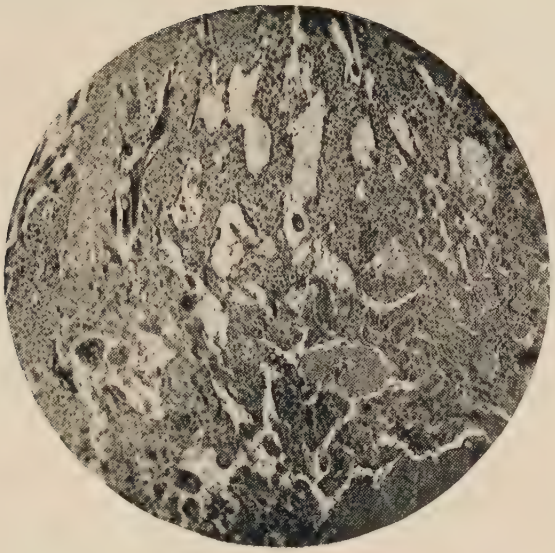

Fig. 4.

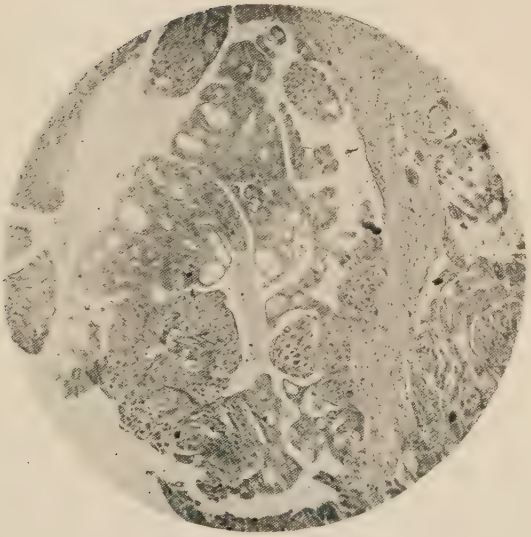

Illustrating Dr. G. F. Blacker's case of Chorion-epithelioma of the Uterus; Lutein Cysts in both Ovaries.

Adlard & Son, Impr.

granulating surface in the right lateral fornix. This cavity was plugged firmly with iodoform gauze under chloroform, and the patient was transfused with one and a half pints of saline fluid. This treatment led to a rapid improvement in the symptoms, and no further bleeding occurred.

On the second and third days after the operation the patient had a slight rigor. On the fifth day the vaginal plug was extracted under nitrous oxide anæsthesia. On the seventh day two more slight rigors occurred, the temperature only reaching 102° F. Since this time the patient has made good progress, although her recovery has been retarded by a somewhat irregular temperature, an attack of diarrhœa, and a good deal of cough with, on two occasions, the expectoration of a little blood. Examination of the chest does not show definite signs of any growths in the lungs, although over the scapular and axillary region on the right side there is some impaired resonance, weak breath-sounds, and in front some fine crepitations on taking a deep breath. The abdominal wound is soundly healed, and the vagina is almost entirely healed. The signs in the chest, taken together with the cough and the slight hæmoptysis, are very suspicious of some secondary growths in the lungs, but, if there are any, possibly they may undergo atrophy, as has happened in other cases where the primary growth has been completely removed.

Unfortunately, no doubt in part as the result of the constant coughing, the patient has lost the control over the bladder which she had for the first week after the second operation, and at the present time there is almost complete incontinence of urine.

The specimen consists of the uterus, Fallopian tubes, ovaries, and some secondary growths removed from the vagina.

The uterus (Fig. 1) is enlarged, measuring 10 cm. at its widest part by 11·5 cm. from fundus to external os. The uterine wall, on section, varies in thickness from 1 cm. in the left wall to 2·5 cm. in the middle of the right wall

of the body, where there is a small interstitial fibroid 1·5 cm. in diameter. A few small interstitial fibroids are situated in the right wall of the body and one in the left. The interior of the uterus is occupied by a growth which is invading the uterine wall above and on the right side, and to a lesser extent on the left side. The lower rounded margin of the growth descends to within 1·75 cm. of the internal os; the space left is occupied by blood-clot. The growth itself, on section, has a friable surface, and is reddish-brown in colour, closely resembling in appearance a mass of blood-clot, except at its site of origin in the uterine wall, where there is a layer of tissue, yellow in colour, softish, and rather more granular in appearance than the uterine wall it is invading. The whole surface of the growth presents a homogeneous appearance, and there is no evidence of the presence of cysts or of chorionic villi.

The cervical canal, which measures 3 cm. in length, is healthy. Both ovaries are enlarged (Fig. 1), the right one measuring 5·5 cm. by 4 cm. (Fig. 2), the left 6 cm. by 5 cm. in its widest part. They both contain a number of cysts distributed throughout their substance, the largest of these being 2 cm. in diameter. The outer surfaces of the ovaries present a greyish-red appearance, and the thin-walled cysts cause well-marked translucent projections on the surface. A section through the right ovary (Fig. 2) shows four cysts with well-defined walls, with a smooth inner surface, containing a clear mucinous fluid, and showing a considerable degree of vascularity. Several of the cysts show hæmorrhages into their interior and into the cyst wall. In the stroma of this ovary there is a small, quite distinct, corpus luteum 6 mm. in diameter. A section through the left ovary presents a similar appearance, although in this case the cysts (three in number) do not occupy so large an area of the section. The largest cyst in this ovary shows a definite inner lining which can be stripped away from the cyst wall. There is marked vascularity of the tissues and especially of the stroma. In

some of the cysts the mucinous contents have coagulated into a jelly-like mass *in situ*, while from others it has escaped.

Both Fallopian tubes are healthy.

The growths removed from the vagina comprise two large tumours and three smaller ones. The largest of these, measuring 6·5 cm. by 4 cm., was attached to the anterior vaginal wall, involving the inferior wall of the urethra, and extended on to the left wall of the vagina. The latter part of the growth had destroyed the mucous membrane and formed an ulcerating and breaking-down mass. Intimately united to the upper part of this tumour and removed with it is the lower 2·75 cm. of the urethra, which has been laid open along the middle line superiorly. On section portions of this tumour present a greyish-white granular appearance; the tissue is soft and friable and breaks down readily. A smaller growth of similar character was removed from the left lateral wall of the vagina above the larger tumour. An oval mass 4 cm. by 3 cm., of similar appearance on section, was removed from the right vaginal wall and extended high up into the right vaginal fornix, and two small tumours 1 cm. in diameter were excised from the upper part of the posterior wall of the vagina.

Microscopic examination of the tumour in the uterus (Fig. 3) shows the greater part of it to be composed of fibrin and blood-clot. The growth itself is made up of branching columns of polyhedral cells with round or oval vesicular nuclei, arranged in an alveolar manner, while here and there are large cells containing several nuclei. There is an almost entire absence of any large syncytial masses in the uterine growth, although in places strands of syncytium are interspersed between the cell masses. The growth in the vagina (Fig. 4), on the other hand, contains large masses of undifferentiated protoplasm containing numerous oval darkly-staining nuclei and many vacuolar spaces, as well as masses of smaller cells, evidently derived from Langhans' layer of the chorionic epithelium, which are mingled with the syncytial masses in an irregular

manner. Everywhere blood-clot and masses of fibrin are present with the tumour elements, even penetrating between individual cells, but there is no connective-tissue stroma.

An examination of the ovaries shows that all the cysts (Fig. 5) exposed on the cut section are derived from corpora lutea. The great majority of these cysts have no epithelial lining, but two small cysts in the right ovary have an internal lining of several layers of spherical cells. The cysts are limited externally by a layer of fibrous tissue derived from the stroma of the ovary; internal to this there is a well-marked layer of lutein cells of varying thickness, but present without exception in some portion of the wall of all the cysts examined, and in most of them exceedingly well marked. With the exception of the two small cysts already alluded to, in none of the others is there any epithelial lining internal to the lutein layer, although in many places there is a well-marked layer of fibrin lining the inner surface of the lutein cells. In both ovaries some lutein cells can be seen between the cells of the stroma (Fig. 6), some little distance from the nearest cyst, but there is no general distribution of lutein cells such as has been described in other instances. Besides the cysts there is a well-marked corpus luteum in the right ovary and a smaller one in the left ovary. In some of the cysts the innermost layer of the fibrous tissue immediately outside the lutein layer, namely the tunica vasculosa, is extremely vascular. If the amount of lutein tissue in the walls of the cysts be taken into account there can be no doubt that there is an excess of this tissue present in both ovaries.

This case is a good example of the simultaneous occurrence of a chorion-epithelioma of the uterus with lutein cysts in both ovaries. These two conditions have now been found present at the same time in so many cases that such an association must be due to something more than mere coincidence. I am, however, I must confess, rather sceptical as to the truth of the hypothesis which assumes that they stand in a definite causal relationship

DESCRIPTION OF PLATE IX,

Illustrating Dr. G. F. Blacker's case of Chorion-epithelioma of the Uterus; Lutein Cysts in both Ovaries.

FIG. 5.—Section of the wall of one of the lutein cysts in the right ovary, showing fibrous tissue of stroma, layer of lutein cells, and coagulated contents of cyst.

FIG. 6.—A portion of the right ovary, showing lutein cells scattered throughout the stroma.

Fig. 5.



Fig. 6.

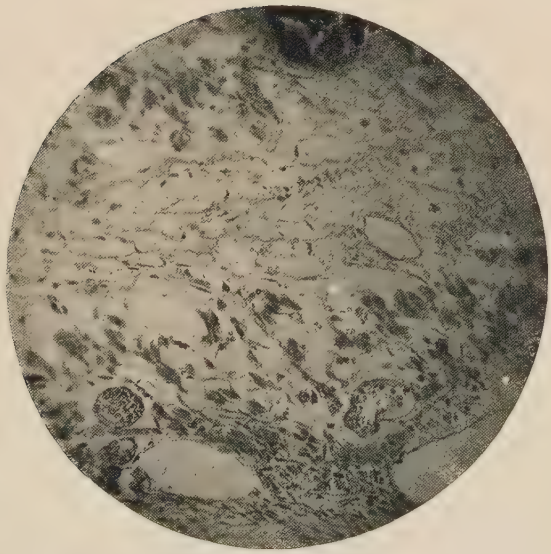

Illustrating Dr. G. F. Blacker's case of Chorion-epithelioma of the Uterus; Lutein Cysts in both Ovaries.

Adlard & Son, Impr.

to one another. That is to say that the development of a chorion-epithelioma in the uterus is due to an excess of lutein tissue in the ovary and an over-production of the internal secretion of that organ. Such an excess of lutein tissue has now been met with in so many cases of hydatidiform mole and chorion-epithelioma as to constitute a most remarkable fact. If we consider, however, for a moment the changes which occur in the uterus and in the ovaries in these cases we cannot but be struck by the very marked similarity between them. In the case of the uterus we have an excessive proliferation of the trophoblast or of the epithelium of the chorionic villi, together with the development of cystic spaces, no doubt due to serous transudation into the tissues of the villi. In the ovary we have a marked proliferation of the cells of the corpora lutea with the development of cysts, possibly of similar origin. In both instances the tissues chiefly affected are composed of young, rapidly-growing cells such as might be expected readily to respond to any undue stimulus. It would seem probable that the cause of the development of a chorion-epithelioma, conforming, as it does, to the general law of carcinomatous growths in that it affects a tissue which is already old if we consider the total period of its growth, will be found not to differ from the cause of a malignant growth in any other part of the body, and that future researches will demonstrate it to consist in some chemical change in the blood of the patient, or in the fluids bathing the tissues of the part affected. Further evidence in favour of such an interpretation is, I think, to be found in the fact that some excess of lutein tissue has been demonstrated to occur in all cases of normal pregnancy, although not to such a marked extent as in cases of hydatidiform mole or chorion-epithelioma ; nor is this surprising when we recollect that in cases of normal pregnancy there is no atypical proliferation of the trophoblast, and therefore we would not expect any undue development of the cells of the corpus luteum.

The experiments of Fränkel and others which have been brought forward to support the theory of the important part played by the corpus luteum in presiding over the development of the early ovum appear to me to be far from conclusive; and although the development of the trophoblast and of the cells of the corpus luteum certainly appear to proceed *pari passu* in these cases of hydatidiform mole and chorion-epithelioma, yet the assumption that the one depends upon the other seems to me to be far from warranted. Many more cases of this kind must be examined critically before we shall be able to come to any definite conclusion on this difficult subject. In this particular case, whatever may be the true explanation as to the cause, the fact remains that in the ovaries there is a marked excess of lutein tissue, and in the uterus there is a typical chorion-epithelioma.

Postscript, April, 1907.—As the patient has died since the specimen was shown it is possible to complete the history of the case. The general weakness, which was a marked feature from the time of the second operation, gradually became more and more apparent, and the patient rapidly wasted. On March 8th it was found, owing to the constant dribbling of urine, that the capacity of the bladder had become greatly diminished. At this time there was very great weakness of the leg and thigh muscles, and subsequent examination showed a well-marked reaction of degeneration in the thigh muscles, although the leg muscles were normal. On March 17th a secondary growth was found present on the inner side of the right thigh. On March 18th the growth, which lay quite superficially under the skin and external to the deep fascia, was removed. There was practically no bleeding, all the vessels entering the growth appearing to be thrombosed. A week later examination of the chest showed definite signs (namely, impaired resonance, weak breath sounds, and fine crepitations) pointing to the existence of secondary growths, over the lower lobes of both lungs, especially on the right side. On March 29th

the patient had two convulsions, with clonic and tonic spasms, the second being followed by a semicomatose condition which lasted some two hours, which were considered to be uræmic in origin. On the following day her condition was very grave, but there was no paralysis of the arms or legs, the cranial nerves were unaffected, and the pupils reacted well. On April 1st the woman gradually sank and died in a state of coma.

A *post-mortem* examination showed the abdominal wound to be soundly healed; in the remains of the vagina there were some small nodules of growth, which showed signs of ulceration. There were no growths in the peritoneum. The right ureter and the pelvis of the right kidney contained pus. There were several small growths a quarter to one inch in diameter in either kidney. There was also a mass of breaking-down growth in the left suprarenal gland. There were small nodules of secondary growth in the liver, spleen, and scattered beneath the mucous membrane of the small intestine. There were no growths in the glands of the abdomen or of the chest.

Both lungs, more especially the lower lobe of the right lung, were studded with small nodules of growth varying from one twelfth to one inch in diameter. In the brain there were some small growths in the left parietal and occipital lobes. The spinal cord was healthy and there were no growths in the bones.

Dr. Amand Routh was glad that Dr. Blacker had operated in this case, for many cases had been reported where permanent recovery had followed removal of the primary uterine growth, when the patient, judging from the symptoms and physical signs, had secondary growths in the lungs. Could Dr. Blacker explain these recoveries?

The President agreed with Dr. Blacker that lutein cysts had no causal relation to chorion-epithelioma. In his own case, published in the 'Transactions' in 1896, the ovaries contained no cysts, and the single corpus luteum was solid. Dr. Blacker's case raised several important points for discussion, especially the presence of hæmoptysis and of secondary growths in the vagina. These growths in the vagina, which were probably embolic, had been found even when the uterus was healthy, and they had been

known to disappear spontaneously. It was therefore important that their presence should not be taken as a contra-indication to operation. It was possible that a secondary growth in the lungs might disappear in the same way.

Dr. BLACKER, in reply, said that with reference to the possibility of the secondary growths in the lungs, if there were any present, clearing up, Dr. Blacker had recorded, in the 'Transactions,' vol. xlvi, p. 57, a case of chorion-epithelioma, in which a secondary growth in the vulva had sloughed out under observation, and the raw surface left had healed up entirely. Some eight or nine cases had now been recorded in which patients had recovered, although presenting signs of secondary growths in the lungs, when the primary growth had been completely removed.

A CASE OF SUPPOSED RECURRENCE AFTER VAGINAL HYSTERECTOMY FOR CANCER OF THE CERVIX.

(With Plate X.)

Microscopic sections shown by Dr. C. HUBERT ROBERTS.

THE patient, a multipara, aged 43, was admitted to the Samaritan Free Hospital, on October 19th, 1906, with a history of nine months' bleeding and discharge from the vagina, together with pain and wasting. On examination, there was a well-marked patch of ulceration on the posterior lip of the cervix, extending upwards as far as the os internum. The growth was friable and bled profusely on touch. The uterus was mobile and no thickening could be detected in the broad ligaments. Vaginal hysterectomy was performed on October 22nd, 1906. The operation was difficult due to pelvic adhesions which were probably old. Owing to slipping of a ligature on the left broad ligament there was some severe bleeding before it could be secured. Both broad ligaments were tied off with silk ligatures. Those on the right side soon sloughed away, but several on the left side remained very firm, and it

DESCRIPTION OF PLATE X,

Illustrating Dr. Hubert Roberts's case of Supposed Recurrence after Vaginal Hysterectomy for Cancer of the Cervix.

Fig. 1.—Section of the original growth. It is an atypical squamous-celled carcinoma. The growth has invaded the vaginal portion as far as the os internum.

Fig. 2.—Section of supposed recurrence. It is not malignant. The stroma consists mostly of fibrous tissue with large vessels (A, A). In the centre are well-marked plicæ (B, B) of the Fallopian tube which had been included in the ligatures.

Fig. 1.

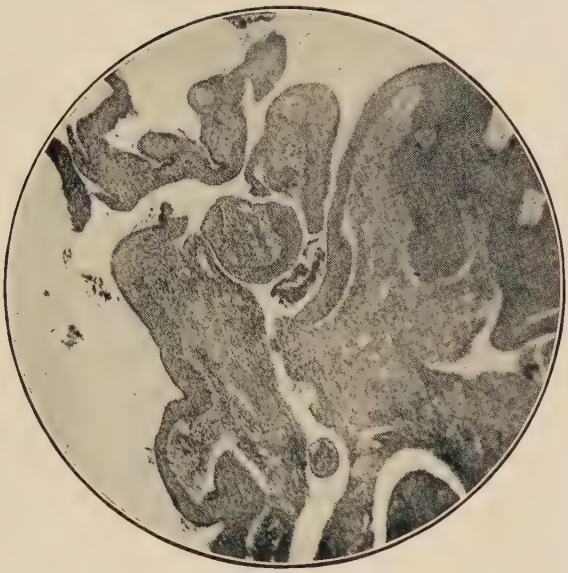

Fig. 2.

Illustrating Dr. Hubert Roberts's case of Supposed Recurrence after Vaginal Hysterectomy for Cancer of the Cervix.

Micro-photographs by Dr. Eastes. *Adlard & Son, Impr.*

was decided to cut them short and leave the knots *in situ*. This bears on the subsequent history of the case. In December, 1906, two months after the operation, the patient came back to show herself, and it was then found that there was a suspicious patch of granulations high up on the left side of the vagina in the region of the scar. At the time I feared this was recurrence, and advised the patient to come into the hospital again for operation. She however refused, and went elsewhere for treatment. On February 9th, 1907, five months after the original operation, the patient came back to the hospital, and I then found the mass in the roof of the vagina on the left side had increased considerably in size and bled freely on touch. I advised its removal, and this was done on February 11th. The growth was of the size of a mulberry, and seemed to have a very tough pedicle. On cutting through this several knots of thick silk were discovered embedded in thick fibrous material. No infiltration of the vaginal scar or parametrium could be detected.

Sections of the original growth proved it to be one of atypical squamous-celled carcinoma. The "recurrence," or what has been taken to be recurrence, was in no sense malignant. It consisted of fibrous tissue covered with granulations, the whole forming a papillomatous mass. The stroma showed much small cell infiltration and several thick-walled vessels. One part of the section contained well-marked folds of mucous membrane which, without any doubt were altered plicæ belonging to the Fallopian tube included in the ligature.

Dr. Roberts remarked that he thought the case one of some interest, as, before microscopical examination, he took the condition to be a malignant recurrence. Cases of a similar nature had been reported by other authorities both after vaginal hysterectomy, and the old clamp method of abdominal hysterectomy for fibroids in which the included tubes had subsequently given rise to curious hæmorrhages from the stump.

Dr. Roberts regretted that in his case he had used such

thick silk and that the ligatures had been cut short, as evidently the Fallopian tube had been included, and subsequently given rise to the papillomatous mass arising in the first instance from the mucosa of the tube itself.

Mr. TARGETT had seen several specimens of a similar kind, which had been mistaken for nodules of recurrent growth. The inclusion of the Fallopian tube in the scar was probably not due to the method of vaginal hysterectomy employed, as he had seen it after both clamp and ligature operations. The mucous membrane at the cut end of the tube became irritated in the healing vaginal wound, and produced a papillary formation.

INAUGURAL ADDRESS.

Ladies and Gentlemen,—My first and pleasant duty on occupying this Chair is to thank you for the very high honour which you have conferred upon me by electing me your President. It is an honour which I greatly appreciate, and I will do my best to carry out the duties which the office entails. But I am met at the very outset with the difficulty of giving an inaugural address.

When I think of the many distinguished, learned, and eloquent men who have held the position of President of this Society, I am diffident of my ability to deliver an address which shall be worthy to take its place in your 'Transactions' beside some of the eloquent addresses of the past.

Many of my predecessors have given brilliant and learned inaugural addresses. I have no gift for saying elegant, pretty, or pleasant things. But if my remarks have no flavour of Attic salt, they are at least not to be taken with a grain from the cellar. They will be sincere, and will be directed to a few subjects which an experience of twenty years as an obstetrician and gynæcologist has convinced me are in need of consideration at the present time if we are to carry on scientifically the work which modern developments have rendered possible.

Perhaps I have one qualification. The Obstetrical Society and I have grown up together. If I did not actually "watch by its cradle," I did the next best thing by being in the cradle with it, having come into the world at the same time as the first volume of our 'Transactions.' I am able to look upon our 'Transactions' with the sympathy of a twin brother, as well as with that of an Editor and President. The Society is passing through a

critical period of its life at the age of forty-nine. It is happily celebrating the event by receiving back into the family its only daughter, and it is not likely that it will have any more offspring.

At the Inaugural Meeting of this Society in 1858, Dr. Babington quoted a derisive remark made about the obstetrician of his day, that "like Lord John Russell, he would deliver a woman with child, cut a man for the stone, or take command of the Channel Fleet," a testimony, said Dr. Babington, to his boldness, energy, talent and presence of mind.

Endowed with only the first of Lord John Russell's powers, I find some difficulty in delivering an Inaugural Address, and must claim your indulgence for its shortcomings.

I shall exercise one of the privileges of youth and address myself mainly to the future, in which I have every confidence, rather than take up your time with a consideration of the past, which is recorded in our 'Transactions,' in our libraries, and in our journals.

The advances made in obstetrics and gynæcology have been so great—indeed, so marvellous, in the lifetime of our Society, that there is no lack of material for one who chooses the *rôle* of the *laudator temporis acti*; the advance has been so rapid that we have nearly attained perfection in many of the operative procedures, such as Cæsarean section, ovariotomy, and hysterectomy, which were almost uniformly fatal at the time our Society was founded. Of the graver diseases only eclampsia and cancer and embolism baffle us, and much progress is being made in the treatment of the two former affections. But for many minor ailments severe operations are recommended by some gynæcologists, and condemned by others, and there are differences of opinion as to the justifiability of methods of treatment, differences which would disappear if the facts were frankly stated and sound judgment were brought to bear upon the consideration of those facts. In a few directions we have advanced to certain

knowledge, but in many others the way to truth has been blocked by obstructions which it is the function of societies like this to remove.

I saw some time ago a suggestion made for a presidential address to a learned society—"things we do not know." This would be too large a subject for an address on obstetrics and gynæcology. But some remarks on the principles which underlie the true advancement of scientific knowledge, with illustrations of the extent to which those principles are followed at the present time by obstetrical and gynæcological authors, may possibly not be unacceptable, especially to the younger Fellows of our Society, in whose hands the future of the Society rests.

Three hundred years ago (1605) our greatest philosopher, Francis Bacon, wrote his treatise on 'The Advancement of Learning.' It contains his inductive method—the accumulation and systematic analysis of isolated facts to be obtained by observation and experiment—which forms the basis of modern scientific work.

Bacon begins his treatise by mentioning three diseases of learning, viz. "vain words," "vain matter," and "deceit or untruth."

The first of these diseases, "vain words," occurred "when men began to hunt more after words than matter; and more after the choiceness of the phrase and the round and clean composition of the sentence, and the sweet falling of the clauses, and the varying and illustration of their works with tropes and figures than after the weight of matter, worth of subject, soundness of argument, life of invention or depth of judgment." The disease of vain words had been scoffed at by Erasmus before Bacon's time in a sentence which was doubtless taken to heart by the University of London when considering the question of compulsory Latin: "decem annos consumpsi in legendo Cicerone" and echo answered in Greek, "ὄνε,"—"ass"!

This disease of learning in its acute classical form is not very prevalent amongst obstetricians and gynæcolo-

gists; but in the form of logorrhœa it is still a common ailment. Certain writers do not indulge in the delicate and polished kind of learning of which Bacon speaks but run riot in words and in diffuseness of expression, so that it is becoming impossible to keep pace with the literature of our subject, the whole inclination and bent of the writers, in Bacon's phrase, being rather towards "copia" than weight. Diffuse writing and florid writing, which Bacon likens to an initial letter of a book, "which though it hath large flourishes yet it is but a letter," form a hindrance to the "severe inquisition of truth" in obstetrics and gynæcology at the present day.

Bacon's second disease of learning is "vain matter," when persons "out of no great quantity of matter and infinite agitation of wit, spin out unto us laborious webs of learning, admirable for the fineness of thread and work, but of no substance or profit." In recent years the study of morbid specimens procured by operations has exercised such fascination for obstetricians and gynæcologists that this disease is less prevalent than it was, and the Fellows of our Society, I think, are almost immune. In the weekly press we occasionally find long unsubstantial papers which offer to our hungry minds but a "halfpennyworth of bread to an intolerable deal of sack."

The third disease of learning, "deceit or untruth," is "of all the rest the foulest; as that which doth destroy the essential form of knowledge which is nothing but a representation of truth; for the truth of being and the truth of knowing are one, differing no more than the direct beam and the beam reflected." Of this disease there are two forms, imposture and credulity, both of which, I fear, occur from time to time sporadically amongst us.

Untruth occurs not in its crudest form of stating what is not a fact but in the insidious form of omitting to state all the material facts. Is it not sometimes misleading to publish cases without any after-history, when a little inquiry might have shown that history to be un-

favourable? Do we not sometimes find a selected consecutive series of favourable cases published, whilst the unfavourable cases preceding and following the series are not published? Do we not find cases of malignant disease published within a few weeks of operation, although they are of no special interest except from the point of view of the possibility of cure? Do we not find severe abdominal and vaginal sections performed for sundry ailments and the cases published as "cures," when some of them have been followed by pain and disabilities greater than those for which the operation was performed, of which mention should have been made in the published accounts? I say, of my own knowledge, and of the knowledge of many of you, that these things occur, and that they form a hindrance to the "glorious inquisition of truth."

Having dealt with these three diseases of learning, Bacon goes on to consider the "peccant humours," "errors," or "deficiences" of learning.

The first of these peccant humours is "the affecting antiquity or novelty."

The modern obstetrician and gynæcologist does not affect antiquity, and, indeed, treats it with unmerited neglect. And yet, especially in obstetrics, the older writers well repay perusal. From want of sufficient acquaintance with the ancient obstetrical classics, one of our Fellows recently described as new a method described by Hippocrates. The Trendelenberg position was figured by Scultetus in 1653; Walcher has in recent years obtained some renown as the inventor of his "position," which was described and figured by Scipio Mercurio in 1595; and in 1895 I described the operation of dividing the child's clavicles, since called "cleidotomy," only to learn recently that it had been described by Aëtius in the sixth century, and that Aëtius had taken the operation from Philumenos.

Not only are the old classical writers neglected, but too little heed is paid by certain gynæcologists at the present time to the tradition of the schools handed down by the

teachers of obstetrics and gynæcology. This neglect is especially prevalent amongst those who have had no special training at the hands of a master, and who base their practice only on their own experience and reading. Yet every obstetrician and gynæcologist who has experience of it knows that there is no teaching equal to that afforded by a skilful master. The want of this opportunity of receiving the tradition of the schools in gynæcology and obstetrics has led some gynæcologists to operate on certain cases of peritonitis and hæmatocele, which would have recovered much more satisfactorily if they had been treated conservatively, as all such cases were treated in the days of old.

But it cannot be attributed to the modern obstetrician and gynæcologist that he does not affect novelty. As it has long ago been said that every obstetrician invents a new forceps, so it will be said in the future that every gynæcologist invents a new method of stitching up the uterus or its appendages. Certainly it is only by trying new methods that advance is made, but it is the "*affecting* novelty" that is undesirable, "the facility of credit and accepting or admitting things weakly authorised or warranted." I believe that if attention had been paid to this Baconian warning, some of the least creditable features in modern obstetrics and gynæcology would have been avoided. Therefore, when new methods of treatment are proposed, it were well to inquire what is the strength of the author and what is the strength of the warrant. Is the author one who by training, by experience, and by his past record, has proved himself to be a lover of truth and skilful in his work, and is his new method warranted by carefully observed facts and by a sound judgment based upon them?

After the error of affecting antiquity or novelty, a second error is cited, "a distrust that anything should now be found out which the world should have missed and passed over so long time." New methods of research have led us to be less "distrustful" than those who lived in Bacon's

time, the most remarkable instances being the discovery of bacterial diseases and of chorion-epithelioma; and I think societies like ours do much to preserve us from the error (of which Bacon complains) of "too great a reverence and a kind of adoration of the mind and understanding of man, by means whereof men have withdrawn themselves too much from the contemplation of Nature and the observations of experience, and have tumbled up and down in their own reason and conceits."

To these two errors Bacon adds "impatience of doubt and haste to assertion without due and mature suspension of judgment," and "the manner of the tradition and delivery of knowledge which is for the most part magistral and peremptory, and not ingenuous and faithful, in a sort as may be soonest believed and not easiliest examined." I think I have met with papers on obstetrical and gynæcological subjects of which this could truly be said.

Bacon advises the keeping of "registers of doubts," and commends them as excellent things, "so that this caution be used, that when they be thoroughly sifted and brought to resolution they be from henceforth omitted, discarded and not continued to cherish and encourage men in doubting."

Is it not time that, if I may borrow the phrase, our present-day "register of doubts" should have certain items expunged from it, such as, that the aseptic method of treatment in midwifery and gynæcology is superior to the antiseptic method; that the bougie method is generally the best means known at the present time for inducing premature labour; that in suturing the abdominal wall the fascia should be separately stitched; that Aveling's repositor is the best means of reducing a chronically inverted uterus; and many other questions which were at one time doubtful, but which I believe the general experience of obstetricians and gynæcologists (of this country, at any rate) has proved to be no longer so.

The last and the greatest error of learning is the mis-

taking the last or furthest end of knowledge, which is "to separate and reject vain speculations, and whatever is empty and void, and to preserve and augment whatever is solid and fruitful."

This definition of the furthest end of knowledge would form an excellent motto for a learned society.

Having dealt with the diseases and errors of learning in general, Bacon has some shrewd remarks upon the deficiences of medicine in his day, a science which he says "hath been more professed than laboured, and yet more laboured than advanced, the labour having been in my judgment rather in circle than in progression. For I find much iteration, but small addition." Amongst the chief deficiences he noted "the discontinuance of the ancient and serious diligence of Hippocrates, which used to set down a narrative of the special cases of his patients, and how they proceeded, and how they were judged by recovery or death." These histories were to be "neither so infinite as to extend to every common case, nor so reserved as to admit none but wonders: for many things are new in the manner which are not new in the kind, and if men will intend to observe they shall find much worthy to observe."

The "history of the case," which Hippocrates and Bacon thought so important, remains so at the present day; but I think the histories are not taken now as fully as they were a quarter of a century ago by the clinical clerks in hospitals. This is partly due to the many calls on the time of the clinical clerks, but there is no doubt that it is a "deficience" at the present day; for a complete history is often a partial diagnosis.

Bacon notes as a deficience amongst the doctors of his time that "they enquire not the perfect cure of many diseases, or extremities of diseases, but, pronouncing them incurable, do enact a law of neglect and exempt ignorance from discredit." Is not this the case at the present day with those who operate only on cases of cancer in which the uterus is freely movable?

He commends the union in doctors of experience and learning in the well-known passage: "they be the best physicians which being learned incline to the traditions of experience, or being empirics incline to the methods of learning."

If I have wearied you with quotations from Bacon's 'Advancement of Learning' my excuse must be that it is useful, periodically, for a Society to have brought before it those great principles in accordance with which alone is true advance possible. They may be summed up in careful, patient collection of facts and judicious comment upon them. I do not know any Society which takes more care in ascertaining its facts than ours. The Pathology Committee, to which all doubtful specimens are referred, is a feature of our work which might well be imitated by other Societies. But I think that with little effort the number of facts for our consideration might be greatly increased. A suggestion which I would make to the Fellows of our Society is that all specimens obtained by operation and all still-born children be submitted to examination. Specimens may now be conveniently preserved in a large tank in formalin solution in layers separated by planks (a method adopted by Mr. Lawrence for my own specimens for some years past). If this method of preserving and examining both macroscopically and microscopically all operation specimens were adopted the rate of our advance in obstetrical and gynæcological knowledge would be increased! If, further, precise measurements were given, preferably in the metric system, instead of using such vague expressions as "fingers'-breadths," how much would time and space be saved and accuracy increased! The value of records would be enhanced if operators would agree as to the meaning of the term "recovery" after operation, as, for instance, that it meant "alive and well twenty-eight days after operation"—whereas at the present time some operators discharge their patients at the end of two or three weeks after an abdominal section, and thus understate the rate of mortality by such deaths as occur in the third or fourth week after operation.

But if we find these errors in the statement of individual facts how much more do we find them in those collections and tabulations of facts which we call statistics! Statistics have become proverbially unreliable; one cynic has gone so far as to define them as "lies expressed in figures." Yet there is no reason, except the carelessness and imposture of authors, why they should not be *truths* expressed in figures, and they form the most valuable means we have of advancing the knowledge of medicine, for in Morgagni's words, which the 'Lancet' reminds you of weekly, "nulla autem est alia pro certo noscendi via, nisi quam plurimas et morborum et dissectionum historias, tum aliorum tum proprias, collectas habere, et inter se comparare." How necessary is it, then, that the statistics should be sound, unaffected by the disease of "vain words" or "untruth," or by the peccant humour of being expressed "in a sort as may be soonest believed and not easiliest examined!"

In no disease is it of more importance that statistics should be reliable than in the case of the treatment of cancer of the cervix. This greatest scourge of woman is attracting many workers, and the solution of the question of its treatment is the goal towards which all the Fellows of a Society like ours should strive. Yet it is "more laboured than advanced, and the labour is rather in circle than in progression." For what is our knowledge on the subject after twenty-five years' work by hundreds of gynæcologists on thousands of patients? It amounts to this: (1) That cancer of the cervix is curable in its early stages by local removal either of the cervix by high amputation, or of the uterus by hysterectomy; (2) that in somewhat advanced cases abdominal hysterectomy permits a more extensive operation and one more in accordance with surgical principles than is possible by the vagina.

The first fact, the curability of cervical cancer in its early stages, is denied by some authors, who rely only on their own unfortunate experience. The fact of its cura-

bility, however, is well known to all but a few individuals of whom some have gone so far as to give up operating on cancer of the cervix, thus trying to "enact a law of neglect and exempt ignorance from discredit"; but they will not succeed.

The second fact is also undeniable. But this is no reason for performing abdominal hysterectomy for all cases of cancer of the cervix: in the early cases, especially of cancer of the portio, the vaginal operations are certainly more suitable and have a much lower mortality. With regard to the mortality of the abdominal operation for cancer of the cervix, both forms of Bacon's untruth are frequently met with—imposture on the part of the author and credulity on the part of the reader.

I have for many years collected published statistics of operations for cancer of the cervix, and have been surprised to find how rarely the statistics were not misleading.

A common way in which they are fallacious may be illustrated by a hypothetical table:

Cases of cancer of the cervix seen . .	100
Cases of cancer operated on . . .	50
No. of deaths from operation . . .	10
No. of deaths from other causes within five years of operation	10
No. of patients who did not reply to inquiries .	10
No. of patients with recurrence within five years of operation	15
No. of patients free from recurrence after five years	5

Now it is clear that in this table only 10 per cent. of the patients operated on, and 5 per cent. of those seen, have been proved to be free from recurrence after five years, *i. e.* have been proved to be "cured," to use the conventional term. But many authors omit the cases of deaths from operation, the cases of deaths from other causes, and the cases of patients who do not reply to inquiries, and give their cures as five in twenty, or 25 per

cent. They omit these cases on the ground that it is impossible to say whether these cases would have had recurrence or not. This is no doubt true ; but it is not true to state, as by inference these writers do, that cases which die after operation, being probably the more advanced cases, are no more likely to recur than those which survive the operation, and it is not true that a patient who is dead from recurrence is as likely to reply to an inquiry as one who is alive and well.

This method of reckoning the percentage of cures may have the remarkable effect of giving an operator's results as 30 per cent. free from recurrence after three years, and 50 per cent. free from recurrence after five years for the same series of operations! Indeed, it would be possible for an author using this method of computation to claim that if *one* patient of one hundred operated on remained well for five years, 100 per cent. of his cases were "cured," and yet ninety-nine out of the hundred cases operated on may have died from the immediate effects of the operation.

I submit that if a gynæcologist performs one hundred hysterectomies for cancer of the cervix, and only ten are known to be free from recurrence after five years, the proper way of stating his percentage of cures is that it is "at least ten."

But the percentage fallacy has become so frequent since the severer operations were introduced that, in my opinion, no notice should be taken of results stated in percentages unless full details are given of the figures on which those percentages are based.

There is yet another fault in statistics of this disease to which I must allude, which consists in the author's giving great prominence to his rate of mortality (if it is a small one), sometimes giving it in leaded type but without any information as to the special methods of treatment which explain the low rate of mortality, leaving it to be supposed that the low rate of mortality is due to his own special skill. I think many statistics would be increased

in value if they gave a little less of the man and a little more of the method.

I do not think I need apologise for drawing attention to these faults in the statistics of cancer of the cervix which are apt to be overlooked by gynæcologists. I feel sure that advance in the treatment of this dread disease can only take place when these errors are eliminated, and when the cases come for treatment in the early stages. In order that we may get the cases early two things are desirable, first, diffusion among women of knowledge of the symptoms of the disease, a course which has been adopted with good results in Germany, and which might well be undertaken by the Royal Colleges in this country; and, secondly, a recognition by general practitioners, if not by the General Medical Council, that it is a neglect of duty to treat hæmorrhage or discharge which may be due to cancer of the uterus without making or advising a local examination.

It might be thought that in their own interests general practitioners would advise an examination, for by not doing so they lay themselves open to an action at law for negligence; but, unfortunately, experience shows that there are still many practitioners who prescribe medicines and injections for uterine hæmorrhages and discharges due to cancer without making a local examination. In some cases this would be refused by the patient; but the doctor should at least protect himself by advising it. I am sure I am expressing the opinion of all gynæcologists when I say that there is nothing sadder in our work than to find, as we frequently do, that the cancer has been allowed to grow beyond the possibility of removal, sometimes through feelings of false modesty on the part of the patient, but sometimes, alas! through the negligence or deference of the doctor to whom she has gone for advice, and in whom she has put her trust.

When the cases are brought to our notice in the early stages I believe that the extended abdominal operation will be adopted for a few cases only, that most of the

cases will be treated by the vagina by the galvano-cautery, and I am fortified in this opinion by the fact that Werder, one of the pioneers of the abdominal operation, has given it up in favour of the Byrne operation with the galvano-cautery. But this question can only be decided by the publication of statistics free from the fallacies to which I have alluded, and I appeal to the Fellows of this Society to do their share in providing them.

My occupation of this Chair occurs at an eventful stage in the history of our Society. You are aware that the Obstetrical Society and the British Gynæcological Society have agreed to amalgamate and to form the Obstetrical and Gynæcological Section of the new Royal Society of Medicine. This Society is in course of formation, and will be incorporated in the course of the present year. The union of the various medical societies of London has been accepted by the great majority of the societies, and I have no doubt that when it has taken place the societies which at present refuse to join for various reasons, which I believe are partly matters of detail and partly groundless, will see the advantage of union and will join the amalgamation.

I look upon this union of medical societies as a step towards a union of far greater importance, viz., the union of the Royal College of Physicians and the Royal College of Surgeons of England, which was advocated by the late Sir John Burdon Sanderson. These are the bodies which ought to be at the head of a Royal Academy of Medicine and Surgery. They have already co-operated in undertaking a conjoint examination. I can see no reason why they should not completely unite. What a library, what a museum should we then have! A new building would be required in a central part of London, with library, museum, laboratories, and meeting-room. At present the Royal College of Surgeons' Library and Museum is too far away to be used as its importance deserves.

While waiting for this "consummation devoutly to be wished," we have accepted the instalment of concentration

of work involved in the union of the Obstetrical Society of London with the British Gynæcological Society. The amalgamation of the two societies is a subject for congratulation in the interest of obstetrics and gynæcology. For it was clearly an anomaly that there should exist two societies in London both dealing with the same subjects; and although the Obstetrical Society is bringing into the amalgamation scheme a sum of over £4000 and a splendid Library, which will be shared by the present Fellows of the Gynæcological Society, this is but a small price to pay for the advantages of union, which is strength. For in works for the advantage of humanity there should be no rivalry in doing, but rivalry in doing good—"certare ingenio, contendere nobilitate." This, the only rivalry which is worthy of our profession, will be carried on under the ægis of the Obstetrical and Gynæcological Section of the new Society with an increased advantage from the circumstance that all the serious British workers in Obstetrics and Gynæcology will be members of the section. I look forward to the future with the greatest confidence that the high aims which have always guided our Society will be continued, and the results of those aims will be increased by the additional workers who will be added under the new scheme.

One of the most necessary factors in successfully carrying on the business of our meetings is that the rules and customs of the Society should be conformed to, and it will be my endeavour as President to keep this point before you.

By way of illustration, one of the rules which is apt to be encroached upon is that which puts a limit of half an hour to the time during which specimens may be shown and short communications read; a second, which is sometimes disregarded, is that accounts of specimens exhibited may not be read, notes only being used to refresh the memory; another, that a "short communication" must not occupy more than ten minutes in reading, and must be deposited with the secretaries at least a week before

the meeting. There is, however, no need for a short communication to take up so long a time as ten minutes, and the shorter these communications are the more time is left for the exhibition of specimens, which often form the most interesting part of the evening's work. I would ask Fellows to let their communications and their papers be as concise as possible.

The last two volumes of 'Transactions,' printed on lighter and bulkier paper, are thicker than the previous volumes, and the question will soon arise whether we should not enlarge the size of the volume; but in the meantime the conciseness in the papers, for which I have appealed, would save some time for the meeting and improve the appearance of the volume, and, I think, the papers too.

It has been the custom, though I believe there is no rule on the point, to announce the names of donors of books with the titles of the books at the beginning of each meeting. As books written in many languages are presented to the Society, the announcement of their titles may make a great demand on the linguistic faculty of the honorary secretaries and on the time of the Society. Probably most of the Fellows would derive more pleasure and instruction from the exhibition of another specimen than from the announcement of the titles of the gifts. I purpose, therefore, omitting the titles while reading out the names of the donors—*pour encourager les autres*—and sending round the meeting-room the type-written names of the donors and the titles. We shall thus, I think, gain a little more time for the exhibition of specimens.

The Obstetrical Society has been distinguished in the past for the large amount and high quality of the work it has done in Obstetrics and Gynæcology and there is an assurance that this high standard will be maintained in the excellent work done by so many of its younger Fellows, which forms the best evidence of a Society's vitality.

I am happy in having to assist me two secretaries who

have enriched our 'Transactions' by excellent papers. Both of them were my fellow-students and fellow-workers twenty-eight years ago, and they remain fellow-students and fellow-workers still. With their help and your kind indulgence I hope to be able to carry out the duties of the position which this Society has conferred upon me.

Dr. CHAMPNEYS, in moving "that the best thanks of the Society be given to Dr. Spencer for his interesting address, and that he be asked to allow it to be published in the next volume of 'Transactions,'" said that the Society was fortunate in having, during the period of transition, and as last President of the Obstetrical Society, a gentleman who had shown so much public spirit in its affairs, and who had so abundantly identified himself with its best work and interests. He believed that the work in connection with the transition was proceeding well, and felt sure that the Society would be safe in its President's hands.

APRIL 3RD, 1907.

HERBERT R. SPENCER, M.D., President, in the Chair.

Present—42 Fellows and 1 visitor.

A Report was presented by the Hospital Staff of the Madras Government Maternity Hospital.

James Montague Wyatt, M.R.C.S., L.R.C.P.Lond.; Archibald Montague Gray, M.D., B.S.Lond.; Clifford White, M.D., B.S.Lond.; and Herman Stedman, M.D. Cincinnati, F.R.C.S.Ed., were admitted Fellows of the Society.

The following candidates were proposed for election: John Prescott Hedley, M.B., B.C.Cantab.; William Gordon Speers, M.R.C.S., L.R.C.P.Lond. (São Paulo, Brazil).

The Report of the Council was read as follows; and, on the motion of Dr. HERMAN, seconded by Dr. AMAND ROUTH, No. 1 was adopted, while No. 2 was put from the Chair and adopted.

REPORT OF THE COUNCIL.

AN extraordinary meeting of the Council was held on March 18th, 1907. The PRESIDENT (Dr. Herbert R. Spencer) in the Chair.

The minutes of the last meeting were read and confirmed.

The Report of the Finance Committee (see Finance Committee minute book) was read and considered.

(1) On the motion of Dr. CULLINGWORTH, seconded by Dr. EASTES, it was decided to give an honorarium to Miss Hannam of £300 (three hundred pounds).

It was decided, on the motion of Dr. CHAMPNEYS, seconded by Dr. HANDFIELD-JONES, to give a gratuity of £25 (twenty-five pounds) to Tatlock; and, on the motion of Dr. CHAMPNEYS, seconded by Dr. HUBERT ROBERTS, to give a gratuity of £5 (five pounds) to Tapson.

It was decided, on the motion of Dr. CHAMPNEYS, seconded by Dr. CULLINGWORTH, to inform the Amalgamation Committee, in reply to its letter, that the Society had recognised the past services of Miss Hannam, Tatlock, and Tapson by granting the above-mentioned sums.

(2) The following twenty Fellows were nominated to serve with an equal number of Fellows of the Gynæcological Society on the Council of the Obstetrical and Gynæcological Section of the Royal Society of Medicine: Herbert R. Spencer, M.D.; Montagu Handfield-Jones, M.D.; John Phillips, M.D.; Robert Boxall, M.D.; Arthur H. N. Lewers, M.D.; William John Gow, M.D.; Francis Henry Champneys, M.D.; George Ernest Herman, M.B.; William R. Dakin, M.D.; Henry Russell Andrews, M.D.; Henry Briggs, M.B., F.R.C.S. (Liverpool); Charles James Cullingworth, M.D.; George Eastes, M.B., F.R.C.S.; John Shields Fairbairn, M.B.; John M. Munro Kerr, M.B., C.M. (Glasgow); Cuthbert Lockyer, M.D.; Amand Routh, M.D.; Mary Ann Dacomb Scharlieb, M.D.; Herbert Williamson, M.B.; Thomas Wilson, M.D. (Birmingham).

Report of the Pathology Committee on Mr. G. F. Darwall Smith's Specimen of Perithelioma of the Uterus (*see p. 97*).

WE have examined the specimen and the microscopic sections taken from it, and agree that it is a type of

sarcoma, best described as perithelioma, for reasons given by the exhibitor.

(*Signed*) H. T. Hicks.
Cuthbert Lockyer.
C. Nepean Longridge.
C. Hubert Roberts.
G. F. Darwall Smith.
Corrie Keep.
W. S. A. Griffith, *Chairman.*

SUPPOSED SARCOMA OF THE CERVIX.

Shown by Dr. Henry Russell Andrews.

L. C—, aged 35, came to the Out-Patient Department at the London Hospital three weeks ago. She had had three children and one miscarriage. For four months she had had an offensive vaginal discharge, with occasional bleeding. For two months she had noticed something coming down the front passage. For two weeks she had had pain and constant bleeding. Ten years ago she had a polypus, of the size of a fist, removed in the north of England.

The patient was very anæmic. On examination, a long, sloughing, polypoid mass was found hanging from the cervix. It seemed to be a greatly elongated anterior lip. Behind this projecting polypus could be felt a rough, rather friable mass, apparently the posterior lip. I did not know at all what the condition was. I admitted her under the care of Dr. Lewers. As he had an unusually long list of operations on his next hospital day, he asked me to carry out the treatment of this case.

Under an anæsthetic it was found that the anterior lip of the cervix was occupied by a large growth quite as large as a fist. It was a firm, bluish-red, rather sloughy

mass, which was broken up in a peculiar way into lobules. One long tongue of tissue, covered anteriorly by squamous epithelium, lay in front of the main mass. The posterior lip, which could now be felt for the first time very high up, appeared to be normal. I thought that the growth must be a sarcoma.

Abdominal hysterectomy seemed to be out of the question, as the growth was septic, so I proceeded to perform vaginal hysterectomy. The operation was laborious and difficult, because it was impossible to open Douglas' pouch from below, as the vagina was filled tightly by the growth. For the same reason the original ligatures had to be applied close to the uterus; later, I was able to remove a good deal of the tissue of the broad ligament on each side. A para-vaginal incision was made. After working up gradually on each side, I got the fundus out and then split the uterus antero-posteriorly, and opened Douglas' pouch from above. I did not close the peritoneal cavity completely, as the growth was septic. The patient has made a good recovery, and is now (two and a half weeks after the operation) convalescent. The specimen shows the body of the uterus unaltered, except that it contains a small, hard, round fibroid in its posterior wall. I have not had any sections cut from this fibroid. The posterior lip of the cervix is healthy. From the anterior and lateral parts of the cervix springs a large, bluish-red, lobulated growth of peculiar appearance.

Microscopical sections show, I think, that the growth is a sarcoma. In some parts the tumour is very fibrous, but there are an extraordinary number of vessels. Dr. William Bulloch, who kindly examined the sections, is of opinion that the growth is a spindle-celled angeiosarcoma of high malignancy. I hope that the specimen will be referred to the Pathology Committee, as there may be a good deal of difference of opinion as to the nature of the growth, at any rate at first.

The specimen was referred to the Pathology Committee (*see p.* 169).

The PRESIDENT thought, from a short examination of the slides, that the specimen was a degenerated myoma. He had not seen any large or multinucleated cells to which he was inclined to attach importance in the diagnosis of sarcoma of the uterus. The vessels appeared to be somewhat numerous, but not more so than was sometimes observed in congested fibroids. It was, however, clearly a case for the careful study of the Pathology Committee.

Dr. CUTHBERT LOCKYER said he must disagree with Dr. Russell Andrews and Dr. Williamson in their opinion that the case was one of sarcoma. Dr. Lockyer regarded it as a fibromyoma, blood-supply of which had undergone obstruction in the process of extrusion. The stasis would fully account for the free interstitial hæmorrhage and for the leucocytic infiltration; both phenomena were most marked at the periphery of the growth, and, in the speaker's opinion, sections taken at or near the attachment of the uterus would give a more satisfactory picture of the true nature of the growth. Dr. Lockyer had seen the condition shown in Dr. Russell Andrews' specimen in many cases of polypi undergoing the process of extrusion, and had always attributed them to the combined effects of strangulation and inflammatory reaction. In all these cases the blood-vessels are seen to be fully formed, each vascular coat being represented, whilst in sarcoma delicate embryonic blood-spaces abound. Dr. Lockyer, at Dr. Russell Andrews' request, undertook to cut further sections of the growth for the purpose of submitting them to the Pathology Committee.

FIBROMYOMATOUS UTERUS WITH A CALCIFIED FIBROID LYING FREE IN ITS CAVITY.

Shown by Dr. DAUBER.

THE patient, Mrs. L—, aged 64, was sent up to the Hospital for Women, Soho, by Dr. North, of New Southgate, suffering from a tumour in the abdomen, together with a copious offensive vaginal discharge, which contained, occasionally—according to the patient's statements —"small pieces of bone."

On examination, the pelvis and abdomen, to three or four inches above the pubes, were occupied by a hard, irregular swelling. There was an intensely foul-smelling

and very copious discharge from the vagina. The patient stated that she had suffered from the tumour for thirty-two years, but had never had the courage to submit to operation. She was induced, with difficulty, to enter the hospital.

On February 21st, 1907, Dr. Dauber operated, assisted by Dr. Graham, the Resident Medical Officer. A median incision was made from the pubes to two inches above the umbilicus, passing to the right of it. The tumour was lobulated, being composed of many fibroids, and the bladder was firmly adherent to the anterior surface of it, to some three or four inches above the pubes. It was separated with some difficulty, the broad ligaments were rapidly clamped, divided, and dissected down until the uterine arteries were reached, which, as soon as seen, were ligated and the stump divided about an inch above the external os. No pus was spilt. The cervical canal was swabbed out with pure carbolic acid, and the stump sewn over with continuous silk in the usual way, the broad ligaments being closed similarly. Both ovaries and tubes were removed as they were intimately connected with the tumour. The abdomen was closed in three layers of continuous silk. The operation lasted thirty-five minutes. Recovery was uninterrupted and complete.

Directly after operation it was found that the vagina was full of pus and that a considerable quantity had escaped during the operation. Presumably the handling of the tumour had squeezed the pus from the uterine cavity into the vagina. A vaginal douche was immediately given, and the contaminated skin cleansed. Dr. Dauber took occasion to remark that he thought this case was one in which subtotal was preferable to pan-hysterectomy, as it would have been difficult, perhaps, to obviate soiling of the peritoneum in the latter operation in view of the pus in the vagina, whereas in subtotal hysterectomy this was easily effected.

On opening the uterine cavity a completely calcified fibroid, about as large as a hen's egg, was found lying loose within it, evidently a pedunculated sub-mucous

fibroid of long standing, which had become impregnated with calcareous salts in the course of long years, and then had become detached, owing to its weight, twisting of its pedicle or other accident.

This was a very rare condition, and the case was shown both on account of its rarity and as a further illustration, if that were needed, of the futility of waiting for the menopause in cases of fibroid disease, which, far from being a panacea, was not infrequently the starting point of degenerative or other dangerous changes.

The specimen was referred to the Pathology Committee.

Dr. Lockyer regretted that no microscopical slides were forthcoming. A doubt had been raised as to whether the cavity in which the loose calcified body lay was really the cavum uteri. Dr. Lockyer had no doubt that it was the cavity of the uterus, as he fancied he could see an edge of mucous membrane still left, but inasmuch as the canal of the cervix had not been opened up before the specimen was hardened the only way to settle the question was to make a section of the wall of the cavity in which the calcified fibroid lay.

The President said it would be interesting if the calcified fibroid were found to be lying free in the uterine cavity; he had not seen, nor did he remember to have read of, a calcified tumour in this situation.

In reply, Dr. Dauber still considered subtotal hysterectomy in this case the preferable operation, as, the vaginal outlet being small owing to senility, time would have been occupied in sewing up the cervix, in the cleansing of the operator's hands, changing gloves, etc., between the vaginal and abdominal operations, and time was an important consideration in his opinion.

BILATERAL PRIMARY TUBERCULOUS SALPINGITIS WITH SECONDARY INFECTION OF THE PERIVASCULAR LYMPHATICS OF THE UTERINE WALL.

(With Plates XI and XII.)

Shown by Dr. Cuthbert Lockyer.

The patient (M. G—) was seen in consultation with Mr. Sydney Wareham, F.R.C.S., on November 23rd, 1906.

Her age was twenty years. She gave the following history: In May, 1906, she had chickenpox, and during convalescence was seized with acute pain in the right groin, *i. e.* above Poupart's ligament. This lasted for three weeks. In July, 1906, the patient was again confined to her bed with the same symptoms—severe pain in the right iliac region. In October, 1906, she was laid up for twenty-eight days, this time with pain in the left iliac fossa, which soon became diffuse, radiating all over the pelvic area and round to the sacrum. A swelling was now detected for the first time; it lay just above Poupart's ligament on the left side. Mr. Wareham had previously attended the patient in 1905 for acute rheumatism. The attack lasted from July to September; the joints involved were both knees, ankles, wrists, and elbows. After the rheumatism, a period of three months' amenorrhœa set in, and a yellow vaginal discharge started which has continued ever since. After the three months' amenorrhœa, the periods returned very gradually to the usual type of five or six days' loss every month. The menstrual habit was established at the age of thirteen years; the flow was always free, three towels being used daily; there had been no dysmenorrhœa.

The family history was important, the father, who was a miller, died of phthisis, and there was consumption in the maternal grandmother's family.

The patient herself had lost weight considerably during her recent illnesses; she was of the "pretty struma" type with long eyelashes and tapering fingers. The heart was normal. A few adventitious crepitations were occasionally heard (after admission) at the right pulmonary base in the axillary line, otherwise the lungs were normal. The patient complained of flatulent dyspepsia. *Per abdomen*: both iliac regions were very tender on palpation, but the abdomen moved well on respiration. No tumour was felt on the right side, but on the left there was a semi-fluctuating swelling visible to ordinary inspection just above Poupart's ligament. This swelling was nodular,

DESCRIPTION OF PLATE XI,

Illustrating Dr. Cuthbert Lockyer's specimen of Bilateral Primary Tuberculous Salpingitis with Secondary Infection of the Perivascular Lymphatics of the Uterine Wall.

Uterus opened from behind. A, B, C, Sites of microscopical sections.

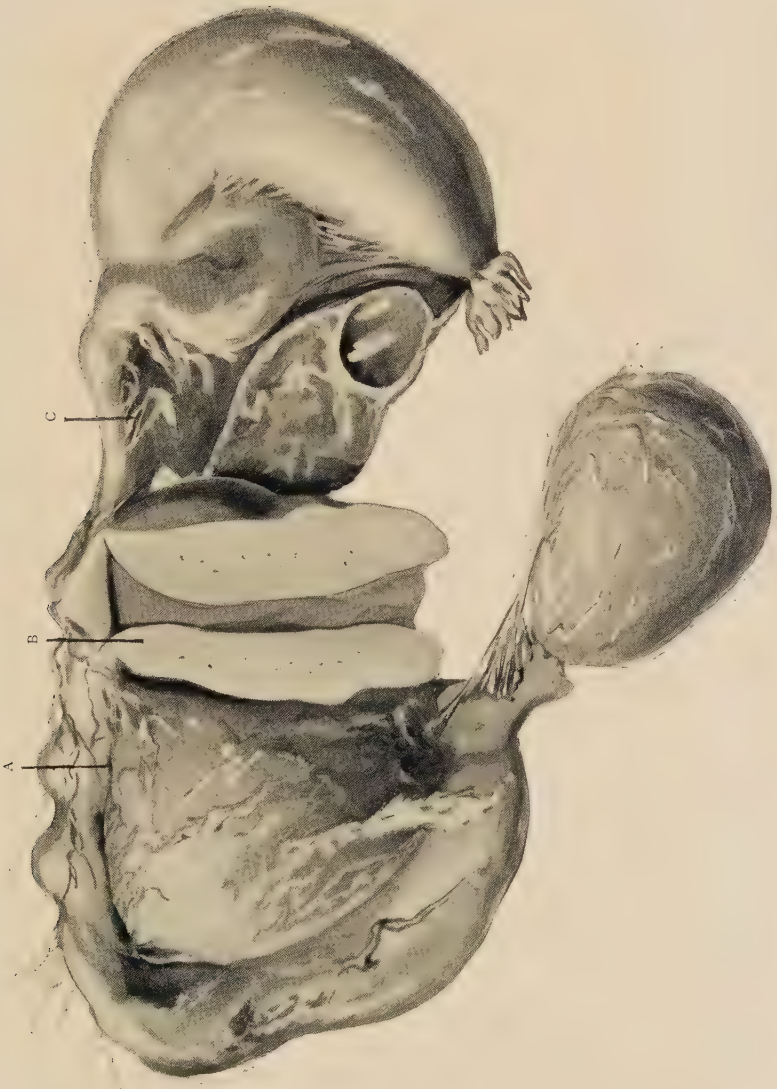

Illustrating Dr. Cuthbert Lockyer's specimen of Bilateral Primary Tuberculous Salpingitis with Secondary Infection of the Perivascular Lymphatics of the Uterine Wall.

Adlard & Son, Impr.

DESCRIPTION OF PLATE XII,

Illustrating Dr. Cuthbert Lockyer's specimen of Bilateral Primary Tuberculous Salpingitis with Secondary Infection of the Perivascular Lymphatics of the Uterine Wall.

Section taken through B (Plate XI), showing tubercular systems in uterine wall.

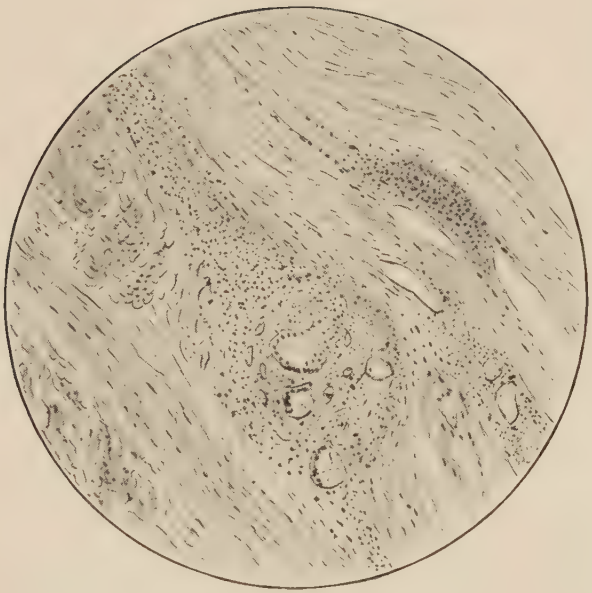

Illu strating Dr. Cuthbert Lockyer's specimen of Bilateral Primary Tuberculous Salpingitis with Secondary Infection of the Perivascular Lymphatics of the Uterine Wall.

Adlard & Son, Impr.

and the visible knuckle of the same felt as if it were immediately underneath the skin. *Per vaginam* the os uteri was drawn high up and fixed. In the left fornix a hard, tortuous, worm-like mass continuous with the nodule visible above Poupart's ligament was easily made out. From the physical signs and the family history the diagnosis of tuberculous salpingitis was made.

The abdomen was opened on November 29th, 1906. The patient was placed in the high pelvic posture. A mesial four-inch incision was made right down to the symphysis, and on opening the peritoneum a very flaccid transparent cyst appeared amongst the intestines, to which it was anchored by filmy adhesions. This proved to be an inflammatory serous cyst, and looked like a flabby tentacled medusa. It broke in spite of delicate handling. It was eventually traced to another cyst of similar character attached to the back of the left broad ligament, thereby obscuring the ovary of that side from view. The left tube was nodular, dilated, and tortuous; it ran around the serous cyst seen on the back of the left broad ligament like a chaplet. The uterus was small, but very adherent by filmy inflammatory bands to all adjacent structures. As the right tube was already transformed into a huge pyosalpinx of the ordinary banana shape, it was decided to clear out all the pelvic genitalia *en masse*, and fearing that the uterus might be involved in a tuberculous process it was removed entire together with the complete adnexa. The abdomen was sewn up in three layers, and a collodion swab applied to the wound. Mr. Wareham and Dr. Pearson (the senior house surgeon) acted as assistants. The operation, which took forty-four minutes to complete, was well borne by the patient, and the recovery was afebrile and uneventful. Mr. Wareham reports that he is giving the patient ovarian extract for menopastic disturbance, but otherwise her health is good, there being no sign of further tuberculous trouble so far—*i. e.* four and a half months after the operation.

The interest of this case lies in its histology. In the

year 1899 Mr. Targett showed a case of double tuberculous pyosalpinx, in which he pointed out that the typical thin-walled elongated sacs, although containing cretaceous deposit, caseous material, or inspissated pus, may show no histological evidence of tuberculous disease, but that if the uterine ends of the tubes be examined, tuberculous foci will be discovered. The cornual attachment of a pyosalpinx has since that date been the site of election in my routine histological examinations. In the present case I have examined three sections of the tubes and two of the uterus. Of the tubal sections one is taken through the proximal caseous nodule of the left tube, one through the cornual attachment of the same tube, whilst the third is taken from the undilated portion of the right tube. In the thinned-out tube wall investing the caseous nodule there are no giant-celled systems; they have given place to fibrosis; their former position is indicated by oval areas of early fibrosis which still include a few epithelioid cells—not enough evidence of tubercle to convince a sceptical tyro. In the section of the left tube, at its fusion with uterine muscle, beautiful giant-celled systems become evident, whilst in the adjacent uterine muscle the spread of the disease is most clearly shown as a round-celled infiltration in the lymphatics amidst the muscle-bundles breaking forth into a typical giant-celled system as soon as a larger perivascular lymphatic is reached. A section taken through the endometrium and adjacent muscular strata reveals nothing abnormal beyond a somewhat hyperplastic and hypertrophical mucous membrane. The narrow part of the right tube, one inch from the cornu, reveals no definite tuberculous foci. (Incidentally the uterine muscle from the region of the left cornu shows the remains of the Wolffian tubules.) Now this specimen is a most complete vindication of Mr. Targett's word of warning expressed at the Obstetrical Society eight years ago, viz. that for accurate diagnosis we must examine the uterine ends of the tubes in tuberculous pyosalpinx. Moreover, as regards secondary infection of

the uterus it shows an absolute analogy to the spread of cancer from ovaries to uterus. I have already shown ('Obstet. Soc. Trans.,' vol. xlvi, pp. 302, 305, 1904, Dr. Maurice's specimen) that in the case of malignant ovaries the cancer cells reach the uterus *viâ* the perivascular lymphatics of the Fallopian tubes, and this is the course taken in secondary tuberculous disease of the uterus.

Interesting as these findings are, the clinical lesson they teach is entirely lost if we fail to see in them a clear indication for hysterectomy in advanced cases of double tuberculous salpingitis. This was the plea I urged in 1904, when writing on the subject of "carcinoma in the muscular wall of the uterus secondary to cancer of both ovaries," and the same teaching is equally applicable here where we are dealing with an advanced and spreading tuberculous process instead of cancer. Personally I go further and often adopt the practice of removing the entire genitalia (total hysterectomy) for double gonorrhœal or puerperal pyosalpinx and double ovarian abscess. The uterus in such cases is often a useless or even dangerous organ, and, moreover, is so adherent to the disorganised appendages as to make its retention a difficult and unsatisfactory procedure. The advantages of free vaginal drainage after its removal is another strong inducement to carry out the radical measure which I am here advocating.

The PRESIDENT thought that the results of removal of tubercular tubes alone, without the uterus, were too good to warrant the removal of the uterus in all cases. He mentioned two cases, in one of which removal of the tubes was followed by complete recovery, although the patient had tubercular disease of the spinal column at the time of the operation, five years ago; in the other, apparently complete cure of a case of tubercle of the body of the uterus had followed curetting followed by the application of iodine and iodoform.

Mr. MALCOLM thought that possibly Dr. Lockyer had not really meant that in every case of operation for removal of tubercular ovaries or Fallopian tubes the uterus also should be taken away. The speaker had adopted this course on occasions,

however, and he believed that it was the best treatment in selected cases.

Dr. Eden said that he considered that the operation Dr. Lockyer had performed was quite right in this particular case. He was not, however, prepared to admit that complete extirpation of the uterus and its appendages was necessary in all cases of double tuberculous salpingitis. He thought the most important point was the condition, not of the tubes, but of the ovaries. If both ovaries were completely disorganised the complete operation practised by Dr. Lockyer was no doubt advisable; the uterus was, in all probability, functionally useless without the ovaries; its removal did not seriously increase the severity of the operation, while if it were left an active focus of disease might possibly be left with it. If, however, it were possible to conserve even a portion of one of the ovaries with the uterus, he thought it was most important to do so, especially in young women.

Mr. Alban Doran considered that it was dangerous to leave a ligatured bunch of tuberculous tissue on each corner of the uterus. He had known of bad, or even fatal results often delayed until months after the operation. On that account amputation of the uterus, as well as the tuberculous appendages, was advisable. We must remember the element of luck always associated with tuberculous disease involving the peritoneum. One bad case might recover after extensive removal of ovaries, tubes, and other structures, whilst another, apparently milder, might die after simple opening of the peritoneal cavity. Therefore it was best to be on the safe side, and not to leave pedicles of tuberculous appendages when it was clearly safer to amputate the uterus.

Dr. Lockyer, in reply, thanked the Fellows of the Society for so kindly and fully discussing his case. He would like to point out that there was no question of tuberculosis of the endometrium; the uterine disease was a secondary infection of the muscular wall due to the spread of tubercle along the lymphatics. Such a lesion would not be benefited by curettage. Dr. Lockyer quite agreed that hysterectomy would not be indicated for *early* tuberculosis of the Fallopian tubes; he intended his remarks to apply to advanced cases, such as the one under discussion, where all the pelvic organs were matted together, including the ovaries, which, moreover, were quite disorganised.

CASE OF ENTIRE FULL-TIME OVUM IN TWINS.

By Dr. Robert Wise.

Dr. Robert Wise showed, from a case of *full*-time live twins, the second ovisac with two placentæ in its walls, the second ovum having been born *entire*, the cord to the first and lower child passing from the edge of the lower placenta in the wall of the second ovum. Both twins are alive and full-time.

ON THE ADVISABILITY OF REMOVING THE CERVIX IN PERFORMING HYSTERECTOMY FOR FIBROMYOMATOUS UTERINE TUMOURS.

BY

JOHN D. MALCOLM, F.R.C.S.Edin.,

SURGEON TO THE SAMARITAN FREE HOSPITAL.

(*Abstract.*)

IT is pointed out that after a partial hysterectomy the cervix uteri, with its blood supply to some extent cut off and with its narrow central tube lined by mucous membrane which may be chronically inflamed, offers a favourable nidus for the development of pathogenic micro-organisms in the divided uterine tissue, whilst the provision for drainage of discharges is imperfect.

Two cases are recorded in which local signs of insidious septic change in the cervix uteri were accompanied by evidences of irritation elsewhere, one patient suffering very severely from phlegmasia dolens and the other from a painful œdematous swelling in the side and in the joints. Both recovered. Notes of a third case are given, in which, after a partial operation by another surgeon, the cervix was found actively inflamed with a fairly copious muco-purulent discharge from the os and giving rise to much irritation of the lower bowel.

A note of all the author's fatal cases of hysterectomy is given. Excluding malignant cases (two deaths), those treated by the old-fashioned serre-nœud (eight cases, of which six are already published in detail) and one of enucleation of a fibroid, there remain six deaths. In two of these, large fibroids so involved the cervix that the greater part of it was necessarily removed; in one the normal uterus was partially removed, and in one it was

completely removed because in each case it was so incorporated with an ovarian tumour deeply buried in the broad ligament that its removal was easier than leaving it. These four cases died within forty-eight hours of the operations from the severity of the necessary procedures. In two other cases of pan-hysterectomy death was due to lung complications. It is held that these cases, although in five of the six the whole uterus was removed, offer no guidance to treatment on the main question raised in the paper.

The effects of the various methods on the symptoms of the artificially induced menopause are also regarded as not giving very satisfactory indications for treatment,—excellent results having been obtained by all methods.

The removal of the cervix is urged on the theoretical consideration that leaving it gives an increased opportunity for the development of septic mischief, and because of the belief that in practice the convalescence is smoother by this method.

It is therefore recommended that in performing hysterectomy the cervix should be removed, that before operating the patient's health should be made as good as possible, and that no woman should be advised to retain a uterine tumour of any considerable size, or which has become definitely prejudicial to her health.

These are the points to be attended to with a view to improving the results of this, which is already one of our most successful operations.

A little over twenty years ago the death-rate from the removal of fibroid tumours of the uterus was decidedly high, but from various causes the mortality has rapidly diminished, and now a hysterectomy is almost, if not quite, as safe as an ovariotomy.

Whether it is wiser to remove the cervix or to leave it is, however, still an open question, and I therefore wish to publish the following notes, which seem to me to support the view that the complete operation is the better, the more scientific, and the safer.

When the cervix is not removed the broad ligaments are divided, the ovarian and uterine vessels are ligatured, and the uterus is cut away about the level of the inner os,

so as to leave anterior and posterior flaps of its tissue, which are brought together and secured in apposition by sutures. The peritoneal edges are then adjusted so as to cover over all the raw surfaces.

Every precaution must, of course, be taken to prevent septic infection, and it is obvious that a special danger of contamination exists at the point of section of the uterus.

Careful attention must also be paid to the arrest of hæmorrhage, which is sometimes by no means easy, because, if myomatous growths involve the lower part of the uterus or the cervix, the vessels are often not only enlarged, but numerous and erratic in distribution.

The difficulties of preventing a contamination of the area of operation by the contents of the genital tract do not vary much whether the cervix is left or taken away. But when the cervix is left, even if the raw surfaces are perfectly cleaned, if all parts are properly adjusted, and if hæmorrhage is satisfactorily arrested, the conditions after the operation is finished are, in theory, particularly unfavourable for healing.

The cervix consists of firm tissue, and the proper securing of the vessels diminishes the supply of blood to it. So much may this be the case that I know of an instance in which the cervix sloughed. Fortunately it separated without doing any harm. In the centre of the cervix, the nourishment of which is thus interfered with, there is a tube of mucous membrane containing many glands, which are not infrequently in a state of chronic inflammation, and no practicable method of cleansing can be relied upon to make such a membrane sterile. Moreover, its cut surface is necessarily left in contact with the raw uterine tissue, and the narrowness of the tube interferes with the escape of discharges. It is obvious that this arrangement must be favourable to the development of noxious organisms in the injured parts and thus constitutes a source of danger.

Although supra-cervical hysterectomy has proved undoubtedly a very successful procedure, the dangers which

I have pointed out must exist so long as the method is adopted, and the following cases, although the patients completely recovered, show that the risks directly due to the method should not be neglected.

In the first case the patient was a nulliparous married woman, aged 40, who had a soft fibromyoma of the uterus rising nearly to the umbilicus. It had been known to exist for two years and had brought about a condition of extreme anæmia by the profuse hæmorrhages which accompanied its development. The patient had suffered from a feverish illness attributed to tuberculosis of the bases of both lungs in 1894, but she appeared to have recovered completely and to be in all other respects healthy. The tumour and the body of the uterus were removed at the Samaritan Free Hospital on June 23rd, 1903, the cervix being left, and there seemed to be no reason to expect other than a good convalescence when the patient was put back to bed. The abdominal incision never showed any sign of irritation and there was no evidence of peritoneal mischief at any time. Nevertheless, the patient had the most severe and prolonged attack of phlegmasia dolens that I have seen. From the first the temperature was high. On the fifth day there was pain at the base of the right lung, and, on auscultation, friction sounds were detected both before and behind the seat of pain. No râles or evidences of mischief within the lung were detected, and the signs of irritation of the pleura ceased after about a week.

On the ninth and tenth days the temperature was above 104° F. for seventeen consecutive hours, rising as high as 106·2° F. The patient was then delirious and obviously very ill, but the highest pulse was 126. The temperature fell from 106·2° to 101° F. in seven hours. There was no immediate explanation of the rapid fall, but about a week later there was a slight escape from the vagina of thick white matter, which ceased after a few hours. When an examination was made there was always some fulness and tenderness of the cervix. No swelling was

felt at any time beyond or beside the cervix, and no appreciable discharge was noted except on the occasion mentioned.

It was not until shortly after the pleural irritation subsided and the temperature moderated that any sign of mischief developed in the legs. First one and then the other calf became swollen and painful, and then apparently recovered. With, and following, these manifestations there was a prolonged period of febrile temperature.

Eleven weeks after the operation the patient again became very ill, the temperature rising nearly to 106° F. This was followed by an enormous swelling and much pain in the feet, legs, and thighs, the two sides being about equally affected. There was then some evidence of rectal and bladder irritation, but these symptoms only lasted a few days.

At this time 10 c.c. of antistreptococcic serum were injected subcutaneously without any very obvious effect. A few days later there was a slight general improvement, just as there had been before, and this marked the end of the last acute exacerbation. The temperature remained above normal, however, and variable, whilst the pain and swelling subsided only very gradually, and it was not until nineteen weeks after the operation that the patient left the hospital.

In the summer of 1906 she looked exceedingly healthy and said she could walk six miles without being tired. There was still some tendency to swelling of the legs, which was checked by means of elastic stockings. The patient has recently developed tumours in other parts of the body—a lipoma and a sarcoma apparently involving three costal cartilages—but her further history has no bearing on the subject under discussion. The uterine tumour was not examined microscopically. I had no suspicion that it was other than a simple fibromyoma.

It is, perhaps, important to state that in this case the operation was performed during a week of excessively hot and close weather. I was informed that about the same

time, both in the Samaritan Free and in other London hospitals, there had been cases of very high temperature without any obvious cause, and that in one instance death took place with an unexplained hyperpyrexia a few days after a hysterectomy.

If my patient had died from a slightly greater absorption within three or four days of the operation, I think that very little evidence of mischief would have been found at a *post-mortem* examination, and there might have been no satisfactory explanation of the cause of death.

The pleurisy, the phlegmasia, the tenderness around the cervix, and the absence of any signs of mischief within the peritoneal cavity or in the abdominal incision all pointed, however, to the existence of an insidious form of septic mischief beginning in the uterine stump.

In another case the pathological changes were very similar.

The operation was undertaken on account of a fibromyoma uteri causing persistent hæmorrhages in a patient aged 42. Only the supra-cervical parts were removed, and at first there was no unusual symptom, the bowels being evacuated after two days. The temperature on the third day, instead of falling, rose to 102·2° F., and continued at about the latter level. Nothing, except that the cervix was somewhat swollen, was discovered to account for the prolonged fever until the eighth day, when there was a little purulent discharge from the vagina. Its escape was preceded by a further rise of temperature to 103·4° F., and immediately afterwards there was a rapid fall of three degrees. The pulse-rate kept comparatively at a lower level than the temperature, the highest record being 96.

The escape of pus was followed almost at once by a slight loss of bright red blood. The hæmorrhage continued for four days, and then there was again a discharge of yellow matter, which gradually ceased. Except that the temperature continued to fluctuate, the patient seemed

fairly well, and the pulse did not rise above 96. On the tenth day, when the hæmorrhage had begun, 10 c.c. of anti-streptococcic serum were injected. This treatment did not seem to have any useful effect. The cervix became less swollen, but a steady escape of blood was taking place.

On the eighteenth day the temperature rose to 105° F., the highest pulse-rate at this time being 100. The patient had for some days complained of severe and increasing pain over the liver in the mid-axillary line, and there was considerable œdema of the subcutaneous tissues at the seat of pain. As the patient lay on her back the centre of this swelling was about five inches below the completely healed puncture-wound caused by injecting the serum. The patient was put under an anæsthetic, and an examination showed that the cervix was quite mobile, the whole pelvic and abdominal contents seeming to be soft and normal. An incision three inches in length was made through the œdematous fat on the right side down to the fascia over the muscles, but I found no bulging or other sign of intra-abdominal mischief. I therefore closed the incision, and it healed by first intention. The pain ceased, the œdema disappeared, and the temperature fell to 99·6° F. two days later. On the third day, the twenty-first after the hysterectomy, the temperature again rose to 104·8° F., and this was accompanied by tenderness in many joints, particularly in the wrists and knees. Sodium salicylate was administered and after another three days the temperature was normal.

The vaginal discharge had ceased before this time, and there was no discovered cause for the amelioration of symptoms apart from the administration of the salicylate, but the improvement was permanent.

In this case it would almost appear that the treatment by injecting antistreptococcic serum might be held responsible for some of the unfavourable conditions which arose. This is important, for at present it is not certain when the method will prove beneficial, and in the fore-

going cases it was resorted to as being at least very unlikely to do harm. In administering it every care was taken to prevent septic contamination.

The history of this second case also strongly supports the view that mischief may arise from a form of septic infection spreading from the cervical canal. It seems certain that a small collection of blood was retained and became infected, the septic products partially escaped, then a vessel bled for a few days, and the parts healed by granulation.

Undoubtedly there was also a pathological process affecting tissues at a distance from the seat of operation, but there was not sufficient evidence to show whether this was due to an infection from the injured tissues, to an effect of the injection of serum, or to a constitutional disturbance of a rheumatic nature. There was no history of a previous rheumatic attack, although the patient had occasionally complained of pains in her joints.

A third case, in which I did not myself perform the operation, but which is instructive in connection with the subject under consideration, has recently come under my observation. The patient was brought to me by her medical attendant thirteen months after hysterectomy had been performed. She was aged 33. She was of a nervous constitution, and the symptoms of the artificially induced menopause—flushings, headaches, etc.—were severe. An additional trouble was a considerable discharge of mucus from the bowel, and I gathered that this had been regarded as the chief cause of the complaints which the patient had made since the operation. It may have been so, but the cervix had been left in the body, and was large, swollen, and tender. On inspection it was red and angry in appearance around the os, from which there was a considerable muco-purulent discharge, and this was said to be increasing in quantity. A sound was easily passed fully half an inch into the cervix, but I did not think it wise to insinuate it further.

It seemed to me that all the symptoms of the "change

of life" were exaggerated by the debility and irritation induced by the cervical condition. A catarrh of the rectum with a profuse discharge, and sometimes with mucous casts of the intestine, is not an uncommon result of an inflammation affecting some part of the genital tract, and it is highly probable that the state of the bowel and the vaginal discharge in the case under consideration were directly due to the presence of the inflamed cervix, and that both would have been avoided if a complete hysterectomy had been performed. I thought that possibly a ligature was becoming loose and would be discharged, and therefore palliative treatment was recommended for the time, but in such a case the question of removing the cervix by a second operation might have to be considered, and conditions directed to the state of the intestine could not, I think, prove better than palliative until the inflammation in the cervical stump subsided. I understand that the immediate convalescence in this case gave rise to no anxiety.

Although such conditions as those above recorded are, I believe, rare, nevertheless there are cases, and I have already alluded to one, in which death follows a hysterectomy a few days after the operation without any cause being discovered, and such a fatal issue may be due to a sepsis arising by contamination from the contents of the cervix without any local change obvious to the naked eye being induced.

The causes of white leg and of painful œdematous conditions elsewhere as a consequence of an operation are very obscure. I have seen a phlegmasia dolens arising three weeks after a simple abdominal section, from which, in all other respects, the patient appeared to make a perfectly satisfactory convalescence. It is sometimes held that an extreme degree of anæmia, which existed in the first two cases above recorded, favours the onset of such complications, and it might be argued that the process is not always a septic one, although in many cases it obviously is so. There cannot, however, be any doubt that methods

which facilitate the healing of an intra-abdominal injury must tend to prevent the subsequent development of this and similar complications.

It may perhaps be held that the complete removal of the uterus only shifts the point of danger from the cervix to the vagina, and without doubt the vagina also offers opportunities for septic infection. Since the above was written I have met with a very mild case of phlegmasia dolens after a complete hysterectomy. The patient, whose age was 39, appeared to be making a satisfactory recovery, with the exception that the temperature during the first three weeks, although the highest point recorded was only 100·2° F., did not come down to normal in the evenings. There was no other adverse sign and I thought it well to get the patient up with a view to removing her to the country. Accordingly on the twenty-third day she began to move about. The temperature again rose to 100·2° F., but the abdominal condition seemed perfect, and there was no other indication of danger until the thirty-fifth day, when there was a slight painful swelling of the right leg. Two days later the temperature rose to 103·4° F., but within a week it was normal, morning and evening, and the swelling and pain were gone. After this the patient's progress was good, and I have recently heard that her condition is very satisfactory.

The history of this case favours the view that anæmia is an important predisposing cause of phlegmasia dolens, for before the operation the patient was of extremely unhealthy appearance. Six years earlier she had been told that she had a tumour, but that the state of her health was too bad to permit of operative treatment. In 1906 she came under the care of Mr. Wale, of Croydon, who sent her to me. I had no hesitation in advising her to take the risks of an operation as her prospects of improvement, without this treatment, seemed very remote. That, in such a case, everything did not progress with complete freedom from complications does not seem to me necessarily to indicate a fault in the method.

The chief disadvantages of the total operation as compared with the partial are that it generally takes longer to perform, and that the manipulation is more difficult. The greater time required may, however, be made up for, to some extent, by the fact that when the cervix is left a very exact arrest of all bleeding points should be obtained; whereas when it is removed if there be some oozing after the patient is put to bed the blood escapes easily, and it is therefore harmless. Indeed, unless the loss is dangerous from its quantity, a slight escape may be beneficial by reducing local tension and by washing away infective material.

The difficulties of manipulation are due to the great length which the cervix occasionally attains, and to the depth in the pelvis at which the surgeon may have to work.

It is sometimes easier to cut away the uterus as low down as possible, and then to seize the rest of the cervix with a volsella and to cut it out. Mr. Bland-Sutton recommends that only the mucous membrane and the parts around it should be removed, a shell of cervical tissue being left. By this plan many of the advantages of the complete operation may be obtained, the chief of these being the removal of the lining membrane of the cervical canal. Mr. Bland-Sutton's method has not, however, seemed to me easier of execution or more certain of securing a free escape of discharges than that by which there is a complete extirpation of the cervix. Moreover, when this part is much elongated, and I have seen it three inches in length, it must be very difficult to excise the central tube, and I think it must sometimes be almost impossible to be sure that the whole of the mucous membrane has been removed.

In considering the question as to the best method of performing an operation, the deaths immediately following the procedures under discussion may be important. Our President, in a former debate on this matter, quoted statistics showing that the mortality from hysterectomy

was less when the cervix was taken away than when it was left, the figures being 8·27 per cent. against 8·64 per cent.* My own mortality would compare favourably with either of these figures if I exclude cases operated on by the old-fashioned serre-nœud method. I cannot give exact details because, for a considerable period, I left the cervix or removed it, as I thought fit at the moment, and I find that I have not always been careful to state which method was employed in the cases that recovered. Statistics are, however, in my opinion, of no value unless very large numbers are involved, and even then they may be misleading. There are so many circumstances besides the surgical methods that may influence the death rate, and often there may also be a considerable range of legitimate difference of opinion regarding the placing of cases in a table. Moreover, bald figures may lead to false conclusions, and a consideration of the individual cases leads me to believe that my fatalities are of no value in connection with the particular point raised in this paper. I set aside cases operated on by the serre-nœud method, from which I had eight deaths, six of which have already been published in detail.† I also set aside two fatal cases in which malignant tumours were removed and in which it was, of course, right to take the cervix away if it was possible to do so. Besides these, I find only one fatality from the partial operation and five from total hysterectomy. Clearly, it might be argued from these figures that the incomplete operation should, at least, have a further trial, and might prove the more successful in my hands. Moreover, in the one fatality from the incomplete operation the body of the uterus was removed only

* 'Obstet. Soc. Trans.,' 1905, p. 403.

† "Some Complicated Cases of Abdominal Section," Case No. II, 'Lancet,' July 18th, 1891, p. 119; "Illustrations of Some Modes of Death after Ovariotomy," Cases Nos. IV and VI, 'Med.-Chir. Trans.,' 1895; "Twenty-six Cases in which an Abdominal Section has been Performed a Second Time," Cases Nos. XII, XXI, and XXII, 'Med. Soc. Trans.,' 1896.

because it was so closely incorporated with a deeply-buried ovarian tumour that it was easier to excise than to leave it. The patient died next day from the direct effects of the operation, the duration and severity of which would certainly not have been shortened by an attempt to separate the uterus. As there was no tumour in this case it might be ignored altogether, leaving my results from the incomplete operation for removal of fibroid tumours perfect so far as the mortality is concerned.

Of the five cases in which death followed a total hysterectomy one might be dismissed on the same grounds, namely, because there was no uterine tumour. The patient was suffering from septicæmia when I removed a large semi-solid ovarian cystoma, which was suppurating in several places and so deeply buried in the broad ligament that it was, again, easier to remove the uterus than to separate it. This patient also died the day after the operation.

In two cases in which there were large tumours, one a cervical fibroid, the other a tumour of the uterine body as big as a uterus in the seventh or eighth month of gestation, the cervix was so expanded that a pan-hysterectomy, or practically that operation, could not be avoided. Both patients died within forty-eight hours of the operation.

Another of these cases is interesting in connection with the probability that a septic infection may have arisen from the vaginal wound. The patient was aged 46, and I removed the whole uterus and both ovaries at the Samaritan Free Hospital in 1898. She had frequently suffered from bronchitis with expectoration, but immediately before the operation there was no sign of lung mischief, except a few crepitant râles in the left apex. After the operation the patient was very restless from the first, the pulse was above 120 for two days, and the temperature rose to 103·8° F. on the second evening.

There was no difficulty in getting the bowels to move, and no evidence of peritoneal mischief at any time. On

the fifth day the calf of the left leg was swollen and painful and the temperature rose to 104·4° F., whilst the pulse was 150. These unfavourable symptoms moderated, but on the sixth day the patient had a troublesome cough, and on the ninth expectoration was profuse. She took food well to the end and showed no signs of peritoneal mischief, but she gradually developed a general septicæmia, and died on the sixteenth day, the chest condition being certainly an important cause of the fatal issue. A *post-mortem* examination was not allowed.

Whether the character of the bronchitis was altered by an infection from the contents of the genital tract, similar to that which caused the temporary swelling in the leg, is perhaps an open question, but it seemed to me that this did occur.

In the last of these fatal cases death was also due to a lung complication. Much blood was lost in separating adhesions from which the hæmorrhage could not be arrested until the tumour had been released and removed from the pelvis. Several pints of normal saline solution were introduced into a vein with the most gratifying immediate results, but loud râles were heard all over the chest the same evening, and the patient died the next afternoon from acute bronchitis. She had not been subject to any lung trouble before the operation. I am inclined in this case to associate the transfusion with the fatal issue. The method is far too active to be unassociated with dangers of its own. Its employment must, to some extent, depend upon the anæsthetist's opinion of the condition of the patient, and it seems to me that there is at present a too great readiness to resort to treatment by venous infusion. This is largely fostered, in my opinion, by erroneous views on the condition of the blood-vessels during severe operations.

When I add one case in which a semi-pedunculate uterine tumour was removed from a pregnant uterus, the operation being followed by a miscarriage and death from septicæmia, I have mentioned every case in my

practice of death from operation for the removal of uterine new growths. Of the six cases bearing on the question raised, four died from the excessive severity of the operation, two from lung complications, and I do not think that any weight, either in favour of leaving or of removing the cervix, can be attributed to these results.

Another view of the question at issue may be obtained from a study of the remote effects of treatment. My colleague, Mr. Alban Doran, has published the results of a series of hysterectomies performed for fibro-myomatous tumours, and recorded after an interval of not less than two years ('Obstet. Soc. Trans.,' vol. xlvii, p. 363). He was inclined to favour a partial removal, the cervix and even a portion of the mucous membrane of the body of the uterus being left. By this procedure it was suggested that a less troubled convalescence might be obtained.

The effects of the operation upon the progress of the "change of life" are important. But, as was pointed out by Mrs. Stanley Boyd, in the debate on Mr. Doran's paper, if we consider how much the troubles of the menopause vary in women who have not undergone surgical treatment and have had no recognised disease of the genital organs, it seems to me that we ought not to lay too much stress in regard to this matter on the results of a series of operations, unless the indications are very strongly in favour of one view, and this was not asserted.

Surgical treatment cannot, for example, make a neurotic woman cease to be so, and in those rare cases in which insanity follows an operation on the genital organs I think there is generally a predisposition to mental disorder. I only remember two such cases in my own practice, and in each the patient came from an affected stock. In fact, when the condition of a patient after treatment is not satisfactory it may be that the method is not in any way at fault.

I would suggest that women who are otherwise healthy generally make the best recoveries, both as regards the

immediate and the remote results of a hysterectomy. One of my earliest recollections of abdominal surgery is the remarkable success, as judged by the after-results, of many cases in which the old operation, with the use of the serre-nœud and removal of both ovaries and Fallopian tubes, was employed. Similarly, by every modern method or combination of methods as regards taking or leaving the cervix and one or both ovaries, the most gratifying after-results are common. When both ovaries have been removed I have seen patients get well so quickly that I am by no means persuaded that the leaving of an ovary or part of an ovary is so important a point as some surgeons believe.

There are patients who are not so fortunate, but one of the worst cases of nervous disturbance after a hysterectomy in my practice was that of a patient aged 54 from whom I removed a very hard fibroid tumour, which filled the pelvis and caused much trouble from its weight, three years after the periods ceased. The tumour was so calcareous that I could hardly cut it with a knife. Its removal, the ovaries and cervix being left, was followed by a perfect convalescence, so far as the surgical condition was concerned, but for three years there was almost constant distress, especially in warm weather, from irritation of the skin all over the body. At the end of that time the health of the patient began to improve, and she now says that she is very comfortable.

From a consideration of such cases I hesitate to conclude that after-troubles, connected with the artificial induction of the menopause by removal of the uterus, should be attributed altogether to the method of operating, and from a careful study of the whole question I have formed the opinion that the advantages of removing the cervix decidedly outweigh the disadvantages, both in theory and in practice.

In theory the removal of the cervix seems to me exceedingly desirable, for the reasons which I have stated, and in practice the patients, in my experience, recover

much more smoothly and comfortably after the total removal of the uterus.

I would, therefore, urge that in performing hysterectomy the excision of the cervix should be undertaken whenever there are no very special reasons against it; that, when time permits, the general health of the patient should be made as satisfactory as possible before this operation is performed; and that no woman should be advised to retain a fibroid tumour which has begun to have a definitely prejudicial effect upon her health, or which is of any considerable size. These seem to me to be the chief points to be attended to with a view to obtaining a still further success from this which is already one of our most satisfactory operations.

Mr. Alban Doran admitted that Mr. Malcolm had most ably pleaded for panhysterectomy, yet, for several reasons, in part admitted by himself, his arguments could hardly persuade us that the so-called "subtotal" operation ought to be abandoned. In the first place the cervix was one important part of the pelvic floor which should not be treated as a negligeable quantity by the operator. We knew how safely it could be left when the body of the uterus, badly damaged during the removal of an adherent ovarian tumour, had to be sacrificed. Pozzi and others saved the cervix in many cases where the rest of the uterus was taken away with diseased appendages, provided, of course, that no septic condition was probable. In the second place there was reason to believe that, in order to ensure the full benefits which should follow the saving of more or less of the ovaries in hysterectomy, it was advisable to leave a portion of the endometrium as well; in other words, not only the cervix, but a little more of the uterus, should be spared. Mr. Doran had brought forward evidence, based upon long after-histories of sixty subtotal hysterectomies, showing the value of this practice, and further experience had not induced him to alter his views. Mr. Doran laid great stress on long after-histories, for a woman convalescent from hysterectomy for fibroid was never so sure of permanent benefit as was a patient convalescent from ovariotomy for a non-malignant tumour. The method of Crewdson Thomas should be applied to all series of subtotal and panhysterectomies, and it would be instructive to hear some day of Mr. Malcolm's results after passing a test of that kind. Until then (if even then) the death-knell of the subtotal method could not be sounded.

Dr. Amand Routh did not consider that Mr. Malcolm had proved his contention that it was better to perform total rather than subtotal hysterectomy in operations on uterine fibroids. Hitherto panhysterectomy in fibro-myomatous uteri had been urged from the point of view that the cervix was apt to become malignant if not removed. It had not, however, been proved that fibroids predisposed to uterine cancer, and still less had it been shown that the cervix was especially prone to malignant changes if fibroids were present in the uterine body. Even if such a connection were proved it had still to be shown that such a tendency persisted after the fibroids were removed by a subtotal hysterectomy. To-night, however, Mr. Malcolm had advocated the removal of the cervix "on the theoretical consideration that leaving it gives an increased opportunity for the development of septic mischief." Dr. Routh thought that this was theory alone, and that the author had advanced no sufficient proof that the cervix was inflamed in his case, or that the autotoxæmia from which the patient undoubtedly suffered was of cervical origin. He did not believe that the blood-supply of the cervix after subtotal hysterectomy was "to some extent cut off," nor that the cervix tended to degenerate, and he thought the phlegmasia and other symptoms in the author's cases were secondary to infection of the pelvic cellular tissue. In the absence of proof that leaving the cervix was likely to cause mischief, Dr. Routh thought the disadvantages of its removal should be carefully considered. The mortality of panhysterectomy was distinctly greater. Taking over 1000 cases, collected by Pozzi, of each of these two forms of hysterectomy, he found the percentage of mortality of panhysterectomy was 10·4, whilst the mortality of the subtotal operation was only 7·4. The subtotal operation could be performed more quickly, and there was less hæmorrhage, and the hæmorrhage was more easily controlled. Sepsis was much more likely to occur, with infection of ligatures and prolonged suppuration, if the vaginal canal were opened up. The length of the vagina was maintained if the cervix was retained, and colpocele could be avoided by drawing the stumps, formed by the ligation of the uterine and ovarian vessels, together on each side. This procedure was useless in panhysterectomy. There remained, too, the question of internal secretion, and it was quite certain that such a glandular structure as the cervix must have one. If organs were to be removed for possible dangers in the future, where is the line to be drawn? Following the same argument, no one would leave a second ovary *in situ* if one were being removed; no one would leave the appendix vermiformis if the abdomen were opened for any cause. He was sorry that he did not think that Mr. Malcolm had made out his case.

Mrs. Boyd used both methods for fibro-myoma, according to

which seemed best suited to special conditions, and did not speak, therefore, as a partisan of either method. She had on more than one occasion seen a cellulitis about the stump of a cervix left by supra-vaginal amputation, but she had also seen cellulitis about the exposed base of the bladder, accompanied by troublesome cystitis, in cases of panhysterectomy. She found panhysterectomy the more troublesome operation, and agreed with Mr. Doran that the greater interference with the pelvic floor, and the more difficult hæmostasis, where the vaginal vault was incised, were points of considerable importance.

Dr. EDEN said that he had performed a large number of hysterectomies for fibro-myoma by the supra-vaginal method, and a small number by the total method, and he was equally satisfied with both. He was not at all convinced by Mr. Malcolm's arguments that the total operation possessed any real advantages over the other. Mr. Malcolm's objections to the supra-vaginal operation were two in number: (1) the blood-supply of the cervical stump was impaired by the operation, and it was therefore more liable to become infected; (2) the mucous membrane of the cervix was a greater source of danger than that of the vagina. With regard to the first objection, it must be recollected that the blood-supply of the cervix consisted of the circular artery from the uterine and anastomosing branches from the vaginal arteries. In the supra-vaginal operation the uterine arteries were divided above the origin of the circular branches, while the vaginal arteries were uninjured; the blood-supply of the cervix was therefore not affected in any way by this operation. With regard to the second objection, he thought that bacteriology showed the vaginal flora to be much oftener pathogenic than those of the cervix. The clinical evidence brought forward by Mr. Malcolm in support of his contention upon this point was singularly unconvincing. For instance, cases of phlegmasia occurred quite as often after a simple ovariotomy as after a panhysterectomy, and the cervical stump could have nothing to do with its causation. Again, the occurrence of localised cellulitis around the stump after the supra-vaginal operation might be due to faulty technique; he had seen such cases himself, and he explained them in that way. And lastly, he suggested that the case in which Mr. Malcolm observed a purulent discharge from the cervix and the rectum thirteen months after supra-vaginal hysterectomy might have been due to gonorrhœal infection acquired subsequent to the operation. On the whole, he was not convinced that there was any practical advantage in the total operation. It was argued that better drainage was obtained by the removal of the cervix, but under ordinary circumstances drainage ought not to be required; it was much better to arrest hæmorrhage completely before sewing over the peritoneal edges. It certainly appeared to him that prolapse of the bladder was

more likely to occur after the total operation, especially if vaginal drainage were employed for a few days afterwards. Since it could be more rapidly performed, he should continue to prefer the sub-total operation, except in special circumstances.

The PRESIDENT said that he had performed total abdominal hysterectomy for fibroids to the entire exclusion of the partial operation for the past six years, and agreed with the main conclusions of the author that total abdominal hysterectomy was superior to supra-vaginal amputation, but he did not think that Mr. Malcolm had produced much evidence of its superiority. He (the President) had given the points of superiority of the total operation at the Manchester meeting of the British Medical Association, in Allbutt, Playfair, and Eden's 'System of Gynæcology,' and in that Society. He had not seen any evidence brought forward which led him to modify his opinion as to the superiority of the total operation when performed by Doyen's method. It was superior in that it had a lower mortality (as is shown in Saenger and Herff's* extensive statistics); it provided for drainage; it gave security against injury to the bladder and ureters and against unrecognised hæmorrhage; it removed the cervix, which might become infected, slough, contain unrecognised malignant disease, or develop malignant disease subsequently. It was also less likely to be followed by intestinal obstruction if the peritoneum were closed by a purse-string suture. He had never seen prolapse or trouble with the bladder caused by the operation. The bladder troubles which Mrs. Boyd had met with, he thought, might be due to her employing gauze drainage. Bumm had noticed these troubles after Wertheim's operation, and attributed them to the use of gauze drainage. The President had not employed gauze drainage after abdominal hysterectomy for fibroids for several years past, and knew that it was unnecessary, and believed it to be injurious. The supposed advantage of the internal secretion of the cervix and the slight shortening of the vagina by the removal of the cervix could not be seriously set off against the above-mentioned advantages. Their importance was disproved by the excellent results of vaginal hysterectomy.

Mr. MALCOLM, in reply, said he was quite aware that his argument would not be conclusive to those who thought the supra-cervical the better operation. He had brought forward all the clinical evidence he possessed against the view he advocated, as well as that in its favour. Nevertheless, he had come to a very decided opinion, founded on the facts stated, that the complete operation was the better one. Of course, it was open to anyone to say that the complications which arose were due to faulty technique, but every care was taken, and the two first cases offered no difficulties of manipulation, so that he was himself

* 'Encyklopädie der Geb. und Gyn.,' 1900, pt. 2, p. 91.

confident that, so far as he was concerned, these cases should have given no trouble. Moreover, as stated in the paper, there was no mischief to be detected by manipulation around the stump, and clear evidence of mischief in it. The idea that the third case might be one of gonorrhœa was also possibly correct, but the mischief was not in the vagina, except just round the os, and there was certainly much inflammation in the cervix, whilst the trouble dated from soon after the operation. On the whole the evidence seemed to favour the view that a ligature was separating. Mr. Doran had pleaded for longer after-histories. The speaker had not tackled this extremely laborious investigation in a series of cases, and it might be that he heard most of his successful operations, but he had plenty of long histories, in which the results were all he could hope for. He had not met with trouble from weakness of the pelvic floor, nor from cellulitis around the bladder. He did not pack the vagina.

MAY 1st, 1907.

Dr. Herbert R. Spencer, President, in the Chair.

Present—30 Fellows and 4 visitors.

Books were presented by the Johns Hopkins Hospital Staff, The Medical Society, The Journal of Obstetrics and Gynæcology of the British Empire, and a copy of a medal by the Executive Committee of the Semmelweis International Memorial.

The following candidates were elected Fellows of the Society: John Prescott Hedley, M.B., B.C.Cantab.; William Gordon Speers, M.R.C.S., L.R.C.P.Lond. (São Paulo, Brazil).

Report of the Pathology Committee on Dr. H. Russell Andrews's Specimen of Supposed Sarcoma of Cervix (*see p.* 137).

We have examined this specimen and microscopic sections taken from various parts of the tumour (cut by Dr. Cuthbert Lockyer specially for this Committee), and agree that the growth is not a sarcoma, but a degenerating fibro-myoma, the vessels of which are fully formed and

enormously dilated, due to strangulation. Some of the sections show adenomatous tissue, as is frequently seen in benign polypi.

(*Signed*) Herbert R. Spencer.
Cuthbert Lockyer.
John S. Fairbairn.
R. D. Maxwell.
A. Lionel Smith.
G. F. Darwall-Smith.
Corrie Keep.
W. S. A. Griffith, *Chairman.*

A CASE OF INTRA-PERITONEAL RUPTURE OF THE BLADDER OCCURRING DURING LABOUR.

By Charles R. Porter, M.R.C.S.Eng., L.R.C.P.Lond.

(Introduced by Dr. Russell Andrews.)

The patient, M. J—, a primipara, aged 32, was seen on January 11th, 1907, as labour was supposed to have commenced. The pains had been few in number, had lasted only a short time, and had chiefly been felt in the sacral region. On examination of the abdomen the child was felt to be lying in the first vertex position; the abdomen being otherwise normal, there being no evidence of any undue distension of the bladder. There were no pains at the time of examination. Urine had been passed, and the bowels, which had been constipated during the past fortnight, had been open the day before. *Per vaginam* the os uteri was the size of a threepenny-piece, the cervix was soft and shortened; the vertex could easily

be felt and the sutures made out. There was no indication of any contraction of the pelvis. The membranes were unruptured, though there was a history of "waters running away" for the past two or three days. It should be mentioned that the patient had been seen on January 7th on account of this symptom, and was then found to be not in labour.

The patient was of a decidedly neurotic temperament, and as she had slept very little the night before she was given tr. opii ɱxx that night, but with very little effect. She was not seen again till the morning of January 14th, when the following history was obtained from the nurse: The interval between January 11th and January 13th had been practically free from real labour pains, the patient being up and about until 8.30 p.m on the 13th, when labour apparently started in earnest. Labour pains continued at intervals all night, increasing in severity. At 8.30 a.m. on the 14th the patient, suddenly, during a pain, cried out that "something had given way inside," and was from that moment evidently in a great deal of general abdominal pain. At this point the nurse sent for me, but as the house was three and a half miles away it was 9.30 before the message was received.

When seen at 9.50 the patient was lying on her back in bed, looking very ill indeed, calling out from time to time with pain, and tossing her head from side to side. The knees were bent and the thighs were flexed upon the abdomen. The pulse was very rapid, about 160 per minute, and small in volume; the respirations were rapid and shallow. The lips were dry, and the tongue furred and somewhat dry in the centre. The abdomen was considerably distended and tympanitic, especially at the epigastrium. The pain complained of was general and continuous, and not like labour pains. The body of the child could still be made out, and the uterus did not appear to be tonically contracted; slight rhythmical contractions could still be made out. *Per vaginam* the head was found to be still in the first vertex position and well down in the pelvis.

The os uteri was nearly fully dilated, and the head could be pushed up with ease, though this caused somewhat more pain.

As there seemed to be no obstacle to delivery except the absence of strong uterine contractions, and taking into consideration the serious condition of the patient, chloroform was at once administered and delivery was quickly and easily accomplished with forceps. The cord was pulsating very feebly, and after a few gasps at ten-minute intervals, the child (a well-nourished full-term male), died in spite of artificial respiration being continued with for nearly an hour. The placenta and membranes were expressed after fifteen or twenty minutes, and this was followed by somewhat severe post-partum hæmorrhage, which, however, yielded to bimanual compression of the uterus, ergot, and a hot douche. An examination was now made as far as possible of the uterus, but beyond a small tear in the cervix nothing abnormal could be made out, the uterus contracting down well after the hæmorrhage had ceased.

After delivery the patient ceased to complain of pain of any kind, and palpation of the abdomen did not produce any marked discomfort. There had been and were no symptoms referable to the bladder, and the question seemed to be whether labour had been complicated by perforation of the appendix or of a gastric or duodenal ulcer. There was no previous history suggesting any of these, and the patient had been known and treated for at least three years prior to her pregnancy. There had been no vomiting.

The pulse rate and respirations still continued very rapid after delivery, but as the patient seemed much more comfortable it was decided to leave her for the time being with the hope that the general condition would improve sufficiently to risk her removal to hospital. This meant a horsed-ambulance drive of eight and a half miles. Her condition at 4.30 p.m. the same day was about the same; she had not vomited, and expressed herself as

feeling somewhat more comfortable. The tongue was moist, the pulse, however, being still rapid—about 120 to 130. No urine had been passed, and as there was no obvious distension of the bladder, and no discomfort, and also in view of the neurotic element in the case, a catheter was not passed.

On January 15th, at 10.30 a.m., the patient was obviously much worse. She had been vomiting frequently during the night. No urine had been passed.

It was decided to remove her as soon as possible to the West Herts Infirmary, but in consequence of the distance (the ambulance being three and a half miles from the patient's house) the patient was not admitted until 3 p.m.

For the following notes of the subsequent treatment I am indebted to my partner, Dr. S. A. Bontor, under whose care she was admitted, and also to Mr. W. R. Kirkness, the house-surgeon.

The patient's condition on admission was very grave. The pulse was barely perceptible at the wrist, the face was sunken and the expression anxious. The tongue was dry and brown. The abdomen was enormously distended and tympanitic. The respirations were rapid and shallow. A catheter was passed and yielded about two or three ounces of almost pure blood mixed with a slight quantity of urine. It was decided to open the abdomen at once. Chloroform was administered and the abdomen opened in the middle line below the umbilicus. On reaching the general peritoneal cavity a large quantity of semi-serous fluid escaped; this ultimately proved to be partly urinous. There was slight general hyperæmia of the coats of the small intestine. The sigmoid, descending, transverse, and ascending colon were literally packed with hard fæces. The cause of the condition was not at first apparent as examination of the bladder did not at first reveal any laceration. The examination of the abdominal organs, as also the respirations of the patient, were considerably interfered with by enormous distension of the stomach. The abdominal incision was therefore

enlarged in the direction of the ensiform cartilage and a small trocar was thrust into the anterior wall of the stomach, the gas evacuated, and the puncture closed with two Lembert sutures. Further examination then revealed a vertical rent about one and a half inches in length in the upper and posterior aspect of the bladder somewhat to the right of the middle line. It was observed that this aspect had been somewhat obscured by the introduction of a Doyen's retractor. The edges of the rent were ragged, but were easily approximated by two Lembert sutures, the wall of the bladder being again invaginated and rendered more secure by two more sutures of the same kind. The whole peritoneal cavity was then flushed out with hot normal saline solution and the peritoneum cleansed with gauze swabs as far as possible. The lower angle of the wound was drained by a large-bored rubber tube leading down to the bladder, and the abdomen was closed with silkworm-gut sutures.

The patient was not very markedly worse for the operation, but in spite of all the usual means to combat shock she never rallied, and died at 9 p.m. on the same evening.

Unfortunately no *post-mortem* examination was allowed, but there was no reason to believe that there was any disease of the bladder.

A UTERUS FOUR YEARS AFTER CÆSAREAN SECTION.

Shown by Mr. J. Bland-Sutton.

A woman, E. C—, aged 27, well advanced in pregnancy, was admitted into the London Hospital in October, 1902. The pelvis was occupied by a tumour which furnished the signs of a cervix-fibroid, and as it would clearly

obstruct the transit of the fœtus, Dr. Herman performed Cæsarean section and extracted a living female child. The tumour was considered to be irremovable. Before the patient left the hospital she was examined under an anæsthetic by Mr. F. Eve, who regarded the tumour as a fibro-sarcoma springing from the pelvic wall and adherent to the rectum; he did not recommend an operation. This opinion was also endorsed by Mr. Hutchinson, who

FIG. 2.—A uterus in sagittal section. It had been subjected to Cæsarean section four years previously, and the sutures used to close the uterine incision are clearly visible on the cut surface.

happened to be present. For this information I am indebted to the courtesy of the registrar.

In February, 1907, this patient came under my care in the Middlesex Hospital, and I found the abdomen occupied by a solid tumour as big as a football. This I succeeded in removing, for it proved to be an ovarian fibroid; it had an adhesion to the rectum and to the back of the uterus; this latter organ was spread over the face of the tumour like a pancake, and the sutures used to close the uterus at the time of the Cæsarean section were visible on its anterior surface, and appeared like a series of transverse braids on a military coat. The uterus was

detached from the tumour, but the oozing was troublesome and it appeared safer to remove it. The injury to the serous coat of the rectum was carefully sutured, and it seemed prudent, as there had been some free oozing, to drain with a narrow rubber tube. This proved a wise precaution as some suppuration ensued, but the patient made a satisfactory recovery. Soon after the uterus was removed it contracted into its natural shape; it was then carefully hardened and bisected (Fig. 2). On casually inspecting the cut surface it looks like a normal uterus, and there is nothing to indicate that it had been opened. When the cut surface is examined with a magnifier the sutures used to close the incision are clearly visible, and their position is indicated in the drawing. A portion of the uterine wall was excised for microscopic examination, and we have ascertained that the stuff in which the sutures are embedded has the characters of fibrous tissue. I am rather puzzled in regard to the material of the sutures; to the naked eye they appeared to be catgut, but under the microscope they are seen to be broken up into strands, and yet they do not show the characters of silk. On application to the Registrar it has been ascertained that Dr. Herman usually employed No. 5 Chinese silk, but in regard to this particular case there is no mention in the notes as to the nature of the suture material.

The specimen is interesting as demonstrating the completeness of repair in the uterine wall after Cæsarean section, but it is, of course, a question what would happen to such a cicatrix had the uterus become gravid again, and in relation to this matter I am able to show a uterus from a case of repeated Cæsarean section which bears on this matter.

In May, 1905, Dr. Mulloy performed Cæsarean section on a primigravida, who had congenital absence of the cervix uteri, the communication with the vagina being a narrow opening barely capable of admitting a probe. The operation was performed when the patient was in labour

and the fœtus was dead when extracted. The incision in the uterus was closed with silk sutures.

In November, 1906, the patient had again become pregnant and was particularly anxious for a living child. She had such a large ventral hernia that the fundus of the uterus occupied the hernial sac. She was admitted into the Chelsea Hospital for Women, January, 1907, and her delivery was calculated to happen towards the end of the month. She came into labour January 25th, and a living, healthy, female child was extracted by Cæsarean section. At the patient's urgent wish I removed the uterus as she did not wish a repetition of this trouble, and apart from this, the relation of the uterus to the enormous hernial sac made this course practically a necessity. The hysterectomy was by no means simple, as the uterus adhered to the adjacent coils of bowel as well as the walls of the hernial sac. The patient made an uneventful recovery and the child has thriven.

In this instance an examination of the uterus shows a well-marked depressed scar on the anterior wall, and on section it was found that the uterine wall had not united throughout its whole thickness. There are no traces of suture material.

Cases have been reported in which patients having survived Cæsarean section and again become gravid have sustained rupture of the uterus through yielding of the scar. I think this specimen helps us to realise how such an unfortunate event may come to pass.

To me it is a novelty to see a uterus four years after a successful Cæsarean section, and it is certainly interesting to note the complete union of the incision, which would not be detectable to the naked eye save for its betrayal by the unabsorbed suture material.

The PRESIDENT said that the first specimen exhibited by Mr. Bland-Sutton showed the length of time which silk might remain in the uterus. He had recently seen a patient on whom he had performed Cæsarean section on three occasions—the last over seven years ago. The silk sutures used in closing the uterine wound remained quiescent for nearly seven years, but a

few months ago, the patient having become infected with syphilis, a small abscess formed, and, by means of a crochet-hook, one of the sutures was removed from the resulting sinus, which then closed. The suture appeared to be in much the same condition as when inserted. He always used thickish silk in sewing the uterus and on ovarian pedicles, and this was the only occasion in which he had known such a ligature come away after operation. The silk suture communicated with the uterine cavity, though he was always careful not to penetrate the mucous membrane in sewing up the uterus, and he thought it had probably become infected from the uterus, as a result of endometritis of syphilitic or gonorrhœal origin. The President did not think it was justifiable to remove the uterus after Cæsarean section, or to sterilise the patient, except where the uterus contained fibroids, cancer, or was damaged or infected. In the slighter forms of pelvic contraction, alluded to by Dr. Heywood Smith, in which a viable child would subsequently be delivered by induction of premature labour, patients were frequently sterilised without any sort of justification, in his judgment.

Dr. Lewers had performed Cæsarean section a second time in one patient about two years after the first operation, and had an opportunity of inspecting the site of the incision made at the first operation. He used silkworm-gut sutures for the uterine wound, and these could be felt almost as plainly as when first inserted. They were embodied in organised lymph and omental adhesions. As regards the justifiability of attempting to sterilise patients during Cæsarean section, in this case he had endeavoured (at the patient's request) to sterilise her at the second operation. He thought it best to advise the patient against such attempts at a first Cæsarean section. At a second operation it seemed much more reasonable to make such an attempt, if the patient wished for it. He thought, in any case, that the patient's wishes on the matter should be acted upon, when all the circumstances had been put before her.

Dr. Amand Routh considered that the patient herself, or her husband, should decide as to whether she should run the risk of another pregnancy and another Cæsarean section, and should therefore have the possible dangers fully explained to her. Rupture of the uterus during a succeeding pregnancy and other complications had to be faced. Sterilisation should only be effected with the patient's consent.

Dr. Heywood Smith asked whether, in reference to the important question raised by the President as to the sterilisation of women who were the subjects of Cæsarean section, such proceeding would not be justifiable in cases where there was marked deformity of the bony pelvis, in contra-distinction to those cases where the obstruction was due to some remarkable disease, as for instance, a fibroid tumour of the cervix.

Dr. Griffith had not had an opportunity of operating twice on the same patient, though in one case his colleague, Dr. Gow, had operated during his absence on a case on which Dr. Griffith performed Cæsarean section a year or two previously. He informed Dr. Griffith there were no adhesions, nor any trace of the uterine incision, nor of the sutures. Dr. Griffith was of opinion that perfect coaptation of the cut surfaces led to perfect union in the case of the uterus, and the absence of trouble from sutures, whilst depending on their asepticity, was also materially influenced by the fineness of the material. For some years he had therefore used Singer's thread, Nos. 40 and 60, in preference to silk for ligatures and most sutures. He entirely agreed with the President that sterilisation in these cases was, as a rule, unjustifiable, though in cases of large fibroids or malignant disease there was no alternative.

TWO SPECIMENS FROM CASES OF CANCER OF THE CERVIX, THE PATIENTS REMAINING FREE FROM RECURRENCE TWENTY AND ELEVEN YEARS RESPECTIVELY AFTER OPERATION.

Shown by Dr. Lewers.

Dr. Lewers showed these specimens and sections under the microscope for the purpose of giving the after-histories.

In the first case, one in which there was a malignant ulcer of the vaginal portion of the cervix, the cervix was removed by the supra-vaginal amputation on March 17th, 1887. Dr. Lewers held in his hand a letter from this patient written in March, 1907, in which she stated she continued quite well. The microscopical examination showed the case to be one of squamous epithelioma. In this case the disease appeared to be in a fairly early stage.

In the second case, also one of squamous epithelioma of

the cervix, the disease was in a much more advanced stage. There was a large "cauliflower" growth of the cervix, and the body of the uterus was much enlarged owing to pyometra. In this case vaginal hysterectomy was performed on June 1st, 1895. The patient, now being in Australia, writes to Dr. Lewers on the anniversary of the operation every year, and he produced a letter written on June 1st, 1906, eleven years after the operation, in which she reported herself as being quite well.

Full details of these cases are given in Dr. Lewers' monograph, "Cancer of the Uterus," pp. 96 and 131 respectively.

Dr. Lewers said these cases showed that both the supra-vaginal amputation of the cervix and vaginal hysterectomy could, in some cases at all events, give as good after-results as could be wished for. In similar cases he still, therefore, continued to perform vaginal hysterectomy; at the same time he was in favour of trying the more extensive operation performed by Wertheim for cases where there was evidence that the disease had extended moderately beyond the limits of the uterus. Time alone could show whether such more extensive operations, in the class of case mentioned, when the disease had spread beyond the uterus, would be followed by as good, or better, results than attended supra-vaginal amputation of the cervix and vaginal hysterectomy in the relatively earlier cases, where the disease seemed not to have spread beyond the uterus. He was not at present in favour of performing Wertheim's operation as a routine treatment for every case thought to be operable.

The PRESIDENT said that he had not operated on a case of cancer of the cervix so long ago as twenty years; but the three cases in which it complicated labour, which he had already brought before the Society, remained well ten years after operation. He agreed with Dr. Lewers as to the importance of early operation and also as to the good results obtained in such cases by high amputation. The modern extended abdominal hysterectomy, however, permitted a clean surgical operation to be per-

DESCRIPTION OF PLATE XIII,

Illustrating Dr. May Thorne's specimen of Uterus showing Malignant Villous Tumour and a Fibroid which has undergone Sarcomatous Change.

Section showing sarcomatous change.

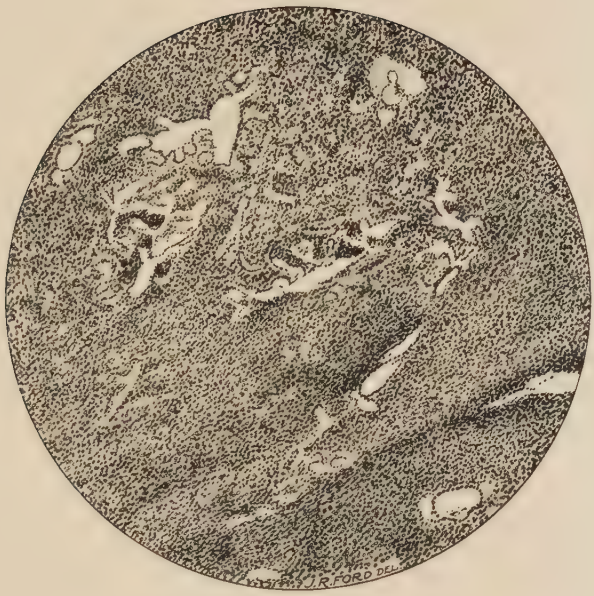

Illustrating Dr. May Thorne's specimen of Uterus showing Malignant Villous Tumour and a Fibroid which has undergone Sarcomatous Change.

Adlard & Son, Imp^rs.

formed in cases where such an operation was impossible by the vagina. In publishing after-histories of cases of cancer it was important that microscopic sections of the growths should be exhibited, as had been done in Dr. Lewers's cases and in his own.

UTERUS SHOWING MALIGNANT VILLOUS TUMOUR AND A FIBROID WHICH HAS UNDERGONE SARCOMATOUS CHANGE.

(With Plate XIII.)

Shown by Dr. May Thorne.

Dr. May Thorne showed a uterus removed on account of hæmorrhage from an unmarried patient, aged 61, in whom hæmorrhage occurred about ten years after the menopause. The pathological report on the uterus by Dr. Cuthbert Lockyer states: "The endometrial growth takes the form of a malignant villous tumour. The latter shows but little tendency to immediately invade the muscle, but deep in the strata of the solid uterine wall groups of cancer cells exist in the lymphatics. Deep in the uterine wall there is an interstitial growth which started as a fibroid but is now a sarcoma. This condition is confirmed on further examination." The uterus also contained two small, simple fibro-myomata.

The specimen was referred to the Pathology Committee.

MALIGNANT VAGINAL POLYPUS SECONDARY TO AN ADRENAL TUMOUR OF THE KIDNEY.

(With Plates XIV—XVIII.)

By Alban Doran, F.R.C.S.,
SURGEON TO THE SAMARITAN FREE HOSPITAL.

(Received April 3rd, 1907.)

(*Abstract.*)

A married uniparous woman, aged 40, suffered from rigors and sweats in September, 1906. A mass was detected in the vagina, and a small tumour in the right iliac fossa. The vaginal growth was a racemose body attached by a well-defined pedicle to the lower part of the anterior wall of the vagina; its lobules, more or less necrosed, were shed from time to time. Three sessile growths lay in the posterior wall, the mucosa over one was pigmented. In November the author removed the abdominal tumour, which proved to be a malignant adrenal growth in the lower part of the right kidney. The patient declined to allow a second operation for the extirpation of the vaginal growths; lobules of the pedunculated tumour continued to come away. She survived the nephrectomy three months. After death secondary deposits were discovered in the liver and right lung; their presence in the lung had been diagnosed before death. On microscopical examination it was found that the vaginal tumours, as well as the growths in the liver and lung were of the adrenal type, and therefore secondary to the tumour in the kidney.

In this case a pedunculated tumour developed in the vagina, the slow, constant sloughing of its lobules probably accounting

for the rigors. The tumour bore characters usually associated with the type of new growth known to pathologists as "primary sarcoma of the vagina in the adult" (Gow, Veit). Secondary deposits in the lung have been recorded (Herzfeld, Bajardi) and pigmentation has been observed (Horn, Morestin, Boldt). In the author's case, however, sections of the lobules shed from the pedunculated tumour showed the same structure as was seen in sections from the renal tumour. Hence there could be no question of coincidence of a primary vaginal sarcoma and an adrenal tumour or "hypernephroma" of the kidney; the latter being, without doubt, the primary growth.

The specimen was referred to the Pathology Committee.

Introductory Remarks.

Primary sarcoma of the vagina in the adult is clinically and pathologically a disease of high interest, about which much has been written during the past twenty years by many British and Foreign gynæcologists. In the course of that same period, general surgeons and pathologists have bestowed much attention on a far more frequent, yet, until of late, hardly more recognised form of new growth, "hypernephroma" or "adrenal tumour" of the kidney, so-called because it originates in "rests" or tracts of tissue resembling that which makes up the normal zona fasciculata of the supra-renal capsule.

I will now relate a case where a malignant pedunculated tumour developed in the vagina of a woman, aged 40, some of its lobes coming away from time to time, whilst one amongst three sessile adjacent growths showed "pseudo-melanosis" (Horn, Morestin) of the superjacent vaginal mucosa. All these features have repeatedly been recorded in cases of what is specifically known as "primary sarcoma of the vagina in the adult." Nevertheless the tumour proved to be secondary to an adrenal adenoma of the kidney. Nephrectomy was performed, the patient surviving the operation for three

months. After death, metastatic deposits were detected in the liver and lung as well as the vagina.

History of the Case before Operation.

Mrs. E. H—, aged 40, was admitted into my wards in the Samaritan Free Hospital, on November 7th, 1906. She had been referred to me by Dr. W. T. Evans, of Gloucester Terrace, who had detected an abdominal tumour and a polypoid growth in the vagina.

The patient had been married for nineteen years. Her sole pregnancy ended at term two years after her marriage. Dr. Evans could find no history of any serious illness since or before her confinement. Early in September, 1906, she complained of a "chill and tightness of the chest." She kept in bed for a few days and felt extremely weak when she got up. Thenceforward she began to be troubled with profuse sweats, which, as will be seen, continued after the operation. After August, 1906, the catamenia ceased abruptly. They had previously been regular with moderate hæmorrhage for about four days.

On recovering from the "chill" the patient discovered that the abdomen was swelling, and it slowly increased in size.

The patient was rather thin and distinctly sallow. An oval elastic tumour occupied the right iliac region. It was of about the size of a cricket ball, and could be moved laterally to the extent of two or three inches, but could not be pushed far backwards or upwards. On percussion there was resonance which varied from day to day. The kidney could not be defined in the loin and there were no enlarged glands in the inguino-femoral region.

There was hardly any vaginal discharge. On the posterior commissure lay a flat nodule under an eighth of an inch in diameter, and its surface bore papillæ. A pedunculated morbid growth of somewhat unfamiliar type

DESCRIPTION OF PLATE XIV,

Illustrating Mr. Alban Doran's paper on Malignant Vaginal Polypus secondary to an Adrenal Tumour of the Kidney.

FIG. 1.—The vaginal polypus. Lateral view of the largest detached portion, natural size. AT. Line of attachment to pedicle.

Fig. 1.

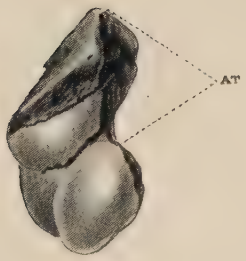

Illustrating Mr. Alban Doran's paper on Malignant Vaginal Polypus secondary to an Adrenal Tumour of the Kidney.

Adlard & Son, Impr.

sprang from the mucous membrane of the vagina two inches above the vulval orifice anteriorly and a little to the right of the middle line. It was racemose rather than polypoid, consisting of several out-growths varying in shape and size; some were like grapes, others cylindrical, elongated, and irregularly bent. They were for the most part dark grey in colour. The entire growth was attached to the vaginal wall by a stout, fleshy pedicle about three quarters of an inch in length; the secondary branches of the pedicle running to each outgrowth were, on the other hand, short, thin, and friable. Two lobules came away after admission, before the operation. They were sent to the College of Surgeons (Pl. XIV, fig. 1). I detected on further examination three sessile growths in the mucous membrane of the posterior part of the vaginal wall. The largest was about half an inch in diameter and there was a black patch on its surface. They were not adherent to the subjacent tissues and the rectum was free from new growths.

The cervix appeared quite healthy and moved freely with the rest of the uterus. There was no deposit above the vaginal fornices, and the tumour in the right iliac fossa could not be pushed down below the pelvic brim.

The tongue was rather raw, but not glossy; the appetite was bad and the bowels were neither constipated nor relaxed.

The patient had observed that the urine had been very thick ever since the chill, but declared that it had never contained blood. It was loaded with bright pink urates, yet the specific gravity never exceeded 1022; about twenty fluid ounces were passed daily; no albumen could be detected.

The temperature fluctuated considerably during the seven days between admission and operation. The maximum was 102° F. (November 11th, evening), the minimum (November 13th, morning, before operation) 98·6° F.

The pulse was 108 on admission and never fell any

lower before the operation. It was fairly full and very soft. My clinical assistant, Major S. Colin Evans, I.M.S., to whom I am much indebted for help in preparing these notes, detected a faint organic systolic murmur at the heart's apex, but no abnormal pulmonary signs.

I diagnosed the vaginal growth as a pedunculated sarcoma, a type noted of recent years by many writers, some of whom have observed its tendency to undergo necrosis, so that its lobes come away one by one. About the tumour, in the right iliac region, I felt much less certain; I believed that it was either an enlarged kidney or an ovarian dermoid held back by adhesions, and bearing adherent intestine on its anterior surface.

The Operation.

The operation was performed on November 13th, with the assistance of Major S. Colin Evans and Dr. W. T. Evans, Mr. W. S. Morley administering the anæsthetic.

My intention was to excise the vaginal growths after removing the abdominal tumour.

When the peritoneal cavity was opened by a median incision about one pint of clear ascitic fluid escaped. A dull white tumour bearing small red, wattle-like outgrowths on its surface lay behind the ascending mesocolon. The uterus and ovaries were normal and in no way connected with the growth. The intestines showed no signs of disease and there were no adhesions. I made a longitudinal incision through the layer of peritoneum which passed from the ascending colon on to the parietes in the flanks, encapsuling the outer part of the tumour. I then enucleated that part and set free the front of the tumour without damage to the colon. The ascending mesocolon, strongly adherent to the tumour, was torn, but without injury to its vessels, which were much dilated. I passed my hand under the lowest and undermost part of the tumour, which proved to be the greater part of the right kidney, almost unchanged and rotated

downwards and inwards so as to lie over the lumbar spine. A great deal of fat was now detached from above and behind the tumour, and much oozing ensued. The renal vessels lay in a thin, tense band, which ran upwards from the hilum, and looked like an old adhesion; this band was divided and the kidney itself set free. This stage of the operation proved easy; the ureter was very thin. On the other hand, I had great difficulty in securing vessels in the oozing surface above. I was obliged to push up the liver, which was pale and thin and apparently free from new growths. The gall-bladder was slightly distended. I detached some firm nodules, apparently glands, from the oozing tissues close to the vena cava.

The patient's condition being very unfavourable, I did not proceed to remove the vaginal growths, as I had originally intended. I flushed the peritoneal cavity with saline fluid, applied deep interrupted sutures to the abdominal wound, poured more saline fluid into the peritoneal cavity, and lastly closed the abdominal incision.

I must admit that, at the conclusion of the operation, I felt anxious about immediate results. I could not feel certain that the tumour was not situated in the supra-renal body itself, and when separating it from its upper connections I thought of a specimen, presented by Dr. Lediard to the museum of the Royal College of Surgeons (Pathol. Series, No. 3514), removed from a subject after death from Addison's disease. It reads: "A suprarenal capsule with the adjacent vena cava . . . It is abnormally close to the vena cava and compresses its own vein." These words were my own, written after examination of the specimen many years ago. But I have never forgotten them, and in consequence do not feel comfortable when operating on anything which may be the suprarenal capsule, as anatomical relations are not always easy to define in the course of an operation, and I know that even during the removal of a purely renal tumour the vena cava may be wounded.

The Renal Tumour.

The parts removed at the operation consisted of the right kidney surmounted by a tuberous mass, which was separated from the kidney in front by a distinct groove (Pl. XV, fig. 2), whilst posteriorly it blended with the adjacent pole of the kidney without any visible sign of demarcation.

The vertical measurement from the uppermost part of the tumour to the opposite pole of the kidney was $5\frac{1}{2}$ inches. The tumour alone measured $4\frac{1}{2}$ inches horizontally, $2\frac{1}{2}$ inches vertically, and $2\frac{1}{2}$ inches antero-posteriorly. Its surface was somewhat tuberous and bore masses of fat. The kidney was of about the normal size and its capsule was not adherent.

On *section* the new growth was seen to invade the substance of the kidney to a considerable extent at its (apparent) upper pole (Pl. XVI, fig. 3). A piece was cut off the border of the kidney posteriorly where the fusion was, as above stated, most marked, so as to include a portion of the tumour. This piece was preserved for microscopical examination. On the kidney, at the point where the piece had been cut, an isolated tract of new growth, with a well-defined, almost circular border, was exposed; it lay in the cortex of the kidney about half an inch away from the lower limits of the tumour.

[Mr. Shattock, after carefully dissecting the preparation, has pointed out to me that the ureter lay in the hilum *anterior* to the artery. I have no doubt as to the position of the tumour when I operated; the kidney was displaced downwards and inwards so that it lay very conspicuously across the lower lumbar vertebræ with its outer, or convex border downwards. Hence the position of the ureter would imply that the tumour had really developed in the *lower* pole of the kidney (probably movable before it became diseased), and that the organ with the new growth had undergone rotation, bringing the tumour and the lower pole uppermost. This fact in

DESCRIPTION OF PLATE XV,

Illustrating Mr. Alban Doran's paper on Malignant Vaginal Polypus secondary to an Adrenal Tumour of the Kidney.

Fig. 2.—The right kidney and tumour seen from without (anterior aspect). The tumour seems to lie on the upper pole of the kidney, as though it had developed in the supra-renal capsule. In reality it lies within the lower pole, which, owing to rotation of the kidney, lay uppermost.

Fig. 2.

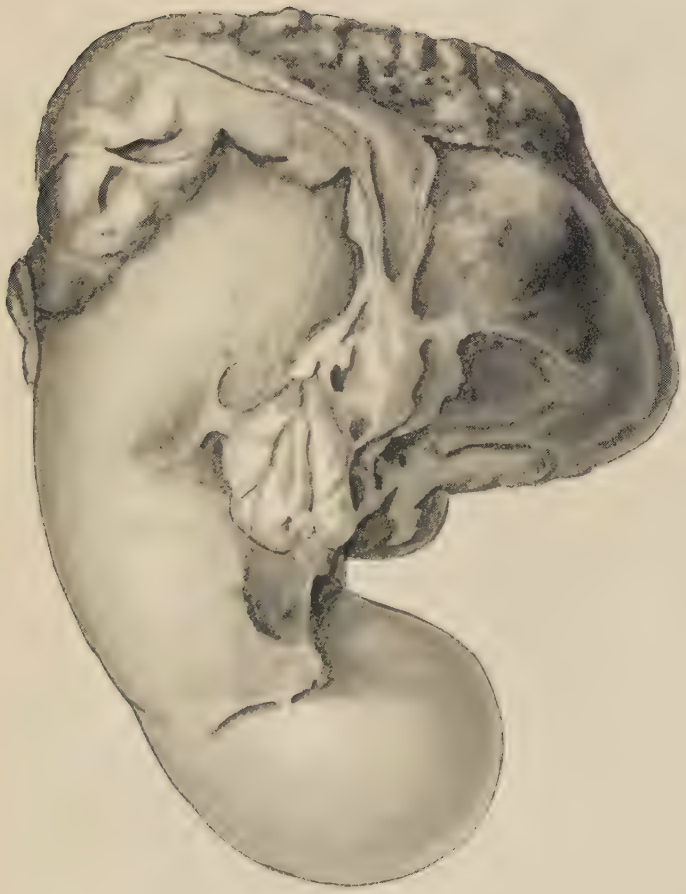

Illustrating Mr. Alban Doran's paper on Malignant Vaginal Polypus secondary to an Adrenal Tumour of the Kidney.

Adlard & Son, Impr.

DESCRIPTION OF PLATE XVI,

Illustrating Mr. Alban Doran's paper on Malignant Vaginal Polypus secondary to an Adrenal Tumour of the Kidney.

Fig. 3.—The right kidney and tumour, showing their cut surface. The tumour is seen to lie within the capsule of the kidney, invading the lower portion of that organ (see Fig. 2). It bears the naked-eye characters of an adrenal growth.

Fig. 3.

Illustrating Mr. Alban Doran's paper on Malignant Vaginal Polypus secondary to an Adrenal Tumour of the Kidney.

Adlard & Son, Impr.

DESCRIPTION OF PLATE XVII,

Illustrating Mr. Alban Doran's paper on Malignant Vaginal Polypus secondary to an Adrenal Tumour of the Kidney.

Fig. 4.—Microscopical section of the renal tumour separated from the adjacent portion of the kidney (above) by an area of fibrous tissue. The tissue of the tumour (below) resembles that of the zona fasciculata of the supra-renal capsule. Low power.

Fig. 5.—The same (lower portion) under a high power. The tumour is seen to be chiefly made up of large cells with big and well-formed nuclei.

Fig. 4.

Fig. 5.

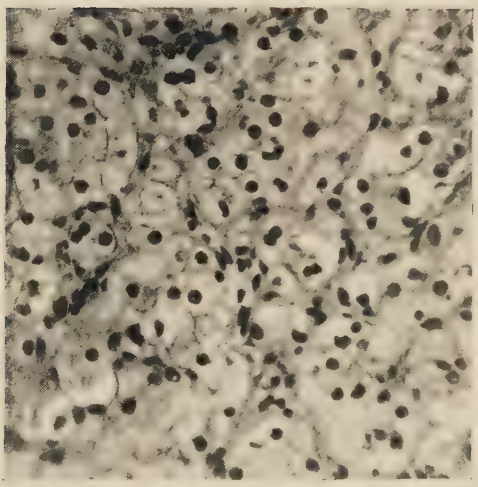

Illustrating Mr. Alban Doran's paper on Malignant Vaginal Polypus secondary to an Adrenal Tumour of the Kidney.

Adlard & Son, Impr.

no ways modifies the pathological aspect of the case in respect to the nature of the vaginal and visceral growths.]

The bisected tumour and kidney have been preserved, the anterior half in the Museum of the Royal College of Surgeons, the posterior in Dr. Cuthbert Lockyer's private collection. The cut surface shows the yellow tissue, with spaces filled with blood, characteristic of adrenal growths.

Microscopical appearances of the renal tumour.—I examined, with Mr. Shattock, some sections of the tumour at its point of junction with the kidney.

On the renal side of the section true cortical tissue was seen, free from new growth. The tubuli uriniferi were well-formed, bearing normal epithelium, but a certain amount of fibrosis was present.

The kidney substance was separated from the new growth by a narrow, but very distinct tract of fibrous tissue (Pl. XVII, fig. 4).

The tumour was made up of large cells with big and well-formed nuclei (Pl. XVII, fig. 5). These cells were arranged in somewhat irregular columns strongly simulating, in Mr. Shattock's opinion, the arrangement of the cells of the zona fasciculata of the cortex in the supra-renal body. The new growth was very vascular, especially at certain points where groups of blood-vessels were seen, some empty and others full of blood. There was very little stroma so that the cells seemed to rest on the capillaries.

The Vaginal New Growth.

The lobules which, as I will relate, came away after the operation, were in a markedly necrotic condition, unfavourable for a study of the histology of the tumour. The two which broke off from the pedicle before the kidney was removed were in a much less altered state, although not absolutely free from necrotic changes. From one lobe, oval, and half an inch in its long diameter, some successful sections were made at the College of Surgeons.

Microscopical appearances.—The tumour was made up of large cells with big nuclei, and, as in the renal tumour, the cells showed in many parts of the section a tendency to a columnar arrangement (Pl. XVIII, figs. 6 and 7). The groups of cells were separated by connective tissue, forming very fine lines excepting at certain points where the tissue was much thickened by free fibrinous exudation.

Mr. Shattock considers that these appearances indicated that the vaginal tumour was secondary to the adrenal growth connected with the kidney. It had none of the microscopical characters of a pedunculated primary sarcoma of the vagina which it so closely resembled to the naked eye.

I must add that near the periphery of the section, corresponding to the surface of the tumour, was a necrosed area separated from the unchanged tumour-tissue by a well-marked layer of fibrin. In that area there was much fibrinous exudation, the tumour-cells had almost disappeared, and there was distinct small-celled infiltration towards the free surface of the tumour.

History after Operation.

The patient recovered from shock sooner than I had expected. She passed urine naturally within four hours after the operation, and never required the catheter. There was very little vomiting, no distension, and no difficulty in the passage of flatus, which passed freely within twelve hours. For a week the temperature seldom rose above 99·2° F. and the maximum was 100·2°, and the pulse became rather stronger and slower than before the operation. In the course of the third week cystitis set in, probably from discharge from the stump of the right ureter and from irritation due to the urine, which was as full of pink urates as before the operation, and could not be kept clear without large doses of citrate of potash, etc.

On November 24th the sweats, which had never entirely

DESCRIPTION OF PLATE XVIII,

Illustrating Mr. Alban Doran's paper on Malignant Vaginal Polypus secondary to an Adrenal Tumour of the Kidney.

Fig. 6.—Microscopical section of a lobule from a vaginal tumour. Its tissue resembles that of the renal tumour (Fig. 4, lower portion), but it is wider meshed and less distinct. Low power.

Fig. 7.—The same, under a high power. Its resemblance to the renal tumour (Fig. 5) is evident, although its tissues are affected by necrotic changes in its neighbourhood.

Fig. 6.



Fig. 7.

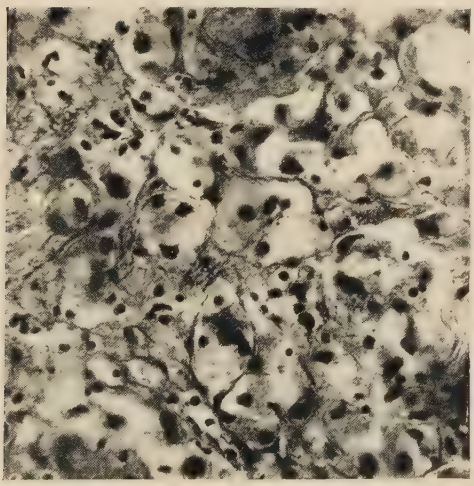

Illustrating Mr. Alban Doran's paper on Malignant Vaginal Polypus secondary to an Adrenal Tumour of the Kidney.

Adlard & Son, Impr.

ceased, became profuse. The thorax was examined and dulness on percussion was detected on the right side up to the third rib. There was increased roughness of breathing-sounds over both lungs, and crepitation at the left apex. These symptoms disappeared within a fortnight, but the dulness never cleared up. On December 2nd a mass of necrosed new growth protruded from the vagina and was easily broken off from the pedicle without much subsequent hæmorrhage. At that date there had already been a rise of temperature for a few days, once reaching 102° F. in the evening. This rise was, apparently, accounted for by the development of a tender body above the right iliac fossa, representing inflammatory exudation around the ligatured tissues, but, as I will endeavour to explain, it was more likely due to another cause.

The patient, contrary to my advice, desired to go home; I had hoped to improve her condition so that she might be able to bear the removal of the vaginal growths. She was discharged on December 12th, a month after the operation. The swelling above the right iliac fossa had grown larger, but was distinctly less tender. As on November 24th, there was dulness in the right mammary line up to the third rib, without cough, hæmoptysis, or dyspnœa. The edge of the liver could be defined three inches below the ribs in the mammary line; it was thin, firm, smooth and not tender. The abdomen itself was not distended, or tender on palpation. The three growths on the posterior wall of the vagina had not increased; in fact, they were necrosing. The pedunculated growth on the anterior wall still bore several lobes. Just as when the patient was admitted, the upper part of the vagina was free from growths and there was hardly any vaginal discharge. The urine was still charged with bright pink urates; the ropy mucus had disappeared after free washing out of the bladder.

The patient was clearly in very weak health. I referred her again to Dr. W. T. Evans. We both feared that she

would never be in a condition which would allow of an operation to remove the vaginal growths.

On January 2nd, 1907, Dr Evans informed me that the patient was losing ground, and that at times she was troubled with cough. "To-day the monthly period began; it is rather profuse." Considering how weak the patient had become this return of the catamenia, after suppression for five months, was remarkable. The patient, notwithstanding her extreme weakness, lived until February 8th, dying twelve weeks and three days after the operation.

Dr. W. T. Evans was permitted to make a *post-mortem* examination, and to him I am indebted for the following report.

The body was greatly emaciated, and the skin uniformly sallow. The *abdominal wound* had healed perfectly.

There was no free fluid in the *peritoneal cavity* or any secondary deposits on the parietal peritoneum. The *stomach* was extremely dilated, its greater curvature almost touching the pubes. The *small* and *large intestines* were almost empty; the rectum contained some soft fæces. There was no sign of obstruction or any trace of secondary deposits. The rent in the ascending mesocolon had closed. The structures forming and surrounding the *pedicle of the right kidney* were removed for examination, as well as an oval body, apparently an enlarged lumbar gland above them; the right supra-renal body could not be distinguished. When examined no collection of pus could be discovered in or around the pedicle, and there was but little inflammatory effusion into its tissues though adhesions were very dense. (The lump in the right side had not increased since the patient left the hospital.)

The *left kidney* and *supra-renal body* showed no outward sign of disease and were put aside with the *spleen*, which was small and firm. The *liver* was large, almost of the normal colour, but slightly mottled at certain points. There were no inflammatory adhesions between it and the diaphragm and viscera. Several secondary

deposits were found in its substance, pale yellow, and firmer than the hepatic tissue. One lay superficially in the anterior part of the right lobe and was as big as a filbert; another of about the same size in the left lobe, but it was ill-defined. Two others, well-defined, lay deep in the substance of the right lobe. The anterior edge of the liver and its under surface showed no signs of secondary deposit. The *gall-bladder* was somewhat distended with dark bile; there were no calculi in its cavity, or in the ducts.

An incision was made in the diaphragm; the right *pleura* was found to be free from adhesions and effusion, the right *lung* appeared normal in consistence, but several secondary growths, similar to those in the liver, were found in the lower part of the inferior lobe, which, together with the liver, was preserved for further examination.*

The *uterus, ovaries* and *vagina* were removed and preserved. Douglas' pouch and the parts around it showed no signs of any secondary growth, but soft adhesions (not existent at the date of the operation) had formed between several coils of small intestine and the posterior surface of the uterus.

The preserved parts were transferred to my care and I submitted them to Dr. Lockyer and Mr. Shattock for microscopical examination.

The left kidney and supra-renal capsule proved to be free from new growths or any other visible morbid condition. The same was the case with the spleen, which, considering the long-standing high temperature, was unusually small and firm. The uterus and ovaries bore no secondary growths.

The pedunculated tumour in the vagina had almost entirely broken down. The three sessile growths in the posterior wall had become necrotic.

The secondary growths.—There was some difficulty in

* The remaining thoracic viscera and the cranial cavity were not examined; the necropsy was made in the house where the patient died.

preparing satisfactory sections of the secondary growths in the right lung and the liver, as they were very soft. At length some sections were successfully cut and stained; under the microscope they showed all the appearances characteristic of adrenal tissue.

Having related my case, I will now review what has been written about connective tissue, tumours of the vagina, and adrenal growths of the kidney.

Vaginal Fibroma and Sarcoma.

Solid tumours of the vagina are not common. Richard R. Smith published five years ago a good monograph on *fibro-myomatous tumours* of the vagina. He collected 101 cases. They are nearly always single; Straussmann and Olenin have reported the only two authentic exceptions. The nature of the attachment of the growth to the surrounding parts is noted in sixty-six cases; in no fewer than thirty-nine the tumour was said to be polypous or pedunculated, whilst the remaining twenty-seven were sessile. Observers, however, differ about what the word "pedunculated" may signify. The most important clinical fact made clear by R. R. Smith is the marked tendency of these innocent fibromas and fibro-myomas to become necrotic, especially when they grow large. The same change has long been known as frequent amongst malignant tumours of the vagina; but Smith's evidence shows that it is no essential proof of malignancy.

Only twelve days before I removed the kidney above described I operated on a fibroma of the vagina. The patient was a married woman, aged 55, who had only once been pregnant; her child was fourteen years of age. She consulted me on account of a large ovarian cyst. There was a history of suppurating femoral glands when she was twenty-two years old. On November 1st, 1906, I removed both ovaries for cystic tumour free from any evidence of malignancy. The vaginal tumour, which I had discovered when examining the patient, lay about

two inches above the posterior commissure. It was perfectly sessile and of the shape and size of a broad bean. The vaginal mucous membrane over it and around it was quite healthy, but I excised the mucosa very freely; much bleeding ensued, easily stopped when the sutures passed under the wound were tied. Dr. Cuthbert Lockyer examined the growth and found that it was made up of pure fibrous tissue. He suspected that it might be keloid in type, an interesting point in relation to the genesis of vaginal fibroids.

We are much more concerned at present, however, with the only other form of vaginal growth which we need discuss, namely, *primary sarcoma of the vagina in the adult*. The last three words are always added in systematic works in order to distinguish this new growth from another of a different type which develops *in the infant*. "Primary sarcoma" will be sufficient here to express solely the type observed in the adult.

A great deal has been written about this primary sarcoma, yet the disease is rare, although Meadows turned attention to it nearly forty years ago, and since then Gow, Veit, Roger Williams, Jellett and Earl, and others have published careful analyses of collected cases inclusive of those under their own observation. Yet Jellett and Earl, the latest writers, could only find thirty-nine authentic reports, less than half the total of genuine instances of primary cancer of the Fallopian tube collected by Orthmann and published in 1906; nevertheless, I believe that most gynæcologists appear to be under the impression that vaginal sarcoma must be much less rare. The labours of R. R. Smith, to which I have already referred, bring up the recorded examples of fibroma and fibro-myoma to 101, and it is highly probable that many other cases remain unreported. For innocent tumours are held by many operators as trifles not worth writing about, and on the other hand fibroma of the vagina often grows slowly and gives no trouble, so that it is liable to be overlooked by the patient, as in my own case, where, as I have explained,

I discovered the vaginal tumour accidentally when examining a woman subject to ovarian cyst. For the above reasons we may feel sure that, in the vagina, fibroma is commoner than sarcoma.

Veit concludes his remarks on *das Sarcom der Scheide bei Erwachsenen* by solemnly warning all future observers who may come across sarcomatous growths in the vagina not to be satisfied with a cursory examination of a case hurriedly embodied in a brief clinical report, but to make sure of the precise significance of any histological element which they may detect—striated muscular fibre, for instance—and above all to satisfy themselves and others as to whether the new growth be primary or secondary. To this view of the question we must all cordially assent, for the collected records of primary sarcoma up to the present date cannot as yet satisfy the pathologist, guide the practitioner, or aid the operator.

Veit, I have observed, mentions striped muscle as an element which arrests our attention. My experience shows that it may be arrested by another highly interesting tissue, the discovery leading to the important conclusion that the vaginal tumour is not primary. Since very little was known about these adrenal "rests" until a few years ago, I suspect that even on more than one occasion a secondary tumour of the vagina similar to my own may have been misinterpreted and ranked as a primary sarcoma.

Thus Klien published as long ago as 1894 a report of a vaginal tumour which he classified as a lymphangio-endothelioma cavernosum hæmorrhagicum. The patient was a multipara, aged 56. Two pedunculated, tuberous, elastic tumours sprang from the vaginal mucous membrane, they were very friable. Both were amputated and the patient was discharged on the seventh day; the after-history was incomplete.* The new growth was reticular

* Klien (*loc. cit.*, p. 301) states that recurrence took place, but at the date on which his report was published the patient could not be persuaded to return to hospital. The case, he said, was being closely watched. I

in structure with the meshes filled with blood. But Neusser, amongst others, reminds us that tumours arising in adrenal "rests" are apt to become "almost telangiectatic." I cannot help thinking that Klien's tumour might have been of that type.

I will now dwell for awhile on two clinical features common to my case and to many examples of alleged primary sarcoma of the vagina in the adult, namely *pedunculation* and *pigmentation*.

Pedunculation.—According to published reports, a large proportion of all types of primary connective-tissue tumours of the vagina are pedunculated. Such is the case, we have seen, in respect to innocent tumours. The reports of pedunculated and sessile primary sarcoma are, I find, not highly reliable. In the first case, errors have crept into tables and statistics. Thus Gow writes, in describing his original case: "On the lower part of the posterior wall is situated a small, round, *sessile* tumour," and in that writer's tables the same case is entered under the heading "Clinical form of growth" as a "sessile lump." Yet in Veit's tables, widely quoted, Gow's case (No. 14) is entered as *gestielt*. In the second place, as I have already had occasion to remark, authors differ as to what the words "pedunculated," "pediculated," "polypous," and "sessile" precisely signify. We know that they do so when describing subserous fibroids of the uterus. A tumour with a sharp edge overhanging a relatively narrow attachment seems to be considered by some as pedunculated and by others as sessile, the latter description being the more correct. These doubtful cases represent an intermediate stage between the absolutely sessile growth merely projecting from the surface of the mucosa, and the tumour with a distinct stalk, a true pedicle in fact, undoubtedly the latter stage

cannot find any further note of it by Klien himself. Veit ('Handbuch der Gynäkologie,' vol. i, p. 362) suspects that Klien's tumour was a carcinoma. Klien makes no mention of any examination of the abdomen before the removal of the tumour.

of the former type. This fact was demonstrated in my case, where the larger, older, and sloughing tumour had a very distinct pedicle, whilst the smaller growths were, when I examined them, absolutely sessile. The large tumour was racemose rather than what is understood by polypoid. Ziegler, in his 'Pathologie,' states that vaginal fibromas, myomas, and sarcomas may be racemose as well as polypoid. The primary sarcoma of the infant's vagina is well known to be racemose.

The fact that this pedunculated tumour of the vagina was secondary to an adrenal growth in the kidney shows how careful we ought to be about exploring the patient's abdomen and thorax and also about choosing a really competent pathologist to examine the vaginal growth under the microscope. I was under the impression, until I received Dr. Lockyer's and Mr. Shattock's reports, that there might be coincident primary vaginal sarcoma and renal hypernephroma, the more so as when I detected evidence of new growth in the base of the right lung I remembered that such a complication had already been observed in primary sarcoma of the vagina.* The microscope, however, showed that both the vaginal tumour and the new growths in the lung were secondary to the renal growth.

Pigmentation.—In this case, as I have already observed in the clinical report, the largest of the three sessile growths in the mucous membrane of the vagina posteriorly bore a black patch on its surface. Unfortunately this appearance was lost because the growth became sloughy before the patient's decease. The pigmentation was very possibly confined to the vaginal mucous membrane investing the growth. In Horn's case of primary sarcoma the mucosa was pigmented, though the tumour itself was free from pigment; yet some secondary growths in the

* Herzfeld: Case where nodules of the new growth were detected in the lungs and pleura at the necropsy. Also Bajardi: Case where the clinical evidence was strong, though no *post mortem* was permitted. Gow (*loc. cit.*) gives good abstract reports of the two cases.

inguinal glands were much pigmented. Later on pigmentary growths developed on the vulva, whilst a big, irremovable, encephaloid, abdomino-pelvic mass was found to be free from pigment. Horn ascribed the pigmentation, which was so remarkably irregular in his case, purely to hæmorrhages, and gave good reasons for his opinion. Morestin, in examining a pedunculated round-celled sarcoma from an elderly virgin, found that some of the cells were charged with pigment, which, like Horn, he ascribed to blood.* My own experience shows that a secondary adrenal tumour of the vagina may be pigmented, and in all probability from the same cause. Pigmentation seems to be a fascinating subject to many writers; as for true melanosis† I may refer the reader to my friend Professor W. Sampson Handley's Hunterian Lectures on "The Pathology of Melanotic Growths in Relation to their Surgical Treatment," delivered last February at the Royal College of Surgeons ('Lancet,' April 6th, 1907, p. 927).

There remains one more feature in my case, interesting in respect to the vaginal tumour.

The sweats.—I have noted that the patient was troubled with free sweats at the beginning of her illness. They never ceased entirely and became profuse again in the second week after the operation. At the time I attributed the marked aggravation of the symptom to exudation in the stump of the pedicle, possibly to suppuration. At the necropsy, however, but little evidence was

* Veit includes in his tables Parona's "melanotic spindle-celled sarcoma," with reference—'Annal. Univ. Med.-Chir. Milano,' 1887—but, like myself, was unable to obtain a copy of the original report. Most probably Parona's case resembled those described by Horn and Morestin.

† Since the above observations were written I have come across a third case, recorded by Dr. Boldt ("Primary Melanotic Sarcoma of Posterior Vaginal Wall," with a photogravure. Report of a meeting of the New York Obstetrical Society, 'Amer. Journ. Obstet.,' October, 1906, p. 550). The patient was a nullipara, aged 37; the tumour was sessile and made up of "small round-cells"; the deeper were "laden with dark pigment." Rapid recurrence followed removal. This case would hardly induce Horn and Morestin to alter their views as to the origin of the pigment.

found of inflammation, and there was no trace of pus in the stump or round about it. On the other hand, there were no inflammatory changes in the kidney which I removed nor, as far as I am aware, does the development of abnormal adrenal tissue cause perspirations.

The true cause of this symptom was, in all probability, septic infection from the sloughing vaginal growths, a complication noted by Howard Kelly in his 'Operative Gynæcology' (vol. i, 2nd ed., p. 332): "There is a great tendency in all of these tumours to undergo necrosis, and this, together with the foul discharges, opens up an avenue for the entrance of an infection, which in the end often causes death." The vagina was kept as clean as possible after the operation, but a considerable amount of absorption was inevitable. The speedy removal of the growths shortly after the nephrectomy might have given temporary relief, but the patient would not consent to any further operation. When I removed the kidney the patient was in a state of collapse after I had secured the numerous vessels divided when the upper part of the tumour was set free. Removal of the vaginal growths, which would have required free dissection of mucous membrane around all of them, was, therefore, unadvisable.

Cancer of the vagina.—A cancerous vaginal growth does not tend to assume a polypoid form,* so that I need not dwell on that type of tumour.

Adrenal Sarcoma or Hypernephroma of the Kidneys.

In the present case the primary seat of the new growth was the kidney, and the structure of the new growth resembled that of the supra-renal capsule. There were secondary adrenal tumours in the vagina, one of which was clinically conspicuous; these new growths may put us in mind of Eastwood's case of adrenal tumour of the uterus, but in that instance the tumour was primary.

* One exceptional case has recently been reported by Dr. Macnaughton-Jones.

The above facts compel us to dwell for awhile on a very intricate subject. Numerous monographs and essays on adrenal tumours have been made public since that not very remote period, the dawn of the twentieth century.

We are not concerned with certain tumours of the supra-renal capsule itself, new growths observed in children and associated with abnormal growth of hair and other marked anomalies. Bulloch and Sequeira have written much about these new growths arising in the supra-renal capsule ; we must at the same time remember Knowsley Thornton's case, where the patient was an adult, a lunatic, aged 32. The face and extremities were extremely hairy. The preparation is now in the museum of the Royal College of Surgeons (Pathol. Series 3518 E.).

In the present instance the primary growth lay, not in the supra-renal capsule, but in the kidney, so that we must consider adrenal tumour or hypernephroma of that organ. The best summary by a special authority has been drawn up by Neusser. That writer speaks of excessive proliferation of circumscribed portions of supra-renal substance, giving rise in the first instance to small tumours resembling lipomata, which have been termed supra-renal strumas or adenomata. " These are situated in the cortex of the supra-renal capsule or, more frequently, in accessory glands occurring in the kidney. In the latter situation the term renal adenoma or ' heterologous renal struma ' has been applied. They are small masses, varying in size from a pin's head to a pea, yellowish-white in colour, sharply defined and surrounded by a connective-tissue capsule. They are histologically identical with the supra-renal cortex, even the typical fatty infiltration of the parenchyma being present." In addition to this formation of metastases, in itself a manifestation of malignancy, supra-renal strumas, after existing for a long period of time, tend to assume malignant characters. These malignant growths become vascular, almost telangiectatic. They are subject to degenerative changes, all but exclusively fatty. Hæmorrhagic cysts thus develop.

I have already referred to these changes observed in supra-renal "rests" when commenting on Klein's case of vaginal tumour. A clear general summary of the characters of accessory adrenal tissue in the kidney will be found in the sixth edition of Mr. Bland-Sutton's 'Tumours Innocent and Malignant,' page 111. Great attention should be paid to that author's observations at page 116, warning us against confusing primary tumour of the supra-renal capsule with primary tumour of adrenal "rests" developing in the kidney. The fallacy is due to a very natural notion "that some of these tumours arise in the adrenal and gradually become incorporated with the adjacent parts of the kidney."

Such an error might readily arise from a hasty inspection of the kidney which I removed in the case under consideration. Anteriorly the new growth appears to be separated from the upper pole of the kidney by a distinct groove,* so that it looks like a supra-renal capsule considerably enlarged (Pl. XV, fig. 2). But posteriorly there is no such groove, and when the cut surface of the kidney is inspected it becomes evident that the tumour lies inside the renal capsule, and has nothing to do with the anatomical supra-renal capsule (Pl. XVI, fig. 3). I may call attention to Mr. Waring's very similar specimen in the museum of St. Bartholomew's Hospital (No. 2390, G. 2), where externally the tumour seems at first sight to lie in the supra-renal capsule, on the top of the kidney, though it really lies in the kidney itself.

When, however, we turn to another specimen in the same museum (No. 2320 G.) we find a tumour of the same type, but it lies on the *lower* pole of the affected kidney.† I inverted the bottle containing this specimen,

* These remarks require modification, as far as my specimen is concerned, since the position of the ureter was accurately defined (see above, p. 188). There can be no doubt, however, that in Mr. Waring's specimen the tumour lay in the upper pole of the kidney.

† See also Fig. 6 in Owen Richards' "Growths of the Kidney and Adrenals" ('Guy's Hospital Reports,' vol. lix), where the tumour occupies the lower pole (Golding-Bird's case). Richards, however, is not absolutely certain of the nature of the tumour.

when I examined it, and then it struck me how very much the tumour resembled a diseased supra-renal capsule on the top of the kidney. Several other instances of adrenal tumours in the lower pole of the kidney have been recorded (Eastwood, etc.*). They are good object lessons, settling the once disputed question on naked-eye evidence. For the supra-renal capsule is not in the habit of growing on the lower pole of the kidney, and in No. 2390 G. "both supra-renal bodies were present in their normal positions." On the other hand, in cases of tumour of the supra-renal capsule itself, the kidney is as a rule quite intact (Bulloch and Sequeira, Adams; see also Knowsley Thornton's specimen, Museum R.C.S., Path. series 3597 B.)

The invasion of the lung in my case is a complication already noted in association with "hypernephroma" of the kidney; indeed, it is frequent, because, as Bland-Sutton observes, the tumour is apt to invade the renal vein or its branches. This question of the advance of the tumour reminds us of another subject of clinical interest. The new growth, it has been asserted, does not tend to invade the renal pelvis. Hence hæmaturia is said to be exceptional.† In one case, Mr. Waring's, which I have already noticed, the patient, a man, aged 47, suffered from "painless hæmaturia on several occasions." On inspecting the kidney in the Museum of St. Bartholomew's Hospital (2930 G. 2) I found that the growth had replaced not only the cortex, but also the upper pyramids, and had reached the renal pelvis.

However, it is hardly necessary for me to dwell any longer on adrenal tumours of the kidney, for there can be no doubt that such was the character of the renal tumour in my case, and that the vaginal growths were secondary like the deposits in the liver and lung.

* An adrenal tumour may stretch the kidneys over its outer surface (Fairbairn), but in that case the observer could hardly be deceived as to the organ in which the new growth had originated.

† I find that, according to Owen Richards, it is not rare, as other writers lead us to believe (twenty-six out of forty-one cases, *loc. cit.*, pp. 245, 247).

References.

Adams, Chas. E.—A Case of Precocious Development associated with a Tumour of the Left Supra-renal Body. Path. Soc. Trans., vol. lvi (1905), p. 208.

Bulloch and Sequeira.—On the Relation of the Supra-renal Capsules to the Sexual Organs. *Ibid.*, p. 189, with bibliography.

Eastwood.—The Occurrence in the Pelvis of Malignant Tumours originating from Adrenal Remnants. *Ibid.*, vol. liii (1902), p. 153, with bibliography. See also Fairbairn. —A Renal Tumour arising from Adrenal Elements. *Ibid.*, p. 184.

Gow.—Primary Sarcoma of the Vagina. St. Bart's. Hosp. Reports, vol. xxvii (1891), p. 97.

Horn.—Zur Kenntniss primären Scheidensarcome bei Erwachsenen. Monats. f. Geb. u. Gyn., vol. iv (1896), p. 409.

Jellett and Earl.—Primary Sarcoma of the Vagina in an Adult, with the Notes of a Case. Journ. of Obstet. and Gyn. of Brit. Emp., vol. v, p. 230. (With table of thirty-nine cases and analysis.)

Klien.—Lymphangio-endothelioma cavernosum hæmorrhagicum. Archiv f. Gynäk., vol. xlvi (1894), p. 292.

Morestin.—Sarcome de la paroi Recto-vaginale. Bulletins de la Soc. Anatom. de Paris, 1898, p. 431.

Neusser.—Diseases of the Supra-renal Capsules. Nothnagel's Encyclopædia of Practical Medicine, English Edition, 1903.

Smith, R. R.—Fibro-myomatous Tumours of the Vagina. Amer. Journ. Obstet., vol. xlv (1902), p. 145.

Veit.—Das Sarcom der Scheide bei Erwachsenen. Handbuch der Gynäkologie, vol. i (1897), p. 360.

Waring, H. J.—Descriptive List of Specimens Revised and added to the Museum. St. Bart.'s Hosp. Reports, vol. xlii, p. 209 (No. 2390, G. 2).

Williams, W. Roger.—Sarcoma of the Vagina. Journ. Obstet. and Gyn. Brit. Emp., vol. i (1902), p. 400.

Dr. Beckett-Overy (introduced by Mr. Alban Doran) described briefly a similar case, which occurred under the care of Dr. Hugh Playfair at the Metropolitan Hospital, and to whom he was indebted for permission to mention it. The patient, a woman, aged 55, complained of hæmorrhage from the vagina for two months. The climacteric had occurred at 44. On examination a polypoid mass was found attached to the anterior vaginal wall. This was removed in hospital, and a large tumour in the right side of the abdomen was discovered. On microscopical examination of the vaginal growth it was said, after some discussion, to be a very vascular sarcoma. The patient returned to the hospital within two months of the removal of the growth with a recurrence at the previous site, and it was again removed. The patient died a month later, and on *post-mortem* examination the speaker found the following conditions: The right side of the abdomen was occupied by a large tumour which extended into the right iliac fossa almost to Poupart's ligament. The colon had been pushed down and surrounded the tumour on three sides. Above it was continuous with the liver, although clearly defined from the latter. On section the tumour showed a small piece of renal substance at the upper pole, but otherwise it was occupied by a growth measuring at its greatest about five inches by four. The liver, which weighed nearly six pounds, showed a large number of secondary new growths varying in size from a duck's egg to a pea. Many were softening and breaking down, and some showed extensive hæmorrhage. The suprarenal capsule was not affected. The lungs were riddled with a large number of small nodules, but none were degenerating. The vaginal wall was thickened and very dark from hæmorrhage, but showed no obvious new growth. Sections from the various organs showed more or less typical adrenal tissue, the most typical being that in the lungs. On comparing the sections of the vaginal growth with these the likeness was at once seen. There could be no doubt that the original growth was in the kidney, and was a malignant adrenal tumour starting in an adrenal rest. The occurrence of the tumour in the lower part of the kidney, and the remarkable similarity of the primary and secondary growths to adrenal tissue, conclusively proved this. In Mr. Waring's case, where removal of the kidney had been performed early, the patient was alive and well. In his case there was a distinct fibrous capsule intervening between the growths in the supra-renal capsule and that in the kidney, and the tumour was situated in the upper pole of the kidney.

Dr. Lockyer expressed the greatest interest in Mr. Doran's specimen of primary hypernephroma of the kidney, with secondary deposits in the vagina, liver, lung, and omentum. He had studied the growths most carefully from sections prepared by himself, and quite agreed with the diagnosis arrived at by Mr. Shattock

from the sections made at the College of Surgeons—viz. that the growth in the kidney was of the nature of an adrenal inclusion. Now, these tumours, when malignant, more frequently took on the form of sarcomata than carcinomata, but from the cytology and general arrangement of the cells of this growth, shown by Mr. Doran, Dr. Lockyer was disposed to think that it should be classed as an adrenal carcinoma. That very day Dr. Lockyer had, with the assistance of Mr. Ewan Stabb, removed a large renal tumour, together with a (?) sarcomatous fibroid of the uterus, and a parovarian cyst—all from the same patient. Frozen sections had been prepared from the renal growth, which showed it to be a hypernephroma, but of a totally different type to that shown by Mr. Doran. Those who studied Mr. Doran's sections and the sections from Dr. Lockyer's case side by side would be struck at once by the benign character of the latter. It is obviously an adenoma derived from adrenal tissue. This growth had been clinically watched by Dr. Lockyer for six months, whilst the fibroid of the uterus had been observed and measured regularly for the past nine or ten years. The latter tumour had decreased in size with the menopause (the patient is now aged 57 years), but she came complaining that vaginal hæmorrhage had started again, with great pelvic pain. It was then—six months ago—that the renal growth was discovered, and Dr. Lockyer feared that it might be a sarcoma secondary to this change occurring in the shrunken fibroid; this idea seemed the more likely, as the upper pole of the uterine growth had become softer than formerly. Fortunately, this was not the case, and, whatever the nature of the uterine growth, the hypernephroma of the kidney showed a benign structure under the microscope, and shelled out from its capsule during operation with the greatest ease.

Mr. Alban Doran, in reply, trusted that Dr. Beckett-Overy would publish a full account of his important case, similar in many respects to that which had been brought forward that evening. Mr. Bland-Sutton, in inspecting his (Mr. Doran's) vaginal tumour, had expressed to him some suspicion that it might, after all, have been the primary growth, or that the case might be interpreted as a general malignant degeneration of adrenal rests in the kidney, vagina, and elsewhere.

JUNE 5TH, 1907.

HERBERT R. SPENCER, M.D., President, in the Chair.

Present—51 Fellows and 4 visitors.

Books were presented by the St. Thomas's Hospital Staff and by the Staff of the Society of the New York Hospital.

John Prescott Hedley, M.B., B.C., was admitted a Fellow.

The following candidates were proposed for election: Sorab Kaikhoshru Engineer, M.R.C.P.E., L.R.C.S.E., L.M.&S.Bomb. (Edinburgh); Maneckji Piroshaw Kerrawalla, M.D.Brux., L.M.&S.Bomb.; Stanley Dodd, M.A., M.B., B.C.Cantab.; and Somerville Hastings, M.B., B.S.

Report of the Pathology Committee on Dr. May Thorne's Specimen of Uterus showing Malignant Villous Tumour and a Fibroid undergoing Sarcomatous Change (see p. 181).

WE have examined this specimen and the microscopic sections taken from it, and agree that the growth in the wall of the uterus has the structure of a fasciculated spindle-celled sarcoma in which there are no giant cells.

We find no evidence that this growth originated in a fibro-myoma. We also agree that the villous growth is a carcinoma of endometrium.

(*Signed*) Alban Doran.
Cuthbert Lockyer.
G. Bellingham Smith.
Herbert R. Spencer.
J. H. Targett.
May Thorne.
Herbert Williamson.
Corrie Keep.
W. S. A. Griffith, *Chairman.*

Report of the Pathology Committee on Mr. Alban Doran's Specimen of a Malignant Vaginal Polypus secondary to an Adrenal Tumour (*see p.* 182).

We have examined this specimen and the microscopic sections taken from the vaginal polypus and the kidney, and agree that the primary tumour is a carcinoma originating in an adrenal rest of the kidney, and that the vaginal polypus is a secondary deposit of a similar nature.

(*Signed*) Alban Doran.
Cuthbert Lockyer.
G. Bellingham Smith.
J. H. Targett.
Herbert Williamson.
Corrie Keep.
W. S. A. Griffith, *Chairman.*

TWO CASES OF PREGNANCY IN A RUDIMENTARY UTERINE HORN.

By Dr. Henry Russell Andrews.

(1) Suppuration in a Pregnant Rudimentary Uterine Horn Five Months after the Death of an Eight Months' Fœtus.

On October 18th, 1906, I was asked to see a patient with severe vomiting during pregnancy, to decide whether labour should be induced prematurely. The patient was a primigravida, supposed to be seven calendar months pregnant, the last period having begun on March 19th. Before her marriage she had had two severe attacks of vomiting lasting for several weeks, said to be due to gastric ulcer. Towards the end of April, 1906, *i.e.* when five or six weeks pregnant, she began to vomit again, and the vomiting was so severe that she was fed *per rectum* for six weeks. During July, which she spent at the seaside, there was no vomiting, but on her return home the vomiting began again. She had no pain of any sort. Before the pregnancy began, in December, 1905, she weighed 7 st. When I saw her in October, 1906, her weight was only 4 st. 8½ lb. She was emaciated, weak, and very nervous. The uterus reached up to three inches above the umbilicus. The fœtal heart was heard. The fœtus seemed to be smaller than would be expected at thirty weeks. Bimanual examination revealed nothing abnormal. I said that induction of labour would probably kill the patient, and that as the child was so small it would not be likely to live. The patient was admitted into the London Hospital on October 20th. The vomiting ceased almost entirely from the first; on the third, fourth, and fifth days she did not vomit at all, and after this she vomited on an average once in every twenty-four hours. A

week after admission she was taking mince, chicken, eggs, etc. She improved rapidly, put on one stone in weight in a month, and returned home on November 17th. The fœtal heart was heard on the day before she left the hospital. Only one vaginal examination was made, to see whether there was any tumour in the pelvis.

I heard no more of the patient until April, 1907, when I was told that she had not been delivered, and that she was very ill, with a temperature of 102° F. She was re-admitted to the hospital on April 18th, 1907, when the following history was obtained: On November 19th, two days after her return home, a blood-stained vaginal discharge began, and she had very severe abdominal pain coming on every five minutes for about an hour. She sent for a doctor, who removed several pieces of what he called "dead and bloodless placenta." As the blood-stained discharge persisted he examined the patient under chloroform, but found nothing abnormal. The patient felt no fœtal movements after leaving the hospital. After a few days the bleeding stopped, and the abdominal swelling began to get smaller. The vomiting ceased altogether, and the patient began to put on flesh again. At this time she began to suffer from fits, which her doctor believed to be hysterical. Early in April, 1907, she became ill, and sent for another doctor, who wrote to me about her. For three days before admission the stools had been extraordinarily offensive. On admission, on April 18th, she was flushed, but looked better than when I saw her last, and weighed 6 st. 4 lb.

Her temperature was 102° F. The abdomen contained a rounded swelling, fixed and tender, in the middle line reaching up to 1½ in. above the umbilicus. A "crackle" could be felt over it on palpation. Small, hard irregularities could be felt in it.

On vaginal examination the tumour could not be separated from the cervix. What felt like the fundus of an unimpregnated uterus could be felt projecting from the left side of the tumour low down.

A diagnosis of suppuration in a pregnant rudimentary horn was made, and I proceeded to operate.

When the patient was anæsthetised a sound was passed $2\frac{1}{2}$ in. into the small projection, which was taken for the left half of the uterus.

On opening the abdomen a yellowish tumour was seen adherent to anterior abdominal wall, omentum, sigmoid colon and rectum. It smelt so horribly directly the abdomen was opened that I thought that its wall must be very thin, and packed the abdominal cavity with a sterilised towel as well as gauze swabs. In dissecting the rectum off the tumour the wall of the sac gave way and there was a gush of the most horribly offensive pus. The tumour was then brought up as much out of the abdomen as possible and incised, the placenta and fœtus and much pus being removed. The tumour was then removed as rapidly as possible. As it became possible to distinguish structures the tumour seemed to be an ordinary uterus. It was amputated at the level of the internal os so as to get the septic mass out of the abdomen as soon as possible, and then the cervix was removed. The pelvic cavity was swabbed out and a large rubber drainage-tube was inserted, one end projecting out of the abdominal wound and the other out of the vagina. The head of the bed was raised on blocks.

The patient made a slow but sure recovery and left the hospital on May 24th, five weeks after the operation. In the first fortnight after the operation she had several fits, with rigidity and loss of power in the right arm, and loss of consciousness. There was slight optic neuritis. Dr. Henry Head, who kindly saw the patient, thought that she had a septic cerebral embolus. Before she left the hospital the right arm had regained its power, and there had been no fits for three weeks.

The specimen shows the small uterine cavity on the left side and the large right horn. At the operation the right round ligament was seen coming off from the right side of the pregnant horn, but now that the tissues have

shrunk it is impossible to identify it. Both ovaries and tubes can be seen adherent to the right horn. The junction between the two horns is broad and thick. The fœtus, which is much decomposed, measures 17 inches in length. There is not much left of the placenta.

My experience in this case would make me unwilling to leave a full-term extra-uterine pregnancy alone in the hope that no further trouble would result. I should prefer to operate about a couple of months after the death of the fœtus. This would mean that in a certain number of cases the operation would be performed unnecessarily, but the operation is then not attended by much risk, while if one waits until there are indications that suppuration has occurred in the sac the danger must be increased greatly.

(2) Rupture of a Pregnant Rudimentary Uterine Horn at about the Eighth Month.

On May 6th, a primigravida, aged 32, was sent into the London Hospital with a diagnosis of concealed accidental hæmorrhage. Her last period ended on September 5th, 1906, and she considered that she was eight months pregnant. There were no unusual symptoms during the pregnancy until May 5th, the day before her admission to hospital, when at about 6 p.m. she was seized with sudden violent abdominal pain, which became constant. During the night and the next day she vomited frequently, and fainted four or five times, generally as the result of sitting up. Slight bleeding from the vagina began soon after the onset of the pain.

When I saw her at 5.45 p.m. she was blanched, restless, and very thirsty. The respirations were "sighing," the pulse was almost imperceptible at the wrist, the heart-beats were 140 per minute. The abdomen was distended, tender all over. There was diminished resonance in the flanks, but no dulness on percussion, except over a firm, rounded tumour, which reached out of the pelvis to a point

just above the umbilicus. Fœtal parts were not palpable and the fœtal heart was not heard. The whole abdomen felt firm, as if it contained some fairly solid substance rather than fluid.

The cervix was as soft as the normal cervix in the later months of pregnancy. The tumour in the abdomen could not be separated from the cervix. Continuous with the cervix, and inseparable from the large tumour attached to its left side, was a mass the size of the body of the uterus at two months. Into this the sound was passed 3 inches.

Diagnosis.—It seemed probable that the condition was due to the rupture of a pregnant rudimentary uterine horn. There was no doubt that there had been severe intra-peritoneal hæmorrhage, although the condition of the abdomen was not quite typical of recent bleeding.

Operation.—On opening the abdomen enormous clots, practically a cast of the abdominal cavity, were removed. The right horn of the uterus, which looked exactly like a pregnant uterus at six months, had a small rupture at its upper part through which placenta could be seen. As the tumour was pulled out of the abdomen this rupture became considerably enlarged by tearing. The right horn was attached to the left half of the uterus by a thin band of tissue about 2 inches broad. This band and the broad ligament on the other side were clamped by two pairs of forceps and the right uterine horn was removed. The clamped tissue was then sewn over, the vessels being tied separately. The round ligament came off the right side of the pregnant horn. The remaining blood-clots were removed, and the abdominal cavity was filled with saline solution.

In spite of everything that could be done the patient died about an hour and a half after the operation.

By the time the operation was over the horn had almost completely delivered the intact ovum through the rent, contracting like a normal uterus. The wall of the horn was thick muscular tissue except close by the site of rupture,

where it was so thin as to be translucent. The fœtus appeared to be of less than seven months' development. Unfortunately the right horn and the ovum were thrown away by mistake. The left half of the uterus was removed at the *post-mortem* examination. The attachments of the right horn can be seen.

Rupture occurred unusually late in this case, as although the fœtus did not appear to be of much more than six months' development, the history pointed to the patient's being eight months pregnant. It was much to be regretted that so much valuable time—nearly twenty-four hours—was lost before she was sent to the hospital.

Miss Garrett Anderson was specially interested in the cases reported by Dr. Andrews, because she had lately operated upon a patient with cornual pregnancy. The gestation sac lay in the undeveloped right horn of a double uterus. It corresponded to the size of a two months' pregnancy. The pregnant right horn was closely attached from fundus downwards to the left horn, and thick flaps of muscle had to be cut in order to separate it from the functional and patent left side of the uterus. Mattress sutures controlled the bleeding. The right ovary contained a recent corpus luteum. There was no communication between the right horn and the exterior.

RUPTURE OF THE HEART IN A STILL-BORN INFANT.

Shown by Dr. C. Nepean Longridge.

The case was one of shoulder presentation at full time, admitted to Queen Charlotte's Hospital with a prolapsed and pulseless cord. Craniotomy was performed, and powerful traction was necessary to extract the child, which weighed 9 lb. 5 oz. without the brain. Half an ounce of blood was found lying free in the pericardial sac. There was a rupture at the junction of the inferior vena cava and the right auricle.

DILATED URETERS IN STILL-BORN INFANTS.

Shown by Dr. C. Nepean Longridge.

In the last twenty autopsies on infants at Queen Charlotte's Hospital he had found this abnormality no less than eight times. Six of the cases were male infants. Both ureters were dilated in four cases, the left only in three, and the right only in one. The specimen shown was removed from a female infant, and was doubly interesting on account of the fact that there was a double ureter on each side. In most of the specimens the ureter was dilated throughout its whole length, and in the others only that portion which lay above the brim of the pelvis was dilated. In no case was any stone or obstruction found in the urinary passages. He had found great distension of the rectum by meconium in several of the cases, and considered that the probable explanation of the abnormality lay in the fact that the ureters were compressed between the full bladder and rectum.

Dr. Gray asked Dr. Longridge if he had found any atrophy in the abdominal muscles in his cases. He (Dr. Gray) had met with three cases in infants in which the muscular layers of the anterior abdominal wall were almost completely atrophied, and this was associated with enormous dilatation of both ureters. The kidneys were smaller than normal, and the bladder contracted and its muscular wall much hypertrophied, but no obstruction to the passage of urine could be found. A careful examination of the central nervous system had, he believed, been made and nothing abnormal found. The children were males; one of them had lived to be eight months old, but the other two only a week or two. As far as he was aware no satisfactory explanation had been forthcoming to explain these cases.

THE PELVIC ORGANS OF A CASE WHERE INOPERABLE PAPILLOMA OF THE LEFT OVARY HAD BEEN FOUND SEVEN YEARS PREVIOUSLY.

Shown by Dr. Amand Routh.

Dr. Amand Routh showed the pelvic organs (fibroids) removed by laparotomy from a woman, whose abdomen had been opened by him seven years previously, but was closed again without anything being done owing to a large papilloma of the left ovary which it was impossible to remove.

The following is the history of the case.

Miss E. L—, in 1897, when aged 38, complained of pelvic pain and of menorrhœa, and a pinky discharge every morning on rising.

December 17th, 1898.—Left ovary is enlarged and tender and prolapsed.

February 14th, 1899.—Brownish, watery discharge, now almost continuous. More pelvic pain. Left ovary larger and left Fallopian tube thought to be dilated.

February 1st, 1900.—Not seen for twelve months. Semi-solid, though elastic mass behind uterus, extending to sides of pelvis. Some recent pyrexia and chilliness. Diagnosis was that of either pyosalpinx or left ovarian growth, and as patient would not consent to abdominal operation unless absolutely necessary, I first curetted the uterus and then opened Douglas's pouch *per vaginam*, Dr. Eden assisting me (February 8th, 1900).

We then found that the pelvis was full of a papillomatous mass which appeared to have invaded the cellular tissue on the left side. The abdomen was thereupon opened, and what appeared to be a malignant papillomatous mass was seen filling the pelvis. Nodules were felt above the pelvic brim, and both these and those in

the pelvis appeared to have invaded the subperitoneal connective tissue. The fundus uteri could be distinguished embedded in the growth, but the right ovary could not be located. There were a few nodules on the omentum and parietal peritoneum. Under these circumstances a diagnosis was made of a papillomatous growth arising from the hilum of the left ovary with proliferation into the peritoneal and sub-peritoneal connective tissue, and it was decided to make no attempt to remove the growth. Unfortunately no piece was removed for microscopical examination.

The patient made a good recovery from the operation, but a month afterwards, just as she was about to leave the home, she had an attack of what was thought to be influenza with pleurisy, and Dr. Mitchell Bruce diagnosed an empyema on the right side. Mr. Stanley Boyd treated this by incision and drainage. The patient made a slow recovery and left the nursing home well on May 1st, 1900.

In June, 1901, sixteen months after the operation, she stated that her periods had been regular, but that she now always had a copious watery blood-stained discharge between the periods. On bi-manual examination the uterus was found to be distinctly enlarged but mobile, and no traces of any pelvic growth could be felt, except some induration in left broad ligament.

In June, 1905, the uterus was much larger and nodular, and fibroids were evidently present. As the watery discharge continued, and there was also menorrhagia, I explored the uterine cavity and curetted the lining membrane, but only hypertrophied glandular tissue was found (Lockyer).

After this the fibroid uterus continued to enlarge, and irregular hæmorrhage became frequent, and the periods themselves were very profuse and her general health was getting worse.

On May 1st, 1907, therefore, I removed the uterus and appendages, and I now show the parts removed. At the operation there were numerous adhesions in the true

pelvis, and the general peritoneal cavity was quite shut off from the true pelvis by universally adherent bowels and omentum.

The left ovary was embedded in adhesions at the back of the broad ligament and is small and cirrhotic. I append Dr. Lockyer's report of the specimen.

Report on the Specimen.

The specimen consists of the uterus and its entire appendages. The uterus is much distorted by the presence of numerous fibroids, there being eight distinct and separate tumours in its walls. None of these growths have attained any great size, the specimen as a whole weighing only two pounds. The largest fibroid occupies the left anterior wall of the uterus and lies in front of, and parallel with, the left appendages. At each cornu is situated a subperitoneal fibroid, each growth having the size of a small Tangerine orange. On the top of the fundus between these two lies another smaller subperitoneal growth. The centre of the anterior uterine wall is occupied by an interstitial fibroid. The cavum uteri is opened up by two submucous growths, and finally an interstitial growth projects from the cervix below and to the left of the point of amputation.

The Fallopian tubes are sealed off and distended, the left forming a thin-walled sac in its outer two thirds, whilst the right is thickened throughout. Both tubal sacs on section exuded a thick, grumous material, from which no organism could be grown upon any of the ordinary culture media.

The left ovary is represented by a hard, fibrous mass measuring 1 in. by $\frac{1}{2}$ in. The right ovary appears normal to the naked eye. The entire specimen in the hardened state measures 4 in. from above down, and 5 in. from side to side.

The right ovary measures 1 in. by $\frac{5}{8}$ in. in its two diameters. Its tunica and cortex are thickened; the

latter contains a few degenerate follicles. The stroma presents many corpora albicantia. The vessels at the hilum are thickened throughout, all changes pointing to the presence of chronic oöphoritis. The remains of the left ovary contain no gland-elements. The ovarian stroma is reduced to a minimum, being replaced to a great extent by dense hyaline fibrous tissue. The uterine segment of the right tube shows fibrosis and round-celled infiltration, the fimbriæ are distended with leucocytes, but their epithelium is intact. The uterine end of the left tube shows the same inflammatory changes, but to a less degree.

CUTHBERT LOCKYER.

I thought the specimen interesting in view of the history of the inoperable condition found in 1900, more especially as the left ovary, which was then considered to be the source of the papillomatous growth, is now found to be entirely fibrous tissue with no trace of ovarian structure.

Whether the severe illness from which she suffered (empyema) a month after the operation had anything to do with the disappearance of the growth, or whether it is one of those cases which so unaccountably get well after the abdomen is opened, without anything being done, is, of course, doubtful. The patient is now quite well.

The PRESIDENT thought the disease might have been tubercle, which sometimes assumed the papillary form.

MYOMATOUS UTERUS WEIGHING OVER SEVEN POUNDS, REMOVED FROM A WOMAN AGED 22.

Shown by Dr. HERBERT SPENCER.

(With Plate XIX.)

THE specimen was shown on account of the large size of the tumour and the youth of the patient, and the fact that in appearance at the operation the tumour closely

resembled a pregnant uterus. Nine years ago he had brought before the Society all the cases he had been able to find recorded (forty in all) of fibro-myoma occurring in women under twenty-five years of age, together with two cases of his own, one of which weighed 4 lb. 9¾ oz. Dr. Russell Andrews had published a case of a fibro-myomatous uterus weighing 4 lb. 5 oz. occurring (like his own) in a Jewess, aged 20. Most of the tumours recorded, however, were small, and it was on account of the rarity of such a large tumour in a young subject, and its resemblance to the pregnant uterus, that he desired to record the case. The following are the notes:

F. G—, a Jewish virgin, aged 22, born on March 20th, 1884, as shown by her birth certificate, was seen on December 15th, 1906. She complained of hæmorrhagia, dysmenorrhœa, and enlargement of the abdomen.

Menstruation began at the age of thirteen, and had been regular every four weeks since. At first it lasted one day, but for the last three years it had lasted five days, during the first two of which there had been pain in the left side of the abdomen.

The patient had typhus at the age of nine, and when she was thirteen she was treated at St. Bartholomew's Hospital for rheumatism.

She was admitted to University College Hospital on December 18th, 1906, and looked healthy and not anæmic. The breasts were virginal. The hymen was intact and its opening very small, rendering examination difficult.

The abdomen was distended, measuring, 3 in. below the umbilicus, 31 in. in girth. From the umbilicus to the anterior superior iliac spine measured 6¼ in. on each side.

The distension was caused by a tumour which reached up to 3 in. above the umbilicus and had almost the shape and consistence of the pregnant uterus, but differed in that the lower segment was specially prominent, that the left cornu of the uterus felt rather harder than the rest of the organ, and that neither ballottement nor uterine souffle could be obtained. The tumour felt cystic to

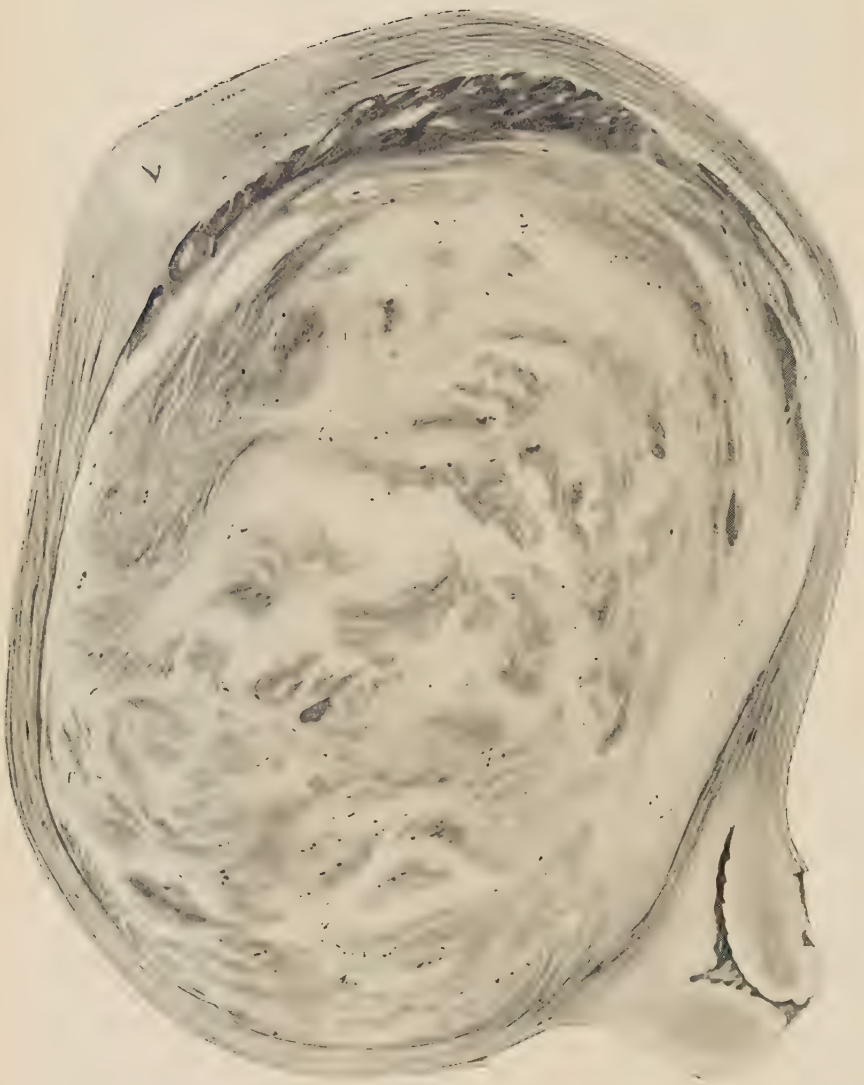

Illustrating Dr. Herbert Spencer's Specimen of Myomatous Uterus weighing over Seven Pounds, removed from a Woman aged 22.

Adlard & Son, Impr.

DESCRIPTION OF PLATE XIX,

Illustrating Dr. Herbert Spencer's specimen of Myomatous Uterus weighing over Seven Pounds, removed from a Woman aged 22.

The line of the uterine cavity is distorted by the tumour; it may be inferred from the position of the section of the cornu cut across at the upper left part of the plate. Note the bulging anterior lower segment below. The tumour has undergone mucous degeneration, especially at its upper part.

palpation, and gave a well-marked thrill on percussion. It was dull on percussion. On vaginal examination the cervix was virginal. The uterus appeared to be small; the tumour could not be reached. The relation of the uterus to the tumour could not be made out without an anæsthetic, even by rectal examination. It was not thought advisable to give an anæsthetic as the case was clearly one which required operation; an ovarian tumour was diagnosed.

On December 20th, 1906, Dr. Spencer operated and found that the tumour, in its shape, and colour and consistence closely resembled a pregnant uterus at the seventh month. The only points in which it differed from the pregnant organ were in the fulness of the lower segment (which in the pregnant uterus is usually flat), in the absence of signs of a fœtus, and in the presence of a white patch where the tumour had pressed against the promontory, which he had often observed in the fibroid uterus but never in the pregnant organ. In spite of the close simulation of the pregnant uterus he decided that the patient could not be pregnant, as the breasts, though having pigmented areolæ, were in other respects typically virginal. He considered that the tumour was a degenerated fibro-myoma, and this diagnosis was confirmed on making an incision into it.

The uterus was then removed by total abdominal hysterectomy, the pelvic peritoneum being closed by a purse-string suture.

The abdominal wound, sutured with buried silk (for the fascia), and through stitches of silk-worm gut, healed by first intention, and the patient left the hospital quite well on January 22nd.

On bisecting the uterus, which weighed 7 lb. 7 oz., it was found to be invaded by an intra-mural fibroid which originated in the right wall and had undergone mucous degeneration. This degeneration was especially marked at the upper part of the tumour, where it formed a gelatinous layer half an inch in thickness (see plate).

Microscopic examination confirmed the naked-eye diagnosis.

OVARIAN PREGNANCY (?).

Shown by Henry Briggs, M.B., F.R.C.S.

Mrs. N—, an active, athletic woman, aged 33; the mother of one child, ten years old.

Previous history good. Since the patient's only confinement there had been chronic retroversion of the enlarged uterus without symptoms, with secondary sterility for which she had often consulted her doctor, who had, at intervals, placed a Hodge pessary, or dressed the uterus with iodine.

History.—Menses regular; the last period, which commenced on February 26th and ended on March 6th, 1907, was of longer duration and a little more painful than usual.

Irregular bleeding ensued on March 12th and 13th (two days), on March 16th (one day); on this occasion the hæmorrhage was accompanied by severe pain, vomiting, and collapse; bleeding again on March 17th, and the following three days (four days).

Physical signs.—A fulness in the right lateral fornix was observed on April 3rd by Dr. Matthews. The physical signs were faint and indefinite. There was no fixation of the uterus or its appendages.

Operation on April 8th, 1907, by a short abdominal incision: two ounces of free, dark, intra-peritoneal fluid blood, and the right tube and ovary were removed. The presence of chorionic villi within the blood-clot was proved by the microscope. The capsule of the ovary was contained over the ovarian attachment of the blood-clot. The blood-clot elsewhere was merely additional to this bursal portion.

The specimen was referred to the Pathology Committee (*see p.* 256).

EARLY TUBAL MOLE.

Shown by Dr. Briggs.

R. S—, aged 35, eight years married, the mother of six children, the youngest aged 2 years.

Menstruation regular.

She was quite well until ten days after the last menstrual period; violent pain in the left lower abdomen, local tenderness, a dark, blood-stained vaginal discharge and general faintness occurred. She had four attacks of severe pain and a continuous blood-stained discharge before the operation of abdominal section twenty-one days later, May, 31st, 1907.

Before operation the diagnosis of ectopic gestation was founded on the locality and character of the pain and on the hæmorrhage, together with a fulness in the left posterior quarter of the pelvis which pushed and slightly fixed the uterus to the right side. One and a half ounces of free fluid blood were present in the peritoneal cavity. The ampullary portion, 1 in. × $\frac{5}{8}$ in., of the left tube contained a small mole.

FIBROID TISSUE FORMED AROUND A NEEDLE AND REMOVED FROM THE LEFT LABIUM MAJUS.

Shown by Dr. Briggs.

The specimen consists of an elongated mass of fibrous and fatty tissue, 2 in. × $\frac{1}{2}$ in., and in it are embedded the two pieces of a darning-needle.

Clinical history.—The spindle-shaped tumour, reaching 1 in. below the external abdominal ring downwards in the left labium, was said to have existed for six weeks. The needle as its cause could not be traced.

The patient was aged 33.

PRIMARY EMBOLIC CHORION-EPITHELIOMA OF THE VAGINA.

By Henry Thomas Hicks, F.R.C.S.Eng.

(Received December 17th, 1906.)

(With Plates XX–XXII.)

(*Abstract.*)

The paper is founded on a case of primary chorion-epithelioma occurring in the vagina of a woman æt. 28 years. A hydatid mole was passed and the growth accidentally discovered about a month later. There was no evidence of primary uterine growth. The sections show that the growth has the structure of a chorion-epithelioma, but no villi are seen. Fourteen other cases have been collected from the literature on the subject, and the question of the degree of malignancy of this form of growth is discussed, as well as the theories as to the origin of the vaginal growths. The time at which the growth may appear in relation to the gestation is also mentioned in the paper.

The patient remained free from growth for seven months after removal of the first growth. The second growth was excised without delay, but two new foci appeared quickly. These were removed, but two months later the anterior vaginal wall became rapidly infiltrated with extensive growth, and it was decided that further operation would be hopeless. The patient, who up to this time had been comparatively well, now went downhill with great rapidity. The growth commenced to fungate into the vagina in many places, causing hæmorrhage. The temperature rose, and signs of pulmonary trouble became evident. The patient died on May 8th, 1907, eleven months after the passage of the mole.

The specimen removed at the autopsy is shown, together with

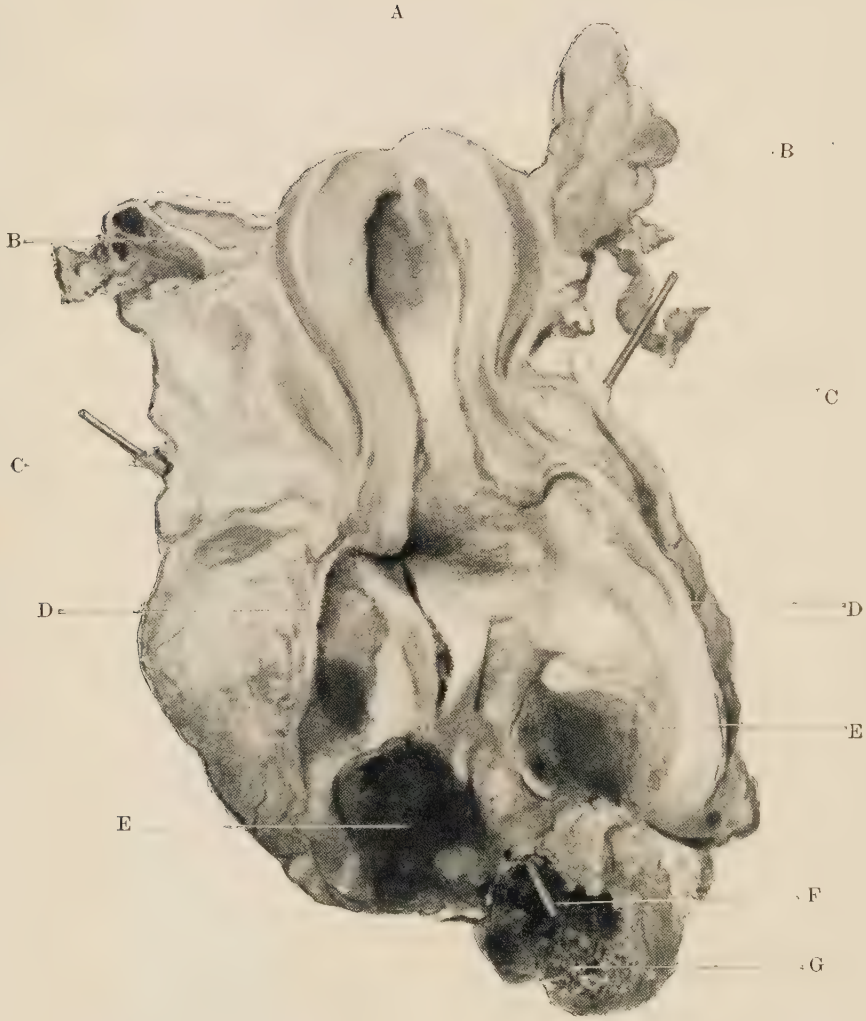

Illustrating Mr. H. T. Hicks's paper on Primary Embolic Chorion-epithelioma of the Vagina.

Adlard & Son, Impr.

DESCRIPTION OF PLATE XX,

Illustrating Mr. H. T. Hicks's paper on Primary Embolic Chorion-epithelioma of the Vagina.

A. Uterus free from growth. B. Ovaries and Fallopian tubes C. Ureters. D. Cut edges of vaginal wall. E. Vaginal growth F. Urethra. G. Growth involving clitoris.

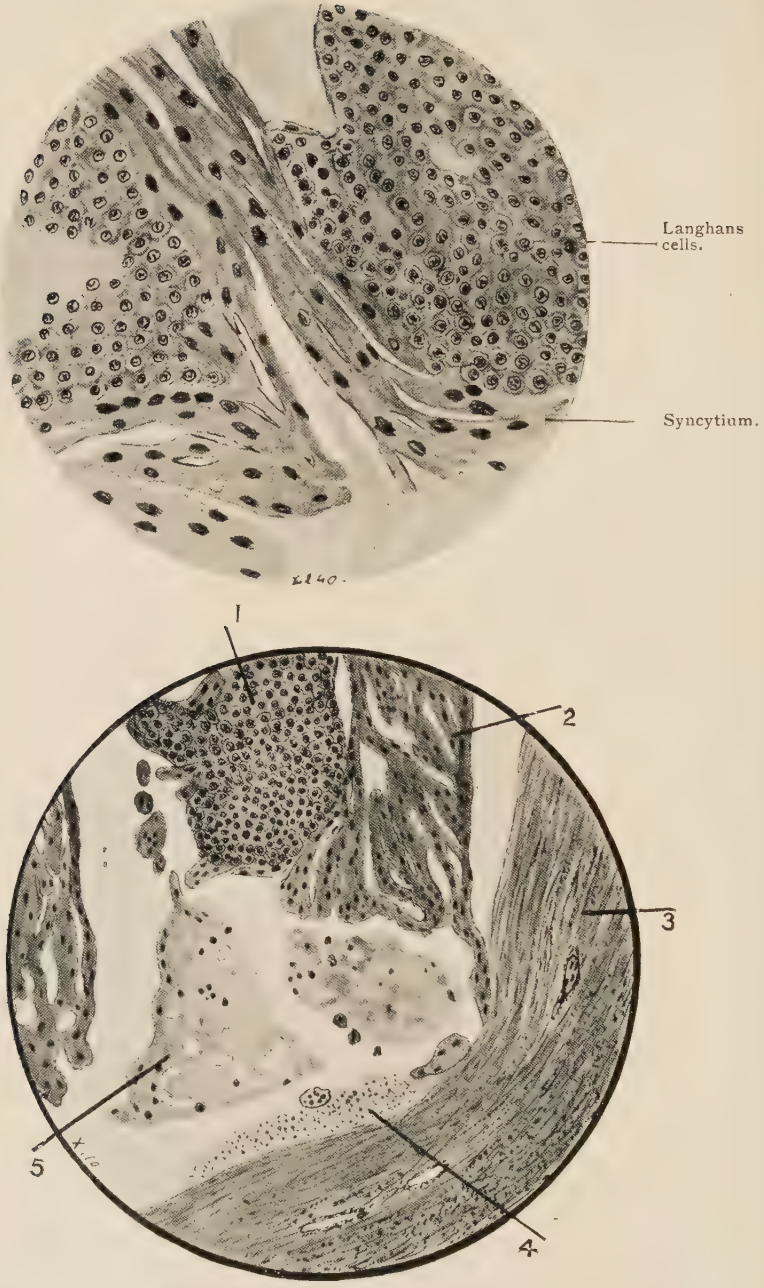

Illustrating Mr. H. T. Hicks's paper on Primary Embolic Chorion-epithelioma of the Vagina.

Adlard & Son, Impr.

DESCRIPTION OF PLATE XXI,

Illustrating Mr. H. T. Hicks's paper on Primary Embolic Chorion-epithelioma of the Vagina.

1. Mass of Langhans' cells. 2. Syncytium. 3. Vaginal wall. 4. Blood and fibrin. 5. Degenerating mass of syncytium.

Illustrating Mr. H. T. Hicks's paper on Primary Embolic Chorion-epithelioma of the Vagina.

Adlard & Son, Impr.

DESCRIPTION OF PLATE XXII,

Illustrating Mr. H. T. Hicks's paper on Primary Embolic Chorion-epithelioma of the Vagina.

A. Vaginal epithelium. B. Vaginal wall. C. Syncytium. D. Langhans' cells. E. Hæmorrhage with degenerating syncytial cells.

sections and drawings of the growth. Some secondary nodules were found in the right lung.

Primary chorion-epithelioma of the vagina is of such great interest and the recorded cases so few that I venture to bring this case before the Society, hoping it may help to throw some light on this rare condition.

E. J—, aged 28, was admitted into Guy's Hospital on July 10th, 1906, for pain in the left chest and dyspnœa.

Previous history.—The patient was married and had had three children and no miscarriages, and had always had good health up to the present illness. Menstruation had been regular and normal in amount up to seven months before admission, since which time she has had amenorrhœa.

On June 21st she was taken ill with shivering and was found to have left basal pneumonia. The next day she began to bleed from the uterus, and her medical attendant sent for the assistance of the obstetric resident at Guy's Hospital. The cervix was dilated and a large hydatid mole, together with a 5½ months dead, but fresh, fœtus, was cleared out of the uterine cavity. Dr. Crofts, the obstetric resident, gave the following description of the uterine contents:

"There was a fœtus about the age of 5½ months, born dead, but in quite a fresh state and enclosed in the amnion. That part of the placenta to which the cord was attached appeared to be normal, but around the periphery of this normal patch of placenta and all over the general aspect of the chorion there was a marked vesicular formation, which, taken as a whole, formed a large vesicular mole. After clearing out, the uterine cavity was found to be smooth but soft, and there was no evidence in favour of twin pregnancy."

The dyspnœa and pyrexia continued and the patient was admitted into Guy's Hospital under the care of Dr. Taylor. Empyema was diagnosed and drained. The temperature, however, rose at night for some weeks after the operation, and Dr. Taylor thought that the pelvic

trouble might possibly be the cause of the continuous pyrexia.

I saw the patient on July 20th, and found no evidence of pelvic inflammation. There was a blood-stained discharge of dark venous colour which the patient said had been present since the miscarriage in June. The bleeding was not profuse, nor did it increase on examination. The uterus was soft and bulky, giving one the impression that involution had been interfered with. The pyrexia had existed for nearly a month and sub-involution was likely. There was a soft single cyst high up in the left fornix of the vagina of about the size of a big Tangerine orange, and below, on the posterior wall of the vagina about two inches from the vulva, was a small knob about the size of a cob-nut. The upper soft cystic swelling seemed to be a superficial vaginal cyst and was covered with unaltered vaginal mucous membrane. The lower swelling was soft and looked bluish-purple beneath the vaginal mucous membrane.

The question of chorion-epithelioma was raised, and Dr. Taylor agreed to an exploration as soon as the condition of the empyema would allow of it. At first the patient did not progress very satisfactorily, owing to some difficulty in draining the pleural cavity, but the pelvic condition became no worse. There was some slight bleeding from the vagina during the next fortnight, and the lower swelling increased a little in size; the cyst remained unaltered. On August 20th an anæsthetic was given, and the small tumour, which about doubled in size, was removed from the vagina for examination. It was very vascular and some large vessels in the perivaginal tissues had to be underrun. The patient took the anæsthetic very badly. The tumour when removed was about the size of a small walnut, and when *in situ* formed a soft, well-defined swelling placed deeply in the perivaginal tissues close against the rectal wall, and covered on its vaginal aspect with normal mucous membrane. The sections show the normal squamous epithelium of the vagina supported by sub-

mucous tissue. In the deeper parts of the vaginal walls are numerous spaces filled with a cellular growth. The cells are of two distinct varieties. There are patches of closely-packed cells; each cell has a clearly defined nucleus: these are Langhans' cells. Arranged around each pack of Langhans' cells large quantities of syncytium are seen. The syncytium is formed of large branching ribbons of multinuclear protoplasm staining deeply with eosin. In many places the protoplasm has undergone vacuolation, and the characteristic oblong nuclei of the syncytium are swollen and less deeply stained than those seen in the syncytium which has not become vacuolated.

Although as a rule the syncytium keeps to the periphery of each pack of Langhans' cells, in many places small pieces of irregular, multinuclear protoplasm are mixed up with the single nuclear cells. In the deeper parts of the sections the growth is more abundant, and here it is embedded in necrotic tissue and fibrin. There are no chorionic villi to be seen in any of the sections, but it is quite possible that degenerate villi may be hidden by the hæmorrhage and necrosis, which occurs in large areas. Many dilated venous spaces appear in the perivaginal tissues, and some of these are filled with masses of syncytium; the larger spaces contain small clumps of Langhans' cells as well. It seems, therefore, that the growth spreads along the peri-vaginal venous spaces, and the syncytium, as it were, pilots the Langhans' cells along these paths.

September 2nd.—The patient seems very well. There is no bleeding, and the uterus is of normal size. The cyst in the left lateral fornix has disappeared spontaneously, but there is a small dimple at its original site.

September 26th.—As far as clinical examination goes the patient is quite free from growth.

October 24th.—Patient came to-day. There is no evidence of any growth. She has had two normal menstrual periods lasting four days on each occasion.

November 29th.—Patient well and putting on weight. There is no hæmorrhage other than a normal period, and the local condition seems in every way satisfactory.

December 23rd.—Examination was again negative.

Further history of the case.—Vagina remained free from growth until January 8th, 1907, when a small, soft, but well-defined tumour, of about the size of a walnut, was found in the lower part of the anterior vaginal wall. In five days the tumour almost doubled in size, and it was deemed necessary to remove it immediately.

The growth was situated deeply in the perivaginal tissues at the vaginal outlet. In front it bulged towards the vestibule to the right of the urethra, which was displaced forwards and to the left. It was covered on its vaginal aspect with normal rugose mucous membrane.

A transverse incision was made in front of the growth, and the urethra was separated off as high as the base of the bladder and upper limit of the tumour. The whole width of the lower half of the anterior vaginal wall was removed with the tumour. The growth was soft, friable, and hæmorrhagic. There was a thin, but definite capsule on its deep aspect, but at the periphery outlying pockets of growth could be seen in the perivaginal tissues, especially on the right, and the vaginal wall was excised freely in consequence of this infiltration. The cut edges of the vagina and the urethra were brought into position by catgut sutures. Six weeks later a soft perivaginal swelling appeared higher up in front and on the left, which seemed to have no connection with the previous tumour, and was covered with normal vaginal mucous membrane. It was about the size of a walnut and was also removed, but with considerable difficulty, owing to the close relationship of the bladder and the brisk hæmorrhage which occurred at its removal.

Within three weeks another tumour appeared in the posterior vaginal wall, below the site of the first tumour, and the cyst, which had disappeared in August last, refilled, and formed a soft swelling in the left lateral

fornix. The cyst and growth were removed on March 16th, 1907. Some thickening was noted in front beneath the scars in the vaginal wall which was taken to be cicatricial and inflammatory tissue, but in a few days soft growth was found creeping forward along the vestibule to the right of the urethra, and on further examination a soft, diffuse infiltration was discovered in the perivaginal tissues high up on the left in front. There was now no definite tumour formation, but a soft growth spread along the perivaginal tissues in a most insidious manner rendering further operation hopeless. Up to the middle of April the patient's general condition remained good, and previous vaginal growths had given rise to no symptoms. The growth now began to increase rapidly, running forward to the clitoris, enlarging it to about the size of a walnut, and the perivaginal tissues in front became boggy and swollen by infiltrating growth. The patient did not waste much but became very anæmic, and complained of considerable local pain. Menstruation had been regular up till February last, since when there had been no loss of blood.

On April 19th hæmorrhage from the vagina set in for the first time, and the growth was found to be fungating through the vaginal mucous membrane on the left. The patient went rapidly downhill, and signs of bronchopneumonia developed at the base of the right lung, which was taken to be due to pulmonary metastases, but there was no hæmoptysis. The bleeding from the vagina recurred several times, was never severe, and no doubt much of the anæmia was due to hæmorrhage into the growth itself.

The patient died on May 8th, 1907, eleven months after the passage of the mole.

Report of the autopsy.—The body is not much wasted, but very pale. There are no secondary deposits in any of the organs except the right lung. The left lung is firmly adherent to the parietal pleura, the adhesions being the result of the old empyema. The left lung contains no growth. This might be explained by the hampering

action of the pleural adhesions. In the right lung many small hæmorrhagic nodules are present, lying close beneath the surface of the lung and confined to the lower lobe. They vary in size between a bean and small nut.

Local condition.—The clitoris is the seat of a soft hæmorrhagic growth, about the size of a Tangerine orange. Along the right side of the urethra, in the position of the bulbous vestibuli, and to a lesser extent on the left, soft friable growth is seen extending forward from a hæmorrhagic mass in the right anterior vaginal wall, measuring $3\frac{1}{2} \times 4$ in. in the vertical and transverse diameter and $2\frac{1}{2}$ in. in thickness. Higher up in the vagina on the left is another large hæmorrhagic mass extending deeply into the cellular tissues between the bladder and the vagina, measuring $4\frac{1}{2} \times 5$ in. $\times$ 3 in. in thickness.

The bladder and urethra were displaced forwards, but are not infiltrated with growth, nor were their functions interfered with during life. In three places the vaginal mucous membrane has given way and hæmorrhagic growth is seen protruding through it. The uterus is enlarged and its muscle soft, but neither the cervix nor the uterine body show any sign of being, or having been, affected with growth, and microscopical section of the muscle fails to show any sign of new growth. The ovaries are small and contain several small lutein cysts, and the microscopic sections show a fairly large quantity of lutein tissue. These cells are, however, situated mostly in close relation to the cyst walls, and do not appear to disseminate widely into the ovarian stroma proper. Both ureters are lifted up, and can be seen running over the upper limit of the two vaginal masses on their way to the bladder. The growth has not infiltrated above the level of the ureters and the broad ligaments are free from invasion. The inguinal, iliac, and bronchial lymphatic glands contained no growth. At each of the later operations the uterine body was curetted, but the microscopical sections failed to reveal the presence of growth. The sections of all the tumours removed are

alike in structure, and are very typical examples of chorion-epithelioma, the syncytium being greatly in excess. The pulmonary nodules are very necrotic and hæmorrhagic, but both varieties of cells can be seen in the sections.

Of course the greatest point of interest in this case lies in the fact that although an intra-uterine vesicular mole was expelled from the uterus this organ remained free from growth, while the vagina became the seat of four separate tumours, which appeared at different times. There was an interval of five months between the removal of the first tumour and the appearance of the second. The chorionic villi must have been lying latent in the peri-vaginal tissues during this time. When they first appeared each tumour formed a soft but well-defined swelling in the perivaginal tissue, causing little or no local disturbance, but as soon as recurrence and infiltration began the rapid and treacherous manner in which the soft growth spread in the perivaginal tissues was truly alarming. Beyond a slight fulness the infiltration in its early stages caused little superficial alteration either in the skin of the vestibule or the mucous membrane of the vagina, and it was extremely difficult to define the limits of the affected areas until the growth had advanced considerably. I think there can be no doubt that the growth spreads along the perivaginal veins, because the sections taken from the growing edges show growth creeping along the vessels in the perivaginal tissues, and at the time of the operations small pockets of cells were found in the perivaginal tissues outside the definite limits of the edge of the tumour, while the deeper portion of each tumour had a definite capsule. I should think it was safe to shell such tumours out of their bed when well encapsuled, but the vaginal wall should be removed as widely as possible at the periphery of the growth, in order to avoid the outlying pockets in the perivaginal tissues. The occurrence of these growths in the vagina after the passage of the mole was so symptomless, and the infiltration so insidious, that I think a routine examination should

be made for some months after the passage of a mole in every case.

With regard to the diagnosis there is no special difficulty. In the early stages small, soft, perivaginal tumours are liable to be overlooked, and in the later stages the hæmorrhagic infiltrating growth may simulate hæmatoma. The history of a molar pregnancy and the knowledge of the fact that these growths occur will leave no doubt as to the nature of the case.

There are a considerable number of cases now recorded of primary chorion-epithelioma occurring outside the uterus, the uterus having escaped infection.

Two theories have been advanced as to the origin of these tumours: one is that the chorionic villi migrate from the uterus to some more or less remote part, and having settled in the tissues the epithelium of the villi proliferates to form a chorion-epithelioma; the second theory is that the intra-uterine mole is primarily malignant, but the uterus expels it and escapes infection, the growths in other organs being looked upon as metastases. Pick and most authorities are in favour of the first of these theories, and, indeed, it seems improbable that true malignant metastases should form in other organs while the primary growth is expelled from the uterus, leaving that organ free from growth. Again, definite chorionic villi are shown in the sections of the vaginal growths in many cases. The myxomatous stroma of the villi with its epithelial coverings is easily made out, which seems to suggest that the villus has first migrated and that its epithelium proliferated to form a growth which has the microscopic appearance of chorion-epithelioma. Moreover, it is impossible to determine whether any given specimen of vesicular mole is malignant or innocent when expelled from the uterus, and it is difficult to imagine that a true malignant growth can escape detection when searched for by competent pathologists.

That the uterus may escape is shown in the following cases: Marchand records the case of a patient who died with symptoms of cerebral tumour several months after

the removal of a hydatid mole. A large growth was found in the right cerebral hemisphere and small nodules in the lungs and kidneys. The uterus was free from growth, the sections showing decidual remains only. There was no vaginal growth.

A similar case is recorded by Busse, whose patient died four months after an abortion, uterus and vagina also being free from growth.

Among the cases with vaginal growths, those of Lindfors and Schmorl died, and at the autopsy no primary growth was found in the uterine cavity in either case.

In four cases the uterus was removed during life, and on examination no chorion-epithelioma was found. In two cases chorionic villi with some proliferation of epithelium were found in the uterine veins. In the remaining cases curetting and clinical signs were relied upon to prove the absence of a primary intra-uterine growth.

Looking at the microscopical descriptions and drawings of the vaginal growths, we find that typical chorionic villi were found in some parts of the nodule, while sections of other parts showed great proliferation of the epithelium only.

I cannot detect any villous stroma in my sections; the growth seems to consist mainly of masses of proliferating chorion-epithelium. In several of the recorded cases villi were also found to be absent.

I think that the most important question which arises is the degree of malignancy of these primary embolic growths. Even primary uterine chorion-epithelioma, which if not attacked early by operation is, as a rule, so intensely malignant, sometimes behaves in a curiously innocent manner. Noble records and gives drawings of a case in which a great portion of a uterine chorion-epithelioma had to be left behind because it was too extensive for removal. The patient recovered and all signs of the growth disappeared.

Secondary vaginal deposits have disappeared in the same way after hysterectomy for primary uterine growth.

I have collected fourteen certain cases of primary

vaginal growths of whom two died. One of them (Schmorl) died eighteen weeks after a normal labour. The second case (Lindfors) died nine months after a normal labour and seven months after removal of the vaginal nodule. In both cases secondary growths were found in the lungs, kidney and liver, but the uterus escaped. The other twelve cases lived, and at the time of reporting were quite well. The nodules were removed in all cases and a full microscopic description is given. In the face of these results one wonders whether these primary vaginal growths are not as a rule almost benign. Judging from two cases recorded by Fleischmann and Eiermann, where the vaginal growth appeared three and a half and four years respectively after the passage of the mole, it seems possible that migrated villi may lie dormant for long periods before proliferation of the epithelium occurs. It is necessary, therefore, to watch these cases for a long time before giving a definite opinion as to the possible occurrence of both primary and secondary growths. That these tumours may be very malignant is shown in the cases of Lindfors and Schmorl and my own.

In the recorded cases of recovery the vaginal tumours were simply excised, and no extensive local operations were undertaken for their removal.

The growths under these circumstances can hardly be very malignant. This question of malignancy becomes a matter of great clinical importance, not only from the point of view of prognosis but also from that of treatment. If in any given case it can be proved that the vaginal growth is primary the prognosis is probably good, and hysterectomy need not be performed. If, on the other hand, we are dealing with a vaginal nodule secondary to an intra-uterine growth, the prognosis is necessarily bad, and the uterus must be removed at all costs. The microscopical examination of the curettings, together with the clinical signs and symptoms, should give reliable evidence of the presence or absence of an intra-uterine growth.

Apparently the microscopical appearances of the struc-

ture of the growth does not help to decide the degree of malignancy. As can be seen in the sections of this case the structure of the growth is that of a typical chorion-epithelioma. Perhaps the arrangement of the two varieties of cells in relation to one another is more regular than that seen in uterine growths, and syncytium is present in larger quantities. In some of the recorded cases typical villi with their stroma are described. Whether the presence of these villi would help to differentiate between primary and secondary vaginal growth is an open question. The vaginal nodules most frequently appear within two or three months after the passage of the mole, but there are four cases recorded in which they made their appearance while the mole was still in the uterus, but, as has been said above, the interval may be as long as four years. The cases which follow full-term pregnancy seem to be more malignant than those following moles or abortion.

With regard to the incidence of lutein tissue overgrowth in connection with primary extra-uterine chorion-epithelioma, it is too early to give a definite opinion either to the frequency or meaning of its occurrence until more control work is done upon the subject of lutein tissue and more notice is taken of the condition of the ovaries in recording cases. In my case the ovaries are not enlarged, but there is a considerable quantity of lutein tissue present in the sections. The patches of lutein tissue are mostly placed in close relation to the small blood cysts, and there is no diffuse dissemination of lutein cells in the ovarian stroma proper. Schickele, however, describes a case (No. 14 in table) in which both ovaries were enlarged to the size of the fist and contained black lutein cysts. The uterus contained a vesicular mole, simultaneously with a small vaginal nodule, which was removed. Hysterectomy and ovariotomy were performed and the patient was well six months after the operations.

There can be no doubt that trophoblastic cell proliferation is frequently associated with lutein overgrowth, but

how the one is directly related to the other must be left an open question until further work has been done upon this most interesting subject.

It seems doubtful whether lutein overgrowth is as often associated with primary extra-uterine chorion-epithelioma as with intra-uterine chorion-epithelioma.

I have seen quite as much lutein tissue in two ovaries not connected with a recent pregnancy as there is in the ovaries in my case.

Conclusions.

(1) That these vaginal growths most often occur after the passage of a vesicular mole, but, like intra-uterine chorion-epithelioma, may follow abortion or full-term pregnancy.

(2) That they may occur while the mole is still within the uterine cavity.

(3) That they originate from the chorion-epithelium of migratory embolic villi.

(4) That there is no evidence to show that a malignant intra-uterine growth or a malignant mole can be expelled from the uterus, leaving that organ free from growth and be followed by metastases in other organs.

(5) That the growth spreads *viâ* the perivaginal venous spaces.

(6) That there is no means of telling whether any given mole will be followed by chorion-epithelioma.

(7) That the large quantities of syncytium seen in the sections is very characteristic of the vaginal tumours.

I have tabulated shortly the recorded cases found in the literature on this subject.

I have to thank Dr. Taylor for kindly allowing me to make use of this case, and the Clinical Research Association for cutting the excellent sections of the tumours.

Table of Recorded Cases of Vaginal Chorion-epithelioma.

Author.	Nature of last pregnancy.	Size and position of nodule.	Operation.	Microscopical description of nodule.	Time of occurrence in relation to pregnancy.	Evidence that uterus was free from growth.	Result.
1. Pick (1) (*v.* Pick and Landau)	Vesicular mole (4 mths.) expelled spontaneously 3 days after excision of nodule	Nodule size of walnut in anterior vaginal wall	Excision of nodule, curetting of uterus	Mole-vesicles in the coagulated blood, with syncytial proliferation and migrating cells	Simultaneous	Curettings negative	Well 3½ years after operation; two normal pregnancies.
2. Schmorl	Normal pregnancy	Nodule in vagina, metastases in lungs, liver, kidneys, intestines	*Post-mortem* examination	Typical structure of syncytial tumour	—	Uterus found normal at *post-mortem* examination	Died 18 weeks *post partum.*
3. Schlagenhofer	Incomplete abortion	Nodule, size of walnut, immediately behind the commissure of posterior vaginal wall	Excision of nodule. Curetting of uterus	In the coagulum, syncytial masses and Langhans' cells; at the periphery syncytial migrating cells	10 months after abortion	Curettings negative	Well 22 months after operation.
4. v. Guérard	Vesicular mole removed manually	Nodule, size of a big nut on the anterior lip of the os	Vaginal total extirpation of uterus	Enormous broad masses of syncytium	2½ months after evacuation of vesicular mole	Excised uterus free from growth	Quite well 3 years after operation.
5. Schmit (1)	Vesicular mole expelled spontaneously	Tumour the size of a hen's egg on the anterior and left vaginal wall from the urethra to the fornix. Another nodule, the size of a nut, at the posterior point of the columna rugarum	Excision of nodules, curetting of uterus	*Large tumour* in the coagulum chorionic villi, with layers of Langhans' cells and proliferated syncytium; migrating cells. *Small tumour* similar, but without villi	3 months after expulsion of vesicular mole	Curettings negative	Well, and menstruating regularly 1½ years after operation.

Author.	Nature of last pregnancy.	Size and position of nodule.	Operation.	Microscopical description of nodule.	Time of occurrence in relation to pregnancy.	Evidence that uterus was free from growth.	Result.
6. Littauer .	Vesicular mole (2nd mth.) expelled spontaneously followed by curetting of uterus	Small vaginal nodule	Excision of nodule	Typical chorion-epithelioma	A few months after expulsion of mole	Curettings after expulsion of mole negative	Well 15 months after operation.
7. Lindfors .	Normal labour	Walnut-sized tumour at the anterior vaginal wall	Excision of nodule, 8 weeks' *post-partum* curetting of uterus, and *post-mortem* examination, large chorion-epithelioma of left lung, smaller nodules in right lung, spleen, brain, and kidneys, and small intestines	In masses of cruor proliferation of syncytium and Langhans' cells. The metastases found *post-mortem* show all through the structure of typical chorion-epithelioma malignum	First noticed 3 weeks after labour	Curettings negative	Died 7 mos. after excision of nodule.
8. Schmit(2)	Vesicular mole expelled partially, and remains removed by curetting	Nut-sized nodule on anterior vaginal wall	Excision of nodule, curetting of uterus	In the coagulum chorionic villi, layer of Langhans' cells and syncytium; Typical chorion-epithelium tissue starting from the surface of the villi; at the periphery syncytial migrating cells	8 weeks after expulsion of vesicular mole	Curettings negative	Well 8 mos. after operation; menstruating regularly.

9. Marchand	Vesicular mole evacuated	No vaginal nodule	*Post mortem*: tumour in left cerebral hemisphere, nodules in lung and kidney	—	—	Decidual remnants only found *post mortem*	Died several months after evacuation of vesicular mole.
10. Pick and Landau (2)	Complete abortion	Two pea-sized nodules on anterior vaginal wall	Excision of nodules, curetting of uterus	Within the coagulum are villi with proliferation of Langhans' cells and of the syncytium which are connected with chorion-epitheliomatous tissue; at the periphery migrating cells	2 weeks after abortion	Curetting negative	Well and pregnant 15 months after operation.
11. Neumann	Vesicular mole	Nodule on the anterior vaginal wall	Excision of nodule and hysterectomy	Villi and proliferating epithelium	Simultaneous with mole	Chorionic villus found in uterine vein	Well.
12. Fleischmann	Vesicular mole evacuated	Nodule, size of chestnut, on anterior vaginal wall	Nodule enucleated, uterus curetted	Vacuoles, chromatin nuclei, syncytial cells, no Langhans', no chorionic villi	Nodule appeared 3½ years after evacuation of mole	Necrotic single syncytial cells in the curettings, no attempt at any definite growth formation	Well 1 year after operation.
13. Poten and Vasmer	Vesicular mole	Small vaginal nodule which recurred 4 weeks later	Excision of nodule, hysterectomy, excised again	Villi and proliferated epithelium	Simultaneous	Chorionic villi in uterine veins	Well some months later.
14. Schickle	Vesicular mole (2 mths.) evacuated	Small nodule on anterior vaginal wall	Nodule excised, hysterectomy and ovariotomy and removal of 2 large lutein cysts from ovaries	Great proliferation of epithelium; distinct villous processes	Simultaneous	Uterus free from growth, but showed necrotic chorion villi in its walls and villi in the uterine veins with some cell proliferation	Well 6 mos. after operation.

References.

Pick.—Von der gut-und bösartigen Blasenmole. Berl. klin. Wochenschr., 49 and 50, 1897; S. 1069 and 1097.

Pick.—Diskussion über Pick und Schmorl's Vorträge auf der 69. Versammlung deutscher Naturforscher und Ärzte zu Braunschweig. Centralbl. f. Gynäk., Nr. 40, 1897, S. 1217.

Pick.—Über Metastasenbildung und Histologie der gutartigen Blasenmole. Centralbl. f. Gynäk., Nr. 40, 1897, S. 1216.

Schmorl.—Demonstration eines syncytialen Scheidentumors. Centralbl. f. Gynäk., Nr. 40, 1897, S. 1217.

Schlagenhaufer.—2 Fälle von Tumoren des Chorionepithels. Wien. klin. Wochenschr., Nr. 18, 1899, S. 486.

von Guérard.—Ein selten schönes Präparat von Deciduoma malignum der Cervix. Monatsschr. f. Geburtsh. und Gynäk., Bd. 10, 1899, S. 239.

Schmit.—Chorioepitheliale Geschwülste der Vagina. Wiener klin. Wochenschr., Nr. 14, 1901, S. 358.

Lindfors.—Zur Frage von Syncytioma malignum vaginæ post graviditatem ohne Geschwulstbildung im Uterus (Upsala Läk Förh., Bd. 6, H. 4). Deutsches Autoreferat in dem Centralbl. f. Gynäk., Bd. 25, Nr. 19, 1901, S. 501.

Lindfors.—Über den weiteren Verlauf und den Ausgang meines Falles von Syncytioma malignum vaginæ nebst Obductionsbefund. Centralbl. f. Gynäk., Bd. 25, No. 21, 1901, S. 557.

Marchand.—Über das maligne Chorionepitheliom nach Mitteilung von 2 neuen Fällen. Zeitschr. f. Geb. u. Gynäk., Bd. 39, 1898, S. 173.

Littauer.—Beitrag zur Frage der Malignität des Chorionepithels. Arch. f. Gynäk., Bd. 72 (Festschrift der Gesellschaft), 1904, S. 295.

Zagorjanski-Kissel.—Über das primäre Chorioepi-

theliom ausserhalb des Bereiches der Eiansiedlung. Arch. f. Gynäk., Bd. 67, Heft 2, 1902, S. 326.

Poten and Vasmer.—Beginnendes Syncytiom mit Metastasen, beobachtet bei Blasenmolenschwangerschaft. Arch. f. Gynäk., Bd. 61, Heft 2, 1900, S. 205.

Fleischmann.—Über eine seltene, vom Typus abweichende Form des Chorionepithelioms mit ungewöhnlichem Verlauf. Monats. f. Geburtsh. und Gynäk., Bd. 17, 1903, S. 415.

Eiermann.—Der gegenwärtige Stand der Lehre vom Deciduoma malignum. Gräfe's Sammlung, Bd. 2, 1897.

Busse.—Diskussion über die Implantation des menschlichen Eies. Greifswalder medizinischer Verein. Wiener klin. Wochenschr., Bd. 15, Nr. 38, 1902, S. 1000.

Schickele.—Die Malignität der Blasenmole. Arch. f. Gynäk., Bd. 78, Heft 1, 1906, S. 211.

A CASE OF CHORION-EPITHELIOMA COMPLICATED BY HÆMATO-METRA.

BY

W. S. A. Griffith

AND

Herbert Williamson.

(Received April 11th, 1907.)

(With exhibition of the specimen, microscopic sections, and a drawing.)

(With Plate XXIII.)

(*Abstract.*)

The case is recorded of a lady, 42 years of age, who was delivered of a mole, probably hydatidiform, on December 30th, 1905.

The patient had borne four children, the last eight years previously; her fifth pregnancy commenced in the early part of June, 1905. From August to December she suffered from numerous small vaginal hæmorrhages; from November 17th until December 29th she was under close observation, and, as no increase in the size of the uterus occurred during this period, a diagnosis of molar pregnancy was made, and abortion was induced.

A mole was expelled which, in its general characters, resembled a carneous mole, but upon the surface were a few vesicles.

Three weeks later (January, 1906) the patient suffered from persistent hæmorrhage and the passage of clots; the uterus was explored, and a quantity of blood-clot and *débris* removed.

From this time the hæmorrhage ceased excepting for the loss of a small quantity of dark blood on February 16th, but the uterus again enlarged, and pain was felt in the pelvis.

On March 3rd the uterus and ovaries were removed by the abdominal route.

In November, 1906, the patient died with signs of new growth in the lungs.

The uterine cavity was distended with fluid and clotted blood, and the cervix completely occluded by blood-clot. A growth, of the nature of a chorion-epithelioma, was found on the anterior wall near the fundus, numerous lutein cysts were present in both ovaries.

A description of the naked-eye and microscopical appearances of the parts removed is given, and special attention is drawn—

(1) To the excessive formation and wide distribution of lutein tissues throughout the ovaries.

(2) To the support afforded by this specimen to the theory that lutein cells may arise by modification of the connective-tissue cells of the ovarian stroma.

(3) To the presence of a layer of necrosed tissue resembling Nitabuch's layer of canalised fibrin between the uterine wall and tumour out-growths.

The patient from whom the specimen exhibited to-night was removed was a lady, aged 42, who had borne four children, the last in 1897.

Menstration commenced at the age of eleven; the periods were never quite regular, the intervals varying from three to five weeks, and the bleeding was usually profuse. In 1903, for a term of three months, menstruation was suppressed; there was no evidence of pregnancy, and at the end of this time the menstrual flow was re-established and continued of the usual type until May, 1905. The last period commenced on May 20th and ceased on May 25th, 1905; shortly after this pregnancy ensued.

The pregnancy ran a course apparently normal until August 9th; on that date a blood-stained vaginal discharge

was noticed and at the same time aching pain was felt in the pelvis over the whole area from pubes to sacrum.

Between August 9th and November 17th there were numerous small hæmorrhages, but the amount lost was never sufficient to cause alarm.

On November 17th the patient's medical attendant, Dr. Sharman, of Rickmansworth, brought her up to consult Dr. Griffith. Although there had been a period of six months' amenorrhœa, the top of the uterus was only six inches above the pubes; its characters, however, resembled those found in a normal pregnancy. Dr. Griffith suspected that the embryo was dead, and advised a delay of one month, and the termination of the pregnancy at the end of that time if the uterus had not increased in size.

The patient was seen again on December 15th, when the following note was made: "The uterus presents no change in size or characters, but behind it can be felt a small tumour, probably the left ovary enlarged."

On December 29th Dr. Sharman induced abortion by inserting a laminaria tent into the cervical canal, and on the following day a mole was spontaneously expelled. The mass presented the general characters of a carneous mole, but Dr. Sharman noticed on the surface a few small vesicles.

On January 28th, 1906, Dr. Griffith was again asked to see the patient on account of persistent hæmorrhage and the passage of clots. The uterus was of almost the same size as at his last examination, and the cervical canal was patent, admitting the finger easily. Under anæsthesia a large quantity of inoffensive blood-clot was removed; the uterus then contracted down well; the curette was introduced and "a considerable quantity of decidua with adherent clot brought away." Hæmorrhage ceased and the patient's progress was regarded as satisfactory until February 16th, when a small amount of dark blood escaped; after this date there was no further bleeding, but aching pain in the epigastrium and hypo-

gastrium persisted, and for this reason Dr. Griffith was consulted again on February 28th. He found the uterus as large as upon his first examination; the fundus reached to six inches above the pubes and the organ was unusually broad from side to side. A diagnosis of chorion-epithelioma was made; but it was difficult to explain the fact that for the last month there had been hæmorrhage on one occasion only, and then slight in amount.

The patient was suffering from a troublesome cough, and from pain in the right side of the thorax. On March 1st Dr. Garrod examined the chest, but could detect no signs which led him to suspect the presence of new growth in the lungs.

On March 3rd the operation of abdominal hysterectomy was performed. When the abdomen was opened a quantity of thin blood-stained fluid escaped; this resembled closely the fluid contained in the cysts of the ovaries. A tumour which proved to be the uterus was seen rising out of the pelvis; its colour, size, and general characters corresponded with those of the uterus at the end of the fifth month of a normal gestation. The ovaries presented a remarkable appearance: both were enlarged by the presence of multiple cysts, and were of a curious dark plum colour. The right was the larger of the two and formed a tumour the size of a goose's egg. The enlargement was due to the presence of a number of cysts, some with serous contents, others filled with a deep red, jelly-like material; some of these cysts ruptured during the process of removal. The left ovary was rather larger than a billiard ball; the cysts on its surface were smaller, but of similar appearance. The uterus, together with the uterine appendages, was removed, the vessels were secured and the body amputated at the level of the os internum; as soon as the cavity was cut across a quantity of dark, semi-fluid blood escaped, the walls shrinking and contracting down. The cervix was removed separately; a nodule was felt in the posterior vaginal wall; it was enucleated, but on investigation proved to be

a small cyst and contained no chorion-epitheliomatous tissue.

The patient made a good recovery: the convalescence was interrupted by no untoward symptoms.

Immediately after removal the condition of the uterus and cervix was investigated; the cervical canal was occluded by a quantity of coagulated blood; a probe could be passed without difficulty, but apparently the clot had been sufficiently firm to prevent the escape of blood, and to lead to distension of the cavity by hæmorrhage from the surface of the growth. As soon as free exit was given the uterus contracted down, forcibly expelling a large quantity of blood.

A puzzling feature in the clinical aspect of the case had been the very rapid increase in size of the uterus associated with cessation of vaginal hæmorrhage. The explanation was now quite clear; coagulated blood had completely occluded the cervical canal; the hæmorrhage, previously external, had become converted into the concealed variety and led to the formation of a hæmatometra.

We have read no account of the association of this condition with chorion-epithelioma, and one of our reasons for recording this case is to draw attention to the possibility of such a complication. The rest of the history is soon told. On August 18th, five months after the operation, Dr. Sharman wrote as follows: "The condition is not quite satisfactory, although Dr. Griffith, Dr. Garrod, and I have been unable to find anything suggesting a recurrence. The patient has had a series of attacks of neuritis and myalgia in different parts of the body, and especially the chest, back and front, simulating pleurisy and pleurodynia, at first accompanied by slight evening rise of temperature. Recently she has been breathless with some palpitation, but nothing definite to account for it." A fortnight later Dr. Garrod detected signs of new growth in the lung. Death ensued in the latter half of November. No *post-mortem* examination was performed.

DESCRIPTION OF PLATE XXIII,

Illustrating Dr. W. S. A. Griffith's and Dr. Herbert Williamson's specimen of A Case of Chorion-Epithelioma complicated by Hæmato-metra.

Illustrating Dr. W. S. A. Griffith's and Dr. Herbert Williamson's case of Chorion-epithelioma complicated by Hæmato-metra.

Adlard & Son, Impr.

Description of the Specimen.

After removal, fluid and clotted blood escaped and the walls of the uterus contracted down, actively expelling most of the clot. At the close of the operation the uterine cavity was packed with cotton-wool soaked in a 10 per cent. solution of formalin.

As seen at the present time the dimensions of the organ are: Length, 8 in.; transverse diameter at the level of the point of entrance of the Fallopian tubes, $6\frac{1}{2}$ in.; circumference at the same level, 15 in.

In appearance it resembles closely a uterus enlarged by pregnancy. The surface is smooth and peritoneum-clad throughout the greater part of its extent; beneath the peritoneum are numerous small dilated vessels; the shape is pyriform and the Fallopian tubes are attached 2 in. below the highest point of the fundus. The lower part of the body is devoid of peritoneum on both its anterior and posterior aspects; from these areas the peritoneum has been stripped during the course of the operation. A short distance above the level of the os internum amputation of the corpus uteri has been performed; the cervix was removed subsequently and the two parts have now been stitched together as nearly as possible in their natural position. The length of the cervix is $1\frac{1}{4}$ in.; its canal is patent, a large probe can be passed through its whole extent. The condition of hæmato-metra did not depend upon any structural change in the cervix, but resulted from occlusion of the canal by blood-clot.

The posterior wall of the uterus has been removed by a longitudinal coronal section. The cavity is greatly dilated, the walls are thickened but unequally so, and measure $\frac{5}{8}$ in. in thickness at the fundus.

On the inner aspect of the anterior wall nearer to the fundus than the cervix is an irregular area of ulceration 3 in. in length and 2 in. in breath, its long axis corresponding roughly with that of the uterus. The edges

of the ulcer are raised, hard, and everted; the base is depressed below the level of the surrounding tissues. The ulcerated surface is covered by a number of papilla-like projections, to which adhere portions of blood-clot and of *débris*.

Nearer to the fundus, 1 in. above the upper margin of the ulcer, are two patches of pale yellow material resembling masses of coagulated lymph. Sections cut through these show them to be composed of growth similar to that which forms the floor of the ulcer.

The points of entrance of the Fallopian tubes are situated 2 in. below the summit of the fundus. The abdominal ostia are patent but deeply congested; in other respects the tubes appear to be healthy. On the surface of each are a number of small sessile subperitoneal cysts (dilated lymphatics), and attached in the neighbourhood of the infundibulum on the right side are three small accessory tubes; two of these are fringed by miniature fimbriæ, the third is occluded at its distal extremity and forms a small cyst (hydrosalpinx of an accessory Fallopian tube).

Both ovaries are enlarged but have shrunken and undergone changes in the process of hardening. As seen immediately after removal the right formed a tumour of the size of a goose's egg, composed of a mass of thin-walled translucent cysts; some of the cysts ruptured during removal, their fluid contents escaping into the peritoneal cavity. A section through the organ discloses three main cavities filled with dark-red gelatinous material.

The left ovary is smaller—of the size of a golf ball; its deeply corrugated surface is raised here and there into rounded eminences by the projection of small cysts. At one spot on the peritoneal aspect was a small yellow plaque measuring $\frac{1}{3}$ in. in diameter and raised slightly above the level of the surface; this was removed for microscopical examination and will be described subsequently. On section the ovarian stroma is of an almost jelly-like consistence and of a red colour.

Microscopical Examination.

Sections have been cut in such a manner as to include the edge of the growth and a part of the adjacent uterine wall. The growth is a typical chorion-epithelioma, composed of Langhans' cells and syncytium. The fibro-muscular stroma of the uterine wall is seen in part of the section; the tissues of which it is composed take the stain badly, many of the nuclei are fragmentary and details of a chromogen network cannot be determined. The fibrillæ of the muscle bundles can still be seen, but the outlines of individual fibres are very indistinct.

The nearer we approach the edge of the growth the more marked is the degeneration of the muscle, and finally, when we reach the growing edge of the tumour the maternal tissues are represented by an almost homogeneous fibrinous material comparable to Nitabuch's fibrin layer. In it, however, we can still trace the remains of degenerate nuclei, and scattered through it are a few round cells, possibly of an inflammatory nature.

In the normal ovum the trophoblast exhibits destructive properties, in virtue of which the highly differentiated tissues of the decidua are, in its immediate neighbourhood, reduced and converted into an almost structureless fibrin-like mass; the same destructive action is exhibited by the tongue-like processes which form the vanguard of the growth.

In a specimen of chorion-epithelioma (probably the oldest in existence, for the patient died in the year 1872) studied by Dr. Williamson and described in the 'Journal of Obstetrics and Gynæcology of the British Empire,' vol. iv, p. 306, he was able to demonstrate in the neighbourhood of the tumour a number of blood-channels in the uterine wall, and to show that around these blood-spaces the cells which formed the outposts of the tumour were grouped. This mode of invasion we cannot trace in

the present case—we can find no constant relation between uterine vessels and the tumour out-growths.

Cells of various forms are seen even in the deeper parts of the uterine wall. Those of one variety are small and possess a central vesicular nucleus surrounded by a scanty cell substance which stains faintly with eosin. In others the cell substance is granular and stains more deeply, the nuclei are denser and not clearly vesicular, in this respect resembling the syncytium.

These various cellular elements are found in the tissues at some considerable distance from the tumour. The smaller cells described first are most numerous; in their characters they differ markedly from the round cells so familiar to us in inflammatory processes, and are evidently derivatives of the fœtal epiblast. They are most numerous in the neighbourhood of the vascular spaces, but are not confined to these areas.

The tumour may be described as consisting of a sponge-work of syncytium, the interstices of which are occupied by large rounded or oval cells, each possessing a single centrally-situated nucleus. From the growing edge tongue-like processes project into the uterine stroma; the maternal tissues in the neighbourhood of these projections have undergone necrosis; they do not persist to form a stroma for the tumour, but disappear completely, first becoming converted into a structureless substance comparable to Nitabuch's layer of canalised fibrin. As the result of the destructive action of the invading tissues many of the processes are surrounded by spaces containing red blood-corpuscles; it is from these vascular channels that the growth derives its principal blood supply.

Two distinct varieties of tissue can be recognised in the tumour:

(1) *Syncytium* present in the form of irregular masses, in the form of the so-called multi-nucleate giant-cells and in the form of ribbon-like strands so united as to constitute a sponge-work. In the spaces of this sponge-work

are groups of tightly-packed cells. Between the masses of syncytium on the one hand and the well-formed discrete cells on the other all stages of gradation are found. The protoplasm of the syncytium stains well with eosin; it is finely granular, opaque and vacuolated. The nuclei show no constant arrangement; in some parts they lie in rows, in others they are scattered irregularly throughout the protoplasm; in form and structure they exhibit marked differences: some are small, round, darkly-staining bodies, others are larger, vesicular, and possess a distinct chromogen net-work.

(2) *The Langhans' cells* are rounded with a clearly defined outline, the nuclei are large, centrally situated and vesicular, the cell-substance is granular and vacuolated, differing from the protoplasm of the syncytium in that it exhibits a reteform structure and stains less deeply with eosin.

The syncytium forms a sponge-work of interlacing strands and in the interstices of this sponge-work lie groups of Langhans' cells packed closely together.

Microscopical examination of the ovaries reveals:

(1) That the organs are unusually vascular.

(2) That lutein tissue is present in three situations: (*a*) in the walls of the cysts; (*b*) in the ovarian stroma; (*c*) on the surface of the ovary.

(3) That the stroma-cells have undergone modifications.

The blood-supply of the organs is a rich one; in addition to well-formed vessels there are present vascular channels possessing little more than an endothelial lining. The red, jelly-like appearance of the ovaries is due to the presence of blood extravasations into the œdematous stroma.

The lutein tissue.—The various cysts scattered through the ovaries are lined by a pale yellow membrane composed of lutein cells; this membrane is thrown into wavy folds. In most instances the lutein cells are in direct contact with the cyst contents; occasionally a lining of fibrinous, almost structureless, material lies within the lutein layer. A stratum of similar material is constantly

to be seen in the normal corpus luteum separating the lutein cells from the central blood-clot, and in our opinion is to be regarded as the membrana propria of the normal Gräffian follicle greatly hypertrophied.

The lutein tissue is formed of rounded and irregularly shaped cells with opaque cell-substance and a centrally situated vesicular nucleus. Karyokinetic figures are seen in some of the nuclei and furnish evidence of rapid cell proliferation; such figures are rarely found in the mature corpus luteum. Groups of lutein cells are scattered through the stroma, and at one spot on the surface of the left ovary a mass of the tissue projects.

We have already drawn attention to a small yellow plaque $\frac{1}{3}$ in. in diameter attached to the surface of the left ovary. The mass is composed of rounded cells with a central vesicular nucleus and opaque cell-substance; between the cells is a scanty intercellular stroma. Three explanations of the origin of this group of cells suggest themselves: (1) that we may have here a "decidual nodule," one of those small masses of decidual cells described originally by Schmorl and Kinoshita, which are so often to be found scattered over the peritoneum of the uterus, of Douglas's *cul-de-sac*, and upon the surface of the ovaries in women dying soon after child-birth; (2) the nodule may represent a secondary deposit of the growth; (3) the nodule may be composed of lutein tissue. The yellow colour of the plaque and the characters of the cells have led us to adopt the latter view. Dr. F. W. Andrewes and Dr. Cuthbert Lockyer, who have been good enough to examine the sections, agree with our conclusions.

The ovarian stroma has become modified; in many parts it is œdematous and degenerate, the cells possess oval or rod-shaped nuclei, and the elongated cell-processes unite to form a network whose meshes are sometimes occupied by red blood-corpuscles. In this degenerate stroma are groups of lutein cells. In other places the stroma-cells are no longer of the embryonic type, but are

oval or rounded, with large, clear, vesicular nuclei, some of which show karyokinetic figures; it is possible that these may represent the earlier stages of the lutein cell, but we possess no differential stain for lutein tissue and therefore are not in a position to state with certainty that these modified stroma-cells are of this nature.

In a paper read before the Obstetrical Society of London in 1905 Dr. Cuthbert Lockyer accepted the theory of migration of lutein cells; there is available no positive evidence in favour of the existence of such a phenomenon. The origin of the lutein cell cannot be regarded as definitely settled; we, however, are firmly convinced that it arises by modification of the cells of theca interna and not from the membrana granulosa. The cells of the theca interna are merely modified stroma cells, and we find no difficulty whatever in believing that lutein tissue may arise directly from the connective-tissue cells of the ovarian stroma. The specimen before us furnishes no clear proof of the truth of this theory, but the marked modifications in the form of the stroma and the presence of the groups of lutein cells scattered through it are very suggestive.

The study of chorion-epithelioma is still in its infancy, and it is important that every case presenting unusual features in either its clinical or pathological aspect should be reported. In its clinical aspect this case was unusual in that a month before operation there was cessation of vaginal hæmorrhage although the uterus continued to enlarge.

In its pathological aspect it presents three points of special interest:

First, in the excessive formation and wide distribution of lutein tissue throughout the ovaries.

Secondly, in that it supports the theory that lutein cells may arise by modification of the connective-tissue cells of the ovarian stroma.

Thirdly, in the presence of a layer of necrosed tissue, closely resembling Nitabuch's layer of canalised fibrin, between the uterine wall and the tumour out-growths.

Dr. Cuthbert Lockyer congratulated Mr. Hicks and Dr. Williamson upon their admirable reports of their two most interesting cases. In respect of Mr. Hicks's case Dr. Lockyer inquired if the uterine walls had been systematically examined for areas of chorion-epithelioma? In two cases recorded by himself, *i. e.* those of Mr. Malcolm and Dr. Oldfield, the uterine infection might easily have been missed as the malignant foci were very small and deeply seated in the uterine muscle; indeed, it was only after slicing the uterus—removed by Dr. Oldfield—into many segments that the chorion-epitheliomatous area was discovered. Dr. Lockyer was particularly interested in the question of lutein excess in the ovaries in cases of vesicular mole and chorion-epithelioma; he had recorded four cases himself (for one of which he was indebted to Dr. Herbert Williamson) in which there were compound lutein cystomata in association with chorion-epithelioma, and it was with full reserve that Dr. Lockyer drew the attention of this Society, in 1903 (four years ago), to Pick's theory of a chorion-epitheliomatous reaction being due to excess of lutein tissue. Dr. Lockyer pointed out then, and several times subsequently, that this question will be settled only by the accumulation of further cases, and in relation to this point it interested him to note that whilst Dr. Williamson's fresh specimen supported Pick's theory, Mr. Hicks's *post-mortem* material did not. Hitherto there had been no case recorded where compound lutein cysts have accompanied normal gestation, whereas whenever bilateral ovarian cysts have been found associated with vesicular mole and chorion-epithelioma the former are always lined by lutein tissue. As already recorded, in one of the cases of this disease, published by Dr. Lockyer (Mr. Doran's case), there was no lutein tissue to be found in either ovary, but the tissues were removed *post mortem* after the fundus uteri had sloughed and produced purulent peritonitis, consequently the material investigated was open to criticism from a controversial point of view. In Dr. Lockyer's opinion the interesting question of a causal relationship existing between excess of lutein cells and chorionic cell-proliferation still remains *sub judice*.

Mr. Targett thought that all cases of double lutein cystic tumours of the ovaries should be carefully recorded. At an operation for an ovarian cyst with pregnancy in the fourth month he found the tumour consisted of multiple thin-walled lutein cysts which partly ruptured on removal. When the uterus was turned aside the opposite ovary was seen to be in a similar condition. Both tumours were removed. A fortnight later the patient aborted; the fœtus was macerated, and the placenta was partly composed of vesicular mole. Though the wound healed naturally the patient remained in a weak, anæmic condition for many weeks, but so far showed no signs of the development of chorion-epithelioma. In view of such an occurrence he had

wondered whether it would not have been safer to have removed the uterus, seeing that both ovaries had been already excised.

Dr. BLACKER thought these two cases of special interest, because while one showed a definite excess of lutein tissue in the ovary the other certainly did not. The case related by Mr. Targett was a further proof of the now well-known fact that the presence of a hydatidiform mole in the uterus was usually associated with an excess of lutein tissue in the ovaries. To argue from this, however, that the one condition depended on the other seemed to him to be quite unwarranted. It was much more likely that the two conditions were due to some common cause, and this appeared the more probable when the changes which took place were considered. In the case of the uterus there was an excessive overgrowth of a young and rapidly-growing tissue, the trophoblast, with the subsequent formation of cysts, no doubt due largely to serous transudation. In the ovary there was also marked proliferation of a young tissue, that of the corpus luteum, with the subsequent development of cysts no doubt of similar origin. The close resemblance between the changes occurring, on the one hand, in the uterus, and, on the other hand, in the ovary, seemed to point to some common cause acting on the two organs. If the theory that the corpus luteum possessed an internal secretion was accepted, then it was curious that such a body derived, as it almost certainly was, from connective tissue should have such a function. If this was so, then it was unlike any other of the ductless glands in the body. Dr. Williamson's sections from the ovaries in his case certainly favoured the view that the cells of the corpus luteum were derived from the stroma cells of the ovary and had a connective-tissue origin, and the slides he had exhibited seemed to give considerable support to the theory that the lutein cells found scattered throughout the stroma of the ovary really developed *in situ*, and were not due to the migration of such cells from the neighbouring corpora lutea.

July 3rd, 1907.

Herbert R. Spencer, M.D., President, in the Chair.

Present—29 Fellows and 6 visitors.

Books were presented by the Westminster Hospital Staff, and Dr. Herman. Dr. Bonney presented a pair of old forceps (in use prior to 1815 by Dr. William Ralfs) with leather-covered handles.

The following gentlemen were elected Fellows of the Society: Sorab Kaikhoshru Engineer, M.R.C.P.E., L.R.C.S.E., L.M.&S.Bomb., (Edinburgh); Manecxji Piroshaw Kerrawalla, M.D.Brux., L.M.&S.Bomb.; Stanley Dodd, M.A., M.B., B.C.Cantab.; and Somerville Hastings, M.B., B.S.

Report of the Pathology Committee on Dr. H. Briggs's Specimen of Ovarian Pregnancy (*see p.* 222).

We have examined this specimen and the microscopic sections taken from it, and find no certain evidence that the imperforated ovum was developed in the ovary, and consider that it may be a tubal abortion which has become adherent to the ovary.

The following report was made on Dr. Dauber's Specimen of Fibro-myomatous Uterus containing a Calcified Fibroid lying free in the Uterine Cavity (*see p.* 139).

We have examined this specimen and the microscopic sections taken from the uterus, and agree that the tumour consists of several fibro-myomata, one of which is calcified and lies loose in a cavity, the walls of which are infiltrated by glandular carcinoma. This cavity communicates directly with the cervical canal and is probably the cavity of the uterus.

The following report was made upon Mr. H. T. Hicks's Specimen of Primary Vaginal Embolic Chorion-epithelioma,

referred to the Pathology Commitee to ascertain if there be chorion-epithelioma of the uterine body (*see p.* 224).

We have examined this specimen, and the microscopic sections specially taken from the uterine wall, and find no evidence of chorion-epithelioma of the body of the uterus.

(*Signed*) Alban Doran.
John H. Dauber.
H. T. Hicks.
Corrie Keep.
W. S. A. Griffith, *Chairman.*

SUPPURATION IN AN OVARIAN CYST CAUSED BY THE BACILLUS TYPHOSUS.

By Frank E. Taylor, M.D., B.S., F.R.C.S.

The occurrence of suppuration in the contents of an ovarian cyst is a well-recognised, though somewhat infrequent, complication of this neoplasm. Indeed, "at first

glance," as Bland-Sutton remarks, "it seems somewhat difficult to understand how ovarian cysts should become inflamed, enclosed as they are in air-tight cavities, and having no communication with other organs." He further states that "a little reflection soon reveals several sources of infection. Of these the principal are: (1) The Fallopian tube, (2) the intestine, (3) the vermiform appendix, and (4) tapping."

Pfannensteil expresses the opinion that infection of ovarian cysts usually comes from the tube or intestine, the latter almost exclusively when the cyst is adherent to bowel, or mere proximity suffices if this is damaged from any cause, and that the infective agent is most seldom transported through the blood after systematic infectious diseases.

Olshausen also lays stress upon the frequency of intestinal infection in suppuration of ovarian cystic neoplasms.

Menge, too, as the result of careful bacteriological examination of many cases, believes that this is the usual source of infection, adhesions between cyst and intestine being almost always found. He does not, however, entirely deny the possibility of infective micro-organisms being transmitted to the contents of new growths by the blood-stream.

In one case Martin conclusively proved that infection came directly from the intestine. A firm, flattish adhesion from bowel to cyst was found permeated along its whole length by *Bacillus coli communis*. The pyogenetic cocci and *B. coli communis* are the most frequent pus-producers in ovarian cysts. Infection with the *B. typhosus* must necessarily be of rare occurrence, for it connotes the occurrence of typhoid fever in a patient already possessing an ovarian cyst. In what percentage of cases presenting these coincident conditions ovarian cysts become infected with the *B. typhosus*, and what percentage of those so infected suppurate, we have no means of knowing.

The following case, for the clinical history of which I am indebted to Mr. H. Speirs, house-surgeon, presents a typical example of this condition:

R. E. S—, IV-para, a widow, aged 37, was admitted into the Chelsea Hospital for Women under the care of Mr. J. Bland-Sutton on April 25th, 1907. She had lived in India for the last fifteen years, and except for occasional mild febrile attacks, which she took to be ague, and for which she took quinine, had enjoyed good health until April, 1906. She then had an attack of fever accompanied by acute abdominal pain and severe diarrhœa, for which she was admitted into the Campbellpur Hospital, India, where she remained until August, 1906. This illness was diagnosed and treated as typhoid fever.

Prior to the onset of this illness the patient had been unaware of the presence of an abdominal tumour. The menstrual function has varied considerably, having sometimes been excessive, but since the commencement of the attack of typhoid fever in April, 1906, there has been complete amenorrhœa. During convalescence, when the patient had become very emaciated, her doctors discovered a small lump in the abdomen. The tumour was extremely mobile and free from pain and tenderness. Since then it had gradually increased in size until her admission into Chelsea Hospital for Women. There have never been any symptoms referable to the tumour apart from its size and presence. Since the attack of typhoid the patient has been quite free from febrile attacks and has gained in weight.

On examination the abdomen was found to be occupied by a large tumour rising from the pelvis up to the umbilicus mesially and to the costal margins laterally. Fluctuation and a fluid thrill were readily obtainable. It was dull on percussion, but a resonant colonic note was observed on the left side, but not on the right.

Bimanual examination showed the uterus to be normal and distinct from the tumour, which lay quite above the fundus uteri. The diagnosis of ovarian cystoma was made.

Cœliotomy through a medium subumbilical incision was performed on April 27th by Mr. Bland-Sutton. A large, congested, plum-coloured, cystic swelling presented, its

anterior surface being covered like a veil by a thin sheet of omentum, which was extensively adherent to it. There were no other adhesions. The appearance of the tumour suggested an ovarian cyst with twisted pedicle. It was found to be a cyst of the left ovary, but there was no torsion of the pedicle. It was removed entire without difficulty. The abdomen was closed in three layers without drainage. An ideal recovery followed; the wound healed by primary union; the temperature never rose above 99° F., and the patient was discharged from hospital in excellent health on June 13th.

The structures removed consisted of the left appendages. The Fallopian tube and mesosalpinx were somewhat stretched and elongated, but were otherwise normal. The ovary was replaced by a unilocular cystic tumour, about the size of a man's head, with some ragged omental adhesions attached to its surface. On incision a uniform greenish-yellow purulent fluid, free from odour, escaped, to the amount of two-and-a-half pints.

The cyst wall was about $\frac{1}{4}$ in. in thickness, and its internal surface was rough, dark red, and necrotic-looking. Microscopic examination showed it to consist of two layers, an outer layer composed of fibrous tissue infiltrated with small round cells, and an inner layer of diffusely-staining necrotic tissue. Epithelial elements were wanting. No micro-organisms could be discovered.

The purulent contents were examined microscopically in films stained by Löffler's methylene blue. They consisted of granular detritus in which were a few degenerated leucocytes. No bacteria could be observed in the films.

Cultures were at once made on agar slopes, and these were incubated at 37° C. A sparse grey growth slowly developed, there being very slight growth at the end of forty-eight hours. This was found to consist of delicate slender rods, with slightly rounded ends, which were not very actively motile, non-spore bearing, stained readily with the ordinary aniline dyes, and were Gram-negative.

In sub-cultures on the various media motility became very active and typical typhoid bacilli.

The following sub-cultures were made, with the results as stated :—

Agar streak.—Thin, translucent, shiny, spreading greyish growths.

Gelatine streak.—Grey, glistening growth with irregular borders, no liquefaction.

Gelatine stab.—Growth in depth, no liquefaction.

Potato.—White, almost invisible growth, no discolouration of the potato.

Broth.—Growth with uniform turbidity.

Glucose agar stab.—Growth along stab, no production of gas.

Neutral red broth.—No change.

Litmus milk.—No coagulation, slight permanent acidity.

Lactose peptone water.—No change.

Dulcite peptone water.—No change.

Glucose peptone water.—Acid, no gas.

Mannite peptone water.—Acid, no gas.

Durham's peptone water.—No indol production.

Conradi-Drigalski plates.—Blue growth, no reddening of medium.

Capaldi-Proskauer Medium No. I.—No growth or change in reaction.

Capaldi-Proskauer Medium No. II. — Growth with markedly acid reaction.

All these culture-reactions are typical of the *B. typhosus* and serve to differentiate it from allied members of the typhoid-coli group.

Agglutination tests, which are specific for the *B. typhosus*, were then undertaken as follows :

A rabbit received injections of typhoid bacilli at intervals until its serum would agglutinate the *B. typhosus* in dilutions of 1 : 4000. This serum was also found to agglutinate the bacilli obtained from the ovarian cyst in dilutions of 1 : 4000. As a control, the agglutinating power of normal rabbits' serum was tested, and was found

positive in dilutions of 1 : 200 but negative in dilutions of 1 : 400, *i. e.* to dilutions ten times stronger than that of the treated animal producing agglutination.

Widal's reaction with the patient's serum and the typhoid bacillus was performed : agglutination was extremely well marked in dilutions of 1 : 100, and present, though less perfect, in dilutions of 1 : 1000 with the time limit of one hour.

Pfeiffer's phenomenon, *i. e.* the production of bacteriolysis in the peritoneal cavity of a guinea pig, injected with the bacilli and with the serum of an immunised animal, could not be obtained. This was due to want of virulence of the bacilli, as control animals, *i. e.* guinea pigs injected with the bacilli and with normal rabbits' serum, were unaffected. For the production of this phenomenon the use of virulent bacilli is essential, otherwise the bacilli are destroyed in the guinea pig's peritoneal cavity. Pfeiffer's phenomenon could, however, have been produced in an indirect manner, even with this avirulent strain, if it were employed for the preparation of an immune serum, and the serum so obtained were tested along with a known virulent culture of typhoid bacilli. The performance of this indirect method was deemed to be unnecessary.

In this case, then, a bacillus was obtained in pure culture from the pus of a suppurating ovarian cyst twelve months after an attack of typhoid fever. This bacillus has been definitely proved from a comprehensive study of its morphological, tinctorial, cultural, and serum-agglutinating properties, to be the *B. typhosus*. Further, the febrile illness from which the patient suffered last year has been definitely proved by the agglutinating powers of her serum with typhoid bacilli to have been typhoid fever.

I consider, however, that as the bacillus isolated from the cyst-contents was not pathogenic to guinea pigs, at first grew feebly and slowly on agar, and at first possessed feeble motility, and was present in such scanty numbers that it could not be observed in the pus, it had almost lost its vitality in the pus (pus possessing well-marked

bactericidal properties), and if the cyst had been allowed to remain for some time longer its contents would have become sterile.

It has long been a recognised clinical fact that suppuration occasionally occurs in ovarian cysts after an attack of typhoid fever, but the first to obtain typhoid-like bacilli from the purulent contents was Werth, in 1893, and since then eleven more cases have been recorded. At this date, however, the methods of identifying the *B. typhosus* were unsatisfactory, and were not sufficient to differentiate the various members of the typhoid-coli group of bacilli. It was not until the discovery of the specific agglutinins that the *B. typhosus* could be identified with certainty, and Wallgren, in 1899, seems to have been the first to apply sero-diagnostic methods to the bacilli so obtained.

The difficulty of diagnosing typhoid fever from clinical signs and symptoms is well known, and this disease has been so closely simulated by suppurating ovarian cysts that it has been diagnosed when this condition existed, and the patient has been treated for typhoid fever until the (possibly accidental) discovery of the tumour has corrected the diagnosis. In some of the earlier recorded cases, prior to the application of bacteriological methods, it may have been the illness preceding the removal of a suppurating ovarian cyst may have been of this nature and not typhoid fever at all. Nowadays, by the application of modern clinical methods it would be easy to differentiate between these two conditions. Typhoid fever would give a fall of leucocytes (*i. e.* leucopenia) on blood examination, a positive diazo-reaction in the urine, a positive Widal reaction with the patient's serum, and the *B. typhosus* could be cultivated from the blood, whereas in a suppurative inflammation in an ovarian cyst there would be a rise in the number of leucocytes in the blood (*i. e.* leucocytosis), a negative diazo-reaction in the urine and a negative Widal's reaction.

A case recorded by Lewis and Le Conte shows the

value of a blood examination in these conditions. A patient with an ovarian cyst developed typhoid fever, and this was accompanied by a leucopenia. Suppuration then occurred in the cyst and a leucocytosis was noted. The cyst was then tapped vaginally, reinfection from the cut surface resulted in a relapse, and a leucopenia again resulted.

Two points of interest are suggested by a consideration of my case, viz.: (1) Infection of the cyst contents by means of the blood-steam; and (2) the production of pus by a pure typhoid infection.

In the absence of bowel adhesions the bacilli must have been carried to the cyst by means of the blood-stream. That typhoid bacilli may enter the circulating blood has been proved by the employment of improved culture media; thus Castellani obtained typhoid bacilli from the blood by culture in twelve out of fourteen cases. On this ground the metastatic transference of the bacilli to various regions and organs of the body, and the occurrence therein of post-typhoid suppuration is not difficult to explain. Such suppuration has been observed, not only in ovarian cysts, but also in the lungs, lymph-glands, diaphragm, the salivary glands, the testis, the thyroid, the gall-bladder, the joints, and with greatest frequency of all in the bones as a suppurative periostitis. As regards the production of pus by a pure typhoid infection, it was long denied, especially by Baumgarten and Fraenkel, that the *B. typhosus* was possessed of pyogenetic properties, and that when such occurred a mixed infection was present, suppuration being caused by the other organisms present; or that the pus-producing organisms had been over-grown by the *B. typhosus*. The incorrectness of this view was settled by Kruse, who collected in Flügge's 'Handbook' a large series of experimental observations, by himself and others, which have conclusively proved the possession of pyogenetic properties by the *B. typhosus*.

From the bacteriological standpoint, post-typhoid suppuration, both in ovarian cysts and in other regions of the body, three varieties may occur:

(1) A mixed infection, where both pyogenetic cocci and *B. typhosus* are present.

(2) A secondary infection caused by invasion with pyogenetic cocci of the organ whose resisting power has been lessened as the result of typhoid fever.

(3) A pure infection, caused by the *B. typhosus*, which undoubtedly possesses pyogenetic properties under suitable conditions.

The case I have just recorded provides a typical example of the last-named variety.

The PRESIDENT said the Society was indebted to the author for the very complete account and scientific investigation of this case. He quite agreed with his opinion that most cases described as typhoid fever complicated by ovarian tumours were really suppurating ovarian tumours, and that the "typhoid" fever was due to the suppuration. He had seen a few cases of that kind. He had, however, removed a suppurating ovarian tumour from a patient who was suffering from typhoid fever in the opinion of a distinguished physician. He asked Dr. Taylor whether Widal's reaction was considered positive proof of the presence of typhoid fever; he knew that physicians did not regard it as such a few years ago. He was surprised to hear that the *Bacillus typhosus* could survive in ovarian fluid for twelve months, for ovarian fluid seemed to have some influence in delaying the action of putrefactive organisms.

Dr. C. NEPEAN LONGRIDGE, referring to the latency of typhoid bacilli in the body, said that pure cultures of typhoid bacilli had been grown from the gall-bladder two or three years after the original attack, and he believed he was right in saying that cultures had been obtained from the interior of gall-stones. The question of leucopenia was one of great interest and importance, since the leucopenia could be demonstrated before a Widal's reaction could be obtained, and thus assist in the early diagnosis of typhoid fever. He remembered two cases, in one of which bronchitis and in the other periostitis had given rise to a leucocytosis in cases of typhoid, but he could not say that these complications were not due to a secondary infection.

Mr. ALBAN DORAN referred to his case of perforating ulcers of the ileum from obstruction after ovariotomy, published in the thirtieth volume of the 'Transactions of the Pathological Society.' A young woman, when under treatment for a condition diagnosed as typhoid fever, was examined and an abdominal tumour was discovered. Five weeks later a suppurating multilocular ovarian cyst was removed. There was evidence of recent peritonitis.

The patient died on the twelfth day. A coil of ileum was found obstructed by adhesions and twisted, and nearly a foot above it was a perforating ulcer, with several others, less advanced, in its neighbourhood. Dr. Goodhart failed to find any trace of ulceration in Peyer's patches.

Dr. TAYLOR said he was interested to hear the President's experience of cases where suppurating ovarian cysts had closely simulated typhoid fever, as he himself had no experience of such cases, having based the remarks in his paper on this condition on descriptions he had come across in reading the literature of this subject. As regards the value of Widal's reaction in diagnosis, much depended upon the technique of its performance, especially with regard to the dilution and time limit employed. The reaction was of extremely great value and assistance, but, like all things human, was not absolutely infallible. Under certain conditions a negative reaction might be obtained in cases of true typhoid fever, whereas a positive reaction might also be obtained under other conditions. It was also interesting to observe that in typhoid fever the reaction might be intermittent and present one day and absent the next, so that a single negative reaction was of little value. The President's suggestion of the possible antiseptic properties of ovarian cyst fluids was new to him. In reply to Dr. Longridge, he remarked that typhoid cholecystitis occasionally causes the formation of gall-stones in which typhoid bacilli have been found many years after typhoid fever. The case of Drs. Lewis and Le Conte, already quoted, went to show that suppuration caused by a pure typhoid infection may give rise to a leucocytosis, their results and those obtained by Dr. Longridge in cases of suppurative typhoid periostitis being quite in accord. Dr. Taylor confessed that he was unaware of Mr. Doran's interesting case, as he had only looked up the literature since the employment of bacteriological methods in these cases. It was impossible to express an opinion on the nature of Mr. Doran's case in the absence of any bacteriological examination, which, however, would have been of little value in 1879, as our knowledge of *Bacillus typhosus* was then very imperfect.

TWO UTERI WITH "FUNDAL LIGAMENT" AFTER HYSTEROPEXY.

Shown by Dr. FRANK E. TAYLOR.

CASE 1.—E. C—, single, aged 29, was admitted to Chelsea Hospital for Women on November 25th, 1905,

under the care of Dr. W. H. Fenton. She complained of dysmenorrhœa so severe as to cause vomiting, menstruation being irregular, the loss being excessive and accompanied by clots; there was also some vaginal discharge.

Menstruation had commenced at the age of twenty and was always painful, irregular and variable in amount from the commencement. The patient had had gastric ulcer seven years and pleurisy two years previously respectively.

She was an in-patient in the Women's Hospital, Birmingham, in May, 1905, where an operation said to be curettage was performed. No improvement followed, patient being unable to move about during menstruation on account of severe abdominal pain.

A satisfactory pelvic examination was only possible under ether, and this was made by Dr. Berkeley on December 12th, 1905, when the uterus was found to be retroflexed. Dr. Fenton performed hysteropexy on December 8th, a satisfactory recovery followed, and the patient was discharged on January 2nd, 1906.

Again there was no improvement, and in addition to dysmenorrhœa patient was never free from a constant gnawing pain in the left iliac region. The patient accordingly went into the Radcliffe Infirmary, Oxford, where she remained without any definite benefit for three months. No surgical treatment seems to have been undertaken there.

She returned to Chelsea for hysterectomy in March, 1907, and on March 15th supra-vaginal hysterectomy was performed by Dr. Fenton. There was a good recovery and patient left the hospital on April 2nd, quite relieved of all her symptoms.

The specimen consists of the body of the uterus, slightly uniformly enlarged, from the anterior surface of which near the fundus springs a "fundal ligament" 1 in. broad and $1\frac{1}{4}$ in. in length.

Case 2.—E. J—, married, aged 38, was admitted into

Chelsea Hospital for Women on June 21st, 1907, under Mr. Bland-Sutton's care, complaining of painful and excessive menstruation. She had had two children eighteen and a half and seventeen and a half years ago respectively and one miscarriage fourteen years ago. Left salpingo-oöphorectomy and ventro-fixation of the uterus were performed in the Middlesex Hospital in 1896. Since then the catamenia have been very irregular or have occurred every fortnight, lasting seven days, the loss being very profuse and always accompanied by very severe pain.

Abdominal hysterectomy and right salpingo-oöphorectomy were performed on June 24th by Mr. Bland-Sutton.

The removed uterus was slightly and uniformly enlarged, the tip of the cervix being absent. It measured 3 in. in length and weighed 3½ oz. Attached to the anterior wall just below the fundus is a "fundal ligament" 2¼ in. in length and a little thicker than a goose-quill.

The appendages removed showed slight chronic inflammatory changes, the tube and ovary being adherent to each other, but the abdominal ostium of the tube was patent and the ovary contained a recent corpus luteum.

The dangers of intestinal obstruction over a band caused by such a fundal ligament is self-evident.

Dr. DRUMMOND ROBINSON remarked that a surgical colleague of his had recently operated on a woman, on whom hysteropexy had some time previously been performed, because she had developed symptoms of acute intestinal obstruction. It was found that a fibrous band, similar to those shown by Dr. Taylor, extended from the fundus uteri to the abdominal scar, and in this the small intestine had become entangled.

Mrs. BOYD asked whether the patients had been pregnant after the suspension. Pregnancy, by dragging on and stretching of adhesion of uterus to peritoneum of anterior abdominal wall, might result in the formation of such bands. She was accustomed to teach that methods of suspension that allowed free play for the uterus were good for pregnancy but bad for the chances of intestinal obstruction.

Dr. LEWERS said that he generally had adopted Kelly's method of suspending the uterus, stitching it to the peritoneum and subperitoneal tissue of the abdominal wall only. The result of that

operation was to produce a band of adhesions similar to that shown in Dr. Taylor's specimen. He had not so far met with any bad result from the presence of such a band.

Mr. Alban Doran could readily understand how obstruction occurred after hysteropexy. In the course of an operation of that class he had witnessed the slipping of a loop of intestine into the space between the parietes and the uterus, below the lowest uterine suture. In order to avoid such an accident Mr. Doran always passed a suture through the fold of peritoneum on the inner side of each round ligament, fixing the two folds to the parietal peritoneum close under the lowest uterine suture.

Dr. Taylor, in reply to Mrs. Boyd, said that neither of these patients had been pregnant since the hysteropexy had been performed. In reply to Dr Williamson he stated that he had no definite information as to the method of performing the hysteropexy which had been employed in these two cases. In the first case the method was probably the one employed by Dr. Fenton, in which the peritoneum is sewn to a broad surface on the anterior abdominal wall, as far removed from the fundus as possible. In the second case the operation had been performed in another hospital. In Mr. Targett's cases, where Cæsarian section was necessary, no fundal ligament seems to have been present; the difficulty resulted from too extensive and unyielding fixation of the uterus to the anterior abdominal wall. Dr. Taylor considered Mr. Targett's opinion, that the normal Fallopian tube is as likely to cause intestinal obstruction as a fundal ligament, to be quite erroneous. The two conditions were not parallel. A fundal ligament forms a narrow band stretching unsupported across the peritoneal cavity with two fixed ends—one attached to the abdominal wall, the other to the anterior aspect of the uterus, whereas the Fallopian tube merely occupies the edge of a broad sheet of tissue—the broad ligament—which prevents any possible chance of bowel slipping beneath the Fallopian tube and so becoming obstructed. Dr. Taylor also noted that Mr. Doran fully recognised the possibility of the formation of a fundal ligament after hysteropexy and its dangers, and was pleased to learn Mr. Doran's method of obliterating the space beneath the attachment of the uterus to the abdominal wall, and so obviating the possibility of subsequent intestinal obstruction.

HÆMORRHAGE IN UTERINE FIBROID.

Shown by J. H. Targett, M.S.

MALIGNANT DISEASE OF CERVIX IN ONE-HORNED UTERUS.

Shown by Miss Aldrich-Blake.

Miss Aldrich-Blake showed a uterus and appendages. Right horn of uterus undeveloped; cervix affected by malignant disease; tubes and ovaries of normal size, the fimbriated ends of both tubes occluded. Removed from a woman aged 32, who had been married fifteen years; had had one child prematurely at eight months; no other pregnancy. The periods had begun at sixteen and been regular, scanty, and painless.

SKELETON OF EXTRA-UTERINE FŒTUS.

Shown by Miss Aldrich-Blake.

Miss Aldrich-Blake showed the skeleton of an extra-uterine fœtus, found lightly attached to the upper aspect of the right tube about ¾ in. from its fimbriated end. All soft parts and all trace of sac or clot had been completely absorbed. The head is missing, the remainder has shrunk together into a small, rounded mass. Judging from the amount of ossification rather than the size, Miss Aldrich-Blake took it to be of between three and four months' development. It was removed from a woman, aged 30, who had been married ten years and had one child seven years before the operation. There was no history of a previous illness typical of extra-uterine gestation; the pregnancy seven years ago had been a normal one. An attack of "slight peritonitis" unassociated with amenorrhœa a few months after marriage marked the most probable date of the occurrence.

The President asked on what grounds the fœtus was said to be of three and a half to four months' development. The specimen, which consisted of a shrivelled fœtus minus its head,

appeared to be about $\frac{1}{3}$ in. in diameter, and the length of its spine not more than $\frac{3}{4}$ in. He did not think it could be of much more than two months' development. It must be remembered that an intra-uterine fœtus of three and a half to four months' development would measure 5 in. or 6 in. in length. He did not think it possible that the small body shown could represent a fœtus of that length. He paid more attention to the size of the fœtus than to the degree of development of the orifice centres, having shown many years ago how much the time of appearance of the centres of ossification in the head of the humerus differed from that given in the text-books of anatomy.

Dr. Lewers said that in the course of an operation for removing a recent tubal gestation on the left side, he had found a spherical body of the size of a large cherry attached to the right tube among a mass of adhesions. This proved to be a fœtus, and in spite of its small size Mr. Keith, who had kindly examined the specimen, considered it represented a fœtus of between three and four months' development.

TWO SPECIMENS OF FIBROID ASSOCIATED WITH BLEEDING AFTER THE MENOPAUSE.

Shown by Dr. Lewers.

(1) A section under the microscope of a fibroid polypus, the size of a walnut, removed from a patient, aged 72. A fortnight before the patient was seen she had had some vaginal bleeding, having previously had no loss of blood since the menopause, which occurred at about the age of fifty. It was interesting to find that she had had a fibroid polypus removed when she was about forty-five. On the occurrence of the bleeding, of course, some suspicion was raised that a malignant growth might be present, but fortunately the result of the microscopical examination was to show that the growth was entirely benign.

(2) A specimen of a uterus enlarged by fibroids removed by abdominal hysterectomy from a single woman, aged 67. The "tumour" corresponded to the size of the pregnant uterus at the seventh month. The patient had been known to have fibroids for at least thirty years.

The menopause had occurred, and for about nine or ten years afterwards the patient had no symptoms at all. Within the last three years the patient had had more or less vaginal bleeding, at first intermittent, and afterwards continuous and rather profuse. On examination the specimen was seen to consist of the uterus much enlarged by several fibroids; one large fibroid, partly cervical, was undergoing hyaline degeneration; but at the very highest part of the endometrium there was a patch of soft growth the size of a shilling, which on microscopical examination was found to be adeno-carcinoma. The patient made an uneventful recovery after the operation, and so far has remained well. Owing to the size of the tumour and the great length of the uterine cavity it would have been practically impossible to obtain a portion of the patch in question for examination before deciding on hysterectomy.

CALCIFIED UTERINE FIBRO-MYOMA REMOVED PIECEMEAL FOR HÆMORRHAGE FOURTEEN YEARS AFTER OÖPHORECTOMY.

Shown by Dr. Herbert Spencer.

The tumour, of the size of a small lemon, weighing 5 oz., was removed on May 24th of this year, on account of hæmorrhage of two months' duration, probably caused by the friction of the hard calcified lower portion of the tumour on the endometrium, which was atrophied, as shown by microscopic examination of portions removed with the curette. The cervix was dilated by a laminaria tent and the tumour found to be sessile, and the lower end of it, which was about as big as a walnut, was of stony hardness and irregular on the surface. The tumour was removed piecemeal by a many-toothed volsella after it had been enucleated from its bed with the finger. The calcification rendered the morcellement difficult; in such

a case a lithotrite would probably be useful. The patient made a painless and afebrile recovery.

The case was interesting on account of the fact that he had performed bilateral oöphorectomy on the patient in August, 1893, on account of profound anæmia due to hæmorrhage produced by the fibro-myoma. The uterus at that time was of the size of a large fœtal head. The uterus soon shrank to half its former bulk and all hæmorrhage ceased after the operation. The symptoms of the climacteric set in soon after the oöphorectomy, but gave little trouble, the patient having been in perfect health for nearly fourteen years when the hæmorrhage occurred. The result of the oöphorectomy had been very satisfactory, but the sequel showed that it would have been better to have removed the tumour, leaving the ovaries.

Dr. Heywood Smith asked the President whether, in the case he had just narrated, he had observed the size of the uterus greatly diminished and to what, after so many years, he attributed the recurrence of the growth and hæmorrhage.

A SPECIMEN OF DIAPHRAGMATIC HERNIA IN A NEW-BORN BABY.

Shown by C. Nepean Longridge, M.D.

The stomach, small intestine and spleen were in the left pleural cavity. The heart was pushed over to the right side. The infant died about half an hour after birth and was full time.

Mr. Eardley Holland said that he had seen two cases of congenital diaphragmatic hernia, which were of especial interest because in both cases the children had survived birth for a considerable length of time, though it would seem hardly possible that an infant with such a serious malformation could exist. The first child was aged 4 months, and was admitted in a comatose and cyanosed condition. A diagnosis of thrombosis of the central sinuses was hazarded. The child survived twelve hours, and the true state of affairs was revealed by a *post-mortem*

examination. The whole of the intestinal tract, with the exception of the stomach, the first part of the duodenum, and the descending colon, occupied the right pleural cavity. The duodenum had a long mesentery. Distension of the intestines with gas, and the consequent embarrassment of the heart and left lung had evidently been the cause of death. A short time afterwards another child, aged 2 months, was admitted with signs of bronchopneumonia in the left lung. Over the right side of the chest the physical signs were vague; there were areas of hyper-resonance and other areas of dulness. The child survived three days. In spite of the fact that this case was under observation for three days, and was examined by excellent clinicians, who had the former case fresh in their memories, it was never suspected that the case was one of diaphragmatic hernia. A *post-mortem* examination revealed an exactly similar condition as in the former case. These cases show that the diagnosis of such a condition during life must be exceptionally difficult.

The PRESIDENT recalled four cases of congenital diaphragmatic hernia he had shown to the Society with remarks on the diagnosis of the condition (vol. xxxii, p. 132; vol. xxxiii, p. 34).

MAMMARY GLAND OF NEW-BORN INFANT.

Shown by C. NEPEAN LONGRIDGE, M.D.

THE heart of a full-time male infant. The breast was enlarged and full of cystic spaces. Several drawings illustrating the development of the infantile breast were shown at the same time.

MYXOMATOUS FIBROID.

Shown by Mrs. SCHARLIEB, M.D., M.S.

MRS. L. D—, aged 26; married three years; has never been pregnant. First seen April 30th, 1907. Periods regular, last four to five days, flow moderate, no pain; bowels regular; appetite good; digestion good. Has noticed some enlargement of the abdomen during the last few months, but no symptoms whatever.

On examination the abdomen was filled with a large uniform tumour which yielded a sense of free fluctuation. *Diagnosis :* ovarian cyst.

Operation, May 8th, 1907, under $CHCl_3$. On opening the abdomen a very pale tumour presented in the wound ; it appeared to be a cyst and it was thought that it was retro-peritoneal owing to the colour of its capsule. It was, however, found that although the trocar entered readily no fluid was tapped. The abdominal wound was therefore enlarged and the abdomen thoroughly explored. It was perfectly evident that the tumour, whatever its nature, was behind the peritoneum, but layer after layer of capsule was cut and stripped back without being able to free the mass. Finally, when it was turned out it was found that the intestines had been pushed away in every direction and that they were in no case adherent to the tumour. The lymphatics in both broad ligaments were so distended that they resembled large bunches of white grapes. Both ovaries and tubes were diseased and were removed with the tumour.

The mass was sent to Dr. Cuthbert Lockyer, who kindly furnished the following description :

Macroscopical Report.

The specimen consists of the entire uterus (except perhaps a thin shaving of the portio-vaginalis cervicis), the appendages and a large uniformly soft growth attached to the whole length of the anterior wall of the corpus uteri.

The uterus measures $4\frac{1}{2}$ in. in length. It is a narrow, thin, atropic organ. Its mucosa is pale and atrophied, the bulk of the cavity being lined by a smooth, thin, yellowish-grey membrane.

For examination it has been opened along the whole of its posterior free surface.

The Fallopian tubes are thinned out and stretched, measuring 6 in. each in length. The meso-salpinges are not opened up by the growth. The ovaries are enlarged

and flattened; the right measures 2½ in. along its attached border and 1½ in. in vertical measurement; the left measures 3 in. along its attachment and 1½ in. in the vertical. On section both organs have a pale fibrous appearance, and are very œdematous; no recent corpora lutea are present, but small corpora albicantia are seen.

The right round ligament is very thin; it measures 5 in. in length; its terminal end is lost in a peritoneal flap investing the top of the large growth. The left round ligament has been cut off 2 in. from the left cornu uteri.

The tumour.—This growth is a flabby, spherical mass, which sinks down and flattens out considerably by its own weight when placed on a hard surface. Its circumference measures 42 in. and it is 15 in. in its maximum diameter, whilst its vertical height is 6 in.; its weight is 23½ lb. A shallow sulcus divides it into two portions, and in this groove lies the uterus, whilst the appendages pass out across the lobes on either side. Of the two lobes the larger lies to the right and the smaller to the left of the uterus. It has no connection whatever with the cervix, nor with the posterior uterine wall, but it is intimately connected with the front of the body of the uterus; therefore with the uterus placed in the vertical the entire tumour lies in front of it.

The bulk of the growth presents a raw uncovered surface, but the peritoneum of the fundus uteri and of the appendages passes off on to the left lobe, covering its upper part and also to a lesser extent over a part of the right and larger lobe. The tumour looks as if it had been very largely extra- or retro-peritoneal, but it had not opened up the mesosalpinx on either side nor yet the meso-ovarium.

The tumour cuts with a pale, glistening, œdematous surface, which everywhere excludes a pale fluid, but no definite cysts are seen.

Histological.—The muscle has undergone myxomatous change, and has extensively disappeared, so that in sec-

tions stained by Van Gieson's method the bulk of what remains is fibrous tissue-bundles, the intervening muscle being either wanting or too degenerate to take on the yellow stain.

MEETING OF COUNCIL.

A meeting of Council was held on July 19th, 1907, at which a letter from the Secretary of the Royal Society of Medicine (Mr. MacAlister) was read, dated June 13th, 1907, addressed to the Secretary and Librarian (Miss Hannam) stating that, as the Royal Society of Medicine could not advantageously make use of part only of her time—the conditions being such that the whole time of all the officers and servants of the Society would be required—it was decided to adopt the proposal of the Obstetrical Society, and to grant her a pension of £65 a year to begin as from 1st October next.

This pension is in lieu of the honorarium of £300 voted by the Council and reported to the General Meeting on April 3rd, 1907 (see p. 136).

OBSTETRICAL SOCIETY OF LONDON.

Abstract of Receipts and Payments from January, 1907, to June, 1907.

RECEIPTS.

1907.	£ s. d.	£ s. d.
To balance from 1906 . . .		71 8 6
„ (1) Annual Subscriptions .		341 5 0
„ (2) Composition Fees . .		10 10 0
„ (3) Sale of 'Transactions' .		2 19 3
„ (4) Interest on Debentures .	40 7 0	
Ditto on Consols . .	7 2 6	
Ditto on L.C.C. 3% Stock	11 10 2	
Ditto on Victoria Government Stock .	8 9 0	
		67 8 8
„ (5) Sale of £628 12s. 0d. N. B. Railway Debenture 3% Stock		530 0 0

Investments:

£834 8 0	N. British Railway 3% Debentures.
1641 18 0	Midland Railway 2½% „
600 0 0	Consols.
807 10 0	L.C.C. 3% Stock.
500 0 0	Victoria Government 3½% Stock.
£4383 16 0	

£1023 11 5

G. E. HERMAN, *Treasurer.*

July 22nd, 1907.

PAYMENTS.

1907.	£ s. d.	£ s. d.
By (1) 'Transactions' . .		251 19 1
„ (2) Library:		
Books purchased . .	27 11 5	
Binding . . .	18 12 6	
		46 3 11
„ (3) Museum and Library:		
Rent . . .	100 0 0	
Librarian's Salary .	154 5 6	
Repairs, Cleaning, etc. .	20 11 10½	
		274 17 4½
„ (4) Expenses of Meetings .		28 16 10
„ (5) Stationery, Stamps, and Printing . . .		40 10 0¼
„ (6) Extraordinary Expenses .		33 3 0
„ (7) Banking Expenses . .		0 2 4
„ (8) Balance at Bank . .		347 14 10
In hand .		0 4 0¼

£1023 11 5

Audited and approved.

NEWSON-SMITH, LORD & MUNDY,
Chartered Accountants.

INDEX.

PAGE

Address (*Annual*) *of the President* (W. R. Dakin, M.D.) . 66
—— (*Inaugural*) *of the new President* (H. R. Spencer, M.D.) . 117
Adeno-carcinoma of the ovary (F. N. Boyd) . . 50
After-history of the case of fibroid of broad ligament associated with an ovarian cyst reported in the forty-third volume of the Society's 'Transactions' (A. Doran) . 94
Aldrich-Blake (Louisa B.), malignant disease of cervix in one-horned uterus (shown) 270
—— skeleton of extra-uterine fœtus (shown) . . 270
Anderson (L. Garrett), *Remarks* in discussion on H. R. Andrews's two cases of pregnancy in a rudimentary uterine horn 214
Andrews (H. R.), supposed sarcoma of the cervix (shown) . 137
—— two cases of pregnancy in a rudimentary uterine horn . 209
—— *Remarks* in discussion on W. F. Shaw's paper on the pathology of chronic metritis . . . 42

Baby, new-born, diaphragmatic hernia in (C. N. Longridge) . 273
Bacillus typhosus, suppuration in an ovarian cyst caused by (F. E. Taylor) 257
Beckett-Overy (H.), *Remarks* in discussion on A. Doran's paper on malignant vaginal polypus secondary to an adrenal tumour of the kidney . . . 205
Blacker (G. F.), chorionepithelioma of the uterus; lutein cysts in both ovaries 104
—— *Remarks* in reply 104
—— suppurating fibroid tumour of the uterus (shown) . 100
—— *Remarks* in reply 114
—— —— in discussion on W. S. A. Griffith and H. Williamson's paper on chorionepithelioma complicated by hæmatometra 254

PAGE

Bladder, intra-peritoneal rupture of, occurring during labour (C. R. Porter) 170
Bland-Sutton (J.), villous tumour of the body of the uterus in a woman aged 84; vaginal hysterectomy; recovery . 46
—— uterus four years after Cæsarean section (shown) . 174
—— *Report* of Committee 93
Bleeding after the menopause, fibroid associated with (A. H. N. Lewers) 271
Boyd (F. N.), adeno-carcinoma of the ovary (shown) . 50
—— pregnancy in the right cornu of a fibroid uterus (shown) 49
—— *Remarks* in discussion on J. D. Malcolm's paper on the advisability of removing the cervix in performing hysterectomy for fibro-myomatous uterine tumours . 165
—— —— in discussion on F. E. Taylor's specimen of uteri with "fundal ligament" after hysteropexy . . 268
Briggs (Henry), ovarian pregnancy (shown) . . 222
—— early tubal mole (shown) 223
—— fibroid tissue formed around a needle and removed from the left labium majus (shown) . . . 223
Broad ligament, fibroid of, after-history (A. Doran) . 94

Cæsarean section, uterus four years after (J. Bland-Sutton) . 174
Cancer of the cervix, supposed recurrence after vaginal hysterectomy for (C. Hubert Roberts) . . . 114
—— two specimens from cases of, the patients remaining free from recurrence twenty and eleven years respectively after operation (A. H. N. Lewers) . . . 179
Champneys (F. H.), vote of thanks to President . . 133
Chorio-endothelioma of uterus; intra-peritoneal hæmorrhage; hysterectomy; death (G. B. Ferguson) . . 57
Chorionepithelioma of the uterus; lutein cysts in both ovaries (G. F. Blacker) 104
—— complicated by hæmatometra (W. S. A. Griffith and H. Williamson) 242
—— primary embolic, of the vagina (H. T. Hicks) . . 224
Cullingworth (C. J.), *Remarks* in discussion on Amand Routh's specimen of fibroid of uterus with a sarcomatous nodule in the centre 4
—— *Remarks* in discussion on A. Donald's paper on chronic septic infection of the uterus and its appendages . 18
—— —— in discussion on W. F. Shaw's paper on the pathology of chronic metritis 41

PAGE

Cyst, ovarian, suppuration in, caused by the *bacillus typhosus* (F. E. Taylor) 257

Dakin (W. R.), *Remarks* in discussion on W. F. Shaw's paper on the pathology of chronic metritis . . . 41
Dauber (J. H.), fibro-myomatous uterus with a calcified fibroid lying free in its cavity . . . 139
—— *Remarks* in reply 141
Donald (Archibald), chronic septic infection of the uterus and its appendages 6
Doran (Alban), after-history of the case of fibroid of broad ligament associated with an ovarian cyst, reported in the forty-third volume of the Society's 'Transactions' . 94
—— *Remarks* in reply 97
—— malignant vaginal polypus secondary to an adrenal tumour of the kidney 182
—— *Remarks* in reply 206
—— —— in discussion on C. Lockyer's specimen of bilateral primary tuberculous salpingitis with secondary infection of the perivascular lymphatics of the uterine wall . 141
—— —— in discussion on J. D. Malcolm's paper on the advisability of removing the cervix in performing hysterectomy for fibro-myomatous uterine tumours . 165
—— —— in discussion on F. E. Taylor's case of suppuration in an ovarian cyst caused by the *Bacillus typhosus* . 265
—— —— in discussion on F. E. Taylor's specimen of uteri with "fundal ligament" after hysteropexy . . 269

Eden (T. W.), *Remarks* in discussion on C. Lockyer's specimen of bilateral primary tuberculous salpingitis with secondary infection of the perivascular lymphatics of the uterine wall 146
—— —— in discussion on J. D. Malcolm's paper on the advisability of removing the cervix in performing hysterectomy for fibro-myomatous uterine tumours . 166
Election of new Fellows . . 1, 45, 93, 169, 256

Ferguson (G. Bagot), chorio-endothelioma of uterus; intraperitoneal hæmorrhage; hysterectomy; death . . 57
Fibro-myoma uteri; suppuration in, following premature delivery, treated by abdominal hysterectomy (W. W. H. Tate) 54

PAGE

Fibro-myoma, calcified uterine, removed piecemeal for hæmorrhage fourteen years after oöphorectomy (H. R. Spencer) 272
Fœtus, extra-uterine, skeleton of (L. B. Aldrich-Blake) . 270

Gland, mammary, of new-born infant (C. N. Longridge) . 273
Gray (Archibald M. H.), *Remarks* in discussion on C. N. Longridge's specimen of dilated ureters in stillborn infants 215
Griffith (W. S. A.), and Herbert Williamson, chorion-epithelioma complicated by hæmatometra . . 242
—— *Remarks* in discussion on J. Bland-Sutton's specimen of a uterus four years after Cæsarean section . . 179

Hæmatometra, chorionepithelioma complicated by (W. S. A. Griffith and H. Williamson) 241
Hæmorrhage fourteen years after oöphorectomy, calcified uterine fibro-myoma removed piecemeal for (H. R. Spencer) 272
—— intra-peritoneal; chorio-endothelioma of uterus, hysterectomy; death (G. B. Ferguson) . . . 57
—— in uterine fibroid (J. H. Targett) . . . 269
Hannam (Miss), honorarium to, voted . . . 136
—— pension voted in lieu of honorarium . . . 277
Heart, rupture of, in a stillborn infant (C. N. Longridge) . 214
Herman (G. Ernest), *Remarks* in discussion on F. N. Boyd's specimen of pregnancy in the right cornu of a fibroid uterus 50
—— —— in discussion on G. F. Blacker's specimen of suppurating fibroid tumour of uterus . . . 103
Hernia, diaphragmatic, in a new-born baby (C. N. Longridge) 273
Hicks (Henry Thomas), primary embolic chorionepithelioma of the vagina 224
Holland (Eardley), *Remarks* in discussion on C. N. Longridge's specimen of diaphragmatic hernia in a new-born baby 273
Honorarium to Miss Hannam, voted . . . 136
—— cancelled by pension 277
Horrocks (Peter), *Remarks* in discussion on A. Doran's after-history of a case of fibroid of broad ligament associated with an ovarian cyst, reported in the forty-third volume of the Society's 'Transactions' . . . 97
—— —— in discussion on G. F. Blacker's specimen of suppurating fibroid tumour of uterus . . . 103

PAGE

Hysterectomy for fibromyomatous uterine tumours, advisability of removing the cervix in performing (J. D. Malcolm) 148
—— vaginal, for cancer of the cervix, supposed recurrence after (C. Hubert Roberts) 114
—— —— for villous tumour of the body of the uterus in a woman, aged 84; recovery (J. Bland-Sutton) . . 46
Hysteropexy, two uteri with "fundal ligament" after (F. E. Taylor) 266

Infants, dilated ureters in stillborn (C. N. Longridge) . 215
Infant, new-born, mammary gland of (C. N. Longridge) . 274
Infection, chronic septic, of the uterus and its appendages (A. Donald) 6

Kidney, adrenal tumour of, to which a malignant vaginal polypus was secondary (A. Doran) . . . 182

Labium majus, fibroid tissue formed around a needle and removed from the left (H. Briggs) . . . 223
Lewers (A. H. N.), two specimens from cases of cancer of the cervix, the patients remaining free from recurrence twenty and eleven years respectively after operation . 179
—— two specimens of fibroid associated with bleeding after the menopause (shown) 271
—— *Remarks* in discussion on A. Doran's after-history of the case of fibroid of broad ligament associated with an ovarian cyst, reported in the forty-third volume of the Society's 'Transactions' 96
—— —— in discussion on J. Bland-Sutton's specimen of a uterus four years after Cæsarean section . . 178
—— —— in discussion on F. E. Taylor's specimen of uteri with "fundal ligament" after hysteropexy . . 268
—— —— in discussion on L. B. Aldrich-Blake's specimen of skeleton of extra-uterine fœtus . . . 271
Ligament, fundal, two uteri with, after hysteropexy (F. E. Taylor) 266
List of Officers and Council for 1907 for the Section of Obstetrics and Gynæcology 136
Lockyer (C.), bilateral primary tuberculous salpingitis with secondary infection of the perivascular lymphatics of the uterine wall 141
—— *Remarks* in reply 141

PAGE

Lockyer (C.), *Remarks* in discussion on Amand Routh's specimen of fibroid of uterus with a sarcomatous nodule in the centre 4
—— —— in discussion on W. F. Shaw's paper on the pathology of chronic metritis 42
—— —— in discussion on J. Bland-Sutton's specimen of a villous tumour of the body of the uterus in a woman, aged 84 49
—— —— in discussion on H. R. Andrews's specimen of supposed sarcoma of the cervix 139
—— —— in discussion on J. H. Dauber's specimen of fibro-myomatous uterus with a calcified fibroid lying free in its cavity 141
—— —— in discussion on A. Doran's paper on a malignant vaginal polypus secondary to an adrenal tumour of the kidney 205
—— —— in discussion on W. S. A. Griffith and H. Williamson's paper on chorionepithelioma complicated by hæmatometra 253
—— *Report* on Amand Routh's specimen of fibro-myoma uteri, showing invasion by a mixed-celled sarcoma in which multi-nucleated giant cells predominate . . 3
Longridge (C. Nepean), rupture of the heart in a stillborn infant (shown) 214
—— dilated ureters in stillborn infants (shown) . . 215
—— diaphragmatic hernia in a new-born baby (shown) . 273
—— mammary gland of new-born infant (shown) . . 274
—— *Remarks* in discussion on F. E. Taylor's case of suppuration in an ovarian cyst caused by the *Bacillus typhosus* 265

Malcolm (J. D.), on the advisability of removing the cervix in performing hysterectomy for fibro-myomatous uterine tumours 148
—— *Remarks* in reply 167
—— —— in discussion on G. F. Blacker's specimen of suppurating fibroid tumour of uterus . . 104
—— —— in discussion on C. Lockyer's specimen of bilateral primary tuberculous salpingitis with secondary infection of the perivascular lymphatics of the uterine wall . 141
Mammary gland of new-born infant (C. N. Longridge) . 273
Menopause, fibroid associated with bleeding after the (A. H. N. Lewers) 271

PAGE
Metritis, pathology of chronic (W. F. Shaw) . . 19
Milligan (Wyndham Anstruther), *Remarks* in discussion on J. Bland-Sutton's specimen of a villous tumour of the body of the uterus in a woman aged 84 . . 48
Mole, early tubal (H. Briggs) 223

Nodule, sarcomatous, in the centre of a fibroid of uterus (A. Routh) 1

Obstetrics and Gynæcology, Section of, of the Royal Society of Medicine 136
Oöphorectomy, calcified uterine fibro-myoma removed piecemeal for hæmorrhage fourteen years after (H. R. Spencer) 272
Ovaries, lutein cysts in both, in chorionepithelioma of the uterus (G. F. Blacker) 104
Ovary, adeno-carcinoma of (F. N. Boyd) . . . 50
Ovum, entire full-time, in twins (R. Wise) . . 147

Papilloma, inoperable, of the left ovary (Amand Routh) . 216
Parturition at term, in co-existing tubal and uterine pregnancy; abdominal section (W. W. H. Tate) . . 51
Parturition, intra-peritoneal rupture of bladder occurring during (C. R. Porter) 170
—— premature, suppuration in fibro-myoma uteri following, treated by abdominal hysterectomy (W. W. H. Tate) . 54
Pathology of chronic metritis (W. F. Shaw) . . 19
Pelvis, organs of, in a case where inoperable papilloma of the left ovary had been found seven years previously (A. Routh) 216
Pension to Miss Hannam 277
Perithelioma of the uterus (G. F. Darwall Smith) . . 97
Polypus, malignant vaginal, secondary to an adrenal tumour of the kidney (A. Doran) 182
Porter (Charles R.) (introduced by Dr. Russell Andrews), intra-peritoneal rupture of the bladder occurring during labour 170
Pregnancy, co-existing tubal and uterine; abdominal section; subsequent delivery at term (W. W. H. Tate) . . 51
—— in a rudimentary uterine horn (H. R. Andrews) . 209
—— in the right cornu of a fibroid uterus (F. N. Boyd) . 49
—— ovarian (H. Briggs) 222

PAGE

Report of the Council 135
—— *of the Honorary Librarian* (Dr. W. J. Gow) . . 64
—— (*audited*) *of the Treasurer* (Dr. G. Ernest Herman) 62, 63
—— *of the Pathology Committee on Amand Routh's specimen of a fibro-myoma of the uterus with a sarcomatous nodule in the centre* (*see p.* 1) 45
—— —— *on Bland-Sutton's specimen of a villous tumour of uterus from a patient aged* 84 (*see p.* 46) . . 93
—— —— *on G. F. Darwall Smith's specimen of perithelioma of the uterus* (*see p.* 97) 136
—— —— *on H. Russell Andrews's specimen of supposed sarcoma of cervix* (*see p.* 137) 169
—— —— *on May Thorne's specimen of uterus showing malignant villous tumour and a fibroid undergoing sarcomatous change* (*see p.* 181) 207
—— —— *on Alban Doran's specimen of a malignant vaginal polypus secondary to an adrenal tumour* (*see p.* 182) . 208
—— —— *on H. Briggs's specimen of ovarian pregnancy* . 256
—— —— *on J. H. Dauber's specimen of fibro-myomatous uterus containing a calcified fibroid lying free in the uterine cavity* 257
—— —— *on H. T. Hicks's specimen of primary vaginal embolic chorion epithelioma* 257
Roberts (C. Hubert), supposed recurrence after vaginal hysterectomy for cancer of the cervix . . 114
Robinson (G. Drummond), *Remarks* in discussion on F. E. Taylor's specimen of uteri with "fundal ligament" after hysteropexy 268
Routh (Amand), fibroid of uterus with a sarcomatous nodule in the centre (shown) 1
—— pelvic organs of a case where inoperable papilloma of the left ovary had been found seven years previously (shown) 216
—— *Remarks* in discussion on W. F. Shaw's paper on the pathology of chronic metritis . . . 41
—— —— in discussion on J. Bland-Sutton's specimen of a villous tumour of the body of the uterus in a woman, aged 84 48
—— —— in discussion on F. N. Boyd's specimen of pregnancy in the right cornu of a fibroid uterus . . 50
—— —— in discussion on G. F. Blacker's case of chorion-epithelioma of the uterus; lutein cysts in both ovaries . 113

PAGE

ROUTH (Amand), *Remarks* in discussion on J. D. Malcolm's paper on the advisability of removing the cervix in performing hysterectomy for fibro-myomatous uterine tumours 165
—— —— in discussion on J. Bland-Sutton's specimen of a uterus four years after Cæsarean section . . 178
Rupture of the heart in a still-born infant (C. N. Longridge) 214

Salpingitis, bilateral primary tuberculous, with secondary infection of the perivascular lymphatics of the uterine wall (C. Lockyer) 141
Sarcoma, supposed of the cervix (H. R. Andrews) . . 137
SCHARLIEB (Mary A. D.), myxomatous fibroid (shown) . 274
SHAW (William F.), pathology of chronic metritis . . 19
Skeleton of extra-uterine fœtus (L. B. Aldrich-Blake) . 270
SMITH (G. F. Darwall), perithelioma of the uterus (shown) . 97
—— *Remarks* in reply 100
—— *Report* of Committee 136
SMITH (Heywood), *Remarks* in discussion on J. Bland-Sutton's specimen of a uterus four years after Cæsarean section . 178
—— —— in discussion on H. R. Spencer's specimen of calcified uterine fibro-myoma removed piecemeal for hæmorrhage fourteen years after oöphorectomy . . 272
SPENCER (H. R.), *Inaugural Address* as President . . 117
—— myomatous uterus weighing over seven pounds removed from a woman aged 22 219
—— calcified uterine fibro-myoma removed piecemeal for hæmorrhage fourteen years after oöphorectomy . 272
—— *Remarks* in discussion on A. Doran's after-history of the case of fibroid of broad ligament associated with an ovarian cyst, reported in the forty-third volume of the Society's 'Transactions' 96
—— —— in discussion on G. F. Blacker's specimen of suppurating fibroid tumour of uterus . . . 103
—— —— in discussion on G. F. Blacker's case of chorion-epithelioma of the uterus; lutein cysts in both ovaries . 113
—— —— in discussion on H. R. Andrews's specimen of supposed sarcoma of the cervix 139
—— —— in discussion on J. H. Dauber's specimen of fibro-myomatous uterus with a calcified fibroid lying free in its cavity 141

PAGE

SPENCER (H. R.), *Remarks* in discussion on C. Lockyer's specimen of bilateral primary tuberculous salpingitis with secondary infection of the perivascular lymphatics of the uterine wall 145
—— —— in discussion on J. D. Malcolm's paper on the advisability of removing the cervix in performing hysterectomy for fibro-myomatous uterine tumours . 167
—— —— in discussion on J. Bland-Sutton's specimen of a uterus four years after Cæsarean section . . 177
—— —— in discussion on A. H. N. Lewers's specimens from cases of cancer of the cervix, the patients remaining free from recurrence twenty and eleven years respectively after operation 180
—— —— in discussion on F. E. Taylor's case of suppuration in an ovarian cyst caused by the *Bacillus typhosus* . 265
—— —— in discussion on L. B. Aldrich-Blake's specimen of skeleton of extra-uterine fœtus . . . 270
—— —— in discussion on C. N. Longridge's specimen of diaphragmatic hernia in a new-born baby . . 274
Suppuration in an ovarian cyst caused by the *Bacillus typhosus* (F. E. Taylor) 257
—— in fibro-myoma uteri following premature delivery, treated by abdominal hysterectomy (W. W. H. Tate) . . 54

TARGETT (J. H.), hæmorrhage in uterine fibroid (shown) . 269
—— *Remarks* in discussion on G. F. Darwall Smith's specimen of perithelioma of the uterus 100
—— —— in discussion on C. H. Roberts's case of supposed recurrence after vaginal hysterectomy for cancer of the cervix 114
—— —— in discussion on W. S. A. Griffith and H. Williamson's paper on chorionepithelioma complicated by hæmatometra 253
TATE (W. W. H.), co-existing tubal and uterine pregnancy; abdominal section; subsequent delivery at term . 51
—— suppuration in fibro-myoma uteri following premature delivery, treated by abdominal hysterectomy . . 54
TAYLOR (Frank E.), suppuration in an ovarian cyst caused by the *Bacillus typhosus* 257
—— *Remarks* in reply 266
—— two uteri with "fundal ligament" after hysteropexy . 266

PAGE
TAYLOR (Frank E.), *Remarks* in reply . . . 269
—— —— in discussion on W. F. Shaw's paper on the pathology of chronic metritis 43
THORNE (May), uterus showing malignant villous tumour and a fibroid which has undergone sarcomatous change . 181
Tissue, fibroid, formed around a needle, and removed from the left labium majus (H. Briggs) . . . 223
Tumour, adrenal, of the kidney, with malignant vaginal polypus (A. Doran) 182
—— fibroid, associated with bleeding after the menopause (A. H. N. Lewers) 271
—— —— of broad ligament associated with an ovarian cyst, reported in the forty-third volume of the Society's 'Transactions' (A. Doran) 94
—— —— calcified, lying free in the cavity of a fibro-myomatous uterus (J. H. Dauber) 139
—— —— of uterus, with a sarcomatous nodule in the centre (A. Routh) 1
—— —— which has undergone sarcomatous change in a uterus showing malignant villous tumour (M. Thorne) . 181
—— —— of uterus, suppurating (G. F. Blacker) . . 100
—— —— myxomatous (M. A. D. Scharlieb) . . 274
—— —— of uterus, hæmorrhage in (J. H. Targett) . 268
Tumours, fibro-myomatous, uterine, advisability of removing the cervix in performing hysterectomy for (J. D. Malcolm) 148
Tumour, villous, of the body of the uterus in a woman æt. 84; vaginal hysterectomy; recovery (J. Bland-Sutton) . 46
—— malignant villous, in a uterus and a fibroid which has undergone sarcomatous change (M. Thorne) . . 181
Twins, entire full-time ovum in (R. Wise) . . . 147

Ureters dilated, in still-born infants (C. N. Longridge) . 215
Uteri with "fundal ligament" after hysteropexy (F. E. Taylor) 266
Uterus, chorio-endothelioma of; intra-peritoneal hæmorrhage; hysterectomy; death (G. B. Ferguson) . . 57
—— chorionepithelioma of; lutein cysts in both ovaries (G. F. Blacker) 104
—— fibroid, pregnancy in the right cornu of (F. N. Boyd) . 49
—— fibroid of, with a sarcomatous nodule in the centre (A. Routh) 1
—— suppurating fibroid tumour of (G. F. Blacker) . . 100

PAGE

Uterus, fibro-myomatous, with a calcified fibroid lying free in its cavity (J. H. Dauber) 139
—— four years after Cæsarean section (J. Bland-Sutton) . 174
—— myomatous, weighing over seven pounds removed from a woman, aged twenty-two (Herbert R. Spencer) . 219
—— one-horned, malignant disease of cervix in (L. B. Aldrich-Blake) 269
—— perithelioma of (G. F. Darwall Smith) . . 97
—— rudimentary horn of, pregnancy in (H. R. Andrews) . 209
—— showing malignant villous tumour and a fibroid which has undergone sarcomatous change (M. Thorne) . 181
—— villous tumour of the body of, in a woman aged 84; vaginal hysterectomy; recovery (J. Bland-Sutton) . 46
—— wall of, secondary infection of the peri-vascular lymphatics of in bilateral primary tuberculous salpingitis (C. Lockyer) 141
—— and its appendages, chronic septic infection of (A. Donald) 6
—— cervix of, advisability of removing, in performing hysterectomy for fibro-myomatous uterine tumours (J. D. Malcolm) 148
—— cervix uteri, cancer of, the patients remaining free from recurrence twenty and eleven years respectively after operation (A. H. N. Lewers) 179
—— —— —— malignant disease of, in one horned (L. B. Aldrich-Blake) 270
—— —— —— supposed sarcoma of (H. R. Andrews) . 137
—— —— —— supposed recurrence after vaginal hysterectomy for cancer of the cervix (C. Hubert Roberts) . 114

Vagina, primary embolic chorionepithelioma of (H. T. Hicks) 224

Williamson (Herbert), *see* W. S. A. Griffith.
Wise (Robert) entire full-time ovum in twins . . 147

OBSTETRICAL SOCIETY.

ADDITIONS TO THE LIBRARY

BY DONATION OR PURCHASE DURING THE YEAR 1907.

Presented by

Ahlfeld (F.). Neuere Bestrebungen auf dem Gebiete der exakten Beckenmessung. (Volkmann's Sammlung klinischer Vorträge, neue Folge, Nr. 443) (Serie xv, Heft 23.) 8vo. Leipzig, 1907 — Purchased.

Bar (Paul). Leçons de pathologie obstétricale. Deuxième fascicule. *illust.*, 8vo. Paris, 1907 — Ditto.

Bland-Sutton (J.). Tumours, innocent and malignant: their clinical characters and appropriate treatment. 4th edition. *illust.*, 8vo. London, 1906 — Author.

Budin (Pierre). The nursling: the feeding and hygiene of premature and full-term infants. Authorised translation by William J. Maloney, M.B., Ch.B., with an introduction by Sir Alexander R. Simpson, M.D., LL.D., D.Sc. *illust.*, 8vo. London, 1907 — Purchased.

Casalis (G. A.). The treatment of uterine retrodeviations. *illust.*, 8vo. Capetown, Pretoria, and Bulawayo, 1906 — Dr. Cullingworth.

Catalogue of Books added to the Radcliffe Library, Oxford University Museum during the year 1906. 4to. Oxford, 1907 — Radcliffe Librarian.

Presented by

FREUND (H. W.). Operation einer ausgetragenen Abdominalschwangerschaft; Versenkungen der Placenta in die Bauchhöhle. (Volkmann's Sammlung klinischer Vorträge, neue Folge, Nr. 448.) 8vo. Leipzig, 1907 — Purchased.

HERMAN (G. Ernest). Difficult labour. New edition. *illust.*, sm. 8vo. London, Paris, New York and Melbourne, 1906 — Author.

——— First lines in midwifery. A guide to attendance on natural labour for medical students and midwives. New edition. *illust.*, sm. 8vo. London, Paris, New York, and Melbourne, 1907 — Ditto.

——— Diseases of women. A clinical guide to their diagnosis and treatment. New and revised edition. *illus.*, 8vo. London, Paris, New York, and Melbourne, 1907 — Ditto.

HOFBAUER (J.). Die menschliche Placenta als Assimilationsorgan. (Volkmann's Sammlung klinischer Vorträge, neue Folge, Nr. 454) (Serie xvi, Heft 4.) 8vo. Leipzig, 1907 — Purchased.

KROEMER (Paul). Untersuchungen über den Bau der menschlichen Tube zur Klärung der Divertikelfrage mittels Modell-Rekonstruktion nach Born. *illust.*, 8vo. Leipzig, 1906 — Journ. Obst. and Gyn. British Empire.

NEUGEBAUER (Fr. von). Zur Lehre von der Zwillingsschwangerschaft mit heterotopem Sitz der Früchte das eine Ei in cavo uteri das andere extrauterin gelagert. Kasuistik von 171 Fällen nebst zwei eigenen Beobachtungen. 8vo. Leipzig, 1907 — Purchased.

POZZI (S.). Traité de gynécologie clinique et opératoire. Quatrième édition revue et augmentée avec la collaboration de F. Jayle. Tome ii. *illust.*, 8vo. Paris, 1907 — Ditto.

RUNGE (Max). Lehrbuch der Gynäkologie. Dritte Auflage. *illust.*, 8vo. Berl. 1907 — Ditto.

STRASSMANN (P.). Wasser und Messer in der Gynäkologie. (Volkmann's Sammlung klinischer Vorträge, neue Folge, Nr. 451) (Serie xvi, Heft 1.) 8vo. Leipzig, 1907 — Ditto.

Presented by

TARNIER (S.) et P. BUDIN. Traité de l'art des accouchements. Tome quatrième. Dystocie fœtale. Accidents de la délivrance. Opérations. Infections puerpérales. *illust.*, 8vo. Paris, 1901 Purchased.

THUMIM (Leopold). Die Zystoskopie des Gynäkologen. (Volkmann's Sammlung klinischer Vorträge, neue Folge, Nr. 444-5) (Serie xv, Heft 24-5.) 8vo. Leipzig, 1907 Ditto.

VEIT (J.). Handbuch der Gynäkologie. Zweite völlig umgearbeitete Auflage. Erster Band. *illust.*, 8vo. Wiesbaden, 1907 Ditto.

——— Handbuch der Gynäkologie. Zweite völlig umgearbeitete Auflage. Zweiter Band. *illust.*, 8vo, Wiesbaden, 1907 Ditto.

VOLKMANN'S Sammlung klinischer Vorträge, neue Folge:

441. *Winckel*, Shakespeare's Gynäkologie.
443. *Ahlfeld*, Neuere Bestrebungen auf dem Gebiete der exakten Beckenmessung.
444-5. *Thumim*, Die Zystoskopie des Gynäkologen.
448. *Freund*, Operation einer ausgetragenen Abdominalschwangerschaft; Versenkung der Placenta in die Bauchhöhle.
451. *Strassmann*, Wasser und Messer in der Gynäkologie.
454. *Hofbauer*, Die menschliche Placenta als Assimilationsorgan.

WINCKEL (Franz von). Shakespeare's Gynäkologie. (Volkmann's Sammlung klinischer Vorträge, neue Folge, Nr. 441) (Serie xv, Heft 21.) 8vo. Leipzig, 1906 Ditto.

——— Handbuch der Geburtshülfe. Dritter Band, iii Teil. *illust.*, 8vo, Wiesbaden, 1906 Ditto.

WINTER (Georg). Lehrbuch der gynäkologischen Diagnostik. Dritte, gänzlich umgearbeitete Auflage. *illust.*, 8vo. Leipzig, 1907 Ditto.

TRANSACTIONS.

AMERICAN GYNECOLOGICAL SOCIETY—
Transactions, vol. xxxi for 1906. 8vo. Phila. 1906 Society.

MEDICAL SOCIETY OF LONDON—
Transactions, vols. xxvii and xxviii, 1905. 8vo. London, 1905 Ditto.

——— ——— vol. xxix. 8vo. London, 1906 Ditto.

REPORTS.

	Presented by
America—Hospitals—Boston Lying-in Hospital; the 74th year for 1906. 8vo. Boston, 1907	Hospital Staff.
——— ——— Johns Hopkins Hospital (the Reports), vols. xiii and xiv. la. 8vo. Balt. 1906	Ditto.
——— ——— The Society of the New York Hospital. Annual Report for the year 1906. 8vo. New York, 1906	Society.
Hospitals—Guy's Hospital Reports. Third Series, vol. xlv. 8vo. Lond. 1906	Hospital Staff.
——— Madras Government Maternity Hospital. Annual Report for the year 1905. la. 8vo, Madras, 1906	Ditto.
——— St. Bartholomew's Hospital Reports, vol. xlii, 1906. 8vo. Lond. 1907	Ditto.
——— St. Thomas's Hospital Reports, New Series, vol. xxxiv. 8vo. Lond. 1906	Ditto.
——— Westminster Hospital Reports, vol. xv. 8vo. Lond. 1907	Ditto.
Lying-in Institutions—Germany—Ueber ein sehr-junges menschliches Ei *in situ*, von Prof. Dr. G. Leopold. IV. Band der Arbeiten aus der Königlichen Frauenklinik in Dresden. *illust.*, 8vo. Leipzig, 1906	Purchased.

PRINTED BY ADLARD AND SON, LONDON AND DORKING.

GENERAL INDEX

TO THE

TRANSACTIONS

OF THE

OBSTETRICAL SOCIETY OF LONDON

FOR

VOLS. I TO XLIX

1859—1907

BY

MISS AGNES HANNAM

SECRETARY AND LIBRARIAN OF THE OBSTETRICAL SOCIETY

London

PRINTED BY ADLARD AND SON

BARTHOLOMEW CLOSE, E.C.

1908

Table of Reference to the dates of the Sessions included in each volume of the 'Transactions':

Vol. I.	1859.
II.	1860.
III.	1861.
IV.	1862.
V.	1863.
VI.	1864.
VII.	1865.
VIII.	1866.
IX.	1867.
X.	1868.
XI.	1869.
XII.	1870.
XIII.	1871.
XIV.	1872.
XV.	1873.
XVI.	1874.
XVII.	1875.
XVIII.	1876.
XIX.	1877.
XX.	1878.
XXI.	1879.
XXII.	1880.
XXIII.	1881.
XXIV.	1882.
XXV.	1883.
Vol. XXVI.	1884.
XXVII.	1885.
XXVIII.	1886.
XXIX.	1887.
XXX.	1888.
XXXI.	1889.
XXXII.	1890.
XXXIII.	1891.
XXXIV.	1892.
XXXV.	1893.
XXXVI.	1894.
XXXVII.	1895.
XXXVIII.	1896.
XXXIX.	1897.
XL.	1898.
XLI.	1899.
XLII.	1900.
XLIII.	1901.
XLIV.	1902.
XLV.	1903.
XLVI.	1904.
XLVII.	1905.
XLVIII.	1906.
XLIX.	1907.

GENERAL INDEX

TO THE

TRANSACTIONS OF THE OBSTETRICAL SOCIETY OF LONDON

FOR

VOLS. I—XLIX, 1859—1907.

ABDOMEN, systematic examination of, for rectifying malpositions of the fœtus in labour (A. W. Edis) . . . xiv, 331
„ macerated fœtus removed two months after spurious labour from the cavity of (Alban Doran) . . . xlii, 8
„ palpation of the, diagnosis of placenta prævia by (H. R. Spencer) xxxi, 203
„ retention of a fœtus in, for forty-three years (R. W. Watkins) viii, 106
„ and chest, the change in size of, during the lying-in period, and the effect of the binder upon them (G. E. Herman) . xxxii, 108

ABDOMINAL SECTION, fifteen months after conception, and eight months after death of fœtus (J. B. Hellier) . . xlv, 366
„ the value of, in certain cases of pelvic peritonitis (C. J. Cullingworth) . . . . . xxxiv, 254
„ fœtus, sac, and pelvic viscera from (Alban Doran) . . xxix, 491
„ followed by localised sloughing of fundus uteri in a case of acute septicæmia (C. J. Cullingworth) . . . xxx, 406
„ ligature discharged after (W. S. Playfair) . . . xxxiii, 386
„ in a case of extra-uterine fœtation (J. B. Hicks) . . ix, 93
„ in a case of extra-uterine pregnancy (J. Braxton Hicks) . xxii, 141
„ — (J. Knowsley Thornton) . . . xxiv, 51, 81
„ — (G. E. Herman) . . . . xxviii, 141
„ in the latter half of pregnancy, the child being alive in cases of extra-uterine gestation (F. H. Champneys) . . xxix, 456
„ in a case of extra-uterine pregnancy at full term; recovery (J. W. Taylor) . . . . . xxxiii, 115
„ for removal of extra-uterine gestation (C. J. Cullingworth) . xxxv, 155
„ extra-uterine gestation (John Phillips) . . . xxxv, 162
„ (E. Sinclair Stevenson) . . . . . xxxv, 175

ABDOMINAL SECTION (*continued*)—
„ performed after four or five months in a case of extra-uterine gestation in which fœtal death occurred at term after spurious labour (John Phillips) . . . . xlii, 121
„ in a case of extra-uterine gestation in which fœtal death occurred at the eighth month after spurious labour (A. Doran) . . . . . xlii, 213
„ in four cases of ruptured extra-uterine gestation occurring in two women; recovery (A. J. Sturmer) . . . xlv, 144
„ [tubal] (Sydney Jones) . . . . . xxvi, 268
„ tubo-abdominal gestation at the fourth month of pregnancy removed by (G. F. Blacker) . . . . xlviii, 137
„ for repeated tubal pregnancy (C. E. Purslow) . . xlvii, 181
„ unruptured tubal gestation removed by (W. Duncan) xxxvii, 197
„ in co-existing tubal and uterine pregnancy; subsequent delivery at term (W. Tate) . . . . xlix, 51
„ and removal of sac in a full-term pregnancy in a rudimentary horn of uterus; missed labour (five months) (J. H. Targett) xlii, 276
„ associated with intra-uterine pregnancy (A. L. Galabin) . xxiii, 141
„ performed during the life of the fœtus at the thirty-fifth week of gestation (John Williams) . . . xxix, 482
„ performed eight months after death of fœtus (C. J. Cullingworth) . . . . . xxx, 480
„ removal of living fœtus (T. R. Jessop) . . . xviii, 261
„ for removal of uterus and both ovaries (Thos. Chambers) . xxiii, 12
„ for hæmatosalpinx and papillomatous ovarian cyst (J. Knowsley Thornton) . . . . . xxvi, 4
„ chorionic villi from a tubal mole removed by (A. H. N. Lewers) . . . . . xxxviii, 106
„ tubal mole removed by (A. H. N. Lewers) . . xxxvii, 78
„ dermoid ovarian cyst impacted in the pelvis removed by, during the ninth month of pregnancy (Thomas H. Morse) xxxviii, 221
„ for dermoid cyst of the ovary five years after causing obstruction to labour (W. W. H. Tate) . . . xlvi, 344
„ for removal of suppurating ovarian cyst which had obstructed labour (W. W. H. Tate) . . . . xlii, 164
„ for removal of fibroid tumour of the ovary (John Williams) . xxv, 35
„ for removal of fibro-myoma of the right ovary (C. H. Carter) . xxix, 190
„ for abscess of the uterus developing during the puerperium (A. W. W. Lea) . . . . . xlvi, 7
„ adeno-carcinoma of uterus and left ovary removed by (W. Duncan) . . . . . xxxix, 289
„ fibro-cystic tumour of the uterus removed by (A. H. N. Lewers) . . . . . xxxvi, 270
„ two specimens of fibroid tumour removed by (G. G. Bantock) xxiv, 91
„ five cases of fibroid tumours of the uterus removed by (G. G. Bantock) . . . . . xxiv, 301
„ for removal of calcified uterine fibroids in elderly women (W. S. A. Griffith) . . . . . xlviii, 17
„ Porro-Cæsarean hysterectomy with retro-peritoneal treatment of the stump in a case of fibroids obstructing labour; with remarks upon the relative advantages of the modern Porro operation over the Sänger-Cæsarean in most other cases requiring (A. Routh) . . . . . xlii, 244
„ four cases of removal of large uterine myomata by (Lawson Tate) . . . . . xix, 274
„ see *Gastrotomy, Laparotomy.*

ABDOMINAL WALL, abscess in (R. J. Probyn-Williams) . xxxvi, 62
ABNORMALITY of uterus, congenital, simulating retention of menses (J. Braxton Hicks) . . . . xxii, 260
„ see *Fœtus*, retroflexion of, *Malformations, Monsters.*

ABOLITION of craniotomy from obstetric practice, in all cases where the fœtus is living and viable (W. T. Smith) . i, 21
ABORTION artificially induced, followed by peritonitis (R. Barnes) iii, 419
„ at six and a half months, with general dropsy of the fœtus (Protheroe Smith) . . . . . xvii, 303
„ case of (W. S. A. Griffith) . . . . . xxxv, 37
„ case of death following vaginal injection of acid nitrate of mercury to produce (John Phillips) . xxxii, 308; xxxiii, 180
„ criminal (J. Shortt) . . . . . ix, 6
„ decidua vera and reflexa from a very early (G. E. Herman) . xxxii, 272
„ followed by septicæmia and fatal cardiac thrombosis (J. T. Musgrave) . . . . . xxi, 81
„ habitual (Leith Napier) . . . . . xxxii, 389
„ hæmorrhage due to retained placenta, supposed to be the placenta of a previous (A. W. Williams) . . . viii, 317
„ showing recent placental hæmorrhage (R. Wise) . . xl, 257
„ induction of, as a therapeutic measure (Sir W. O. Priestley) . xxii, 271
„ — in a patient labouring under cancerous disease of the uterus and rectum (F. W. Mackenzie) . . . i, 11
„ — with subsequent removal of carcinomatous cervix by supra-vaginal amputation (A. H. N. Lewers) . . . xxx, 81
„ influence of lead-poisoning in producing (B. Baker) . . viii, 41
„ knitting-needle used to procure (W. Duncan) . . xxxiv, 223
„ missed, specimen of (G. Roper) . . . . xxii, 108
„ — (H. C. Pope) . . . . . xxiv, 139
„ — with slight cystic degeneration of the chorion (G. E. Herman) . . . . . xxii, 44
„ — fœtus and membranes from a case of (Alban Doran) . xxvii, 224
„ — in which an early embryo in its amniotic sac was retained in the uterus for eight months (W. Duncan) . .xxxvii, 196
„ in which there occurred separate primary and complete expulsion of the unbroken amnion, enclosing a fœtus of about four months' gestation (Graily Hewitt) . . . xxxiii, 461
„ simple maieutic for the induction of premature labour or (Peter Horrocks) . . . . . xxxviii, 168
„ notes of a case of malignant disease of the uterus with numerous deposits in the lungs, and death following (J. D. Malcolm) . . . . . xxxviii, 125
„ procured by tents of common sea tangle (W. E. Pritchard) . v, 198
„ the relation between backward displacements of the uterus and prolonged hæmorrhage after delivery and (G. E. Herman) xxxiv, 14
„ on the relation between backward displacement of the uterus, sterility and (G. E. Herman) . . . . xxxiii, 499
„ retention of the ovum within the uterus and growth of membranes for a period of five months after the death of the fœtus (W. Guttewitt) . . . . . iii, 411
„ retroflexion of the uterus as a frequent cause of (J. J. Phillips) xiv, 45
„ tetanus after (A. Wiltshire) . . . . xiii, 133
„ treatment of cases of, in which the placenta and membranes are retained (Sir W. O. Priestley) . . . iii, 146
„ tubal (J. Bland-Sutton) . . . . xxxii, 342
„ — (W. S. Playfair) . . . . .xxxvii, 224

ABORTION, tubal (*continued*)—
„ — (A. L. Galabin) . . . . . xli, 170
„ — with rupture of tube (A. Routh) . . . xliii, 294
„ — indisputable case of complete (C. J. Cullingworth) . xxxvii, 139
„ — in which the "mole" was in process of extrusion at the time of operation (J. Bland-Sutton) . . . xlii, 311
„ — (J. Bland-Sutton) . . . . . xliv, 44
„ — produced by bimanual examination (A. L. Galabin) . xlvii, 332
„ incomplete (L. Remfry) . . . . . xxxvi, 261
„ — hæmorrhage; operation; recovery (A. C. Butler-Smythe) . xl, 298
„ — showing intra-mural embedding of the placenta (C. Lockyer) . . . . . xlv, 191
„ twin (?) (J. C. Langmore) . . . . iv, 133
„ *report* on (G. Harley and T. H. Tanner) . . . iv, 165
„ enlargements of the uterus following (T. S. Beck) . . viii, 54
„ twin, one emaciated and one acephalous (Clement Godson) xvi, 100, 121
„ repeated (W. Newman) . . . . . iii, 408
„ with albuminuria and convulsions, in six successive pregnancies (W. H. Broadbent) . . . . i, 108
„ see *Miscarriage*.

ABSCESS in abdominal wall (R. J. Probyn-Williams) . . xxxvi, 62
„ chronic, of the female urethra (G. E. Herman) . . xxviii, 181
„ in a corpus luteum (J. D. Malcolm) . . . xlvii, 8
„ mammary, the prevention of, by the application of the principle of rest (W. B. Woodman) . . . . xvii, 9
„ multiple, of the ovary with pyosalpinx (C. J. Cullingworth) . xxxix, 47
„ of ovary (Heywood Smith) . . . . xxxiv, 3
„ of the ovary, three cases of pelvic inflammation attended with (C. J. Cullingworth) . . . . xxxvi, 277
„ ovarian, rupture twelve hours after labour (C. Berkeley) . xliv, 73
„ perimetric (W. S. A. Griffith) . . . . xxiv, 299
„ — retro-uterine (W. S. A. Griffith) . . . xxv, 18
„ in placenta (R. Barnes) . . . . viii, 149
„ in a case of puerperal septicæmia (A. Wiltshire) . . xviii, 181
„ splenic; death on sixteenth day after delivery in case of eclampsia; septic peritonitis (J. C. Holdich Leicester) . xlvii, 271
„ tubo-ovarian, large pyosalpinx simulating (C. J. Cullingworth) xxxiv, 437
„ — pyosalpinx simulating (C. J. Cullingworth) . xxxvii, 2
„ tubo-ovarian (W. Tate) . . . . xxxviii, 319, 380
„ genuine tubo-ovarian (C. J. Cullingworth) . . . xli, 39
„ of female urethra (F. C. Cory) . . . . xi, 65
„ in the uterus (W. F. Victor Bonney) . . . xlvi, 2
„ of the uterus developing during the puerperium; rupture into the peritoneal cavity; abdominal section; recovery (A. W. W. Lea) . . . . . xlvi, 7
„ and fibro-myoma (Wm. Duncan) . . . . xxxi, 332
„ cavity containing offensive pus in which was sarcoma of ovary showing necrosis of central portion (W. W. H. Tate) . xli, 373

ABSENCE of nose, congenital, right palpebral fissure, and right ear; imperforate anus, etc. (W. Duncan) . . xxxvii, 16
„ of uterus and breasts (L. Remfry) . . xxxvii, 12
„ of the uterus and occlusion of the vagina (F. Bousquet) . xxvii, 123

ABSORPTION of fibroid tumours of the uterus, with a report of a suspected case (Alban Doran) . . . . xxxv, 250
„ (?) of placenta in a case of gastrotomy for extra-uterine gestation, in which it never came away (J. Braithwaite) . xxviii, 33

ABSORPTION (*continued*)—
„ of thrombosis of the pulmonary artery in the puerperal state (W. S. Playfair) . . . . . xxvi, 162
ACARDIACUS acephalus (W. H. Kelson, introduced by Alban Doran) . . . . . xxxiii, 195
ACARDIAC acephalous fœtus (G. E. Herman) . . . xxxvi, 65
„ amorphous fœtus (G. E. Herman for G. M. Bluett) . . xxxiii, 493
„ mylacephalus, see *Monsters*.
„ twin, mylacephalous (H. Page) . . . . xxxiii, 302
„ from a cow (J. Bland-Sutton) . . . . xli, 97
„ fœtus, see *Monsters*.
ACCOUCHEURS qualified for the poor (J. T. Mitchell) . . xv, 3
ACEPHALOUS FŒTUS, see *Monsters*.
ACID nitrate of mercury, death following vaginal injection of (John Phillips) . . . . . xxxiii, 180
ACOUSTIC SIGN heard after the death of the fœtus (Robert Harvey) . . . . . xxi, 273
Adams (William), *report* on F. L. Neugebauer's specimens illustrating spondylolisthesis . . . . . xxvi, 186
Addinsell (A. W.), note on the effect of the influenza poison upon the lying-in woman . . . . xxxv, 333
„ case of fœtal deformity . . . . . xxxvii, 204
„ intermenstrual pain (Mittelschmerz) . . . xl, 137
„ microscopical slides from a case of intermenstrual pain (Mittelschmerz) . . . . . xli, 3
„ sections from the uterus of a bonnet monkey . . xli, 141
„ uterus and appendages with ruptured pregnant tube . xli, 172
„ unusual thickening of the endometrium in case of fibroids . xli, 231
„ solid tumour of the ovary removed from a woman aged 36 . xlii, 139
„ tubercular uterus . . . . . xlvii, 336
„ chronic infective metritis . . . . xlviii, 144
ADDRESS delivered at the first meeting of the Society, January 5th, 1859 (E. Rigby) . . . . . i, 1
„ loyal, to the King on the death of Queen Victoria . . xliii, 21
„ — *reply* . . . . . xliii, 143
„ to H.M. the Queen on the completion of the fiftieth year of her reign . . . . . xxix, 250
„ — *reply* of the Home Secretary to ditto . . . xxix, 350
ADDRESSES of condolence on the death of H.R.H. the Duke of Albany . . . . . xxvi, 85, 116
„ of Presidents:
Rigby (E.), i, 1; ii, 1. Smith (W. T.), iii, 3; iv, 6; v, 18. Oldham (H.), vi, 14; vii, 19. Barnes (R.), vii, 37; viii, 25; ix, 18. Davis (J. H.), ix, 30; x, 14; xi, 15. Hewitt (W. Graily), xi, 27; xii, 16; xiii, 5. Hicks (J. B.), xiii, 27; xiv, 25; xv, 16. Tilt (E. J.), xv, 30; xvi, 13; xvii, 24. Priestley (Sir W. O.), xvii, 36; xviii, 29; xix, 17. West (Charles), xix, 42; xx, 10; xxi, 5. Playfair (W. S.), xxi, 29; xxii, 55; xxiii, 46. Duncan (J. Matthews), xxiii, 64; xxiv, 32; xxv, 29. Gervis (Henry), xxv, 47; xxvi, 33; xxvii, 64. Potter (J. B.), xxvii, 85; xxviii, 52; xxix, 86. Williams (John), xxix, 99; xxx, 104; xxxi, 73. Galabin (A. L.), xxxi, 88; xxxii, 86; xxxiii, 41; Black (J. Watt), xxxiii, 76; xxxiv, 33; xxxv, 47; Herman (G. Ernest),

ADDRESSES of Presidents (*continued*)—
xxxv, 3; xxxvi, 75; xxxvii, 42; Champneys (F. H.), xxxvii, 83; xxxviii, 60; xxxix, 56. Cullingworth (C. J.), xxxix, 91; xl, 39, 91; xli, 50. Doran (A.), xli, 107; xlii, 43; xliii, 35. Horrocks (P.), xliii, 79; xliv, 53; xlv, 61. Malins (E.), xlv, 109: xlvi, 67; xlvii, 82. Dakin (W. R.), xlvii, 124; xlviii, 51; xlix, 66; Spencer (H. R.) . . . xlix, 117

ADENO-CARCINOMA of both ovaries (A. W. W. Lea) . . xliv, 225
„ of the ovary (F. N. Boyd) . . . . xlix, 50
„ of uterus and left ovary removed by abdominal section (W. Duncan) . . . . . xxxix, 289
„ of the body of the uterus in an early stage, with microscopical sections (E. W. Hey Groves) . . . . xlv, 138

ADENOMA (carcinoma), malignant, of the cervix uteri (F. J. McCann) . . . . . xl, 2
„ cystic, of the cervix (W. S. A. Griffith) . . . xxx, 4
„ of the labium (H. Williamson) . . . . xlviii, 235
„ unusual example of rupture of an ovarian (J. Bland-Sutton) . xli, 98
„ of the meatus urinarious externus (H. R. Spencer) . . xli, 383
„ of the portio vaginalis uteri forming a depressed sore or ulcer (J. Braithwaite) . . . . xxxvi, 208
„ of the uterus (T. W. Eden) . . . . xlii, 2
„ malignum of the body of the uterus (C. H. Roberts) . xlv, 86

ADENO-MYOMA, diffuse, of uterus (W. W. H. Tate) . . xlvi, 141
„ of the uterus (F. E. Taylor) . . . . xlvi, 188
„ uteri, three cases of (C. Lockyer). . . . xlviii, 84
„ — polyposum benignum (F. E. Taylor) . . . xlviii, 12

ADHERENT PLACENTA, see *Placenta*.

ÆTIOLOGY of gonorrhœa (Frederick J. McCann) . xxxviii, 225
„ of the sickness of pregnancy, observations on the (A. E. Giles) xxxv, 303

AFTER-HISTORIES of three cases of epithelioma of the vulva (A. H. N. Lewers) . . . . . xlviii, 163

AFTER-HISTORY of "a case of cystic fibroid with carcinoma of left ovary and right Fallopian tube" (brought before the Society five years ago) (R. Boxall) . . . xlviii, 136
„ of the case of fibroid of broad ligament associated with an ovarian cyst, reported in the forty-third volume of the Society's 'Transactions' (A. Doran) . . . xlix, 94

AGNEW (T. W.), the forceps in certain breech presentations . xix, 217

AIR in the vagina (A. Rasch) . . . . xii, 281

ALBANY, death of H.R.H. the Duke of, addresses of condolence on xxvi, 85, 116

ALBUMINURIA and convulsions during abortion in six successive pregnancies (W. H. Broadbent) . . . i, 108
„ by hydatidiform degeneration of the chorion associated with (W. B. Woodman) . . . . vii, 113, 117
„ see *Bright's disease*.

ALCOCK (RICHARD), cystic corpus luteum . . . xliii, 208

ALDERSON (F. H.), remarks in the discussion on the use of forceps xxi, 158

ALDRICH-BLAKE (L. B.), malignant disease of cervix in one-horned uterus . . . . . xlix, 269
„ skeleton of extra-uterine fœtus . . . . xlix, 269

ALLANTOIS, specimen preserved in formalin of an early gestation in both horns of the uterus of a bitch, displaying the allantoid vessels in their natural colour (Amand Routh) . . xli, 5

AMAUROSIS observed eight times in succession after parturition (H. E. Eastlake) . . . . . v, 79

AMENORRHŒA, decidual uterine cast expelled after eight weeks, together with an ovum of about five days' growth (W. E. Fothergill) . . . . . xliii, 162

AMMONIA, injection of, into the veins in puerperal fever (W. T. Smith) . . . . . xi, 247

AMNION, fœtus enclosed only in sac of (C. E. Purslow) . xli, 168

„ separate primary and complete expulsion of the unbroken, enclosing a fœtus of about four months' gestation (Graily Hewitt) . . . . . xxxiii, 461

„ retention of the cavity of, in the tube, in a tubal mole, showing escape of the body of the embryo through the fimbriated opening (J. S. Fairbairn) . . . . xliii, 211

AMPUTATION, congenital (J. Marshall) . . . x, 94

„ of the cervix uteri (A. Meadows) . . . . xi, 102

„ of forearm *in utero* (W. G. Hewitt) . . . xiii, 94

„ supra-vaginal, for cancer, cervix uteri removed by (A. H. N. Lewers) . . . . . xxxvii, 201

.. supra-vaginal, for cancer of the cervix, in which from four to fifteen years had elapsed without recurrence (A. H. N. Lewers) xliv, 221

AMUSSAT'S OPERATION, see *Colotomy*.

ANÆMIA and chlorosis, treatment of, with the phosphide of zinc (J. A. Thompson) . . . . . xvii, 57

„ complicated with pregnancy, iron salts in (W. B. Woodman) . xii, 33

ANÆSTHESIA, local, by the ether spray, employed in the removal of epithelioma of the cervix uteri by the écraseur (E. Parson) ix, 47

„ by mixed vapours (R. Ellis) . . . . viii, 224

„ in midwifery (T. Skinner) . . . . iv, 116

ANÆSTHETIC properties of the bichloride of carbon (A. E. Sansom) viii, 49

ANÆSTHETICS, apparatus for the self-administration of (J. M. Crombie) . . . . . xviii, 64

„ value of, in midwifery (C. Kidd) . . . . ii, 340

„ in midwifery (C. Kidd) . . . . . v, 125

„ in obstetric practice (A. E. Sansom) . . . x, 121

ANASARCA and large placenta in a fœtus (R. Boxall) . . xlii, 98

ANATOMY, normal and pathological, of the ganglion cervicale uteri (N. W. Jastreboff) . . . . xxiii, 266

„ pathological, of erosions of the cervix uteri (A. L. Galabin) . xxii, 156

„ — of five specimens of fibroid tumour of the ovary (J. S. Fairbairn) . . . . . xliv, 177

„ of mother and fœtus (H. Madge) . . . . viii, 348

„ of an infant presenting some rare deformities (C. Singer) . xlvii, 250

„ of the pelvic floor, contribution to the (G. E. Herman) . xxxi, 263

„ of the pregnant tube (H. R. Andrews) . . . xlv, 197

„ and nature of two acardiac acephalic fœtuses (A. Keith) . xlii, 99

ANDERSON (IZETT W.), notes on a Jamaica galactagogue . xxii, 31

ANDREWS (H. R.), imperforate rectum and congenital prolapse of the uterus . . . . . xlii, 169

„ sarcoma of the uterus, with a microscopic section . . xlii, 210

„ rudimentary supernumerary digits . . . xlii, 266

„ microscopical sections of the kidneys from a fatal case of puerperal eclampsia (with full notes of *post-mortem*) . xliii, 114

„ two cases of fœtal ascites and œdema . . . xliii, 166

ANDREWS (H. R.) *continued*—
„ primary melanotic sarcoma of ovary . . . xliii, 228
„ fibro-myoma of the ovary . . . . xliii, 231
„ congenital prolapse of the uterus associated with spina bifida xliv, 137
„ and G. Ernest Herman, contribution to the natural history of dysmenorrhœa . . . . . xliv, 371
„ primary carcinoma of the Fallopian tube . . . xlv, 54
„ anatomy of the pregnant tube . . . . xlv, 197
„ chorio-epithelioma . . . . . xlv, 238
„ sections showing muscular tissue in the pseudo-reflexa in tubal pregnancy . . . . . xlv, 333
„ bilateral extra-uterine pregnancy . . . xlv, 461
„ uterine fibroid removed from a patient aged 20 . . xlvii, 154
„ ruptured interstitial pregnancy . . . . xlvii, 259
„ fibroid showing cystic degeneration removed three weeks after labour . . . . . xlviii, 247
„ large cystic fibroid . . . . . xlviii, 249
„ supposed endothelioma of the cervix . . . xlviii, 283
„ complete prolapse of an inverted uterus . . . xlviii, 284
„ Cæsarean section followed by removal of a fibroid which filled the pelvic cavity . . . . . xlviii, 313
„ supposed sarcoma of the cervix . . . . xlix, 137
„ two cases of pregnancy in a rudimentary uterine horn . xlix, 209

ANDREWES (F. W.), sections from two different cases of endosteal sarcoma of the femur, showing syncytial structures . xlv, 237

ANENCEPHALIC DI-PROSOPIA FŒTUS, see *Monsters*.

ANENCEPHALOUS FŒTUS (Amand Routh) . . . xxxv, 241
„ (H. S. Ballance) . . . . . xxxv, 297
„ see *Monsters*.

ANEURYSM of the splenic artery, fœtal rupture of, immediately after labour (J. D. S. Nodes and Frank Hinds) . . xlii, 305
„ traumatic, of the uterine artery (W. G. Hewitt) . . ix, 246

ANGIOMA of labium (Matthews Duncan) . . . xxvi, 118
„ of the ovaries, atrophy with collapse (cirrhosis), fibroid degeneration and (J. Braithwaite) . . . xxxvi, 325

ANNING (G. P.), and HARRY LITTLEWOOD, primary ovarian pregnancy with rupture fourteen days after last menstruation xliii, 14

ANODYNE, extreme cold as, in the pain attendant on parturition (J. M. Granville) . . . . . vi, 105

ANTEFLEXION OF UTERUS, see *Uterus*, displacement of (anteflexion).

ANTISEPSIS and hygiene in fever in childbed (R. Boxall) xxxii, 219, 275

ANTISEPTIC IRRIGATION in childbed, instruments for (Graily Hewitt) . . . . . xxxi, 202

ANTISEPTICS in midwifery (A. L. Galabin) . . . xxxi, 92
„ the advantages of, in obstetric practice (Sir W. O. Priestley) . xxvii, 197
„ pellets of corrosive sublimate (F. H. Champneys) . . xxviii, 66

ANTISTREPTOCOCCIC SERUM in puerperal septicæmia (J. Walters and A. R. Walters) . . . . . xl, 277

ANUS, atresia ani vesicalis, fœtus the subject of (W. R. Dakin) . xxxii, 368
„ imperforate (A. E. Giles) . . . . xxxiv, 129
„ — etc., congenital absence of nose, right palpebral fissure, and right ear (W. Duncan) . . xxxvii, 16

ANUS (*continued*)—
„ orifice of, extrusion of right arm of child through, during labour (H. E. Eastlake) . . . . viii, 320
APOPLECTIC OVUM (G. E. Herman) . . . . xxii, 45
APOPLEXY of decidua (A. Routh) . . . . xxxii, 194
„ of the ovary, cystic dilatation without rupture (Alban Doran) xxxii, 119
„ double ovarian, from a case of acute peritonitis (H. A. Des Vœux) xxxiv, 214
„ of the ovum (C. J. Cullingworth) . . . xxxiv, 182
„ — in a case of unruptured tubal gestation (C. J. Cullingworth) xxxiv, 155
„ sudden seizure terminating fatally in thirty-five hours, on the sixth day of lying-in (R. U. West) . . . ii, 276
APOSTOLI'S METHOD in the treatment of fibroma and other morbid conditions of the uterus (J. Inglis Parsons) . xxxiv, 22
APPENDAGES, see *Uterine appendages, Uterus* (and appendages).
APNŒA, cardiac, after delivery (W. S. Playfair) . . x, 21
ARM, amputation of, in pregnancy (A. Napper) . . vii, 12
ARMS, dissection of (W. L. Heath) . . . . xxiii, 195
„ stumps of, and deformities of lower limbs in a hydrocephalic child (Matthews Duncan) . . . . xxii, 237
ARMS AND HANDS, deformity of (J. Shortt) . . . vi, 205
ARMSTRONG CASE, resolution of the Council on the action of a Fellow in the. . . . . xxviii, 1
ARMSTRONG (JAMES), see *Boulton, Percy.*
ARTERIES, calcification of, in large fibrotic uterus (J. S. Fairbairn) . . . . . xlvii, 299
„ pulmonary, sudden death from occlusion of, seventeen days after parturition (D. Mackinder) . . . i, 213
ARTERY, right hypogastric, absence of (A. E. Giles) . . xxxiv, 129
„ iliac, obstructed by a clot (R. Barnes) . . . xiii, 213
„ pulmonary, embolism of, after ovariotomy (E. Parson) . vii, 8
„ — fatal embolism of, nineteen days after delivery (G. Roper) xxi, 74
ASBURY (E. J.), rupture of the uterus occurring during labour . x, 40
ASCITES, with ovarian disease (G. C. P. Murray) . . v, 190
„ caused by papillomatous cyst of both ovaries (Alban Doran) . xxxiv, 149
„ see *Dropsy.*
ASEPTIC INSTRUMENTS (P. Horrocks) . . . xxxiv, 460
„ means of keeping sponges and instruments, in the vagina (J. Matthews Duncan) . . . . xxiv, 5
ASPHYXIA, causing sudden death in a case of ovarian tumour (R. F. Battye) . . . . . ii, 280
ASYMMETRY, normal, of the fœtal head (A. Wiltshire) . xx, 78
ATRESIA ani vesicalis, fœtus the subject of (W. R. Dakin) . xxxii, 368
„ of the cervix uteri, distension of uterus, and escape of menses between the walls of the vagina (G. Lowe) . . xxix, 401
„ of the female urethra (G. E. Herman) . . . xxviii, 267
„ vaginæ, instruments for (N. Bozeman) . . . xix, 96
„ — case of labour with (Fancourt Barnes) . . . xxv, 99
„ — causing retention of menses of two years' duration (I. B. Brown) . . . . . v, 162
„ — retained menses of two years' duration caused by (I. B. Brown) iv, 21
„ of the vaginal orifice of the neck of the uterus, new operation for (V. de Saboia) . . . . xvi, 116

ATROPHY of chorion (G. E. Herman) . . . xxvii, 195
„ of embryo (G. E. Herman) . . . xxiii, 204, 259
„ of uterus with fibroid (F. H. Champneys) . . . xxii, 185
„ with collapse (cirrhosis), fibroid degeneration, and angioma of the ovaries (J. Braithwaite) . . . . xxxvi, 325

ATTILL (LOMBE), remarks in the discussion on the use of forceps . . . . . xxi, 178

AURICLE, cervical (A. Doran) . . . . xxxiii, 200

AUSCULTATION as a means of diagnosis of pregnancy (E. Copeman) . . . . . x, 62

AUTOPSY and remarks on puerperal eclampsia (R. H. Bell) . xliv, 253

AUVARD'S COUVEUSE or nest (J. Matthews Duncan) . . xxvi, 25

AUVARD'S NIPPLE SHIELD (Clement Godson) . . xxx, 198

AVELING (J. H.), historical notes on displacement of the unimpregnated uterus as a cause of displacement of the gravid organ . . . . . iii, 288
„ polyptrite, a new instrument for crushing the necks of uterine polypi . . . . . iv, 135
„ vaginal lithotomy . . . . . v, 1
„ immediate transfusion . . . . . vi, 126
„ new hysterotome and intra-uterine spring tent . . vii, 155
„ ovariotomy in which the pedicle was tied and returned, and the ligature removed in forty-eight hours . . vii, 229
„ the relative value of the various substances which have been used in dilating the neck of the womb, with a plan for deodorising sponge tents . . . . ix, 264
„ forceps, handles curved backwards . . . x, 40
„ new principle of treatment in prolapsus and procidentia uteri xi, 215
„ gynæcometer . . . . . xiii, 265
„ apparatus for immediate transfusion . . . xiv, 101
„ *post-mortem* parturition, with references to forty-four cases . xiv, 240
„ best mode of opening the vein in transfusion . . xv, 164
„ loop saw . . . . . xv, 221
„ symmetrically hypertrophied clitoris . . . xvi, 1
„ *report* on Alfred Meadows' specimen of membrane passed in a case of membranous dysmenorrhœa . . . xvi, 251
„ presentation of a pair of forceps by . . . xviii, 2
„ rectal protruder, for pressing upon the posterior wall of the vagina to protrude the rectum through the anus for examination . . . . . xviii, 83
„ curved needle made to revolve, for cases of vesico-vaginal fistula . . . . . xix, 66
„ a repositor for inversion of the uterus . . . xx, 126
„ the curves of the midwifery forceps, their origin and uses . xx, 130
„ regulator to be used with Paquelin's cautery . . xx, 293
„ Swan's incandescent carbon lamp . . . xxiv, 304
„ cast of female bladder . . . . . xxv, 33
„ a dilator . . . . . xxvi, 149
„ soft myoma of the uterus showing early cystic degeneration, removed by hysterotomy . . . . xxvi, 270
„ see *Meadows* (*A.*).

AVULSION of the uterus, post-partum (J. H. Walters) xxiv, 136; xxvi, 233

AXIAL ROTATION, see *Rotation*, axial.

AXIS TRACTION FORCEPS used for delivery of a child in a case of persistent mento-posterior position of the face (A. H. N. Lewers) . . . . . xli, 280

AYMARD (J. L. A.), axis pressure-binder for use during labour . xxxii, 173

BABY, new-born, diaphragmatic hernia in (C. N. Longridge) . xlix, 272

Bacillus coli communis found in a case of membranous vaginitis (T. G. Stevens) . . . . . xli, 228

„ *typhosus*, suppuration in an ovarian cyst caused by (F. E. Taylor) . . . . . xlix, 256

BACK, chronic pain in (H. Gervis) . . . . . v, 76

BAILEY (H. W.), statistics of midwifery in the practice of, with tables . . . . . i, 299

„ transposition of the greater part of the abdominal viscera into the left cavity of the thorax . . . . . x, 6

BAKER (BENSON), influence of lead-poisoning in producing abortion and menorrhagia . . . . . viii, 41

BALL (ANCELL), treatment of moles and premature expulsion of the fœtus . . . . . i, 315

BALLANCE (H. STANLEY), case of anencephalic fœtus . . xxxv, 297

BALLARD (THOMAS), supposed invagination of the intestine in a child, aged 20 months, successfully treated . . i, 137

„ ovary after attempt at abortion . . . . xii, 3

„ — *report* on, by Drs. Hicks and Madge . . . xii, 135

BALLS, epithelial, dermoid cyst containing a large number of (W. F. V. Bonney) . . . . . xliv, 354

BANDAGE after labour (A. Meadows) . . . vi, 125

BANNISTER (A. J.), see *Meadows, A.*

BANTOCK (G. G.), Neugebauer's vaginal speculum . . xiii, 51

„ pedicle of ovarian tumour, showing changes caused by ligature xiv, 2

„ treatment of certain forms of menorrhagia and uterine hæmorrhage by means of the sponge tent, with special reference to their occurrence in women residing in tropical climates . . . . . xiv, 84

„ pathology of certain so-called unilocular ovarian cysts . xv, 105

„ two-headed monster with the bodies united from the breast downwards . . . . . xviii, 223

„ uterine polypus of large size . . . . xxii, 105

„ specimens of fibroid tumour of the uterus . . . xxiv, 47

„ fibroid tumour removed by abdominal section, two specimens of xxiv, 91

„ fibroid tumours of the uterus removed by abdominal section, five cases of . . . . . xxiv, 301

„ dermoid cyst of the right ovary . . . . xxv, 38

„ hydrosalpinx . . . . . xxv, 38

„ fibroid tumours of the uterus removed by hysterectomy . xxv, 38

„ fibroid tumours of the uterus . . . . xxvi, 119

„ surgical needles and holder (Hagedorn's) . . . xxvi, 271

BARBER (OLIVER), specimen of an anencephalic fœtus . . xvii, 341

BARBOUR (A. H. FREELAND), uteri at the onset of labour and after delivery . . . . . xxviii, 73

BARKER (FORDYCE), remarks in the discussion on puerperal fever xvii, 222

BARKER (T. H.), annular laceration of cervix uteri . . ii, 329

BARNES (FANCOURT), the indications afforded by the sphygmograph in the puerperal state . . . . . xvi, 255
„ model phantom for obstetric classes, designed by Budin and Pinard . . . . . xix, 229
„ for *Robert Barnes*, vulcanite tubes to facilitate the injection of perchloride of iron or iodine into the uterus . . xx, 60
„ for *C. Duncan*, instrument to measure the amount of flexion of the uterus . . . . . xxiii, 177
„ spurious hermaphroditism . . . . . xxiv, 188
„ case of labour with atresia vaginæ . . . . xxv, 99
„ hypertrophied left nympha . . . . . xxv, 165
„ new cephalotribe . . . . . xxvi, 27
BARNES (R.), some recent cases (fourteen) illustrating physiology and treatment of placenta prævia . . . . i, 83
„ risk to life of first and subsequent pregnancies . . i, 311
„ asymmetrical distortion of the pelvis, the result of unequal length of legs . . . . . ii, 314
„ indications and operations for the induction of premature labour and for the acceleration of labour . . . iii, 107
„ fibroid tumour springing from the posterior lip of the uterus, causing complete prolapse and simulating inversion of the uterus; removal by ligature; recovery . . . iii, 211
„ peritonitis caused by escape of pus or putrilage from the Fallopian tube into the abdominal cavity, following on abortion artificially produced . . . . iii, 419
„ thrombosis and embolism of lying-in women . . iv, 30
„ broncho-pneumonia of lying-in women . . . iv, 55
„ description of a specimen of ovum in ovo . . . iv, 87
„ fibroid tumour situated in the anterior wall of the uterus and which obstructed labour . . . . v, 171
„ association of spina bifida with hydrocephalus . . v, 172
„ face presentation . . . . . v, 173
„ craniotomy forceps . . . . . v, 277
„ spondylolisthesis, with account of a case of pelvic contraction, from this affection, in which premature labour was induced by the author's method . . . vi, 78
„ — appendix to above memoir . . . . vi, 98
„ small fibroid tumour . . . . . vi, 101
„ piliferous cyst of ovary . . . . . vi, 249
„ address, as President . . . vii, 37; viii, 25; ix, 18
„ fibroid tumour removed by enucleation and excision . vii, 55
„ instrument for dividing cervix uteri . . . vii, 72
„ large fibroid tumours expelled spontaneously . . vii, 113
„ third case of hydatidiform degeneration of the chorion, associated with albuminuria . . . . vii, 117
„ dysmenorrhœa, metrorrhagia, ovaritis, and sterility, depending upon a peculiar formation of the cervix uteri, and treatment by dilatation or division . . . . vii, 120
„ — appendix to above, in illustration of the behaviour of the conical cervix with minute os under labour . . vii, 150
„ varieties of form imparted to the fœtal head by the various modes of birth . . . . . vii, 171
„ laminaria tent introducer . . . . vii, 207
„ uterus after death from a simple tapping . . . vii, 207
„ voluminous fibroid tumour from uterus . . . vii, 228
„ presidential address . . . . . viii, 25
„ sudden death during labour . . . . viii, 40

BARNES (R.) (*continued*)—
„ plan for cauterising cervix uteri . . . . viii, 102
„ mummified fœtus expelled after birth of full-term child . viii, 108
„ abscess in placenta . . . . . viii, 149
„ address as President . . . . . ix, 18
„ history of pregnancy complicated with smallpox . . ix, 102
„ uterus of patient after puerperal fever . . . ix, 241
„ uterus and vessels concerned in phlegmasia dolens . . x, 113
„ chorea in pregnancy . . . . . x, 147
„ new method of embryotomy . . . . xi, 126
„ head of child with Hicks's cephalotribe attached . . xi, 191
„ hæmorrhage after labour . . . . xi, 219
„ improved anti-hæmorrhagic case . . . . xii, 271
„ suture for closing the uterine wound in Cæsarean section and for uniting uterine wound to the abdominal wall . . xii, 364
„ modification of Lallemand's porte-caustique and speculum for introducing medicated wool into vagina . . . xiii, 96
„ Mr. De Berdt Hovell's uterine truss for post-partum hæmorrhage . . . . . xiii, 129
„ note on the bursting of intra-peritoneal hæmatocele into the peritoneal cavity . . . . . xiii, 191
„ Boddaert, of Brussels, lever . . . . . xiii, 213
„ iliac artery obstructed by a clot, described by Dr. Williams, of Truro . . . . . xiii, 213
„ abstract of a memoir on osteo-malacia by Dr. Gaetano Casati, of Milan . . . . . xiii, 244
„ the essential cause of dysmenorrhœa as illustrated by cases of partial and complete retention . . . . xiv, 108
„ fibrous tumour from anterior wall of vagina . . xiv, 309
„ modification of Neugebauer's speculum . . . xiv, 309
„ note on the mode of dealing with the placenta where gastrotomy is performed in order to remove the fœtus in extra-uterine gestation . . . . . xiv, 325
„ dermoid cyst . . . . . xv, 35
„ procidentia uteri and inversion of vagina, with hypertrophic elongation of cervix . . . . . xv, 124
„ for *W. H. Kesteven*, upper portion of the trunk and head of a fœtus where the arm, face, and foot had presented . xvi, 100
„ — *report* on ditto . . . . . xvi, 127
„ remarks in the discussion on puerperal fever . xvii, 136, 195
„ dermoid cyst containing hair and several well-developed teeth, and a firm, jaw-shaped palate of osseous substance . xvii, 215
„ uterus from a patient, aged 45, married, subject to eczema for three years . . . . . xvii, 216
„ large conglomerate of colloid tumours grown from the omentum, removed by gastrotomy . . . . xvii, 216
„ further history of ditto . . . . . xviii, 193
„ case of labour with extreme elongation of the cervix uteri . xviii, 293
„ *report* as delegate to the Philadelphia Medical Congress . xix, 2
„ for *Dr. Bernard*, apparatus for facilitating uterine injections after labour . . . . . xix, 118
„ for *Dr. Scott*, pessary for prolapsus uteri . . . xix, 119
„ flexible galvanic stem . . . . . xix, 136
„ for *Joseph R. Beck*, uterine applicator (Beck's) . . xix, 136
„ cancer of the body of the uterus . . . . xx, 28
„ two specimens illustrating two forms or causes of intra-pelvic blood effusions . . . . . xx, 101

Barnes (R.) *continued*—
„ tumour which had been protruded from the rectum during labour . . . . . xxi, 28
„ Marshall's new midwifery forceps, each blade rotating on its axis by means of a pivot joint . . . . . xxi, 90
„ on the use of forceps and its alternatives in lingering labour . xxi, 121
„ remarks in reply . . . . . xxi, 238
„ on the so-called "missed labour," with a case in illustration xxiii, 81, 110
„ note on the so-called "lithopædion," being a supplement to the author's paper on so-called "missed labour" . . xxiii, 170
„ fibro-myoma and a new axis traction vulsellum forceps . xxv, 68
„ hæmorrhagic effusion into an ovarian cyst due to twisting of the pedicle . . . . . xxv, 160
„ on the mechanism of labour, more especially with reference to Naegele's obliquity and the influence of the lumbo-sacral curve . . . . . xxv, 258
„ ovarian tumour with twisted pedicle . . . xxvi, 59
„ cystic disease of ovary in its earliest stage . . xxvi, 157
„ glass injection tube and catheter . . . xxvi, 232
„ *report* on F. L. Neugebauer's specimens illustrating spondylolisthesis . . . . . xxvi, 186
„ see *Barnes, Fancourt.*
„ see *Edis, A. W.*

Bartlett (Hedley C.), lithopædion of fourteen years' duration successfully removed . . . . . xlvi, 200

Barton (E. A.), fœtus compressus . . . . xlv, 417

Barton (Henry T.), fœtus discharged in the membranes entire at six months and three weeks . . . . xxix, 189

Barton (J. Kingston), see *Godson, Clement.*

Bassett (John), cases in practice; accidental hæmorrhage, placenta prævia, rupture of a varix and destruction of the uterus . . . . . xiv, 58
„ on the propriety of administering iron during pregnancy as a preventive of post-partum hæmorrhage . . . xvi, 111
„ case of general dropsy in a fœtus with hypertrophy of the placenta . . . . . xix, 261
„ remarks in the discussion on the use of forceps . . xxi, 192
„ see *Galabin.*

Batchelor (F. C.), see *Alban Doran.*

Battey (R.), treatment of vesico-vaginal fistula by a new method . . . . . i, 275

Battye (R. F.), ovarian tumour, weighing 76½ oz., in a girl, aged 12½, terminating life suddenly by asphyxia . . ii, 280
„ short examination of certain uterine affections, especially those accompanied with leucorrhœal discharge, in their relations to phthisis pulmonalis . . . viii, 237

Baudelocque cephalotribe presented to the Society by Sir Charles Locock . . . . . vii, 208

Beach (F.), uterus and ovaries of child who died of tubercular meningitis . . . . . xv, 57

Beale (Arthur A.), see *Alban Doran.*

Beale (George B.), see *Doran.*

Beck (Joseph R.), see *Barnes, Robert.*

BECK (SNOW), remarks in the discussion on puerperal fever . xvii, 240
„ uterus in a case of puerperal fever . . . vi, 186
„ puerperal fever . . . . . vii, 31
„ enlargements of the uterus which follow abortions, premature or natural confinements; with cases . . . viii, 54
„ puerperal fever, or puerperal pyæmia after an abortion; with remarks . . . . . ix, 275
„ uterus and appendages of pregnant woman who died from convulsions during typhus fever . . . xiii, 239
„ structure of the uterus and the changes the tissues undergo during pregnancy and after parturition . . . xiii, 290
„ pelvic hæmatoma or retro-uterine hæmatocele; with remarks especially as to the source of the hæmorrhage . . xiv, 260
BECK'S UTERINE APPLICATOR (R. Barnes) . . . xix, 136
BED for cases of puerperal hyperpyrexia requiring continuous application of cold (W. S. Playfair) . . . xx, 171
BED-PAN, earthenware, to allow of free ablution (W. Squire) . xv, 163
BEDSORE, acute, following parturition (G. F. Blacker) . . xl, 247
BELL (J. H.), ruptured vagina during labour; child in abdomen three and a half hours; pelvic cellulitis; recovery . iv, 197
BELL (R. H.), puerperal eclampsia, with autopsy and remarks . xliv, 253
„ "paratubal" hæmatocele . . . . xliv, 322
„ cyst in connection with the right Fallopian tube, arising probably from an accessory Fallopian tube . . . xlvi, 21
„ torsion of the pedicle in hydrosalpinx, and other morbid conditions of the Fallopian tube . . . . xlvi, 152
„ on the appearance of thyroid-like structures in ovarian cysts . xlvii, 242
„ further history of a case of degenerating fibro-myoma and sarcoma of uterus . . . . . xlviii, 199
„ see *J. D. Malcolm.*
BELLADONNA, action of, upon the mammary glands (R. Marley) ii, 29
BELT, Bailey's patent abdominal (Heywood Smith) . . xix, 41
„ for use after ovariotomy (Heywood Smith) . . xxii, 45
BENNET (HENRY), remarks in the discussion on the use of forceps xxi, 193
„ on the os uteri internum, its anatomy, physiology and pathology . . . . . xxv, 219
BERKELEY (COMYNS), rupture of an ovarian abscess twelve hours after labour . . . . . xliv, 73
„ spontaneous expulsion . . . . . xliv, 320
„ parovarian cyst with twisted pedicle . . . xlvi, 242
BERLIN, Obstetrical and Gynæcological Society, letter from . xxxix, 85
„ — reply . . . . . xxxix, 125
BERNARD (Dr.), see *Barnes, Robert.*
BERRY (SAMUEL), two cases of obstructed labour, with remarks . vii, 261
BIBBY (S. H.), cast of antique group representing the circumstantials of labour in very early times . . . xvi, 243
BINDER, axis pressure, for use during labour (J. L. A. Aymard) xxxii, 173
„ obstetric (H. E. Eastlake) . . . . vi, 205
„ the effect of, upon the change in size of the chest and abdomen during the lying-in period (G. E. Herman) . . xxxii, 108
BITCH, specimen preserved in formalin of an early gestation in both horns of the uterus of (Amand Routh) . . xli, 5

Black (J. Watt), puerperal fever and septic poisoning . xxxiii, 76
„ annual address as President . xxxiii, 76; xxxiv, 33; xxxv, 47

Blacker (G. F.), uterus with placenta prævia marginalis *in situ* xxxvi, 194
„ ruptured uterus . . . . . xxxvi, 316
„ uterus with fibroid tumours and carcinoma of the cervix removed *post mortem* from a patient on whom eight years previously the operation of oöphorectomy had been performed . . . . . xxxvii, 213
„ and T. W. P. Lawrence, a case of true unilateral hermaphroditism with ovotestis occurring in man, with a summary and criticism of the recorded cases of true hermaphroditism xxxviii, 265
„ treatment of placenta prævia by Champetier de Ribes' bag . xxxix, 138
„ case of acute bedsore following parturition . . xl, 247
„ fibro-adenoma removed from the cervix . . . xli, 374
„ spinal column exhibiting want of ossification in the interarticular portion of the lumbar vertebræ . . . xlii, 90
„ frozen sections of a uterus at the tenth week of pregnancy, showing hæmorrhages into the placenta, decidua reflexa, and decidua vera, from a patient who died of heart disease . xlii, 235
„ uterus removed by vaginal hysterectomy fourteen days after the operation of curetting and steaming had been performed xlv, 80
„ chorion-epithelioma of the uterus, with secondary growths in the vagina, the lungs, and the liver . . . xlvi, 55
„ a case of uterus unicornis and right appendages removed from an epileptic subject . . . . xlviii, 82
„ a specimen of tubo-abdominal gestation at the fourth month of pregnancy removed by abdominal section . . xlviii, 137
„ suppurating fibroid tumour of the uterus . . . xlix, 100
„ chorion-epithelioma of the uterus; lutein cysts in both ovaries xlix, 104

BLADDER, cast of membrane from female (J. H. Aveling) . xxv, 33
„ cedar pencil, extracted from (J. J. Phillips) . . xiv, 37
„ dilatation and hypertrophy of, in a fœtus (F. A. T. O'Meara) . xxix, 54
„ displacement of, as a cause of tedious labour (W. H. Broadbent) . . . . . v, 44
„ distension of, and ascites in a fœtus, necessitating embryotomy (A. L. Galabin) . . . . . xix, 119
„ — considered as a cause of post-partum hæmorrhage (J. L. Earle) . . . . . v, 291
„ — displacement of the uterus by (J. B. Hicks and J. F. Goodhart) . . . . . xviii, 194
„ enlarged, in a case of double pyosalpinx with secondary renal complication (H. Macnaughton Jones) . . . xxxix, 319
„ exfoliation of mucous membrane of (Alban Doran) . . xxiii, 2
„ extraction of a hairpin from that of a female (P. Smith) . x, 59
„ extroversion of (D. L. Roberts) . . . . xii, 361
„ — and other malformations (H. C. Rose) . . . xv, 125
„ — (F. H. Champneys) . . . . . xxiv, 240
„ female, cast of (T. Spencer Wells) . . . iii, 417
„ — exfoliation of (G. Harley) . . . . iv, 13
„ — showing the results of retention of urine after delivery (T. Spencer Wells) . . . . . iii, 354
„ gangrene of base of (G. E. Herman) . . . xxix, 244
„ — from retroversion of the gravid uterus (Ad. Rasch) . xxxi, 129
„ hair-pin from, of young girl (T. C. Hayes) . . . xxxv, 185
„ intra-peritoneal rupture of, occurring during labour (C. R. Porter) . . . . . xlix, 170

BLADDER (*continued*)—
„ irritable, in the latter months of pregnancy (W. S. Playfair) . xiii, 42
„ malformation of (A. E. Giles) . . . . xxxiv, 129
„ perforation of wall of, by large foreign body in the vagina (C. H. Carter) . . . . . xxii, 38
„ sloughing and separation of the mucous lining of, after delivery by forceps in a face presentation (W. Martyn) . . v, 186
„ tumour closely simulating a papillomatous ovarian cystoma attached to the front of (J. D. Malcolm) . . . xli, 226
„ and ureters, dilatation of, from pressure, in an infant (W. McAdam Eccles) . . . . . xxxiv, 250
„ and urethra, female, two cases of repair of (Lawson Tait) . xx, 88

Blake (C. Paget), protracted gestation . . . xxxiv, 28

Blake (J.), modification of Hodges' pessary . . . xiv, 137

Bland-Sutton (J.), ovarian dermoid . . . xxxiv, 5
„ — infiltration of broad ligament with fat . . xxxiv, 7
„ hydrosalpinx undergoing spontaneous cure . . xxxiv, 9
„ ovarian hydrocele containing papillomata . . xxxiv, 215
„ tubal pregnancy, rupture into broad ligament . xxxiv, 217
„ on a case of tubo-uterine pregnancy; primary intra-peritoneal rupture; recovery . . . . xxxvii, 296
„ myomata of the neck of the uterus . . . xxxix, 160
„ abdominal hysterectomy for myoma of the uterus; with brief notes of twenty-eight cases . . . . xxxix, 292
„ on a case of tubo-abdominal pregnancy in which a living fœtus was extracted by cœliotomy after term, and the mother's life preserved . . . . . xl, 308
„ on some cases of tubal pregnancy . . . xl, 313
„ ovary containing a calcareous ball, probably a large calcified corpus fibrosum . . . . . xl, 223
„ acardiac from a cow . . . . . xli, 97
„ unusual example of rupture of an ovarian adenoma . . xli, 98
„ rotation and impaction of a myomatous uterus . . xli, 296
„ tumour of the mesometrium weighing 22 lb. . . xli, 298
„ myomatous uterus weighing 26 lb. successfully removed from a woman aged 74. . . . . xli, 300
„ tubal abortion in which the "mole" was in process of extrusion at the time of operation . . . . xlii, 311
„ gonorrhœal pelvic peritonitis . . . . xliii, 251
„ tubal pregnancy diagnosed before rupture, and a case of tubal abortion . . . . . xliv, 44
„ primary cancer of the Fallopian tube . . . xliv, 311
„ two cases of extra-uterine gestation which went to term . xliv, 316
„ — illustrating changes in fibroids after the menopause . xlv, 105
„ ovarian dermoid with a twisted pedicle six inches in length . xlvi, 147
„ acute axial rotation of a calcified fibroid of the uterus . xlvi, 149
„ pregnancy in a uterus with fibroids: panhysterectomy during labour in the seventh month . . . . xlvi, 238
„ tuberculosis (probably primary) of the body of the uterus in an adult . . . . . xlvii, 72
„ fibroids of the uterus complicated by cancer of the corporeal endometrium . . . . . xlviii, 140
„ a villous tumour of the body of the uterus in a woman, aged 84; vaginal hysterectomy . . . . xlix, 46
„ uterus four years after Cæsarean section . . . xlix, 174
„ see also *Sutton (J. Bland)*.

BLEEDING after the menopause, two specimens of fibroid associated with (A. H. N. Lewers) . . . . xlix, 270

BLOOD, circulation of the, in the uterus, with some of its anatomical and pathological bearings (John Williams) . xxvii, 112
„ concretions in the ovary (Alban Doran) . . . xl, 214
„ intra-pelvic effusions of, two specimens illustrating two forms or causes of (R. Barnes) . . . . xx, 101
„ mixture of various fluids with, in transfusion (E. A. Schäfer) xxi, 316
„ right ovary and tube distended with (Wm. Duncan) . xxxii, 306
„ see *Transfusion* of blood.

BLOOD-SWELLING, cranial, with remarks on the nature of these tumours (E. Rigby) . . . . . i, 231

Bluett (G. M.), case of congenital hydrocephalus complicating labour . . . . . xxix, 396
„ insertio velamentosa . . . . . xxix, 511
„ and G. E. Herman, microscopical sections of tumours of fœtal membranes . . . . . xxix, 243
„ *report* on ditto by committee (A. L. Galabin, G. E. Herman, and Alban Doran) . . . . . xxix, 512
„ see *Herman (G. E.)*.

BLUNT-HOOK, considerably modified (T. Lazareivitch) . . xviii, 190
„ and sling, new form of, for assisting delivery in cases of breech presentation (J. G. Swayne) . . . . xvii, 313

BODKIN nucleus of a phosphatic calculus (Amand Routh) . xxxv, 240

BONE, occipital, report of a specimen showing origin of gluteus maximus from (L. Remfry) . . . . xxxvi, 227

BONES from an extra-uterine fœtation which had undergone spontaneous cure (Sir W. O. Priestley) . . . xxi, 24
„ macerated, of a fœtus from an extra-uterine gestation retained seven years (J. D. Malcolm) . . . . xli, 223

BONNET MONKEY, sections from the uterus of (A. W. Addinsell) xli, 141

Bonney (William Francis Victor), uterus bicornis unicollis . xliii, 77
„ solid tumour of the left ovary with an attached cyst communicating with the left Fallopian tube . . . xliv, 92
„ probable case of superfœtation . . . . xliv, 163
„ uterus and vagina with the child *in situ* in the second stage of labour . . . . . xliv, 292
„ dermoid cyst containing a large number of epithelial balls . xliv, 354
„ and A. G. R. Foulerton, primary infection of the puerperal uterus by *Diplococcus pneumoniæ* . . . xlv, 128
„ uterine myoma undergoing red degeneration . . xlv, 464
„ abscess in the uterus . . . . . xlvi, 2
„ and A. G. R. Foulerton, an investigation into the causation of puerperal infections . . . . xlvii, 11
„ ruptured ovarian cyst with twisted pedicle . . xlvii, 190
„ uterus removed for (?) malignant overgrowth of the endometrium . . . . . xlvii, 191
„ treatment of ovarian prolapse by shortening the ovarian ligament . . . . . xlviii, 339

BONY GIRDLE from a dermoid tumour (S. W. Wheaton) . xxxv, 4

BOSSI'S DILATOR (M. Handfield-Jones) . . . xlv, 103

Bottomley (F. C.), deformed fœtus . . . . xxxix, 134
„ fœtus compressus s. papyraceus . . . . xxxix, 134

BOULTON (P.), paraplegia occurring during pregnancy . . ix, 12
„ extra-uterine fœtation . . . . . xxi, 117
„ case of imperforate vagina . . . . xxiii, 125
„ case of conjoined twins . . . . . xxiii, 260
„ for *James Armstrong*, the alpha constant current syringe . xxx, 198
„ calculi from a case of prolapse of the uterus and bladder . xxxii, 367
„ the purse-string suture, its use in complete rupture of the perineum . . . . . xxxii, 380
BOUSQUET (F.), note on a case of absence of the uterus and occlusion of the vagina . . . . xxvii, 123
BOXALL (ROBERT), adherent placenta . . . xxvi, 58
„ cyst of placenta . . . . . xxvi, 59
„ incomplete pericardial sac, escape of heart into left pleural cavity . . . . . xxviii, 209
„ scarlatina during pregnancy and in the puerperal state xxx, 11, 126, 167
„ the conditions which favour mercurialism in lying-in women, with suggestions for its prevention . . . xxx, 304
„ pelvic hæmatoma following delivery, death four hours after labour . . . . . xxxi, 303
„ fever in childbed.—Part I.—General hygiene and antisepsis xxxii, 219, 275
„ early placenta with localised hydatidiform degeneration . xxxiii, 494
„ ruptured uterus . . . . . xxxiv, 11
„ placenta prævia associated with unusual size and shape of the placenta . . . . . xxxiv, 464
„ fever in childbed.—Part II.—The relation of external meteorological conditions to the incidence of febrile illness in childbed . . . . . xxxv, 340
„ rapidly growing soft fibro-myoma in left broad ligament . xxxv, 410
„ uterine fibroids removed by enucleation fifteen days after delivery . . . . . xxxvi, 64
„ incarcerated ovarian dermoid; Cæsarean section, and removal of tumour at the end of the first stage of labour . . xl, 25
„ uterus with interstitial fibroid from a case of placenta prævia centralis . . . . . xl, 338
„ dermoid tumours of both ovaries; twisted pedicle . . xli, 5
„ fœtus with anasarca and large placenta . . . xlii, 98
„ cystic fibroid with carcinoma of left ovary and right Fallopian tube . . . . . xliii, 71
„ acute inversion of the uterus; spontaneous reposition . xlvi, 292
„ mortality in childbed both in hospital and in general practice xlvii, 196
„ extra-uterine gestation sac ruptured in the fifth month of pregnancy . . . . . xlvii, 297
„ after-history of "a case of cystic fibroid with carcinoma of left ovary and right Fallopian tube" (brought before the Society five years ago) . . . . xlviii, 136
BOYD (FLORENCE NIGHTINGALE), fibroma of ovary . . xliv, 176
„ two cases of abdominal hysterectomy for fibroids, complicated by pregnancy; with specimens . . . . xlvi, 106
„ necrobiotic fibroid . . . . . xlvi, 198
„ pregnant uterus with cancerous cervix removed by panhysterectomy . . . . . xlvi, 345
„ fibroid of broad ligament . . . . xlvi, 348
„ malignant growth of cervix in a girl aged 18 . . xlvii, 313
„ pregnancy in the right cornu of a fibroid uterus . . xlix, 49
„ adeno-carcinoma of the ovary . . . xlix, 50
BOYD (SIDNEY), unusual case of inversion of the uterus . xlv, 170

Boyd (Stanley), suppurating fibroid tumour of the uterus . xliii, 172
Bozeman (N.), instruments for the operations of atresia vaginæ and vesico-vaginal fistula . . . . xix, 96
BRAIN from a case of puerperal septicæmia (Wm. Duncan) . xxxi, 202
„ showing thromboses in the cerebral veins and hæmorrhage into the internal capsule in a case of ingravescent hemiplegia during pregnancy and parturition (P. Horrocks) . . xxxiii, 201
Braithwaite (James), on a new mode of treating certain cases of retroflexion of unimpregnated uterus . . . xix, 122
„ on digital dilatation of the os in labour . . . xxi, 38
„ non-capsulated fibroids resembling retained placenta . xxiii, 182
„ case of gastrotomy for extra-uterine gestation in which the placenta never came away . . . . xxviii, 33
„ adenoma of the portio vaginalis uteri, forming a depressed sore or ulcer . . . . . xxxvi, 208
„ on atrophy with collapse (cirrhosis), fibroid degeneration, and angioma of the ovaries . . . . xxxvi, 325
BRANDY, substitute for, in cases of exhaustion (R. Druitt) . iii, 143
Braun (Carl), blunt-pointed hook, crooked trephine and cranioclast . . . . . xv, 58
BREASTS, abscesses of, prevention of, by the application of the principle of rest (W. B. Woodman) . . . xvii, 9
„ absence of uterus and (L. Remfry) . xxxvii, 12
„ dark crescentic pigmentation round both nipples (Clement Godson) . . . . . xvii, 343
„ eczema of the nipple in both (Thos. Chambers) . xxii, 266
„ glands of, action of belladonna upon the (R. Marley) . ii, 29
„ hypertrophy of (J. A. M. Moullin) . . . xxv, 212
„ inflammation of, and milk abscess (T. W. Nunn) . . iii, 197
„ lymphangitis mammæ—an affection arising about the tenth day of the puerperium with well-marked clinical features (R. H. Vincent) . . . . . xliv, 158
„ supporter, linen (W. Squire) . . . . xv, 163
BREECH PRESENTATION, see *Parturition*.
BREISKY'S KYPHOTIC PELVIS, remarks on (F. H. Champneys) . xxiv, 242
BREPHOTOME, forceps, and blunt hook . . xxxvii, 243
Brewer (A. H.), labour complicated with an ovarian cyst . xx, 184
Briggs (H.), chorion-epithelioma . . . . xlv, 239
„ primary cancer of the right Fallopian tube; right ovary normal . . . . . xlvi, 60
„ ovarian pregnancy . . . . . xlix, 222
„ early tubal mole . . . . . xlix, 223
„ fibroid tissue formed around a needle and removed from the left labium majus . . . . . xlix, 223
BRIGHT'S DISEASE during pregnancy (G. E. Herman) xxix, 539; xxx, 478; xxxii, 320, 349
„ six more cases of pregnancy and labour with (G. E. Herman) . xxxvi, 9
Broadbent (W. H.), abortion, with albuminuria and convulsions, six successive pregnancies (under Dr. Tyler Smith) . i, 108
„ displacement of the bladder as a cause of tedious labour . v, 44
BROAD LIGAMENTS, accessory adrenal bodies in (J. H. Targett) . xxxix, 157
„ ligature and division of the upper part of both, and the result as compared with that following removal of the uterine appendages (L. Remfry) . . . . xxxvi, 202

BROAD LIGAMENTS (*continued*)—
„ mesosigmoid, and mesocæcum, ovarian cyst which had made its way between the layers of both (W. H. B. Brook) . xlv, 415
BROAD LIGAMENT, cancerous pelvic tumour, commencing in the outer cellular tissue of the (T. C. Hayes) . . xvi, 102, 127
„ carcinomatous tumour originating in the (T. C. Hayes) . xvi, 101
„ cyst of (J. Knowsley Thornton) . . . . xxvi, 55
„ — (E. Malins) . . . . . xxvi, 228
„ — with septa (W. S. A. Griffith) . . . . xxvii, 251
„ — (W. Duncan) . . . . . xxxiii, 157
„ — (C. E. Purslow) . . . . . xli, 169
„ cyst, with torsion of the pedicle and extensive hæmorrhage into the broad ligament (F. J. McCann) . . . xlviii, 179
„ fibroid of (F. N. Boyd) . . . . . xlvi, 348
„ — weighing 44½ lb. (20 kils.), removed by enucleation; recovery (Alban Doran) . . . . xli, 173
„ — associated with an ovarian cyst (A. Doran) . . xliii, 260
„ after-history of, fibroid of, associated with an ovarian cyst, reported in the forty-third volume of the Society's 'Transactions' (A. Doran) . . . . xlix, 94
„ fibroid of, weighing 4½ lb., with twisted pedicle (A. H. N. Lewers) . . . . . xliv, 364
„ fibroma of, weighing 44 lb. 8 oz., successfully removed from a woman aged 28 (A. Doran) . . . . xl, 295
„ fibro-myoma of (W. A. Meredith) . . . xxix, 249, 514
„ — (M. Handfield-Jones) . . . . xxxv, 239
„ — large soft, weighing 14 lb. (E. Maclean) . . xl, 134
„ œdematous subperitoneal fibro-myomata of uterus in, removed by abdominal hysterectomy (C. J. Cullingworth) . . xl, 302
„ degenerated fibro-myoma weighing over 17 lb. enucleated from, nine hours before delivery at term (H. R. Spencer) . xlvi, 122
„ pedunculated fibro-myoma of, with twisted pedicle (C. J. Cullingworth) . . . . . xxxvii, 222
„ hydatids of, or connected with, right (C. J. Cullingworth and H. H. Clutton) . . . . . xlvi, 254
„ infiltration of, with fat, in a case of ovarian dermoid (J. Bland-Sutton) . . . . . xxxiv, 7
„ left, and left Fallopian tube, sac formed by, in a case of extra-uterine pregnancy (C. J. Cullingworth) . . . xxx, 480
„ large myoma of left (Wm. Duncan) . . . xxxi, 309
„ phlegmon of the, *post-mortem* appearances of (A. H. N. Lewers) xxx, 7
„ rapidly growing soft (R. Boxall) . . . . xxxv, 410
„ rupture of tubal pregnancy into (J. Bland Sutton) . . xxxiv, 217
Brodie (G. B.), *report* on C. H. Carter's specimen of six months' fœtus which lived for twenty-one hours . . . xvi, 253
BROMIDE OF POTASSIUM in puerperal mania (J. B. Curgenven) ix, 155
BROMINE, cancer of the womb successfully treated by (A. W. Williams) . . . . . xii, 249
„ epithelioma of lip treated by injection of (A. W. Williams) . xiii, 97
BRONCHO-PNEUMONIA of lying-in women (R. Barnes) . . iv, 55
Brook (W. H. B.), primary tuberculosis of the cervix uteri for which vaginal hysterectomy was performed . . xlv, 185
„ ovarian cyst which had made its way between the layers of the mesosigmoid, both broad ligaments, and the mesocæcum xlv, 415
„ further note on a case of primary tuberculosis of cervix . xlvi, 265
„ three cases of glycosuria of pregnancy . . . xlviii, 192

BROOKES (R.), dissection and description of J. Palfrey's specimen of monster . . . . . xix, 98

BROWN (ANDREW), extra-uterine pregnancy; rupture of the cyst and death . . . . . xi, 7

BROWN (C. R.), remarks in the discussion on puerperal fever . xvii, 153

BROWN (GEO. D.), malignant tumour of omentum . . xviii, 24

BROWN (I. BAKER), fibrous tumour of uterus, illustrating a surgical operation for the cure of this affection . . i, 329

„ ruptured perinæum, and birth of the child between the os vaginæ and anus . . . . . ii, 197

„ fibrous tumours of the uterus treated by surgical means . iii, 67

„ five cases of ovariotomy . . . . . iii, 352

„ retained menses of two years' duration caused by atresia vaginæ; puncture of the uterus by the rectum; recovery . iv, 21

„ ovariotomy, the mode of its performance and the results obtained at the London Surgical Home . . . iv, 59

„ vesico-vaginal fistula, the mode of operating and the results obtained in fifty-five cases at the London Surgical Home . v, 25

„ sequel to a case in vol. iv (p. 21) of the 'Transactions' of retained menses of two years' duration, caused by atresia vaginæ, treated by puncture of the uterus from rectum . v, 162

„ stone in the female bladder; vaginal lithotomy . . v, 217

„ ovarian dropsy treated by tapping and pressure; apparent recovery for three and a half years; return of disease; ovariotomy: recovery . . . . . v, 279

„ fibrous tumours of the uterus, treated by surgical means . vi, 21

„ complete extirpation of the uterus and ovaries, with large fibrous tumours . . . . . vi, 249

„ new method of securing the pedicle in ovariotomy . . vii, 28

„ mixture of chloroform for production of anæsthesia . . vii, 208

„ child born with amputated extremities . . . viii, 102

„ use of the actual cautery in ovariotomy illustrated by eleven cases . . . . . viii, 109

„ notice of the Council's recommendation of removal from the Society of . . . . . ix, 56

„ special meeting for considering removal from the Society of . ix, 61

BRITISH LYING-IN HOSPITAL, puerperal fever in (W. G. Hewitt) x, 69

BRUIT, uterine, observations on the (F. H. Champneys) . xxviii, 188

BRUNTON (JOHN), placenta with round tumours in centre . viii, 275

„ — the subject of extreme fatty degeneration . . ix, 85

„ — with fibrinous deposits . . . . x, 20

„ presentation of right breast, followed by prolapsus of the cord and right arm; delivery by version . . . x, 145

„ placenta with knotted cord . . . . xi, 54

„ observations and remarks on cases of twins . . xi, 67

„ cases of twins in which, while the first child presented naturally, there was placental presentation with the second . xii, 167

„ case where the entire ovum was expelled at the seventh month; the child rescued alive . . . . . xiii, 88

„ fibrous enlargement of the uterus successfully treated by ergot of rye . . . . . xiii, 282

„ remarks in the discussion on puerperal fever . . xvii, 148

„ case of extreme dropsy, fatty degeneration, and friability of the placenta . . . . . xvii, 175

„ infant suffering from double cephalhæmatoma . . xx, 293

BRUNTON (JOHN) (*continued*)—
„ specimen of a rare form of fœtal monstrosity . . xxi, 118
„ fœtal head, plaster casts of . . . . xxiii, 206
BRYANT (T.), ovariotomy, with remarks . . . vi, 35
„ Cæsarean section taken from the posthumous papers of the late T. E. Bryant . . . . . vi, 197
„ fibro-cystic disease of uterus and both ovaries; extirpation of the whole; recovery . . . . . xiv, 79
BUCKELL (EDWARD), specimen of transposed viscera from a pregnant woman, *post-mortem* Cæsarean section, the child saved . xix, 179
BEDIN (P.), and A. PINARD, model phantom for obstetric classes (F. Barnes) . . . . . xix, 229
BUDIN (PAUL), on a diagnostic sign of vaginal hæmorrhage during parturition . . . . . xix, 232
BURCHELL (P. L.), turning in cases of contracted brim . . xxv, 61
BURMESE, midwifery among the (J. F. Pedley) . . xxix, 5
BURTON (ARTHUR), deformed fœtus . . . xl, 217; xli, 339
BURTON (W.), extra-uterine pregnancy . . . xxiii, 34
BUTLER-SMYTHE (A. C.), fibro-cystic tumour of uterus . . xxix, 350
„ dermoid cyst of the ovary . . . . xxxiii, 463
„ double pyosalpinx . . . . . xxxiv, 24
„ dermoid cyst containing pill-like bodies . . xxxvii, 15
„ tubal gestation; incomplete tubal abortion; hæmorrhage; operation; recovery . . . . . xl, 298
„ carcinomatous uterus removed eighteen and a half years subsequent to double ovariotomy . . . . xliii, 214

CÆSAREAN SECTION (J. G. Swayne) . . . v, 84
„ (J. B. Hicks) . . . . . x, 45; xi, 99
„ (H. Gibbons) . . . . . xiii, 131
„ (R. P. Harris) . . . . . xv, 166
„ case of (J. Braxton Hicks) . . . . xx, 106
„ — (C. J. Cullingworth) . . . . . xxix, 252
„ (A. D. Leith Napier) . . . . . xxxiv, 105
„ — discussion . . . . . xxxiv, 138
„ taken from the posthumous papers of the late T. E. Bryant (T. Bryant) . . . . . vi, 197
„ recovery of mother; child not viable (W. Newman) . . viii, 343
„ *report* of a case of, with remarks (D. L. Roberts) . . ix, 250
„ in a dwarf, who died three days after from peritonitis (J. Braxton Hicks) . . . . . xxi, 253
„ in 1866, subsequent natural pregnancy and delivery (W. Newman) . . . . . xiv, 142
„ followed by vaginal hysterectomy for carcinoma of the cervix complicating labour at term (J. M. Munro Kerr) . . xlvii, 194
„ in a case of epithelioma of the cervix uteri complicating pregnancy (A. W. Edis) . . . . . xxiv, 304
„ for contracted pelvis (F. H. Champneys) . . . xxxi, 136
„ — (C. J. Cullingworth) . . . . . xxxiv, 89
„ — (John Shaw) . . . . . xxxiv, 98
„ in cases of contracted pelvis, based upon a series of thirty cases (J. M. Munro Kerr) . . . . . xlvi, 309
„ for deformed pelvis (J. W. J. Oswald) . . . xvii, 378
„ in a case of extreme distortion of the pelvis (R. Greenhalgh) . vii, 220

CÆSAREAN SECTION (*continued*)—
„ and removal of incarcerated ovarian dermoid at the end of the first stage of labour (R. Boxall). . . . xl, 25
„ and total abdominal hysterectomy for fibroids complicating labour near term in a patient who had recovered without operation from ruptured tubal pregnancy (H. R. Spencer) . xlviii, 240
„ followed by removal of a fibroid which filled the pelvic cavity (H. R. Andrews) . . . . . xlviii, 313
„ fibro-myoma from (P. Horrocks) . . . . xxix, 98
„ mortality of (A. L. Galabin) . . . . xxxi, 89
„ case of, on account of extensive malignant disease of the cervix uteri (A. L. Galabin) . . . . xviii, 286
„ performed on account of cicatricial obliteration of the vagina (A. L. Galabin) . . . . . xviii, 252
„ *post-mortem*, in a case of transposed viscera, the child saved (G. Buckell) . . . . . xix, 179
„ segment of uterus after (W. S. A. Griffith). . . xxix, 298
„ suture for closing uterine wound in, and for uniting it to the abdominal wall (R. Barnes) . . . . xii, 364
„ uterus after (R. Greenhalgh) . . . . ix, 241
„ — four years after (J. Bland Sutton) . . . xlix, 174
„ — ovaries, and tubes from a case of (C. J. Cullingworth) . xxxi, 308
„ — with kidneys and ureters, from a case of (W. Duncan) . xxxiv, 127
„ ruptured uterus at term through scar of old (J. H. Targett) . xlii, 242
„ and craniotomy, comparative merits of (R. Greenhalgh) . vii, 270
„ — remarks on the relative position of (A. H. N. Lewers) . xxxiv, 161
CALCAREOUS degeneration, fibroma of the ovary undergoing (C. Hubert Roberts) . . . . . xxxix, 8
„ — fibrous tumour of the uterus in a state of (G. Roper) . xix, 255
„ — of placenta (F. H. Champneys) . . . xxiv, 190
„ intra-mural tumour impeding labour (Wynn Williams) . xvii, 172
CALCIFICATION of arteries, in large fibrotic uterus (J. S. Fairbairn) . . . . . xlvii, 299
„ occurring in a fibroid of the uterus (M. Handfield-Jones) . xxxv, 2
CALCULI, URINARY: URETHRAL.
„ — embedded in the female urethra (J. Matthews Duncan) . xxiii, 109
„ — phosphatic, produced by retention of a Zwancke's pessary for six years (A. L. Galabin) . . . . xix, 201
„ — (A. Routh) . . . . . xxvii, 3
„ URINARY: VESICAL.
„ — multiple, the sequel of prolapsus uteri (A. L. Galabin) . xxii, 106
„ — several from a case of old-standing prolapse (Aust Lawrence) . . . . . xxxii, 366
„ — from a case of old-standing prolapse (Percy Boulton) . xxxii, 367
„ — from a case of procidentia (Aust Lawrence) . . xxx, 227
„ — vaginal lithotomy (I. Baker Brown) . . . v, 217
„ URINARY: VESICO-VAGINAL.
„ — (Clement Godson) . . . . . xxvi, 181
CALCULUS, URINARY: VESICAL.
„ — phosphatic, and bodkin nucleus (Amand Routh) . . xxxv, 240
„ — from female (T. Spencer Wells) . . . iii, 285
CALLENDER (G. W.), remarks in the discussion on puerperal fever . . . . . xvii, 162
CAMERON (Dr.), remarkable development of an infant . . xviii, 115
CANCER, colloid tumours, a large conglomerate of, grown from the omentum (R. Barnes) . . . xvii, 216; xviii, 193

CANCER (*continued*)—
„ primary, of the Fallopian tube, glandular structure in the substance of (Alban Doran) . . . . xxx, 194
„ — — (A. Routh) . . . . xxxi, 200
„ — of the Fallopian tubes, unreported case of, in 1847, with notes on primary tubal cancer (Alban Doran) . xxxviii, 322
„ — of the Fallopian tube, tables of cases, reported up to present date (April, 1898) (Alban Doran) . . xl, 197
„ — — (Alban Doran) . . . . xlii, 6
„ — — (J. Bland-Sutton) . . . . xliv, 311
„ — — (H. R. Andrews) . . . . xlv, 54
„ — of the right Fallopian tube; right ovary normal (H. Briggs) . . . . xlvi, 60
„ — of the ovary (A. L. McIlroy) . . . . xlviii, 251
„ cystic fibroid with carcinoma of left ovary and right Fallopian tube (R. Boxall) . . . . xliii, 71
„ of both ovaries primary to carcimona in the muscular wall of the uterus (C. Lockyer) . . . . xlvi, 302
„ case of supposed, of both ovaries (J. L. Worship) . . xix, 235
„ of ovary extending to uterus and rectum (J. W. J. Oswald) . xviii, 122
„ extirpation of the uterus for (W. Duncan) . . xxxiii, 157
„ of the womb successfully treated by bromine (A. W. Williams) . . . . . xii, 249
„ of the uterus (R. Barnes) . . . . xx, 28
„ — and appendages in a case of (T. C. Hayes) . . xx, 293
„ — with extreme degeneration without marked pain (W. Squire) . . . . . xx, 85
„ — epithelial (Clement Godson) . . . . xx, 29
„ — histology of (A. L. Galabin) . . . xxiii, 161
„ — microscopic sections of (A. H. N. Lewers) . . xxviii, 206
„ — removal by Schroeder's operation (Wm. Duncan) . xxvi, 27
„ — vaginal extirpation for (A. W. Edis) . . . xxvii, 2
„ — — (A. L. Galabin) . . . . xxix, 300
„ — — (W. S. Playfair) . . . . xxxi, 227
„ — — (Wm. Duncan) . . . . xxxii, 306
„ — four cases of (C. J. Cullingworth) . . xxxii, 136, 141, 174
„ — (W. S. Playfair) . . . . xxxix, 288
„ — (J. D. Malcolm) . . . . xlvii, 10
„ — (C. H. Roberts) . . . . xlviii, 311
„ — fibroid tumours and (Amand Routh) . . xxxviii, 99
„ — with fibroid tumour (A. L. Galabin) . . xlv, 102
„ and fibroid in the same uterus (M. Handfield-Jones) . xlvii, 337
„ and fibro-myoma co-existing in the body of the uterus (M. Handfield-Jones) . . . . . xlvi, 305
„ of the body of the uterus (A. H. N. Lewers) . . xxxiv, 213
„ — (M. Handfield-Jones) . . . . xl, 34
„ — abdominal pan-hysterectomy for (A. H. N. Lewers) . xliv, 10
„ — vaginal hysterectomy for (A. H. N. Lewers) . . xxxvi, 374
„ — simulating fibroid in a woman, aged 36 (H. R. Spencer) . xlvi, 235
„ of the uterine body, illustrating the difficuly of diagnosis between this disease and senile endometritis (G. Ernest Herman) . . . . . xxxiii, 31
„ cylindrical or adenoid, of the body of the uterus removed by enucleation (A. L. Galabin) . . . xxviii, 4
„ keratinising, of the body of the uterus (A. H. N. Lewers) . xlv, 97
„ of the corporeal endometrium complicating a case of fibroids of the uterus (J. Bland-Sutton). . . . xlviii, 140

CANCER (*continued*)—
„ independent, of the body and of the cervix uteri (Amand Routh) . . . . . xxxviii, 100
„ secondary hepatic, case of pregnancy complicated by (John Phillips) . . . . . xxix, 378
„ multiple medullary, complicated with (T. H. Tanner) . iv, 243
„ pelvic, pain in, and its relief by morphia, illustrated by fifty cases (F. H. Champneys) . . . . xxii, 5
„ of the cervix uteri (Clement Godson) . . . xxvii, 6
„ — (P. Horrocks) . . . . xxviii, 240
„ — epithelial, and its cavity (C. H. F. Routh) . . viii, 290
„ — medullary (F. H. Daly) . . . xvi, 122, 202
„ — clinical notes on the early course of (C. Liebman) . xvii, 66
„ — complicating pregnancy (A. L. Galabin) . . xxiii, 186
„ — two cases of, complicating labour (G. E. Herman) . xxiv, 308
„ — extending into body of uterus (G. E. Herman) . . xxxii, 137
„ of the cervix associated with pregnancy, abdominal hysterectomy for (D. Drew) . . . . . xlviii, 202
„ — uterus and iliac glands removed by abdominal hysterectomy for (T. V. Dickinson) . . . . xlviii, 15
„ — complicating labour in advanced pregnancy, the patients remaining well eleven, eight and a half, and eight years after high amputation of the cervix (H. R. Spencer) . xlvi, 355
„ — complicating a case of combined vaginal and abdominal hysterectomy for a pregnancy of four and a half months (R. Sanderson) . . . . . xliii, 312
„ — supposed recurrence after vaginal hysterectomy for (C. Hubert Roberts) . . . . . xlix, 114
„ — two cases of, the patients remaining free from recurrence twenty and eleven years respectively after operation (A. H. N. Lewers) . . . . . xlix, 179
„ supra-vaginal amputation for (A. H. N. Lewers) . . xxxiii, 301
„ specimens of cervix uteri removed by the supra-vaginal amputation for (A. H. N. Lewers) . . xxxvii, 201
„ of the cervix from eight cases treated by the supra-vaginal amputation, in which from four to fifteen years had elapsed without recurrence (A. H. N. Lewers) . . . xliv, 221
„ of the cervix uteri complicated by pyometra (W. W. H. Tate) . . . . . xxxix, 323
„ of the cervix associated with an œdematous growth in the fundus (C. Hubert Roberts) . . . . xlii, 267
„ primary, tuberculosis of the cervix simulating, treated by vaginal hysterectomy (A. H. N. Lewers) . . . xliv, 144
„ squamous, of the cervix uteri (F. J. McCann) . . xliv, 136
„ of the cervix, two uteri removed by vaginal hysterectomy for (A. H. N. Lewers) . . . . xxxviii, 164
„ see *Carcinoma*.

CANCEROUS disease of the genital canal, the treatment of pregnancy with (G. E. Herman) . . . . xx, 191
„ hypertrophy of the body of the uterus (J. Matthews Duncan) xx, 27
„ polypi, with microscopic sections (A. L. Galabin) . . xx, 82
„ tumour, pelvic, commencing in the outer cellular tissue of the broad ligament (T. C. Hayes . . . xvi, 102, 127
„ uterus with pyometra (A. H. N. Lewers) . . xxxviii, 14
„ — removed by vaginal hysterectomy (P. Horrocks) . xxxiv, 85
„ — — (Amand Routh) . . . . xxxiv, 87
„ and gravid uterus removed *per vaginam* (W. S. Playfair) xxxvii, 198

CANCEROUS (*continued*)—
„ uterus and parovarian cyst removed *per vaginam* (Amand Routh) . . . . . xxxvii, 8

CAPSULES, on the management of true and false, in ovariotomy (Alban Doran) . . . . . xxxix, 265

CARCINOMA of the broad ligament (T. C. Hayes) . . xvi, 101
„ primary, of the Fallopian tube (C. J. Cullingworth . . xxxvi, 307
„ — — (C. Hubert Roberts) . . . . xl, 189
„ — — second case of (C. Hubert Roberts) . . . xli, 129
„ — — (H. R. Andrews) . . . . . xlv, 54
„ of the Fallopian tubes (C. J. Cullingworth) . . xlvii, 263
„ of omentum and Fallopian tube (Heywood Smith) . xl, 135
„ of left ovary and right Fallopian tube with a cystic fibroid (R. Boxall) . . . . . xliii, 71
„ — after-history of a case of cystic fibroid with (R. Boxall) . xlviii, 136
„ of the ovary (W. W. H. Tate) . . . . xlviii, 96
„ — of unusual type (C. Lockyer) . . . . xlvi, 349
„ epithelial, of the ovary (C. J. Cullingworth) . . xxxii, 199
„ of the ovary, hæmorrhagic (C. J. Cullingworth) . . xxxiii, 445
„ primary, of both ovaries (C. Lockyer) . . . xlvi, 229
„ of ovary, primary solid (W. S. A. Griffith) . . xlii, 34
„ of uterus (W. S. Playfair) . . . . xxxix, 288
„ columnar-celled, of the uterus (C. J. Cullingworth) . xxxii, 165
„ primary, extirpation of the uterus for (A. H. N. Lewers) . xxx, 218
„ squamous-celled, of the uterus (C. J. Cullingworth) xxxii, 164—166
„ of the body of the uterus (W. S. Playfair) . . xii, 116
„ — (J. H. Targett) . . . . . xlii, 281
„ of the corpus uteri invading a myoma: hysterectomy (J. M. Munro Kerr) . . . . . xlvii, 191
„ of the body of the uterus, with secondary growth in both ovaries (H. T. Hicks) . . . . . xlviii, 196
„ primary, of the body, uterus removed by abdominal pan-hysterectomy for (A. H. N. Lewers) . . . xliv, 290
„ — of the body of the uterus in which vaginal hysterectomy was performed, etc. (A. H. N. Lewers) . . . xxxvi, 374
„ keratinising, of the body of the uterus (A. H. N. Lewers) . xlv, 97
„ of body and multiple fibromata of uterus removed by abdominal pan-hysterectomy (J. H. Dauber) . . . xxxix, 321
„ of body of uterus, with fibro-myoma and fibroma of ovary (W. W. H. Tate) . . . . . xlvi, 139
„ of the body in a uterus, with multiple fibroids (A. H. N. Lewers) . . . . . xlvi, 266
„ of the cavity of uterus (P. Smith) . . . xii, 299
„ in the muscular wall of the uterus secondary to cancer of both ovaries (C. Lockyer) . . . . . xlvi, 302
„ of the cervix uteri complicating pregnancy (A. L. Galabin) . xviii, 239
„ of the cervix complicating labour at term; Cæsarean section, followed by vaginal hysterectomy (J. M. Munro Kerr) . xlvii, 194
„ of the cervix uteri removed by supra-vaginal amputation, with previous induction of abortion (A. H. N. Lewers) . . xxx, 81
„ of cervix uteri in which the disease extended upwards into the body (Walter W. H. Tate) . . . . xl, 258
„ of the cervix complicated by tubal mole (A. H. N. Lewers) . xlv, 335
„ of cervix uteri, with double salpingitis, complicating fibro-myoma of uterus (W. W. H. Tate) . . . xliii, 270
squamous, of cervix uteri (F. J. McCann) . . . xliv, 136

CARCINOMA (*continued*)—
„ squamous-celled, of the cervix uteri, in which the disease had extended in an upward and not in a downward direction (C. J. Cullingworth) . . . . . xxxiv, 136
„ of the cervix, uterus with fibroid tumours and, removed *post-mortem* from a patient on whom eight years previously the operation of oöphorectomy had been performed (G. F. Blacker) . . . . . xxxvii, 213
„ uterine fibroid associated with (A. L. Galabin) . xxxviii, 102
„ primary, of the vagina (F. J. McCann) . . . xlviii, 181
„ see *Cancer*.
CARCINO-SARCOMA uteri (H. R. Spencer) . . . xlvii, 338
CARBON, anæsthetic properties of the bichloride of (A. E. Sansom) . . . . . viii, 49
CARIES of the pelvic bones following delivery (W. S. Playfair) . xviii, 142
CARLYLE (DAVID), casts of the head of an anencephalous fœtus, with description of the labour . . . . xi, 35
CARTER (C. H.), six months' fœtus which lived for twenty-one hours xvi, 226
„ *report* on ditto by committee (C. H. F. Routh and George B. Brodie) . . . . . xvi, 253
„ and F. H. Daly, foreign body in the vagina, removal after four years, and after-results . . . . xxii, 34
„ case of large foreign body in the vagina for two years, perforating the wall of the bladder, its removal and closure of the fistulous opening . . . . . xxii, 38
„ two cases of extra-uterine fœtation, with results . xxii, 160
„ absence of the vagina, uterus distended by retained menstrual fluid, operation, recovery . . . . xxii, 251
„ fibrous tumour of the uterus . . . . xxiv, 2
„ fibroid tumour of the right ovary . . . xxiv, 139
„ uterine tumour . . . . . xxiv, 161
„ cystic degeneration of subperitoneal fibroid of the uterus . xxv, 108
„ cystic disease of both ovaries . . . . xxv, 109
„ double dermoid ovarian cysts . . . . xxvi, 86
„ fibro-myoma of right ovary removed by abdominal section . xxix, 190
„ double hydrosalpinx . . . . . xxx, 3
„ epitheliomatous growth from the cervix uteri . . xxx, 82
„ ovarian cyst, partly dermoid . . . . xxxii, 6
„ two dermoid cysts from the same patient . . . xxxii, 6
„ lipoma removed from left labium majus of a woman aged 40 . xxxii, 6
„ double pyosalpinx . . . . . xxxii, 64
„ diseased ovaries and tubes . . . . xxxii, 136
CARTER (C. M.), large fibroid tumour of uterus . . xiii, 167
CARUNCLES, urethral, structure of three different types (H. Williamson) . . . . . xlvii, 6
CASELLA (Prof.), transfusion apparatus (presented) . . xvii, 45
CASES IN PRACTICE (J. Bassett) . . . . xiv, 58
„ (E. Copeman) . . . . . xiii, 232
CAST of female bladder (J. H. Aveling) . . . xxv, 33
„ decidual, importance of, as evidence of extra-uterine gestation (W. S. A. Griffith) . . . . xxxvi, 335
„ from the uterus having all the characters of the decidual membrane found in connection with ectopic gestation together with a small ovarian cyst from the same case, with microscopic sections of each (W. R. Dakin) xxxviii, 385

CAST (*continued*)—
„ decidual, of the uterus from a case in which there was no evidence of extra-uterine gestation, with microscopic sections (T. W. Eden) . . . . . xxxix, 132
„ — uterine, expelled after eight weeks' amenorrhœa, together with an ovum of about five days' growth (W. E. Fothergill) xliii, 162
„ of the uterus (T. W. Eden) . . . . xlii, 5
CASTS, epidermic, from the vagina (J. H. Targett) . xxxvii, 218
CAT, pelvis of, with bladder, uterus, and rectum *in situ* (H. T. Rutherfoord) . . . . . xxxiv, 251
„ pregnant horn from the uterus of (Robert Wise) . . xxxix, 260
CATHETER, glass female (R. Barnes) . . . xxvi, 232
CAULIFLOWER EXCRESCENCE of the uterus (E. F. Fussell) vi, 102
CAUSATION of puerperal infections, investigation into (A. G. R. Foulerton and V. Bonney) . . . xlvii, 11
CAUTERISATION by electric heat in the treatment of certain diseases of women (R. Ellis) . . . iii, 424
CAUTERY, actual, use of in ovariotomy (I. B. Brown) . . viii, 109
„ thermo-, Paquelin's, by vapour of petroleum (O. Prevôt) . xviii, 180
„ three new points for (Heywood Smith) . . . xix, 41
„ regulator to be used with (J. H. Aveling) . . . xx, 293
CELLS, vesicular mole, showing syncytium derived from chorionic epithelium, partially differentiated into (A. L. Galabin) . xlv, 240
CELLULITIS, pelvic, noted with special reference to the temperature (C. J. Cullingworth) . . . . xii, 370
CELOSOMA see *Monsters*.
CEPHALHÆMATOMA, double, infant suffering from (J. Brunton) xx, 293
CEPHALHÆMATOMATA, bilateral (S. W. Wheaton) . . xxxv, 6
CEPHALOTRIBE, (J. B. Hicks) . . . . viii, 275
„ (J. M. Duncan) . . . . . xi, 42
„ remarks on (J. B. Hicks) . . . . xi, 43
„ (G. H. Kidd) . . . . . xii, 1
„ (A. E. Martin) . . . . . xiv, 65
„ Hicks's, alteration of (G. Roper) . . . . xix, 137
„ new form of (C. E. Jennings) . . . . xxiv, 238
„ (Fancourt Barnes) . . . . . xxvi, 27
„ face presentation, delivery effected by (J. B. Hicks) . . x, 144
„ fœtus delivered by (J. B. Hicks) . . . xi, 1
CEPHALOTRIPSY as performed at Vienna by Professor Braun (C. (J. Ritchie) . . . . . vi, 75
„ cast from the head of a child extracted by (H. Smith) . xii, 134
„ cast of head of child after (Heywood Smith) . . xiii, 37
„ head of child delivered by, with Hicks's instrument (R. Barnes) . . . . . xi, 191
„ craniotomy; Cæsarean section in case of extreme distortion of the pelvis (R. Greenhalgh) . . . . vii, 220
„ three cases, report of (J. Braxton Hicks) . . . xvii, 49
„ with short remarks (J. B. Hicks) . . . . xv, 41
CEREBRAL HÆMORRHAGE, see *Hæmorrhage*.
CERVIX UTERI, see *Uterus* (cervix of).
Chadwick (James R.), election as Honorary Fellow . . xlii, 40
„ letter acknowledging election as Honorary Fellow . . xlii, 132

CHAHBAZIAN (C.), on the treatment of post-partum hæmorrhage by hypodermic injection of ergotinine . . . xxiv, 286
CHALMERS (JOHN), extra-uterine fœtation . . . xviii, 67
„ *report* on ditto by committee (A. L. Galabin and J. Chalmers) xviii, 82
„ for *Dr. McLaurin*, twin monster in its seventh month . xxii, 155
„ hermaphrodite, genito-urinary organs of . . . xxiv, 239
„ for *C. Hurford*, twin female monster . . . xxv, 111
„ case of spurious hermaphroditism . . xxv, 129, 162
CHAMBERLEN, PAUL or PETER, question of portrait of . . xvi, 245
CHAMBERS (THOMAS), uterine fibroid . . . xi, 31
„ complete inversion of uterus . . . . xvi, 181
„ retroversion of the gravid uterus . . . . xvi, 181
„ fibroid uterus . . . . . xviii, 177
„ fibro-cystic disease of the uterus weighing 14 lb. . . xx, 32
„ — *report* on ditto by committee (A. L. Galabin, G. E. Herman, and T. Chambers) . . . . xx, 54, 55
„ two ovaries from a case of congenital inguino-ovarian hernia (double); recovery . . . . xxi, 92, 256
„ — *report* on ditto by committee (John Williams and A. L. Galabin) . . . . . xxi, 269
„ fibro-cystic disease of the uterus . . . . xxii, 159
„ — *report* on ditto by committee (G. G. Bantock, F. H. Champneys, and Thomas Chambers) . . . xxii, 187
„ eczema of the nipple in both breasts . . . xxii, 266
„ complete extirpation of the uterus with both ovaries, weighing 10 lb.; recovery . . . . . xxiii, 12
CHAMPETIER DE RIBES' BAG, treatment of placenta prævia by (G. F. Blacker) . . . . . xxxix, 138
CHAMPNEYS (F. H.), uterus and neighbouring parts from a woman who died from the bursting of an aneurysm of a branch of the pulmonary artery . . . . . xx, 124
„ on the pain in pelvic cancer and its relief by morphia, illustrated by fifty cases . . . . . xxii, 5
„ retroflexed uterus . . . . . xxii, 156
„ uterus of a woman aged 69, with large fibroid . . xxii, 185
„ incomplete rupture of vagina discovered *post mortem*; death from septicæmia . . . . . xxiii, 10
„ for *G. C. P. Murray*, calcareous degeneration of placenta . xxiv, 190
„ on the obliquely contracted pelvis of a child with left sacro-iliac synostosis, together with remarks on the pelvis of Naegele xxiv, 191
„ extroversion of the bladder . . . . xxiv, 240
„ description of a kyphotic pelvis, with remarks on Breisky's description . . . . . xxiv, 242
„ on the pressure of the femora, and its influence on the shape of the pelvis . . . . . xxv, 70
„ demonstrations illustrating the separation and expulsion from the uterus of the placenta . . . . . xxv, 160
„ the obstetrics of the kyphotic pelvis . . . xxv, 166
„ — second communication . . . . xxviii, 253
„ placenta succenturiata . . . . . xxv, 214
„ ruptured uterus . . . . . xxvi, 329
„ for *Fly Smith*, pellets of corrosive sublimate . . xxviii, 66
„ note on the artificial production of so-called lymphatic varix . xxviii, 144
„ observations on the uterine bruit . . . xxviii, 188
„ the mechanism of the third stage of labour: (1) the separation of the placenta . . . . . xxix, 117

CHAMPNEYS (F. H.), the mechanism of the third stage of labour (*continued*)—
„ — (2) the expulsion of the placenta . . . xxix, 151
„ — (3) the separation and expulsion of the membranes . xxix, 264
„ — (4) some causes of retention of the membranes . . xxix, 317
„ — (5) note on the relation between the implantation of the placenta and the insertion of the cord . . . xxix, 337
„ mechanism of the third stage of labour; adjourned discussion on papers Nos. 3–5 . . . . . xxix, 346
„ on primary laparotomy (that is, abdominal section in the latter half of pregnancy, the child being alive) in cases of extra-uterine gestation . . . . . xxix, 456
„ description of a new operation for vesico-uterine fistula . xxx, 348
„ case of Cæsarean section for contracted pelvis . . xxxi, 136
„ inaugural address as President . . . xxxvii, 83
„ annual address as President . . xxxviii, 60; xxxix, 56

CHANCRE on the cervix uteri (G. E. Herman) . . xxvii, 252
„ on os uteri (W. B. Woodman) . . . . vii, 26

CHAPMAN (W.), retention of the catamenia for more than two years in a married woman . . . . iv, 251

CHEPMELL (CHARLES), uterus from a septic case . . xxxvi, 3

CHEST and abdomen, the change in size of, during the lying-in period, and the effect of the binder upon them (G. E. Herman) xxxii, 108

CHILD (EDWIN), case of extra-uterine fœtation . . xviii, 119

CHILDBED, antiseptic irrigation in, instruments for (Graily Hewitt) . . . . . xxxi, 202
„ fever in.—Part I.—General hygiene and antisepsis (R. Boxall) xxxii, 219, 275
„ — Part II.—The relation of external meteorological conditions to the incidence of febrile illness in childbed (R. Boxall) . xxxv, 340
„ see *Puerperium*.

CHILDBIRTH, see *Parturition*.

CHILDREN, temperature variations in the diseases of (W. Squire) xii, 171
„ vulval discharges in (G. Drummond Robinson) . . xli, 14

CHLORAL TREATMENT of eclampsia (P. von Seydewitz) . xii, 117

CHLORIDE of sodium, sterilised saturated solution of (H. R. Spencer) . . . . . xxxv, 428

CHLOROFORM for production of anæsthesia (I. B. Brown) . vii, 208
„ inhaler for (H. W. Liddard) . . . . xvi, 88
„ — pocket (J. Murray) . . . . . x, 95

CHLOROSIS and anæmia, treatment of, with the phosphide of zinc (J. A. Thompson) . . . . . xvii, 57
„ and menstruation, the relation between (W. Stephenson) . xxxi, 104

CHOLERA in the newly born (J. C. Lucas) . . . xxi, 250

CHOREA with pregnancy (W. B. Woodman) . . . vii, 102
„ in pregnancy (R. Barnes) . . . . x, 147
„ — successfully treated by dilatation of the os uteri (W. F. Wade) . . . . . xxii, 244
„ — (M. Handfield-Jones) . . . . xxxi, 243
„ gravidarum (Fred J. McCann) . . . xxxiii, 413, 466
„ showing the behaviour of the pregnant uterus in (J. Braxton Hicks) . . . . . xxxiii, 486

CHORION, atrophy of (G. E. Herman) . . . xxvii, 195

CHORION (*continued*)—
„ cystic degeneration of, in a case of missed abortion (G. E. Herman) . . . . . xxii, 44
„ stems, hyperplasia of, with partial cystic degeneration (W. S. A. Griffith) . . . . . xxx, 82
„ cystic, hydatiform degeneration of (John Phillips) . . xxxii, 65
„ — disease of (Aust Lawrence) . . . . xxxii, 64
„ hydatidiform degeneration of, associated with albuminuria (W. B. Woodman) . . . . . vii, 113
„ hydatidiform degeneration of preceding deciduoma malignum *without* syncytium; secondary deposits in vagina, lymphatic glands (iliac and lumbar), and lungs (P. Horrocks) . xlv, 243
„ fibro-sarcoma of (A. L. Galabin) . . . . . xxvii, 107
„ myxoma of, not discharged till the seventh month (C. H. Roberts) . . . . . xlii, 168
„ pathology and symptoms of hydatidiform degeneration of (Herbert Williamson) . . . . . xli, 303
„ villi of the, ovum expelled about the eighth week showing (A. W. Edis) . . . . . xvii, 48
„ — and doubtful sarcoma, microscopical sections of uterus showing (Leonard Remfry) . . . . xxxviii, 223
„ — from a tubal mole removed by abdominal section (A. H. N. Lewers) . . . . . xxxviii, 106
CHORION-EPITHELIOMA (H. R. Andrews) . . . xlv, 238
„ (H. Briggs) . . . . . xlv, 239
„ (A. L. Galabin and T. G. Stevens) . . . xlv, 241
„ (J. M. Munro Kerr) . . . . . xlv, 244
„ (J. B. Hellier) . . . . . xlvii, 310
„ (John Phillips) . . . . . xlviii, 45
„ complicated by hæmatometra (W. S. A. Griffith and H. Williamson) . . . . . xlix, 241
„ with pulmonary metastases (Cuthbert Lockyer) . . xliv, 24
„ of the uterus, with secondary growths in the vagina, the lungs, and the liver (G. F. Blacker) . . . xlvi, 55
„ with secondary growths in vagina, kidney, pancreas, lungs, and ? lymphatic glands (C. Lockyer) . . . xlv, 245
„ malignum, with secondary growths in liver (J. H. Teacher for *Professor Sutherland* and *Dr. Buist*) . . . xlv, 252
„ and the occurrence of chorion-epitheliomatous and hydatidiform mole-like structures in teratomata (J. H. Teacher), adjourned discussion on . . . . xlv, 303
„ (the so-called deciduoma malignum) and the occurrence of chorion-epitheliomatous and hydatidiform mole-like structures in tumours of the testis (J. H. Teacher) . . xlv, 256
„ malignum; primary tumour in uterus (J. H. Teacher) . xlv, 252
„ — two photographs of pelvic organs with primary tumour, and a glass tube containing a secondary nodule from the lungs (J. H. Teacher) . . . . . xlv, 253
„ uterus removed by vaginal hysterectomy, showing nodule of (F. W. N. Haultain) . . . . . xlv, 242
„ following hydatidiform mole, in a patient with bilateral ovarian cysts, with pathological report and references to the literature on kindred cases (J. D. Malcolm, R. H. Bell, and C. Lockyer) xlv, 483
„ compound lutein cystomata found in association with vesicular mole and (C. Lockyer) . . . . . xlvii, 157
„ of the uterus; lutein cysts in both ovaries (G. F. Blacker) . xlix, 104
„ of the vagina, primary embolic (H. T. Hicks) . . xlix, 224

CHOROIDO-RETINITIS, central, occurring after labour and post-partum hæmorrhage (H. Macnaughton Jones) . . xxxii, 134

CHURTON (T.), case of recto-vaginal fistula caused by a Zwancke's pessary retained for nearly two years . xvi, 223

CHYLOUS CYST, large, of the mesentery (Ad. Rasch) . . xxxi, 311

CHYLURIA with pregnancy (J. C. Holdich Leicester) . . xlvii, 108

CICATRICES from a burn requiring division during labour (E. F. Willoughby) . . . . . xii, 31

CIRCULATION of blood in the uterus, with some of its anatomical and pathological bearings (John Williams) . . xxvii, 112

CLABBURN (T. G.), see *Playfair, W. S.*

CLAPHAM (EDWARD), shrivelled fœtus of the fifth month utero-gestation . . . . . xxxi, 202

CLARKE (REGINALD), see *Phillips, John.*

CLAY (CHARLES), ovarian cyst co-existing with pregnancy, which ruptured spontaneously ten days after labour . . i, 226

„ ovariotomy, statistical and practical; also a successful case of entire removal of uterus and its appendages . . v, 58

„ wire loops, horseshoe wires, etc., for correcting anteversion, retroversion, obliquities, and prolapse of the unimpregnated uterus . . . . . v, 177

CLEVELAND, (W. F.), infant of doubtful sex . . . ix, 29

„ perforator of wedge-scissors construction . . . ix, 56

„ imperforate anus in which the child lived upwards of ten weeks without relief from the bowel after two unsuccessful operations . . . . . ix, 203

„ apparatus for injecting *ferri perchloridi* . . . xi, 242

„ fœtus and placenta of five months, funis knotted round neck of child . . . . . xiii, 1

„ five months fœtus with intense congestion of head and neck . xvi, 2

„ remarks in the discussion on the use of forceps . . xxi, 226

„ thick gelatinous cord, illustrating the necessity for more than ordinary care in tying . . . . xxi, 313

„ for *G. S. Walker*, large hydrencephalocele in a female child . xxii, 157

„ fleshy substance discharged from uterus, xxiii, 132; xxiv, 297; xxvi, 117

„ *reports* on ditto by committee (A. L. Galabin, John Williams, and W. F. Cleveland) . . . xxiii, 181; xxvi, 334

„ double uterus with deciduous membrane . . . xxvi, 181

CLITORIS, elephantine development of (W. R. Rogers) . xi, 84

„ excision of, as a cure for hysteria (T. H. Tanner) . . viii, 360

„ hypertrophied nymphæ and (W. Duncan) . . xxxvi, 3, 149

„ symmetrically hypertrophied (J. H. Aveling) . . xvi, 1

CLUTTON (H. H.), see *Cullingworth, Charles J.*

COATES (GEORGE), case of labour in a primipara suffering from mitral stenosis . . . . . xxviii, 108

COATES (N.), prolapsus uteri in which the neck of the uterus was partially severed by a ligature of hair which had accumulated around it . . . . . xv, 9

COCCYX, outgrowth from end of (Heywood Smith) . . xxv, 2

COCKELL (F. E., jun.), fœtal monstrosity . . . xxv, 110

COFFIN (MAITLAND), fœtal monstrosity . . . xxiv, 98

CŒLIOTOMY, for extraction of a living fœtus, after term in a case of tubo-abdominal pregnancy (J. Bland-Sutton) . . xl, 308

CŒLIOTOMY (*continued*)—
„ anterior vaginal, anterior hysterotomy and replacement, with recovery after failure of elastic pressure with repositors in a case of complete inversion of uterus of seven months' duration (J. W. Taylor). . . . . xliv, 299
COLE (BEVERLEY), spring pessaries . . . . xxiii, 238
COLEY (—), new forceps bent as a sound for the introduction of laminaria tents . . . . . xx, 170
COLLAPSE (cirrhosis) atrophy with fibroid degeneration, and angioma of the ovaries (J. Braithwaite) . . . xxxvi, 325
COLOTOMY, Amussat's operation for complete obliteration of the canal of the small intestine by fœtal peritonitis (R. Druitt) ii, 135
COLOPOTOMY, anterior (John Phillips) . . xxxviii, 213
„ hydrosalpinx and small ovarian cyst removed by anterior (Amand Routh) . . . . xxxviii, 185
„ cystic fibro-myoma of the uterus removed by posterior (H. R. Spencer) . . . . . xliii, 110
„ posterior, for removal of dermoid cyst of ovary (A. Routh) . xliv, 38
„ for removal of tubal mole (F. J. McCann) . . . xliv, 133
COMMITTEES, REPORTS OF:
„ on G. F. Butler Willing's specimen of five and a half months fœtus (Henry Savage and C. H. F. Routh) . . xvi, 97
„ on C. Godson's specimen of acephalous embryo (John Williams and C. Godson) . . . . . xvi, 121
„ on T. C. Hayes' specimen of cancerous pelvic tumour (Heywood Smith) . . . . . xvi, 127
„ on F. H. Daly's specimen of uterine tumour and attached ovarian cyst (J. B. Potter and T. C. Hayes) . . xvi, 202
„ on Alfred Meadows' specimen of membrane passed in a case of so-called membranous dysmenorrhœa (J. H. Aveling and John Williams) . . . . . xvi, 251
„ on C. H. Carter's specimen of six months fœtus which lived for twenty-one hours (C. H. F. Routh and G. B. Brodie) . xvi, 253
„ on W. R. Rogers' specimen of hæmatocele (Heywood Smith and W. R. Rogers) . . . . . xvi, 274
„ on J. Ashburton Thompson's specimen of an ascitic fœtus (John Williams and J. A. Thompson) . . . xvii, 66
„ on Frederick Wallace's specimen of uterus, left ovary, vagina, and tumour (T. C. Hayes and J. H. Aveling) . . xvii, 276
„ on Frederick Wallace's case of monstrosity (J. H. Aveling and T. C. Hayes) . . . . . xvii, 277
„ on A. L. Galabin's specimen of organs taken from a subject of extra-uterine pregnancy (W. S. Playfair, John Williams, and A. L. Galabin) . . . . . xvii, 384
„ on John Chalmers' specimen of extra-uterine fœtation (A. L. Galabin and J. Chalmers) . . . . xviii, 82
„ on R. Hughes' specimen of carneous mole (John Williams and W. B. Woodman) . . . . . xviii, 311
„ on J. Palfrey's specimen of monster (W. S. Playfair and T. C. Hayes) . . . . . xix, 97
„ on A. L. Galabin's specimen of a fœtus in which ascites was combined with distension of the bladder (John Williams and A. L. Galabin) . . . . . xix, 120
„ on A. L. Galabin's case of suppuration of the uterine cavity resulting from occlusion of the cervix (G. Roper and A. L. Galabin) . . . . . xix, 177

COMMITTEES, REPORTS OF (*continued*)—
„ on T. Chambers' specimen of fibro-cystic disease of the uterus (A. L. Galabin, G. E. Herman, and T. Chambers) . . xix, 55
„ on T. Chambers' specimen of two ovaries from a case of congenital inguino-ovarian hernia (John Williams and A. L. Galabin) . . . . . xxi, 269
„ on C. J. Cullingworth's specimen of fibroma of both ovaries (J. Knowsley Thornton and Alban Doran) . . xxi, 314
„ on Heywood Smith's specimen of uterus and appendages removed by hysterectomy (A. L. Galabin and John Williams) . xxii, 3
„ on Clement Godson's specimen of rupture of Fallopian tube (John Williams, Clement Godson, and A. L. Galabin) . xxii, 82
„ on Thomas Chambers' specimen of fibro-cystic disease of the uterus (G. G. Bantock, F. H. Champneys, and Thomas Chambers) . . . . . xxii, 187
„ on Clement Godson's specimen of ruptured tubal fœtation (John Williams, A. L. Galabin, and Clement Godson) . xxii, 242
„ on W. F. Cleveland's specimen of fleshy substance discharged from the uterus (A. L. Galabin, John Williams, and W. F. Cleveland) . . . . . xxiii, 181
„ on Wynn Williams' specimen of fibroid tumour (Alban Doran, Clement Godson, and F. H. Champneys) . . . xxv, 70
„ on William Duncan's specimen of hydatidiform mole (F. H. Champneys, Alban Doran, and W. Duncan) . . xxv, 233
„ on William Duncan's specimen of ruptured ovarian cyst (Alban Doran, W. S. Playfair, and W. Duncan) . . xxv, 234
„ on F. L. Neugebauer's specimens and photographs of spondylolisthesis (R. Barnes, William Adams, Noble Smith, and Alban Doran) . . . . . xxvi, 186
„ on W. F. Cleveland's specimen of deciduous membrane of pregnancy (John Williams, A. L. Galabin, and W. F. Cleveland) xxvi, 331
„ Robert Harvey's specimen of rupture of the uterus (F. H. Champneys and Alban Doran) . . . . xxvii, 228
„ on E. F. Grün's specimen of supposed extra-uterine gestation with birth through uterus (G. E. Herman and Alban Doran) xxvii, 306
„ on H. Campbell Pope's specimen of gestation in one horn of a uterus bicornis unicollis (G. E. Herman, Alban Doran, and W. S. A. Griffith) . . . . . xxviii, 72
„ on Amand Routh's specimen of fibroid of one-horned uterus (Alban Doran, W. S. A. Griffith, and Amand Routh) . xxix, 57
„ on G. M. Bluett's specimen of tumours of fœtal membranes (A. L. Galabin, G. E. Herman, and Alban Doran) . . xxix, 512
„ on John Williams' specimen of fibroma of the ovary (A. L. Galabin, G. E. Herman, and Alban Doran) . . xxix, 513
„ on W. A. Meredith's specimens of fibro-cystic tumour of the ovary and fibro-myoma of the broad ligament (A. L. Galabin, G. E. Herman, and Alban Doran) . . xxix, 513, 514
„ on J. D. Malcolm's specimen of fibroma (A. L. Galabin, G. E. Herman, and Alban Doran) . . . . xxix, 515
„ on Sidney Harvey's specimen of extra-uterine gestation (J. Braxton Hicks, Sidney Harvey, and W. S. A. Griffith) . xxx, 166
„ on P. Horrocks's specimen of inverted uterus with fibroid (Alban Doran and P. Horrocks) . . . . xxx, 228
„ on Aust Lawrence's specimen of an extra-uterine fœtation (Alban Doran, G. E. Herman, and F. H. Champneys) . xxx, 302
„ on F. G. Penrose's specimen of tubo-abdominal pregnancy (Alban Doran, G. E. Herman, and F. H. Champneys) . xxx, 303

COMMITTEES, REPORTS OF (*continued*)—
„ on John Phillips's case of congenital sarcoma in a new-born infant (John Phillips and Alban Doran) . . . xxx, 335
„ on John Phillips's specimen of an aborted ovum showing cysts in the decidua vera (F. H. Champneys, John Phillips, and W. S. A. Griffith) . . . . . xxxi, 161
„ on W. S. Playfair's specimen of small ovarian cyst and hæmatosalpinx (W. S. Playfair, Alban Doran, and W. S. A. Griffith) xxxi, 162
„ on C. Stewart Pollock's specimen of ovarian dermoid from a mare (J. Bland-Sutton, C. Stewart Pollock, and Alban Doran) xxxi, 253
„ on Alban Doran's specimen of fragment of membrane passed from the uterus (John Williams, W. S. A. Griffith, and Alban Doran) . . . . . xxxi, 310
„ on A. H. Robinson's specimen of placenta prævia (W. S. Playfair, F. H. Champneys, and C. J. Cullingworth) . . xxxii, 107
„ on Amand Routh's specimen of acardiac fœtus (J. Bland-Sutton, Amand Routh, and Alban Doran) . . xxxiii, 26
„ on W. Duncan's specimen of extirpated uterus (W. Duncan, W. S. A. Griffith, S. W. Wheaton, and G. E Herman) . xxxiii, 161
„ on J. H. Targett's specimen of spondylolisthesis in a girl aged 16 (J. H. Targett, A. L. Galabin, G. E. Herman, and F. H. Champneys) . . . . . xxxiii, 463
„ on G. E. Herman's specimen of amorphous acardiac twin (G. E. Herman, W. S. A. Griffith, Alban Doran, and J. Bland-Sutton) . . . . . xxxiv, 11
„ on Heywood Smith's specimen of abscess of the ovary (J. Bland-Sutton, Alban Doran, and Heywood Smith) . xxxiv, 83
„ on C. J. Cullingworth's specimen of unruptured tubal gestation with apoplexy of the ovum (J. Bland-Sutton, C. J. Cullingworth, Alban Doran, and William Duncan) . xxxiv, 157
„ on W. S. Playfair's specimen of hæmatosalpinx (W. S. Playfair, W. S. A. Griffith, and G. E. Herman) . . xxxiv, 467
„ on A. E. Giles's specimen of malformation of rectum and bladder, congenital absence of both kidneys and ureters, etc. (A. E. Giles, W. R. Dakin, and Alban Doran) . . xxxiv, 468
„ on C. J. Cullingworth's specimen of tubal gestation with apoplectic ovum (C. J. Cullingworth, A. Doran, W. Duncan, and J. Bland-Sutton) . . . . . xxxiv, 468
„ on J. R. Ratcliffe's specimen of uterus bicornis (J. H. Targett, J. R. Ratcliffe, and A. Doran) . . . . xxxiv, 470
„ on A. Rasch's case of mollities ossium (A. Rasch, P. Horrocks, R. Boxall, and W. S. A. Griffith) . . . xxxv, 40
„ on S. W. Wheaton's specimen of dermoid tumour with bony girdle (C. J. Cullingworth, H. R. Spencer, and S. W. Wheaton) xxxv, 41
„ on Amand Routh's specimen of fœtus showing ectopia viscerum with retroflexion (W. R. Dakin, J. H. Targett, A. Doran, and A. Routh) . . . . xxxv, 102
„ on Amand Routh's specimen of anencephalic monster (A. Routh, H. R. Spencer, and A. E. Giles) . . . xxxv, 294
„ on Amand Routh's specimen of fibroma spontaneously enucleated (J. H. Targett, W. S. A. Griffith, and Amand Routh) xxxvi, 2
„ on William Duncan's specimen of hypertrophied vulva (P. Horrocks, W. Duncan, and W. W. H. Tate) . . xxxvi, 150
„ on W. A. Grogono's specimen of fœtus acephalus acardiacus (W. A. Grogono, J. Bland-Sutton, and A. E. Giles) . xxxvi, 185
„ on William Duncan's specimen of tumour removed from the abdomen (A. F. Voelcker) . . . . xxxvi, 265

COMMITTEES, REPORTS OF (*continued*)—
„ on Thomas W. Eden's specimen of tubal mole (A. Doran, T. W. Eden, and J. Bland-Sutton) . . . . xxxvi, 301
„ on Leith Napier's specimen of deformed fœtus (A. E. Giles, W. Dakin, and L. Napier) . . . . xxxvi, 302
„ on William Duncan's specimen of double pyosalpinx (W. Duncan, W. S. A. Griffith, and E. J. Maclean) . xxxvii, 295
„ on Herbert J. Ilott's specimen of fœtus papyraceus (H. J. Ilott, A. E. Giles, and A. Doran) . . . xxxvii, 16
„ on C. J. Cullingworth's specimen of supposed tubo-ovarian cyst ('Transactions,' vol. xxxvii, p. 295) (W. S. A. Griffith, C. J. Cullingworth, J. Bland-Sutton, and A. Doran) xxxviii, 4
„ on L. Napier's specimen of solid ovarian tumour ('Transactions,' vol. xxxvii, p. 283) (J. Bland-Sutton, C. J. Cullingworth, L. Napier, and W. S. A. Griffith) . . xxxviii, 32
„ on A. H. N. Lewers's specimen which was shown as a tubal mole ('Transactions,' vol. xxxvii, p. 78) (J. Bland-Sutton, A. Doran, and A. H. N. Lewers) . . . xxxviii, 87
„ on A. L. Galabin's specimen of extra-uterine gestation (A. Routh, A. Doran, A. L. Galabin, and T. W. Eden) xxxviii, 88
„ on A. Routh's specimen of fœtus diprosopus anencephalicus ('Transactions,' vol. xxxvii, p. 162) (W. R. Dakin, C. H. Roberts A. E. Giles, and A. Routh) . . xxxviii, 92
„ on J. Rutherford Morison's and H. R. Spencer's specimen of deciduoma malignum and J. D. Malcolm's specimen of sarcoma of the uterus (A. A. Kanthack, J. Bland-Sutton, J. H. Targett, H. R. Spencer, A. Doran, T. W. Eden, and W. S. A. Griffith) . . . . xxxviii, 183
„ on Walter W. H. Tate's specimen of tubo-ovarian abscess (C. H. Roberts, J. Bland-Sutton, and W. W. H. Tate) xxxviii, 380
„ on A. H. N. Lewers's specimen of fœtus with cystic tumour of neck (A. Doran, A. H. N. Lewers, and J. H. Targett) . xxxix, 2
„ on L. Remfry's specimen shown as chorionic villi and doubtful sarcoma (A. Doran, A. A. Kanthack, J. H. Targett, L. Remfry, J. Bland-Sutton, H. R. Spencer, T. W. Eden, and W. S. A. Griffith) . . . . . xxxix, 2
„ on H. Macnaughton-Jones's specimen of tumour of the ovary (H. Macnaughton Jones, H. R. Spencer, J. H. Targett, and T. W. Eden) . . . . . xl, 213
„ on John Phillips's specimen of monstrosity resulting from amniotic adhesion to skull (John Phillips and C. Hubert Roberts) xl, 131
„ on Arnold W. W. Lea's specimen of tumour expelled from uterus during labour at term (T. W. Eden, J. Bland-Sutton, and A. W. W. Lea) . . . . . xli, 219
„ on Arthur Burton's specimen of deformed fœtus (W. R. Dakin, A. E. Giles, and T. W. Eden) . . . . xli, 340
„ on Amand Routh's specimen of myxo-sarcoma of the uterus (C. H. Roberts, A. Routh, W. S. A. Griffith, H. R. Spencer, and T. W. Eden) . . . . . xli, 370
„ on W. S. A. Griffith's specimen of sarcoma of the uterus (C. H. Roberts, H. R. Spencer, W. S. A. Griffith, A. Routh, and T. W. Eden) . . . . . xli, 371
„ on A. F. Stabb's specimen of myxo-fibroma (? sarcoma) of uterus (W. Duncan, T. W. Eden, G. Drummond Robinson, and A. F. Stabb) . . . . . xlii, 209
„ on H. R. Andrews's specimen of sarcoma of uterus (H. R. Spencer, T. W. Eden, and H. R. Andrews) . . xlii, 265

COMMITTEES, REPORTS OF (*continued*)—
„ on Amand Routh's specimen of fœtus thoracopagus (A. Routh, and C. H. Roberts) . . . . xlii, 31
COMMITTEES, PATHOLOGY, REPORTS OF.
„ on E. O. Croft's specimen of an anomalous case of ectopic pregnancy, probably ovarian (see 'Transactions,' vol. xlii, p. 316) . . . . . xliii, 24
„ on R. Boxall's specimen of cystic fibroid with carcinoma of the left ovary and of the right Fallopian tube (J. H. Targett, C. Lockyer, A. W. W. Lea, and R. Boxall) . . . xliii, 144
„ on A. W. W. Lea's specimen of sarcoma of the uterus and pelvic cellular tissue (J. H. Targett, C. Lockyer, A. W. W. Lea, and R. Boxall) . . . . xliii, 145
„ on P. Horrocks's specimen of deciduoma malignum (P. Horrocks, H. R. Spencer, A. Doran, T. W. Eden, G. B. Smith, J. H. Targett, and W. S. A. Griffith) . . xliii, 288
„ of Teratological Committee on Hugh S. Stannus's specimen of orbital tumour in a fœtus . . . . xliv, 91
„ on A. J. Sturmer's specimen of parasitic cyst of the vulva . xliv, 4
„ on H. Williamson's specimen of pregnancy in rudimentary horn of a uterus bicornis . . . . xliv, 228
„ on W. E. Fothergill's specimen of decidual uterine cast of seven weeks' growth, together with an ovum of about five days' growth . . . . . xliv, 251
„ on Comyns Berkeley's specimen of ovarian abscess ruptured during labour . . . . . xliv, 77
„ on W. F. V. Bonney's specimen of solid ovarian tumour with a cyst attached, with the tube open . . . xliv, 93
„ on J. M. Munro Kerr's specimen of tumour of the uterus . xliv, 130
„ on P. Horrocks's specimen of ectopic gestation . . xliv, 229
„ on W. W. H. Tate's specimen of sarcoma of the uterus (shown May 7th, 1902) . . . . . xliv, 252
„ on A. H. N. Lewers's specimen of uterus removed by abdominal pan-hysterectomy for primary carcinoma of the body xliv, 291
„ on F. J. McCann's specimen of "deciduoma malignum" after the menopause . . . . . xliv, 296
„ on Alban Doran's specimen of retro-peritoneal lipoma (p. 265) xliv, 310
„ on sections from the liver in R. H. Bell's case of puerperal eclampsia (p. 253) . . . . . xliv, 310
„ on J. Bland-Sutton's specimen of carcinoma of Fallopian tube and fibro-myoma of uterus . . . . xliv, 313
„ on J. H. Dauber's specimen of ruptured tubal gestation . xliv, 322
„ on A. E. Giles's specimen of fibroma of the ovary . . xliv, 361
„ on W. C. Swayne's specimen of sarcoma of the body of the uterus, with complete inversion . . . . xliv, 367
„ on G. F. Blacker's specimen of uterus removed by vaginal hysterectomy . . . . . xlv, 85
„ on C. H. Roberts's specimen of adenoma malignum of uterus . . . . . xlv, 91
„ on A. L. Galabin's specimen of hydatidiform degeneration of the placenta and on the fœtus . . . . xlv, 101
„ on E. W. Hey Groves' specimen of fibroid tumour which had developed subsequently to removal of both appendages . xlv, 137
„ on E. W. Hey Groves' specimen of carcinoma of the body of the uterus . . . . . xlv, 139
„ on specimens of chorion-epithelioma . . . xlv, 254
„ on J. B. Hellier's specimen of extra-uterine gestation . xlv, 369

COMMITTEES, PATHOLOGY, REPORTS OF (*continued*)—
„ on A. J. Sturmer's specimen of fibro-myoma of ovary . xlv, 373
„ on W. A. Meredith's specimen of cervical fibroid . . xlvi, 14
„ on W. W. H. Tate's two specimens of diffuse adeno-myoma of the uterus (p. 141) . . . . . xlvi, 178
„ on P. Horrocks's specimen of fibro-myoma of the uterus undergoing sarcomatous degeneration (p. 184) . . . xlvi, 265
„ on H. R. Spencer's specimen of cancer of the body of the uterus simulating fibroid (p. 235) . . . . xlvi, 265
„ on C. E. Purslow's specimen of cystic tumour of uterus (p. 269) . . . . . xlvi, 339
„ on C. E. Purslow's specimen of tubal mole (p. 271) . . xlvi, 340
„ on Frank E. Taylor's specimen of fibroma of the ovary (p. 280) . . . . . xlvi, 341
„ on M. Handfield-Jones's specimen of fibroid tumour of the uterus and cystic disease of the surrounding tissues (p. 307) xlvi, 383
„ on J. H. Dauber's specimen of double symmetrical cystoma of unusual origin and connections (p. 341) . . . xlvi, 384
„ on F. N. Boyd's specimen of fibroma of the ovary (p. 348) . xlvi, 384
„ on A. E. Giles's specimen of extra-uterine gestation . . xlvii, 118
„ on H. Williamson's specimen of grape-like sarcoma of the cervix uteri (p. 119) . . . . . xlvii, 146
„ on A. J. Sturmer's specimen of abdominal gestation (vol. xlvi, p. 385) . . . . . xlvii, 146
„ on R. Hamilton Bell's microscopic sections showing the appearance of thyroid-like structures in ovarian cysts (p. 242) xlvii, 297
„ on J. B. Hellier's specimen (with microscopic section) of chorion-epithelioma . . . . . xlvii, 319
„ on F. N. Boyd's specimen (with microscopic sections) of malignant disease of cervix, in a girl, aged 18 . . xlvii, 320
„ on H. R. Spencer's specimen (with microscopic sections) of carcino-sarcoma uteri . . . . . xlvii, 352
„ on M. A. D. Scharlieb's specimen (with microscopic sections) of endothelioma of the body of the uterus . . xlvii, 406
„ on W. W. H. Tate's specimen of degenerating fibro-myoma and sarcoma of uterus . . . . . xlvii, 407
„ — (adjourned) . . . . . xlvii, 407
„ on W. W. H. Tate's specimen (with microscopic sections) of fibro-myoma of uterus associated with a large cavity containing retained menses communicating with the uterine canal xlvii, 407
„ on W. S. A. Griffith's and H. Williamson's specimen of fibro-myoma of the uterus undergoing sarcomatous change (p. 22) xlviii, 72
„ on John Phillips's specimen (with microscopic section) of chorion-epithelioma (p. 45) . . . . . xlviii, 72
„ on A. L. Galabin's specimen of spindle-celled sarcoma of the ovary (p. 19) . . . . . xlviii, 72
„ on Mrs. Scharlieb's specimen of malignant tumour of the uterus (p. 73) . . . . . xlviii, 127
„ on the doubtfully malignant spot in Dr. Lockyer's specimen of adeno-myoma of uterus (p. 94) . . . xlviii, 128
„ on F. J. McCann's specimen of a hæmorrhagic broad ligament cyst with torsion of the pedicle (p. 179) . . . xlviii, 191
„ on W. W. H. Tate's specimen of degenerating fibro-myoma and sarcoma of uterus, with secondary growths in peritoneum, liver, lungs, and retro-peritoneal glands. (Shown by R. Hamilton Bell.) (*Vide* 'Obstet. Soc. Trans.,' vol. xlvii, 1905, pp. 358, 407) . . . . . xlviii, 225

COMMITTEES, PATHOLOGY, REPORTS OF (*continued*)—
„ on H. Russell Andrews's specimen and microscopic section of endothelioma of the cervix (as described by the exhibitor) (p. 283) . . . . . xlviii, 302
„ on E. E. Young's microscopic section of primary tuberculosis of the cervix uteri (p. 286) . . . . xlviii, 302
„ on C. Hubert Roberts's specimen of a curious case of cancer of the uterus (p. 311) . . . . . xlviii, 330
„ see also *Pathology Committee*, p. 155.

COMMITTEES, TERATOLOGICAL, REPORT OF:
„ on Hugh S. Stannus's specimen of orbital tumour in a fœtus . xliv, 91

CONGESTION, intense, of head and neck in a five months fœtus (W. F. Cleveland) . . . . . xvi, 2

CONSULTATION midwifery in private practice, statistical and practical remarks on (E. Copeman) . . . xvi, 103

CONSTRICTOR for removal of tumours of the uterus (J. Lazarewitch) . . . . . xv, 63

CONTRACTION of the uterus (J. Matthews Duncan) . . xxviii, 91
„ irregular uterine (E. H. Trenholme) . . . xiv, 231
„ of uterus without retraction, with prolonged high temperature of nervous origin (G. E. Herman) . . . xlviii, 204
„ pelvic, from spondylolisthesis (R. Barnes) . . . vi, 78
„ tonic, without completeness of retraction (Matthews Duncan) . . . . . xxix, 369

CONTRACTIONS of the uterus throughout pregnancy, their physiological effects and their value in the diagnosis of pregnancy (J. B. Hicks) . . . . . xiii, 216

CONTRIBUTION to the clinical knowledge of puerperal diseases (J. Braxton Hicks) . . . . . xxxv, 412

CONVULSIONS and albuminuria during abortion in six successive pregnancies (W. H. Broadbent) . . . . i, 108
„ epileptiform in the third week of the puerperal state (R. U. West) . . . . . iii, 35
„ hereditary, confined to the males of a family, occurring during infancy and at about the eighth month of intra-uterine life (J. B. Curgenven) . . . . . ix, 116
„ puerperal, complicated with mania, apparent recovery, sudden decease (A. Hall) . . . . . iv, 222
„ puerperal, in the ninth month of pregnancy; delivery with parallel forceps, child stillborn; recovery (J. Lazarewitch) . xv, 59
„ and pelvic tumour, case of labour complicated by (H. M. Madge) . . . . . xvii, 20
„ cases of, in the Montreal University Lying-in Hospital (D. C. McCallum) . . . . . xx, 43
„ see *Eclampsia*.

COOKE (LOUIS), uterine and extra-uterine (fimbrial) pregnancy, progressing simultaneously to the full period of gestation; death; *post-mortem* examination . . . v, 143

COPEMAN (E.), cases exemplifying some of the difficulties encountered in determining the existence of pregnancy, and the value of auscultation as a means of diagnosis . . x, 62
„ imperforate hymen with retained menstrual fluid . . x, 246
„ tumours of the pelvis obstructing delivery . . xii, 313
„ cases in practice . . . . . xiii, 232
„ statistical and practical remarks on consultation midwifery in private practice . . . . . xvi, 103

CORD, see *Funis, Umbilical.*

Cordes (Aug.), cases of prolapsus . . . xvii, 63
„ letter read in the discussion on puerperal fever . . xvii, 217

CORNU, left uterine, sloughing fibroid of; abnormal relations (A. Doran and C. Lockyer) . . . . xliii, 272

CORPUS FIBROSUM, large calcified, in ovary (J. Bland-Sutton) . xl, 223

CORPUS LUTEUM, on the (W. A. Popow) . . . xxiv, 100
„ abscess in (J. D. Malcolm) . . . . xlvii, 8
„ cystic (R. Alcock) . . . . . xliii, 208
„ compound lutein cystomata found in association with vesicular mole and chorio-epithelioma (C. Lockyer) . . xlvii, 157
„ ovarian tumour containing (A. L. Galabin) . xxxviii, 101

CORROSIVE SUBLIMATE, pellets of (F. H. Champneys). . xxviii, 66
„ irrigation, mercurialism in lying-in women undergoing (W. R. Dakin) . . . . . xxviii, 281

Cory (F. C.), ovum forceps. . . . . viii, 5
„ abscess of female urethra . . . . xi, 65
„ successful case of tracheotomy in croup . . . xi, 78

Cory (Robert), head said to have been ruptured by the use of the forceps . . . . . xx, 81
„ microscopical sections of a uterus, from a subject who died the day menstruation commenced . . . . xx, 104
„ on membranous dysmenorrhœa . . . . xx, 113
„ uterus from a case of severe uterine hæmorrhage, and injection of perchloride of iron . . . . . xxi, 51

COTTON-LEAF TEA as a galactagogue in Jamaica (Izett W. Anderson). . . . . xxii, 31

COTTON-WOOL, medicated (R. Greenhalgh) . . . viii, 217

COUCH-TABLE (Robert Wise) . . . xxxvii, 79

COUCHAID, to assist labour and economise force during parturition (A. W. Edis). . . . . xvii, 48

COUVEUSE, Auvard's, or nest (Matthews Duncan) . . xxvi, 25

COW, acardiac from (J. Bland-Sutton) . . . xli, 97

Coward (J. W. S.), inversio uteri . . . . xii, 344

Cox (Richard), case of rupture of the uterus. . . . xxviii, 225

Craddock (S.), occluded vagina after delivery, with subsequent retention of menses . . . . . xiii, 101

Craig (James), see *Thornton (J. Knowsley).*

CRANIOTOMY (R. Druitt) . . . . . i, 81
„ abolition of, from obstetric practice, in all cases where the fœtus is living and viable (W. T. Smith) . . . i, 21
„ cephalotripsy, Cæsarean section in case of extreme distortion of the pelvis (R. Greenhalgh) . . . . vii, 220
„ in a case of exhaustion and convulsions from protracted labour (J. T. Mitchell) . . . . . xii, 368
„ in which delivery was readily effected by turning after perforation, when instrumental extraction was found impossible (F. W. Mackenzie) . . . . . i, 267
„ methods of (A. Donald). . . . . xxxi, 28
„ spontaneous version after, in a case of obstructed labour (S. D. Hine) . . . . . xxvii, 293

CRANIOTOMY (*continued*)—
„ six cases of, with remarks on the relative position of, and Cæsarean section (A. H. N. Lewers) . . . xxxiv, 161
„ forceps (R. Barnes) . . . . . v, 277
„ — (J. H. Davis) . . . . . vi, 123
„ — see also *Forceps.*

CRANIUM, fracture of, in a new-born child (S. W. Poole) . xx, 105

CRANNY (JOHN J.), remarks in the discussion on the use of forceps xxi, 194

CRAWFORD (JAMES), ovarian cyst; uterine myoma and polypus; death of patient from pneumonia . . . xxxiii, 74
„ fibroma of the ovary . . . . xxxvi, 190

CRIPPS (HARRISON), abdominal hysterectomy with intra-peritoneal treatment of the stump, with notes of eight cases . xxxviii, 41, 107
„ and HERBERT WILLIAMSON, two cases involving the question of the site of impregnation . . . . xlvi, 88

CROFT (E. OCTAVIUS), anomalous case of ectopic pregnancy, probably ovarian . . . . . xlii, 316
„ tuberculosis of cervix . . . . . xliv, 142

CROMBIE (J. M.), self-administration of anæsthetics, apparatus for xviii, 64

CRONK (H. G.), see *Godson, Clement.*

CROUP, membranous (R. U. West) . . . . . i, 53
„ successful case of tracheotomy in (F. C. Cory) . . xi, 78

CULLINGWORTH (C. J.), pelvic cellulitis noted, with special reference to the temperature . . . . . xii, 370
„ fibroma of both ovaries . . . . . xxi, 276
„ — *report* on ditto by committee (J. Knowsley Thornton and Alban Doran) . . . . . xxi, 314
„ case of Cæsarean section . . . . . xxix, 252
„ thick-walled cyst connected with, and simulating enlargement of, the uterus . . . . xxx, 165, 198, 202
„ — *report* on ditto by committee (C. J. Cullingworth, Alban Doran, and P. Horrocks) . . . . xxx, 199
„ localised sloughing of fundus uteri in a case of acute septicæmia following abdominal section . . . xxx, 406
„ extra-uterine fœtation; abdominal section eight months after death of fœtus; sac formed by left Fallopian tube and left broad ligament; recovery . . . . xxx, 480
„ hæmatosalpinx . . . . . xxxi, 226
„ — and intra-peritoneal hæmatocele from rupture of a varicose vein in the inner surface of the right Fallopian tube . xxxi, 257
„ uterus, ovaries, and tubes from a case of Cæsarean section . xxxi, 308
„ case of vesico-utero-vaginal fistula . . . xxxi, 320
„ for *A. H. Robinson*, uterus showing placenta prævia . . xxxii, 67
„ — *report* on ditto by committee (W. S. Playfair, F. H. Champneys, and C. J. Cullingworth) . . . xxxii, 107
„ uterus removed by Porro's operation . . . xxxii, 135
„ fœtus and placenta from a case of extra-uterine gestation . xxxii, 135
„ cancerous uteri removed by vaginal hysterectomy . . xxxii, 136
„ four cases of vaginal hysterectomy . . . xxxii, 141
„ carcinoma of the ovary . . . . . xxxii, 199
„ fœtus, placenta, membranes, and Fallopian tube from a case of ruptured tubal gestation, complicated by a large hæmatosalpinx on the opposite side . . . . xxxii, 273
„ hæmorrhagic carcinoma of the ovary . . . xxxiii, 445

CULLINGWORTH (C. J.) (*continued*)—
„ suppurating ovarian cyst . . . . xxxiii, 446
„ a series of seven cases of pyosalpinx . . xxxiii, 447
„ case of Cæsarean section for contracted pelvis . . xxxiv, 89
„ ruptured tubal gestation . . . . xxxiv, 134
„ case of squamous-celled carcinoma of the cervix uteri, in which the disease had extended in an upward and not in a downward direction . . . . . xxxiv, 136
„ unruptured tubal gestation, with apoplexy of the ovum . xxxiv, 155
„ tubal gestation with apoplectic ovum, sac unruptured . xxxiv, 182
„ two cases of pyosalpinx . . . . xxxiv, 219
„ myoma of the cervix uteri . . . . xxxiv, 223
„ large pyosalpinx simulating tubo-ovarian abscess . . xxxiv, 437
„ the value of abdominal section in certain cases of pelvic peritonitis, based on a personal experience of fifty cases . xxxiv, 254
„ — *adjourned debate* . . . . . xxxiv, 442
„ note supplementary to a paper read before the Society on April 2nd, 1890, on vaginal hysterectomy, giving the subsequent history of the cases . . . . xxxv, 25
„ large œdematous fibroid of the uterus removed by abdominal hysterectomy . . . . . xxxv, 38
„ case of extra-uterine gestation, in which the fœtal movements ceased at the end of the eighth month and abdominal section was performed four weeks later . . . . xxxv, 155
„ large gangrenous interstitial myoma of the uterus . . xxxvi, 268
„ three cases of pelvic inflammation attended with abscess of the ovary, with clinical remarks . . . xxxvi, 277
„ primary carcinoma of the Fallopian tube . . . xxxvi, 307
„ pyosalpinx simulating a tubo-ovarian abscess . xxxvii, 2
„ an indisputable case of complete tubal abortion . xxxvii, 139
„ diffuse (non-capsulated) myoma of uterus . . xxxvii, 143
„ pedunculated fibro-myoma of the broad ligament, with twisted pedicle . . . . . xxxvii, 222
„ necrotic change in a small uterine myoma occurring in a young subject . . . . . xxxvii, 284
„ supposed case of tubo-ovarian cyst . xxxvii, 295; xxxviii, 1
„ multiple fibro-myomata of the uterus . . xxxviii, 6
„ large fibro-cystic myoma growing from the cervix uteri xxxviii, 8
„ pyosalpinx, with multiple abscesses of the ovary . . xxxix, 47
„ inaugural address as President . . . . xxxix, 91
„ fibroma of the ovary . . . . . xxxix, 279
„ gangrene of an interstitial fibro-myoma of the uterus . xxxix, 281
„ fibro-myomata of the uterus causing intestinal obstruction and death two years after the menopause . . xxxix, 282
„ early ectopic gestation (? tubo-uterine) complicated by fibro-myomata of the uterus. . . . . xxxix, 284
„ malignant growth involving the right uterine appendages . xl, 6
„ annual address as president . . . . xl, 39
„ bibliographical appendix to Annual Address:
Part I.—List of Sir Thomas Spencer Wells' published writings, arranged chronologically . . . . xl, 91
Part II.—List of Dr. J. Braxton Hicks's published writings, arranged chronologically . . . . xl, 102
„ early ectopic gestation (? tubo-uterine) complicated by fibro-myomata of the uterus . . . . xl, 285
„ œdematous subperitoneal fibro-myomata of uterus in right broad ligament removed by abdominal hysterectomy . xl, 302

CULLINGWORTH (C. J.) (*continued*)—
„ genuine case of tubo-ovarian abscess . . . xli, 39
„ annual address as President . . . . xli, 50
„ and J. S. FAIRBAIRN, large inflamed cyst (? ovarian) communicating with an inflamed Fallopian tube . . . xlii, 96
„ incarcerated fibro-myoma of uterus in an unusually young subject . . . . . xlii, 132
„ and H. H. CLUTTON, notes on a case of hydatids of, or connected with, both ovaries, right broad ligament, liver, omentum, mesentery, and other parts . . . xlvi, 254
„ carcinoma of the Fallopian tubes . . . xlvii, 263
„ Pozzi medal . . . . . xlviii, 271

CULTURES, method of taking intra-uterine bacteriological (A. W. Sikes) . . . . . xlv, 381

CURATULO (J. EMILIO), on the influence of the removal of the ovaries on metabolism in connection with osteomalacia xxxviii, 17

CURETTE, for the removal of uterine fungoid granulations (J. M. Sims) . . . . . vii, 72

CURETTING and steaming of uterus followed by vaginal hysterectomy fourteen days after (G. F. Blacker) . . xlv, 80

CURVENGEN (J. B.), hereditary convulsions confined to the males of a family, occurring during infancy and at about the eighth month of intra-uterine life . . . . ix, 116
„ bromide of potassium in puerperal mania . . . ix, 155
„ hereditary twin-bearing family . . . . xi, 106
„ knotted cord . . . . . xiii, 187

CURTIS (H. J.), "grape-like" sarcoma of the cervix uteri, fungating into and infiltrating the walls of the vagina, in a child, aged 12 months; extirpation of uterus and vagina . xlv, 320

CUTLER (LENNARD), kidneys from a case of eclampsia . . xxxvi, 176
„ and PROBYN-WILLIAMS (R. J.), some observations on the temperature, pulse, and respiration during labour and the lying-in . . . . . xxxvii, 19, 152

CYANURIA, case of (John Phillips) . . . . xxxi, 256

CYCLOPS, case of (W. J. McC. Ettles) . . . xxxvi, 149

CYST, abdominal, in a newly-born female child (Gomer Davies) . xix, 5
„ large, abdominal (A. W. Williams) . . . viii, 218
„ of the broad ligament (J. Knowsley Thornton) . . xxvi, 55
„ — (E. Malins) . . . . xxvi, 228
„ — with septa (W. S. A. Griffith) . . . xxvii, 251
„ — (W. Duncan) . . . . . xxxiii, 157
„ — (C. E. Purslow) . . . . xli, 169
„ — fibroid associated with an ovarian (A. Doran) . . xliii, 260
„ — with torsion of the pedicle and extensive hæmorrhage into the broad ligament (F. J. McCann) . . . xlviii, 179
„ chylous, of the mesentery (Ad. Rasch) . . . xxxi, 311
„ congenital cœlomic (C. Lockyer) . . . . xliii, 7
„ dermoid (W. T. Smith) . . . . . vii, 45
„ — (R. Barnes) . . . . . xv, 35
„ — (A. W. Edis) . . . . . xxv, 66
„ — (A. L. Galabin) . . . . . xxxiv, 441
„ — two from the same patient (C. H. Carter) . . xxxii, 6

CYST, dermoid (*continued*)—
„ — (T. C. Hayes) . . . . . xxxiii, 389
„ — containing a large number of epithelial balls (W. F. Victor Bonney) . . . . . xliv, 354
„ — containing hair and well-developed teeth and osseous substance (R. Barnes) . . . . . xvii, 215
„ — containing pill-like bodies (A. C. Butler-Smythe) xxxvii, 15
„ — suppurating (Wm. Duncan) . . . . xxxii, 346
„ — of the pelvis, the suppuration and discharge into mucous cavites of (G. E. Herman) . . . . xxvii, 254
„ — with dentigerous plate (Leith Napier) . . . xxxv, 429
„ — of ovary; *post-mortem* (W. B. Woodman) . . vii, 158
„ — (J. Shaw-Mackenzie) . . . . xxxiii, 461
„ — (A. C. Butler-Smythe) . . . . xxxiii, 463
„ — ovarian (J. Bland-Sutton) . . . . xxxiv, 5
„ — ovary containing three (S. W. Wheaton) . . xxxiii, 28
„ — — with infiltration of broad ligament with fat (J. Bland-Sutton) . . . . . xxxiv, 7
„ — of ovary, with minute pedicle produced by torsion of mesovarium only (A. L. Galabin) . . . . xlvii, 331
„ — of right ovary; twisted pedicle (W. Duncan) . . xxxvi, 267
„ — ovarian, impacted in the pelvis, which was removed by abdominal section during the ninth month of pregnancy (Thomas H. Morse) . . . . xxxviii, 221
„ — of the ovary removed by abdominal section five years after causing obstruction to labour (W. W. H. Tate) . . xlvi, 344
„ — incarcerated ovarian, removed during pregnancy *per vaginam* (Amand Routh) . . . . xl, 217
„ — ovarian, the size of a child's head in a case of ruptured uterus (A. H. N. Lewers) . . . . xlii, 95
„ — of ovary, obstructing labour; displacement of the tumour from the true pelvis and extraction of the child with forceps; removal of tumour five weeks later; recovery (J. M. Munro Kerr) . . . . . xliii, 148
„ — — removed by posterior colpotomy (Amand Routh) . xliv, 34
„ — in Fallopian tube (C. J. Ritchie) . . . vii, 250
„ — suppurating (A. D. Leith Napier) . . . xxxiii, 465
„ in the decidua vera, aborted ovum showing (John Phillips) xxxi, 52, 161
„ dilated tubes and cystic ovaries (early stage of tubo-ovarian) (W. Duncan) . . . . xxxvii, 150
„ of the Fallopian tube (A. Meadows) . . . viii, 139
„ in connection with the right Fallopian tube, arising probably from an accessory Fallopian tube (R. Hamilton Bell) . xlvi, 21
„ from case of extra-uterine fœtation (J. Scott) . . xv, 124
„ hydatid, of the mesentery (E. Malins) . . . xxix, 245
„ hydatidiform, growing in the vulva (A. J. Sturmer) . xliii, 148
„ from the labia minora (A. Wiltshire) . . . xxiii, 206
„ of the larynx removed *post mortem* from an infant (A. W. Edis) . . . . . xviii, 2
„ lutein, in both ovaries, in chorion-epithelioma of the uterus (G. F. Blacker) . . . . . xlix, 104
„ multilocular, of left ovary removed six years after removal of right ovary (T. Spencer Wells) . . . . x, 19
„ — of oöphoron (Cuthbert Lockyer) . . . xlii, 37
„ myoma of uterus, weighing over 15 lb. (Alban Doran) xxxviii, 164
„ of the great omentum (Alban Doran) . . . xxiii, 164
„ ovarian (T. W. Eden) . . . . . xxxv, 408

CYST, ovarian (*continued*)—
„ — appearance of thyroid-like structures in (R. Hamilton Bell) . . . . . xlvii, 242
„ — associated with a case of fibroid of broad ligament, after-history (Alban Doran) . . . . . xlix, 94
„ — presence of sarcomatous tissue in the walls of (F. E. Taylor) . . . . . xlvii, 411
„ — chronic axial rotation of an, giving rise to extreme twisting of the elongated uterus (Thomas Wilson) . xxxix, 167
„ — ruptured, with twisted pedicle (V. Bonney) . . xlvii, 190
„ — two, removed by ovariotomy (T. Spencer Wells) . . iii, 285
„ — bilateral, in a patient with chorio-epithelioma following hydatidiform mole (J. D. Malcolm, R. H. Bell, and C. Lockyer) . . . . . xlv, 483
„ small ovarian, and hydrosalpinx removed by anterior colpotomy (Amand Routh) . . . xxxviii, 185
„ — with cast from the uterus having all the characters of the decidual membrane found in connection with ectopic gestation (W. R. Dakin) . . . . xxxviii, 385
„ — suppuration in, caused by the *Bacillus typhosus* (F. E. Taylor) . . . . . xlix, 256
„ suppurating ovarian, complicating tubal pregnancy (molar) (John Phillips) . . . . . xli, 384
„ — — obstructing labour, removed by abdominal section eighteen months later (W. W. H. Tate) . . . xlii, 164
„ attached to solid tumour of left ovary and communicating with the left Fallopian tube (V. Bonney) . . xliv, 92
„ ovarian, which had made its way between the layers of the meso-sigmoid, both broad ligaments, and the meso-cæcum (W. H. B. Brook) . . . . . xlv, 415
„ (? ovarian) communicating with an inflamed Fallopian tube (C. J. Cullingworth and J. S. Fairbairn) . . . xlii, 96
„ unilocular, involving both ovaries and with both Fallopian tubes attached (J. Knowsley Thornton) . . . xxi, 119
„ unilocular ovarian, containing solid masses undergoing necrotic change (J. S. Fairbairn) . . . xliv, 126
„ — pathology of certain so-called (G. G. Bantock) . . xv, 105
„ tubo-ovarian (W. S. A. Griffith) . . xxix, 273, 302; xxx, 3
„ — (J. Bland-Sutton) . . . . . xxxi, 338
„ — (W. C. Grigg) . . . . . xxxiii, 75
„ — (M. Handfield-Jones) . . . . xxxiv, 85
„ — large double (William Duncan) . . xxxviii, 37
„ — double pyosalpinx with (W. C. Grigg) . . . xxxiii, 75
„ — supposed case of (C. J. Cullingworth) . . xxxvii, 295
„ — supposed case of (C. J. Cullingworth) . . xxxviii, 1, 4
„ papilliferous, of the ovary (John Williams) . xxix, 247, 513
„ papillomatous ovarian (J. Knowsley Thornton) . . xxvi, 4
„ — removed during the fourth month of pregnancy (W. A. Meredith) . . . . . xxxii, 374
„ — of an accessory ovary (A. L. Galabin) . . . xliii, 267
„ (?) parasitic, of vulva (A. J. Sturmer) . . . xliv, 2
„ parovarian (Lawson Tait) . . . . xxv, 112
„ — with twisted pedicle (C. Berkeley) . . . xlvi, 242
„ — removed *per vaginam* (Amand Routh) . . xxxvii, 8
„ — with acute axial rotation (A. W. W. Lea) . . xxxix, 8
„ on cases of associated parovarian and vaginal, formed from a distended Gärtner's duct (Amand Routh) . . xxxvi, 152

CYST (*continued*)—
„ of placenta (R. Boxall) . . . . . xxvi, 59
„ — on the fœtal surface of (John Williams) . . xxv, 69
„ polypiform, growing from anterior wall of vagina, distended by a viscid olive-coloured fluid, and projecting at os externum vaginæ. Incision, iodine injections. Subsequent removal by wire rope écraseur (J. H. Davis) . . . ix, 32
„ retro-peritoneal, associated with solid malignant (?) intra-cystic growth (A. L. Galabin) . . . . . xxviii, 179
„ thick-walled, connected with, and simulating enlargement of, the uterus (C. J. Cullingworth) . . . xxx, 165, 198, 202
„ uterine (W. S. A. Griffith) . . . . xxvi, 229
„ of the vagina (M. Handfield-Jones) . . . xxxi, 129
„ — their ætiology, pathology, and treatment (Henry T. Rutherfoord) . . . . . xxxiii, 354
„ removed from the vulva (A. L. Galabin) . . . xxvi, 56

CYSTIC adenoma of the cervix (W. S. A. Griffith) . . xxx, 4
„ disease of the chorion (Aust Lawrence) . . . xxxii, 64
„ — hydatiform degeneration (John Phillips) . . xxxii, 65
„ — of the fœtal kidney (H. Gervis) . . . xx, 84
„ — of the ovary, new method of examination of the tumour in cases of suspected (W. G. Hewitt) . . . i, 55
„ — of ovary in its earliest stage (R. Barnes) . . xxvi, 157
„ — of both ovaries (C. H. Carter) . . . xxv, 109
„ ovary, the seat of hæmorrhage (M. Handfield-Jones) . xxxiii, 27
„ degeneration, see *Degeneration.*
„ growths and tubal dilatation, uterine appendages showing (T. C. Hayes). . . . . xxxiii, 4

CYSTOCELE, vaginal, new operation for (E. W. Hey Groves) . xlvii, 65

CYSTOMA, compound lutein, found in association with vesicular mole and chorion-epithelioma (C. Lockyer) . . xlvii, 157
„ double symmetrical, of unusual origin and connections (J. H. Dauber) . . . . . xlvi, 341
„ ovarian, origin of, from Graafian follicles (A. L. Galabin) . xxi, 288
„ ovarian, complicating pregnancy; infection of the cyst five days after labour; operation on the forty-third day; extensive peritoneal and bowel adhesions; recovery (H. Macnaughton-Jones) . . . . . xlii, 140
„ papillomatous ovarian, removed after double ovariotomy fifteen years previously (J. D. Malcolm) . . . xxxv, 36
„ double tubo-ovarian (W. Duncan) . . xxxvii, 149
„ tumour closely simulating a papillomatous ovarian, attached to the front of the bladder and quite separate from both ovaries (J. D. Malcolm) . . . . xli, 226
„ perimetric (J. H. Targett) . . . . xli, 343

Dakin (W. R.), on mercurialism in lying-in women undergoing sublimate irrigation . . . . . xxviii, 281
„ dissection of a fœtus, the subject of retroflexion, ectopia viscerum, etc.; with remarks on the frequent association of these abnormalities, and its cause . xxxi, 308; xxxii, 200
„ sarcomatous uterus removed by vaginal hysterectomy . xxxii, 139
„ fœtus, the subject of atresia ani vesicalis . . . xxxii, 368
„ uterus and appendages affected with tubercle . . xxxiii, 3
„ tetany in pregnancy . . . . . xxxiii, 163
„ sarcoma of ovary . . . . . xxxvi, 313

DAKIN (W. R.) (*continued*)—
„ concealed accidental hemorrhage; fœtus, placenta, and membranes delivered entire . . . . xxxvi, 315
„ cast from the uterus having all the characters of the decidual membrane found in connection with ectopic gestation together with a small ovarian cyst from the same case with microscopic sections of each . . . xxxviii, 385
„ uterus ruptured during unobstructed labour (with a microscopic section) . . . . . xl, 29
„ uterine fibroid clinically resembling sarcoma . . xl, 32
„ fibro-myoma spontaneously enucleated during labour . xli, 105
„ inaugural address as President . . . . xlvii, 124
„ annual address as President . . . . xlviii, 51
DALY (F. H.), advantages of the early use of the long forceps . xii, 3
„ uterus occupied by a tumour the size of a large orange, with attached ovarian cyst . . . . . xvi, 122
„ *report* on ditto by committee (J. B. Potter and T. C. Hayes) . xvi, 202
„ large fibroid tumour in the uterus. . . . xviii, 65
„ case of intra-uterine tumour . . . . xviii, 222
„ remarks in the discussion on the use of forceps . . xxi, 227
„ extra-uterine gestation . . . . xxiv, 155
„ tumour expelled from the uterus after delivery . . xxviii, 170
„ and C. H. CARTER, foreign body in the vagina, removal after four years, and after-results . . . . xxii, 34
DAUBER (J. H.), carcinoma of body and multiple fibromata of uterus removed by abdominal pan-hysterectomy . xxxix, 321
„ ruptured tubal gestation . . . . xliv, 321
„ double symmetrical cystoma of unusual origin and connections xlvi, 341
„ fibro-myomatous uterus with a calcified fibroid lying free in its cavity . . . . . xlix, 139
DAVIES (GOMER), abdominal cyst in a newly-born female child . xix, 5
DAVIS (J. HALL), ovarian gestation . . . . i. 241
„ polypus of the uterus . . . . i, 247
„ intra-uterine fibro-plastic tumour, extensively adherent, recovered by enucleation . . . . ii, 17
„ double battledore placenta with a single umbilical cord, connected with one child . . . . ii, 273
„ hydatid mole expelled from the uterus immediately after a living fœtus and its placenta, at about six months' gestation; the hydatid growth being the degenerated ovum of a twin conception . . . . . iii, 177
„ complete occlusion of the os uteri, with retention of menses, after difficult labour . . . . iv, 91
„ craniotomy forceps . . . . vi, 123
„ fibrous tumour of the uterus attended by early pregnancy; retroversion of the uterus and retention of urine; death and decay of the fœtus and subsequently of the mother from pyæmia . . . . . viii, 11
„ inaugural address as President . . . . ix, 30
„ polypiform cyst growing from the anterior wall of vagina, distended by a viscid olive-coloured fluid; incision; iodine injections; removal by wire-rope écraseur . . ix, 32
„ large fibroid polypus pediculated at its base to posterior margin of os uteri, its neck protruded at vulva, removed by the single wire écraseur . . . . ix, 152
„ annual address as President . . . . x, 14

DAVIS (J. HALL) (*continued*)—
„ membranes of a twin ovum of supposed ten weeks' gestation x, 57
„ intra-uterine fibroid tumour; a part removed by the single écraseur, the remainder strongly adherent, cut into in different directions, and thrown off by disintegration on the fourth day . . . . . x, 227
„ annual address as President . . . . xi, 15
„ puerperal convulsions, illustrated by cases . . . xi, 268
„ extra-uterine pregnancy; the left ovary and the fimbriæ of left Fallopian tube formed the cyst which had ruptured, discharging fœtus of eight months' growth into abdominal cavity; survival till sixth day; necropsy . . xii, 331
„ inversion of the uterus after childbirth in a primipara; amputation by écraseur at expiration of ten months on account of hæmorrhage with great exhaustion . . xiv, 104
„ new vaginal speculum . . . . . xvi, 98

DAVOREN (J.), see *Duncan, William.*

DAWSON (E. RUMLEY), rupture of an early (fifteenth day) tubal gestation complicated by fibro-myomata of the uterus . xl, 155
„ the essential factor in the causation of sex; a new theory of sex . . . . . xlii, 356

DAY (E. E.), extra-uterine fœtation, followed by intra-uterine pregnancy; induction of premature labour . . vi, 3
„ adhesions between uterus and rectum, dragging down the fundus uteri . . . . . vi, 10

DAY (W. HANKES), case of fibroid tumour complicating delivery treated by enucleation . . . . . xxvii, 158

DEATH, causes of, in ewes, during and after parturition (J. Hutchinson) . . . . . xvii, 88

DECIDUA, apoplexy of (A. Routh) . . . . xxxii, 194
„ aborted ovum showing cysts in (John Phillips) . xxxi, 52, 161
„ or fleshy substance discharged from unimpregnated half of a double uterus (W. F. Cleveland) xxiii, 132, 181; xxiv, 297; xxvi, 117, 331
„ hypertrophy of (G. Ernest Herman) . . . xxxiii, 456
„ menstrual, passed on the first day of menstruation (A. L. Galabin) . . . . . xxi, 312
„ pieces of, illustrating the extent to which the ovum may be occasionally interfered with without abortion occurring (W. S. Playfair) . . . . . xxi, 290
„ structure of the (G. Hoggan) . . . . xvi, 228
„ vera and reflexa from a very early abortion (G. E. Herman) xxxii, 272
„ reflexa and decidua vera from a patient who died of heart disease; frozen sections of a uterus at the tenth week of pregnancy, showing hæmorrhages into the (G. F. Blacker) . xlii, 235

DECIDUOMA malignum, occurring in England (J. Rutherford Morison) . . . . . xxxviii, 130
„ — (Herbert R. Spencer) . . . xxxviii, 135
„ — a criticism (T. W. Eden) . . . xxxviii, 149
„ — addendum to paper on (T. W. Eden) . . xxxviii, 162
„ — adjourned discussion on . . . xxxviii, 171
„ — *report* of Committee on specimens of . . xxxviii, 183
„ — primary sarcoma of the body of the uterus, in a patient, aged 24, treated by vaginal hysterectomy (A. H. N. Lewers). xxxix, 246

DECIDUOMA malignum (*continued*)—
„ — (J. H. Targett) . . . . . xl, 113
„ —primary sarcoma of the body of the uterus (A. H. N. Lewers) . . . . . xl, 225
„ — (P. Horrocks) . . . . . xliii, 109, 283
„ — after the menopause (F. J. McCann) . . . xliv, 294
„ — (T. A. Helme) . . . . . xlv, 243
„ — (A. H. N. Lewers) . . . . . xlv, 245
„ — (F. J. McCann) . . . . . xlv, 247, 248
„ — (H. R. Spencer) . . . . . xlv, 250
„ — (A. J. Sturmer) . . . . . xlv, 251
„ — (malignant hydatid mole) (J. B. Hellier) . . xlv, 242
„ — *without* syncytium; secondary deposits in vagina, lymphatic glands (iliac and lumbar), and lungs, after hydatidiform degeneration of the chorion (P. Horrocks) . . xlv, 243
„ — of uterus (J. R. Morison) . . . . xlv, 249
„ — with secondary deposit in vagina; lungs showing secondary deposits (F. J. McCann) . . . . xlv, 248
„ — secondary growth from vagina of (J. R. Morison) . xlv, 249
„ — (so-called) and the occurrence of chorion-epitheliomatous and hydatidiform mole-like structures in tumours of the testis (J. H. Teacher) . . . . xlv, 256

DEFORMITY, congenital, in two children, and the natural impressions to which the deformities were attributed (Ashburton Thompson) . . . . . xix, 94
„ curious congenital (C. H. Roberts) . . . xxxvi, 341
„ case of fœtal (A. W. Addinsell) . . . xxxvii, 204
„ in an early human embryo with retroflexion, showing absence of spinal medulla and imperfection of the vertebral column (C. B. Lockwood) . . . . . xxix, 234
„ influence of abnormal parturition, difficult labour, premature birth, and asphyxia neonatorum on the mental and physical condition of the child, especially in relation to (W. J. Little) iii, 293
„ rare, in the anatomy of an infant (C. Singer) . . xlvii, 250
„ of lower limbs and stumps of arms in a hydrocephalic child (Matthews Duncan) . . . . . xxii, 237
„ — dissection of ditto (W. L. Heath) . . . xxiii, 195
„ of hand and foot in a child (John Phillips) . . xxviii, 89
„ of arms and hands (J. Shortt) . . . . vi, 205
„ pelvis deformed by mollities ossium (W. S. A. Griffith) . xxvi, 230
„ see *Malformations*.

DEGENERATION, colloid, uterine fibroid undergoing (T. G. Stevens) . . . . . xxxvi, 225
„ cystic, in large fibroid tumour of uterus (P. Horrocks) . xl, 227
„ marked cystic, in fibro-myoma of uterus removed from a patient, aged 63, from whom both ovaries had been removed eleven years before (W. W. H. Tate) . . . xliii, 26
„ cystic of the cervix uteri (H. Gervis) . . . xxvi, 144
„ — of chorion, in a case of missed abortion (G. E. Herman) . xxii, 44
„ — with hyperplasia of chorion stems (W. S. A. Griffith) . xxx, 82
„ — of subperitoneal fibroid of the uterus (C. H. Carter) . xxv, 108
„ — of soft myoma of the uterus (J. H. Aveling) . . xxvi, 270
„ — umbilical cord in a state of (Clement Godson) . . xxiii, 180
„ fatty (J. Brunton) . . . . . ix, 85
„ fibroid, of uterus, with sub-peritoneal and interstitial fibrous tumours, in a state of disintegration (A. W. Edis) . . . xi, 34

DEGENERATION, fibroid (*continued*)—
„ — and angioma of the ovaries, atrophy with collapse (cirrhosis) (J. Braithwaite) . . . . xxxvi, 328
„ hydatid, of the ovum (F. Webb) . . . . ix, 85
„ hydatidiform, of the ovum (W. G. Hewitt) . . ii, 112
„ — — (C. H. F. Routh) . . . . . ii, 242
„ — — (W. A. Russell) . . . . . vii, 228
„ — of the chorion, associated with albuminuria (W. B. Woodman) . . . . . vii, 113, 117
„ — — (J. Phillips) . . . . . xxxii, 65
„ — — (H. Williamson) . . . . . xli, 303
„ — — preceding deciduoma malignum *without* syncytium; secondary deposits in vagina, lymphatic glands (iliac and lumbar), and lungs (P. Horrocks) . . . xlv, 243
„ myxomatous, of uterine fibroids (Clement Godson) . . xxv, 140
„ — and cystic, in a pedunculated sub-serous fibro-myoma of uterus (A. F. Stabb) . . . . . xlii, 133
„ red, uterine myoma undergoing (W. F. V. Bonney) . . xlv, 464
„ sarcomatous, with fibro-myoma of the uterus (P. Horrocks) . xl, 178
„ — in fibro-myoma of uterus (P. Horrocks) . . xlvi, 184
„ partial vesicular, of the placenta (A. L. Galabin) . . xlv, 100
„ villous, of the endometrium (D. C. MacCallum) . . xxiii, 37
„ see *Calcareous degeneration.*

DELBASTAILLE'S speculum *à glissières* (Alban Doran) . . xxxii, 307

DELIVERY, awkward, in singular case of unsuspected pregnancy (J. Shortt) . . . . . iv, 202
„ by forceps, in a face presentation: subsequent sloughing and separation of the mucous lining of the bladder and expulsion of the same (W. Martyn) . . . . v, 186
„ by the natural powers, or spontaneous evolution (R. Hodges) iv, 140
„ by the vagina in extra-uterine gestation (G. E. Herman) . xxix, 429
„ large fibrous tumour impeding (H. M. Madge) . . iv, 129
„ polypus uteri complicating labour, removed by ligature two days after (H. L. Freeman) . . . . v, 42
„ state of the internal surface of the uterus after (J. Matthews Duncan) . . . . . iv, 107
„ sudden and unconscious (J. Shortt) . . . iv, 210
„ see also *Parturition.*

DENTIGEROUS bony plates from a dermoid ovarian tumour (Alban Doran) . . . . . xxxi, 86
„ plate with large dermoid cyst (Leith Napier) . . xxxv, 429

DEPRESSION of child's head by forceps (Clement Godson) . xxiii, 161
„ of frontal bone, the result of pressure from the sacral promontory (Clement Godson) . . . . xxiii, 32

DERMOID CYST, see *Cyst.*

DERMOID TUMOUR, see *Tumour, Ovarian.*

DES VŒUX (H. A.), double ovarian apoplexy from a case of acute peritonitis . . . . . xxxiv, 214
„ placenta with hæmorrhage . . . xxxvii, 9

DEVELOPMENT, arrest of, in genito-urinary tract in a female fœtus (Alban Doran) . . . . . xxiii, 107
„ arrested, of one twin, double placenta (A. W. Edis) . xxv, 213
„ remarkable, of an infant (Dr. Cameron) . . . xviii, 115
„ and normal structure of the human placenta (T. W. Eden) xxxvii, 205, 227

Dewar (John), see *Godson, Clement.*

DIABETES insipidus in pregnancy and labour (J. Matthews Duncan) . . . . . xxix, 308
„ puerperal (J. Matthews Duncan) . . . xxiv, 256

DIAGNOSIS of placenta prævia by palpation of the abdomen (H. R. Spencer) . . . . . xxxi, 203
„ *post-mortem*, of a nulliparous uterus (A. Meadows) xvii, 355; xviii, 69
„ and treatment of retroflexio-versio uteri gravidi (W. J. Sinclair) . . . . . xlii, 338

DIAPHRAGM, congenital hernia through, three cases of (H. R. Spencer) . . . . . xxxii, 132

DIAPHRAGMATIC HERNIA, congenital (A. E. Giles) . . xxxiv, 132

Dickinson (T. V.), uterus and iliac glands removed by abdominal hysterectomy for cancer of cervix . . . xlviii, 15

DICOTYLEDONOUS PLACENTA (W. T. Greene) . . xviii, 68

DIGITS, rudimentary supernumerary (H. Russell Andrews) . xlii, 266

DILATATION of the bladder in a fœtus (F. A. T. O'Meara) . xxix, 54
„ of the cervical canal for spasmodic dysmenorrhœa and sterility (C. Godson) . . . . . xxiii, 277; xxiv, 6
„ cystic, without rupture in a case of apoplexy of the ovary (Alban Doran) . . . . . xxxii, 119
„ digital, of the os in labour (J. Braithwaite) . . xxi, 38
„ of the os uteri for chorea in pregnancy (W. F. Wade) . xxii, 244
„ of the uterine canal by continuous elastic pressure (Lawson Tait) . . . . . xxi, 291

DILATOR (J. H. Aveling) . . . . . xxvi, 149
„ Bossi's (M. Handfield-Jones) . . . . xlv, 103
„ rapid, after Ellinger's (W. C. Grigg) . . . xvi, 248
„ uterine, graduated metallic (S. Sloan) . . . xxviii, 114

DILATATION of bladder and ureters from pressure, in an infant (W. McAdam Eccles) . . . . . xxxiv, 250

DIPHTHERIA (A. W. Williams) . . . . ix, 35
„ complicating puerperal fever (R. Druitt) . . . iii, 30
„ symptoms simulating, in a case of pregnancy complicated by cancer of the cervix followed by pyæmia (A. L. Galabin) . xxiii, 186

Diplococcus pneumoniæ, primary infection of the puerperal uterus by (A. G. R. Foulerton and W. F. Victor Bonney) . . xlv, 128

DISCOLORATION of the skin of the forearms and hands during pregnancy (J. G. Swayne) . . . . iv, 18

DISEASES, puerperal, further contribution to the clinical knowledge of (J. Braxton Hicks) . . . . xxxv, 412

DISINTEGRATION of organic tissue by high tension discharges (J. Inglis Parsons) . . . . xxxvii, 124

DISLOCATION, congenital, of both hips (S. W. Poole) . . xxii, 214

DISPLACEMENT of the bladder as a cause of tedious labour (W. H. Broadbent) . . . . . v, 44
„ of dermoid cyst of ovary obstructing labour, from the true pelvis, and extraction of the child with forceps; removal of tumour five weeks later; recovery (J. M. Munro Kerr) . xliii, 145
„ of uterus, see *Uterus*, displacement of.

DISPROPORTION, turning in cases of (A. H. McClintock) . . iv, 175

DISSECTION of a malformed child (W. L. Heath) . . xxiii, 195
„ of the muscles of the female pelvis and perineum (Alban Doran) xxviii, 274
„ of a case of spina bifida (T. W. Eden) . . . xxxv, 336
DISTENSION of vagina and uterus with muco-puriform fluid in a child aged 7 weeks (W. McAdam Eccles) . . . xxxiv, 250
DIVER (Dr.), see *Edis* (*A. W.*)
DIVERTICULA, urethral (A. Routh) . . . . xxxii, 69
„ Meckel's, prolapse of, forming an umbilical tumour (S. W. Wheaton) . . . . . xxxiv, 184
DONALD (ARCHIBALD), chronic septic infection of the uterus and its appendages . . . . . xlix, 6
„ methods of craniotomy . . . . . xxxi, 28
„ ectopic intra-ligamentous gestation at the seventh month, in which the fœtus was extracted by vaginal incision . . xli, 7
„ fibroid tumours complicating pregnancy and labour . xliii, 180
DORAN (ALBAN), tubal gestation and the effects of chronic retro-uterine hæmorrhage . . . . . xxi, 169
„ deficient development of the uterus, atresia of the os externum, atrophy of the ovaries, insanity . . . . xxi, 253
„ pelvic viscera showing congenital communication between the rectum and the genito-urinary tract . . . xxii, 79
„ exfoliation of vesical mucous membrane . . . xxiii, 2
„ microscopic sections of a dermoid ovarian cyst . . xxiii, 105
„ case of extreme arrest of development of the genito-urinary tract in a female fœtus. . . . . xxiii, 107
„ cyst of the great omentum . . . . xxiii, 164
„ twisting of pedicle in an incipient dermoid ovarian cyst . xxiv, 133
„ interstitial or tubo-uterine gestation, with notes on similar cases in the museums of London hospitals . . xxiv, 227
„ relation of prolapse of the vagina to hernia, illustrated by two pedigrees . . . . . xxvi, 88
„ ruptured secondary cyst in the wall of a multilocular ovarian tumour . . . . . xxvi, 118
„ specimen showing the relations to each other of inflammation of the endometrium, Fallopian tube, ovary, and pelvic peritoneum . . . . . xxvii, 164
„ fœtus and membranes from a case of missed abortion . xxvii, 224
„ malformations of the Fallopian tube . xxviii, 171; xxix, 186
„ papilloma of the Fallopian tube and the relation of hydro-peritoneum to tubal disease . . . xxviii, 229, 243
„ dissection of the muscles of the female pelvis and perineum . xxviii, 274
„ fœtus, sac, and pelvic viscera from a case of extra-uterine pregnancy . . . . . xxix, 491
„ glandular structure in the substance of a primary cancer of the Fallopian tube . . . . . xxx, 194
„ on myoma and fibro-myoma of the uterus and allied tumours of the ovary . . . . . xxx, 410
„ dissection of H. G. Trestrail's case of mylacephalus acardiac twin, with notes on acardiac monsters in the museums of London hospitals . . . . . xxxi, 4
„ for *William Skene*, anencephalous fœtus . . . xxxi, 52
„ dentigerous bony plates from a dermoid ovarian tumour . xxxi, 86
„ anterior serous perimetritis simulating ovarian sarcoma when explored by abdominal section; recovery with disappearance of the cyst . . . . xxxi, 217; xxxiii, 185

Doran (Alban) (*continued*)—
„ fibroma of the ovarian ligament . . . . xxxi, 200
„ fragment of membrane passed from the uterus . . xxxi, 229
„ — *report* on ditto by Committee (John Williams, W. S. A. Griffith, and Alban Doran) . . . . xxxi, 310
„ on closure of the ostium in inflammation and allied diseases of the Fallopian tube . . . . . xxxi, 344
„ apoplexy of the ovary; cystic dilatation without rupture . xxxii, 119
„ Delbastaille's speculum *à glissières* . . . . xxxii, 307
„ for *Ernest Hart*, ancient Greek charm from Crete representing woman in labour . . . . . xxxiii, 26
„ double hæmatosalpinx; suspected early tubal gestation on both sides . . . . . xxxiii, 112
„ sequel to the case of anterior serous perimetritis simulating ovarian sarcoma . . . . . xxxiii, 185
„ congenital auricular sinus; absence of external meatus on opposite side; cutaneous sinus over sacrum . . xxxiii, 199
„ cervical auricle . . . . . xxxiii, 200
„ for *George B. Beale*, fatal rupture of an ovarian cyst in an infant xxxiv, 24
„ papillomatous cyst of both ovaries causing profuse ascitic effusion . . . . . xxxiv, 149
„ on ligature of the pedicle in ovariotomy . . . xxxv, 131
„ for *Arthur A. Beale*, fœtus in peritoneal cavity; question of abdominal gestation, with a summary of reported cases of primary abdominal and ovarian pregnancy . . xxxv, 222
„ on the absorption of fibroid tumours of the uterus, with a report of a suspected case . . . . xxxv, 250
„ for *Walter Lowe* and *Harvey Bradbury*, acardiacus mylacephalus . . . . xxxvii, 209
„ placental polypus . . . . xxxvii, 229
„ cystic myoma of uterus weighing over 15 lb. . xxxviii, 164
„ cases of fibroma of the ovary and ovarian ligament removed by operation; with a series of after-histories of cases reported in the 'Transactions' since 1879 . xxxviii, 187
„ unreported case of primary cancer of the Fallopian tubes in 1847, with notes on primary tubal cancer . . xxxviii, 322
„ fibroma of the ovary; impaction; ascites; removal . xxxix, 37
„ lipoma of the lumbar region, 44 lb. in weight, and of twenty years' growth . . . . . xxxix, 40
„ fibroma of the abdominal wall; increase during pregnancy . xxxix, 42
„ management of true and false capsules in ovariotomy . xxxix, 265
„ hæmorrhage from the Fallopian tube without evidence of tubal gestation . . . . . xl, 180
„ tables of cases of primary cancer of the Fallopian tube reported up to present date (April, 1898) . . . xl, 197
„ blood concretions in the ovary . . . . xl, 214
„ fibroma of broad ligament weighing 44 lb. 8 oz. successfully removed from a woman aged 28 . . . . xl, 295
„ sarcoma of both ovaries . . . . xl, 296
„ inaugural address as President . . . . xli, 107
„ fibroid of the broad ligament weighing 44½ lb. (20 kilog.) removed by enucleation; recovery. (With table and analysis of thirty-nine cases) . . . . xli, 173
„ fibroid in undeveloped cornu of an uterus unicornis; from a parous subject . . . . . xli, 295
„ double hydrosalpinx without salpingitis . . . xli, 379
„ for *Professor Pawlik*, photographs from a case of primary cancer of the Fallopian tube . . . . . xlii, 6

DORAN (ALBAN) (*continued*)—
„ macerated fœtus removed from the abdominal cavity two months after spurious labour . . . . xlii, 8
„ annual address as President . . . . xlii, 43
„ tubal mole; fœtus three quarters of an inch in length, in perfect preservation . . . . xlii, 134
„ extra-uterine gestation in which fœtal death occurred at the eighth month after spurious labour; abdominal section two months later . . . . xlii, 213
„ acute torsion of an ovarian pedicle from a case where there was chronic torsion of the pedicle of a tumour of the opposite ovary . . . . xliii, 12
„ annual address as President . . . . xliii, 35
„ pregnant fibroid uterus removed at the fifth month . . xliii, 178
„ fibroid of broad ligament associated with an ovarian cyst . xliii, 260
„ and CUTHBERT LOCKYER, sloughing fibroid of the left uterine cornu; abnormal relations . . . . xliii, 272
„ retro-peritoneal lipoma weighing 13 lb. 12 oz. . . xliv, 265
„ fibroma of ovary one third of an inch in diameter . . xliv, 173
„ pure myoma of the ovary, with a microscopic section . xliv, 168
„ pure fibroma of the ovary . . . . xliv, 172
„ pregnancy after removal of both ovaries for cystic tumour . xliv, 231
„ for *F. C. Batchelor* (Dunedin), primary squamous-celled epithelioma of the body of the uterus . . . xlv, 374
„ pregnant fibroid uteri removed by operation . . xlvi, 119
„ solid mesenteric tumour (fibro-myoma) weighing 30 lb. . xlvi, 145
„ hæmatoma and hæmatocele; a study of two cases of early tubal pregnancy . . . . xlvi, 206
„ and H. WILLIAMSON, necrobiotic uterus associated with recent pregnancy . . . . . xlvi, 274
„ repeated tubal pregnancy . . . . xlvii, 235
„ subtotal hysterectomy; after-histories of sixty cases . xlvii, 363
„ fibroma of the ovary weighing 17 lb.; under observation for ten years . . . . . xlvii, 421
„ fibro-myoma removed by abdominal myomectomy in second month of pregnancy; labour at term . . . xlvii, 426
„ myomectomy during pregnancy and labour at term in an elderly primipara, with notes on similar cases . . xlviii, 303
„ for the late *Dr. G. Bagot Ferguson*, chorio-endothelioma of uterus; intra-peritoneal hæmorrhage; hysterectomy; death xlix, 57
„ after-history of the case of fibroid of broad ligament associated with an ovarian cyst, reported in the forty-third volume of the Society's 'Transactions.' . . . xlix, 94
„ malignant vaginal polypus secondary to an adrenal tumour of the kidney . . . . . xlix, 182

DOUBLE UTERUS, see *Uterus*, malformations of (double).

DOUCHE can (John Shaw) . . . . . xxxi, 262
„ new utero-vaginal (A. Wiltshire) . . . x, 20
„ the invalid's compendium (Graily Hewitt) . . xxx, 198
„ sublimate, mercurialism in lying-in women undergoing (W. R. Dakin) . . . . . xxviii, 281
„ syphon (A. W. Edis) . . . . . xxiii, 8
„ uterine, as a therapeutic agent (W. G. Hewitt) . . iv, 27
„ — and vaginal (A. E. Sansom) . . . . viii, 219

DOUGLAS' POUCH, calcified tumour of uncertain origin removed by laparotomy from (A. H. N. Lewers) . . . xlvii, 151

Down (J. Langdon), the obstetrical aspects of idiocy . . xviii, 296
DOYEN'S METHOD for the removal *per vaginam* of myomatous uteri (W. J. Smyly) . . . . . xli, 96
Drage (Charles), extra-uterine pregnancy . . . ii, 254
Drage (Lovell), case of rupture of the uterus . . xxviii, 2
„ four cases treated by electrolysis . . . xxx, 241, 260, 265
DRAINAGE in the treatment of suppurating ovarian cysts (J. J. Phillips) . . . . . xiv, 340
Drew (Douglas), abdominal hysterectomy for cancer of the cervix associated with pregnancy . . . xlviii, 202
DRILL-CROTCHET, description, and indications for the employment of (H. E. Eastlake) . . . . ix, 146
DROPSY extreme, with fatty degeneration and friability of the placenta (J. Brunton) . . . . . xvii, 175
„ of fœtus in a case of abortion at six and a half months (Protheroe Smith) . . . . . xvii, 303
„ — case of general (Lawson Tait) . . . . xvii, 307
„ — complication in the delivery of (J. A. Thompson) . xvii, 4
„ — hypertrophy of the placenta (J. Bassett) . . xix, 261
„ — and distension of bladder in, necessitating embryotomy (A. L. Galabin) . . . . . xix, 119
„ — (T. W. Eden) . . . . . xlv, 45
„ — and œdema (H. R. Andrews) . . . . xliii, 166
„ obstructing delivery in fœtus with absence of urethra (T. G. Stevens) . . . . . xxxvii, 5
„ ovarian (H. W. Sharpin) . . . . vii, 102
„ — (J. S. Turner) . . . . . x, 39
„ — treated by tapping and pressure; apparent recovery for three and a half years; return of disease; ovariotomy; recovery . . . . . v, 279
„ with fibroma of the ovary; impaction; removal (Alban Doran) xxxix, 38
Driutt (R.), craniotomy . . . . . i, 81
„ complete obliteration of the canal of the small intestine by fœtal peritonitis; Amussat's operation . . . ii, 135
„ effects of reckless vaccination . . . . ii, 305
„ puerperal fever complicated with diphtheria in which life was saved by the sesquichloride of iron . . . iii, 30
„ substitute for brandy in cases of exhaustion . . iii, 143
„ syphilis after vaccination . . . . v, 196
Duncan (C.), see *Barnes, Fancourt.*
Duncan (J. Matthews), state of the internal surface of the uterus after delivery . . . . . iv, 107
„ cephalotribe . . . . . xi, 42
„ long delay of labour after discharge of liquor amnii. . xiv, 216
„ spontaneous separation of placenta when it is prævia . xv, 189
„ letters read in the discussion on puerperal fever . xvii, 101, 132
„ general cancerous hypertrophy of the body of the uterus . xx, 27
„ on traction by the lower jaw in head-last cases; a laboratory note . . . . . xx, 61
„ the revolutions of the fœtal head in passing through a brim contracted only in the conjugate diameter—laboratory note . xx, 151
„ two specimens of pyometra . . . . xxi, 54
„ on expression of the cord . . . . xxi, 302
„ hydrocephalic child with stumps of arms and deformity of lower limbs . . . . . xxii, 237

DUNCAN (J. MATTHEWS) (*continued*)—
„ for *H. A. Lediard*, double ovariotomy . . . xxiii, 6
„ delivery in a case of double uterus . . . xxiii, 21
„ inaugural address as President . . . . xxiii, 64
„ calculi embedded in female urethra . . . xxiii, 109
„ case of phlegmasia dolens with lymphatic varix . . xxiii, 132
„ on shortness of the cord as a cause of obstruction to the natural progress of labour . . . . xxiii, 243
„ Fallopian tube pregnancy . . . . xxiii, 263
„ means of keeping sponges aseptic in the vagina . . xxiv, 5
„ annual address as President . . . xxiv, 32; xxv, 29
„ case of so-called imperforate hymen . . . xxiv, 212
„ on puerperal diabetes . . . . . xxiv, 256
„ Auvard's couveuse or nest . . . . xxvi, 25
„ angioma of labium . . . . . xxvi, 118
„ on fœtal revolutions . . . . . xxvi, 171
„ on the ulceration of lupus of the female generative organs, including perforations, pits, and excavations . . xxvii, 139
„ on the hypertrophy of lupus of the female generative organs . xxvii, 230
„ on the inflammations of lupus of the pudendum . . xxvii, 310
„ on contraction, inhibition, and expansion of the uterus . xxviii, 91
„ on elasticity, retraction, and polarity of the uterus . . xxviii, 115
„ on hæmorrhagic parametritis . . . . xxix, 191
„ on diabetes insipidus in pregnancy and labour . . xxix, 308
„ on tonic uterine contraction without completeness of retraction . . . . . xxix, 369
„ on locking, retroversion, and strangulation of uterine fibroids in the pelvic excavation . . . . . xxx, 435
„ laceration of the vagina in labour . . . xxxi, 236
„ Münchmeyer's transfusion apparatus . . . xxxii, 5
„ and J. B. HURRY, on extensions or retroflexions of the fœtus, especially of the trunk, during pregnancy . . xxvi, 206
„ vote of condolence on the death of . . . xxxii, 306
DUNCAN (WILLIAM), hydatidiform mole . . . xxv, 162
„ — *report* on ditto by committee (F. H. Champneys, Alban Doran, and W. Duncan) . . . . xxv, 233
„ large fibro-cellular tumour . . . . xxv, 212
„ ruptured ovarian cyst . . . . . xxv, 212
„ — *report* on ditto by committee (Alban Doran, W. S. Playfair, and W. Duncan) . . . . . xxv, 234
„ cancerous uterus removed by Schroeder's operation . . xxvi, 27
„ pedunculated fibroid . . . . . xxvi, 186
„ ovarian tumour . . . . . xxvi, 229
„ on extirpation of the entire uterus . . xxvii, 8, 93
„ hæmatocele from ruptured Graafian follicle . . xxviii, 210
„ cystic ovaries removed for dysmenorrhœa . . . xxviii, 211
„ sloughing uterine fibroid . . . . xxix, 250
„ ovaries and jejunum . . . . . xxx, 82
„ secretion of milk in a new-born male child (living specimen) . xxx, 226
„ uterus and appendages from a single woman . . xxx, 408
„ uterus, with its contained placenta, removed from a rachitic woman, aged 30, by Porro's operation . . . xxx, 408
„ uterus, the subject of sarcoma, removed by hysterectomy, with microscopical sections . . . . . xxxi, 2
„ Fallopian tube and ovary from a case of tubal gestation . xxxi, 165
„ uterus, heart, and brain from a case of puerperal septicæmia . xxxi, 202
„ an anencephalic fœtus . . . . . xxxi, 202

Duncan (William) (*continued*)—
„ uterus, rectum, and left kidney of a woman who died of uræmia . . . . . xxxi, 255
„ dermoid ovarian tumour . . . . . xxxi, 255
„ simple ovarian cyst . . . . . xxxi, 255
„ large myoma of left broad ligament . . . xxxi, 309
„ hæmatosalpinx and pyosalpinx . . . . xxxi, 332
„ hydrosalpinx . . . . . xxxi, 332
„ fibro-myoma and abscess . . . . xxxi, 332
„ rapidly fatal cerebral hæmorrhage occurring in a case of pregnancy complicated with multiple fibroids . . xxxii, 2
„ should pregnancy be terminated prematurely in cases of phthisis? . . . . . xxxii, 7
„ right ovary and tube distended with blood . . xxxii, 306
„ uterine appendages the subject of tubercular deposits . xxxii, 306
„ uterus with primary cancer of the body extirpated *per vaginam* xxxii, 306
„ suppurating dermoid cyst . . . . xxxii, 346
„ ovary and tube with papilloma . . . . xxxii, 346
„ broad ligament cyst . . . . . xxxiii, 157
„ extirpation of the uterus for cancer . . xxxiii, 157
„ *report* on ditto by committee (W. Duncan, W. S. A. Griffith, S. W. Wheaton, and G. E. Herman) . . . xxxiii, 161
„ uterus, with kidneys and ureters, from a case of Cæsarean section . . . . . xxxiv, 127
„ knitting-needle used to procure abortion . . . xxxiv, 223
„ for *H. A. Lediard*, specimen of sessile fibro-myoma from the supra-vaginal portion of cervix uteri which had obstructed labour, removed by laparotomy . . . xxxv, 296
„ tubal gestation of nine weeks' duration, successfully removed three hours after rupture . . . . xxxvi, 66
„ ruptured tubal gestation . . . . xxxvi, 114
„ fibroid polypus of cervix . . . . xxxvi, 114
„ fœtus and placenta removed by laparotomy from a case of extra-uterine gestation . . . . xxxvi, 146
„ gangrenous uterine fibroid removed by abdominal hysterectomy . . . . . xxxvi, 181
„ hypertropied nymphæ and clitoris . . xxxvi, 3, 149
„ cystic sarcoma of omentum simulating ovarian tumour; removal; recovery . . . . . xxxvi, 264
„ dermoid cyst of right ovary; twisted pedicle . . xxxvi, 267
„ ovarian tumour complicating pregnancy; cyst ruptured during examination; immediate laparotomy; recovery . xxxvi, 312
„ for *J. Davoren*, a case of congenital absence of nose, right palpebral fissure, and right ear; imperforate anus, &c. . xxxvii, 16
„ degenerating uterine myoma . . . xxxvii, 147
„ double tubo-ovarian cystoma . . . xxxvii, 149
„ dilated tubes and cystic ovaries (early stage of tubo-ovarian cysts) . . . . . xxxvii, 150
„ case of missed abortion, in which an early embryo in its amniotic sac was retained in the uterus for eight months xxxvii, 196
„ unruptured tubal gestation removed by abdominal section xxxvii, 197
„ sloughing fibroid removed by hysterectomy . xxxvii, 197
„ for *G. H. Jones*, conjoined twins (thoracopagus) . xxxvii, 198
„ ruptured tubal gestation . . . xxxvii, 244
„ double pyosalpinx . . . . xxxvii, 245
„ — simulating extra-uterine pregnancy; removal; recovery xxxvii, 291
„ unruptured tubal gestation . . . . xxxviii, 36

DUNCAN (WILLIAM) (*continued*)—
„ large double tubo-ovarian cysts . . . . xxxviii, 37
„ fibroids removed by the intra-abdominal method . . xxxix, 88
„ double pyosalpinx . . . . . xxxix, 89
„ adeno-carcinoma of uterus and left ovary removed by abdominal section . . . . . xxxix, 289
„ uterus with submucous and interstitial myoma removed by hysterectomy . . . . . xxxix, 290
„ multiple myxomatous polypi from cervix uteri . . xlii, 243
„ uterus removed at full term by intra-peritoneal hysterectomy in a case of contracted pelvis . . . . xliii, 9
„ multiple myxomatous polypi from the cervix uteri . . xliii, 75
„ uterine fibroids removed by intra-peritoneal hysterectomy . xliii, 76
„ sarcoma of uterus . . . . . xliii, 228
„ subperitoneal fibroma . . . . . xliii, 228
„ three months' gravid uterus removed by vaginal hysterectomy for squamous epithelioma of cervix . . . xliv, 297

DUNN (ROBERT) statistics of midwifery from the records of private practice . . . . . i, 279
„ fatal case of concealed accidental hæmorrhage occurring at the eighth month of pregnancy . . . . viii, 285
„ — rupture of the uterus occurring at the eighth month of pregnancy . . . . . ix, 65

DYSMENORRHŒA, essential cause of, as illustrated by cases of partial and complete retention (R. Barnes) . . xiv, 108
„ cystic ovaries removed for (Wm. Duncan) . . . xxviii, 211
„ mechanical (R. Greenhalgh) . . . . viii, 142
„ — and sterility, with a description of a new metrotome (R. Greenhalgh) . . . . . v, 164
„ membrane of (Wynn Williams) . . . . xxv, 233
„ membranous (R. Cory) . . . . . xx, 113
„ — membrane passed in a case of (A. Meadows) . xvi, 230, 251
„ metrorrhagia, ovaritis, and sterility, depending upon a peculiar formation of the cervix uteri; and the treatment by dilatation or division (R. Barnes) . . . . vii, 120
„ nature, cause, and treatment of (G. Hoggan) . . xvi, 250
„ on the natural history of (John Williams) . . xxiv, 103, 141
„ contribution to the natural history of (G. Ernest Herman and H. Russell Andrews) . . . . . xliv, 371
„ on the relation between backward displacements of the uterus and (G. E. Herman) . . . . . xxiv, 161
„ the pathology and treatment of (John Williams) . . xix, 138
„ the relation of anteflexion of the uterus to (G. E. Herman) . xxiii, 209
„ spasmodic, the treatment of, by dilatation of the cervical canal with graduated metallic bougies (Clement Godson) xxiii, 277; xxiv, 6
„ see *Menstruation*.

DYSPAREUNIA, see *Vaginismus*.

DWARF, case of Cæsarean section in a, and death from peritonitis (J. Braxton Hicks) . . . . . xxi, 253

EAR, right; congenital absence of nose, right palpebral fissure; imperforate anus, etc. (W. Duncan) . . . xxxvii, 16
„ congenital auricular sinus; absence of external meatus on opposite side; cutaneous sinus over sacrum (A. Doran) . xxxiii, 199

EARLE (J. LUMLEY), new pelvimeter . . . iii, 145
„ distension of the bladder, considered as a cause of post-partum hæmorrhage . . . . . v, 291
EASTLAKE (H. E.), case in which amaurosis was observed eight times in succession after parturition . . . v, 79
„ obstetric binder . . . . . vi, 205
„ management of third stage of labour . . . vi, 226
„ uterine therapeutics . . . . . viii, 6
„ case in which the right arm of the child was extruded through the anal orifice during labour . . . . viii, 320
„ complete epispadias in male infant . . . . ix, 63
„ indications for the employment of a drill-crotchet; its special advantages in certain forms of labour, with a description of the instrument . . . . . ix, 146
„ child with posterior fontanelle large and quadrangular . ix, 243
EATON (J. C.), see *Godson, Clement.*
ECCLES (W. MCADAM), distension of vagina and uterus with muco-purulent fluid, accompanied by dilatation of bladder and ureters from pressure, in a child aged 7 weeks . . xxxiv, 250
ECHINOCOCCUS (J. B. Hicks) . . . . . viii, 109
ECLAMPSIA, note on the ætiology of (H. Macnaughton-Jones) . xxxix, 12
„ chloral treatment of (P. von Seydewitz) . . . xii, 117
„ in a case of erysipelas followed by premature labour (J. B. Hurry) . . . . . xxxii, 309
„ kidneys from a case of (L. Cutler) . . . xxxvi, 176
„ of pregnancy, with observations on the state of the renal function (G. E. Herman) . . . . xxix, 517
„ puerperal, pathology of (J. B. Hicks) . . . viii, 323
„ — pathology and treatment of, with special reference to the use of saline transfusion (E. W. Hey Groves) . xliii, 117, 148
„ — cases of, especially illustrating the temperature and urine in this disease (G. E. Herman) . xxxii, 17; xxxiii, 315
„ — the behaviour of the uterus in (J. Braxton Hicks) . xxv, 118
„ — five more cases of, especially illustrating the temperature and urine in this disease (G. Ernest Herman) . . xxxiii, 315
„ — (Horace Savory) . . . . . xli, 284
„ — with a description of a five-weeks' ovum removed in a subsequent pregnancy (W. S. A. Griffith and T. W. Eden) . xli, 151
„ — microscopical sections of the kidneys from a fatal case of (H. R. Andrews) . . . . . xliii, 114
„ — with autopsy and remarks (R. H. Bell) . . xliv, 253
„ — treated by thyroid extract (A. J. Sturmer) . . xlvi, 126
„ — primary, pneumococcus meningitis, simulating (T. Wilson) xliv, 5
„ septic peritonitis; splenic abscess; death on sixteenth day after delivery (J. C. Holdich Leicester) . . . xlvii, 271
„ with two special details of treatment (C. N. Longridge) . xlvii, 353
„ see also *Convulsions.*
ÉCRASEUR (C. H. F. Routh) . . . . . xv, 38
„ with single steel wire (A. Meadows) . . . ix, 111
„ single wire, for removal of fibroid polypus (J. H. Davis) . ix, 152
„ — intra-uterine fibroid removed by (G. C. P. Murray) . xi, 78
„ — for removal of fibroid polypus (A. Meadows) . . xi, 241
„ improvement in single wire (H. Smith) . . . xv, 86
„ improvement on mode of fastening the rope in (J. B. Hicks) . vii, 71
„ polypus of the uterus, removed by (W. G. Hewitt) . . iii, 350

ECTOPIA VISCERUM and retroflexion of fœtus (W. R. Dakin) xxxi, 308; xxxii, 200
„ retroflexion and (John Phillips) . . . xxxiii, 490
„ with retroflexion (Amand Routh) . . . xxxv, 102

ECTOPIC GESTATION, see *Pregnancy*, extra-uterine.

ECTROPION of the os uteri, case of bilateral laceration with (A. L. Galabin) . . . . . xxi, 312

ECZEMA of the nipple in both breasts (Thos. Chambers) . xxii, 268
„ uterus from a patient subject to, for three years (R. Barnes) . xvii, 215
EDEN (T. W.), dissection of a case of spina bifida . . xxxv, 336
„ ovarian cyst . . . . . xxxv, 408
„ unruptured tubal gestation . . . . xxxvi, 6
„ on the development and normal structure of the human placenta . . . . . xxxvii, 205, 227
„ addendum to paper on deciduoma malignum . xxxviii, 162
„ deciduoma malignum: a criticism . . xxxviii, 149
„ on the structure of the ripe placenta, and the changes which occur in placentæ retained *in utero* after the death of the fœtus . . . . . xxxviii, 360
„ decidual cast of the uterus, from a case in which there was no evidence of extra-uterine gestation, with microscopic sections . . . . . xxxix, 132
„ and W. S. A. GRIFFITH, notes of a case of puerperal eclampsia, with a description of a five weeks' ovum removed in a subsequent pregnancy . . . . . xli, 151
„ adenoma of the uterus . . . . . xlii, 2
„ cast of the uterus . . . . . xlii, 5
„ case of fœtal ascites . . . . . xlv, 45
„ primary hydatid disease (echinococcus) of the Fallopian tube xlvi, 243
„ and F. LIONEL PROVIS, intra-ligamentous, fibro-cystic tumour of the uterus, weighing about 30 lb., removed by enucleation and sub-total hysterectomy . . . . xlviii, 264
„ tubal pregnancy with acute salpinitis . . . xlviii, 272

EDIS (A. W.), fibroid degeneration of uterus, with subperitoneal and interstitial fibrous tumours, in a state of disintegration xi, 34
„ four and a half months' fœtus with encephalocele . . xi, 173
„ hydrocephalic fœtus . . . . . xi, 173
„ ovarian cyst . . . . . xiii, 41
„ abscess of ovary; peritonitis and death . . . xiii, 99
„ systematic examination of the abdomen with a view to rectifying malpositions of the fœtus in cases of labour . . xiv, 331
„ on the necessity for caution in the employment of extra-uterine stems . . . . . xvi, 3
„ ovum expelled about the eighth week, showing the villi of the chorion . . . . . xvii, 48
„ for *Dr. Diver*, apparatus called the couchaid, to assist labour and economise force during parturition . . . xvii, 48
„ india-rubber speculum trough . . . . xvii, 49
„ for *James Stothard*, case of twins in which one died at an early period of pregnancy . . . . . xvii, 211
„ hydrocephalic fœtus which had presented by the breech, and had caused an impediment to delivery . . . xvii, 302
„ case of epithelioma of the cervix uteri; pregnancy, parturition, extraction of a living child, death of the mother, two weeks after delivery, from pyæmia . . . . xvii, 344

EDIS (A. W.) (*continued*)—
„ specimen of cyst in the larynx removed *post mortem* from an infant . . . . . xviii, 2
„ specimens of nulliparous and multiparous uteri, with tables of measurements . . . . . xviii, 74
„ case of pyæmia with extensive purulent deposits in a new-born infant . . . . . xix, 12
„ the forceps in modern midwifery . . . . xix, 69
„ for *Robert Barnes*, modification of Tarnier's forceps . . xx, 163
„ double ovarian cysts, with fibroid of the uterus and ascitic fluid from peritonitis . . . . . xx, 164
„ two placentæ from cases of twins, prematurely expelled about the fifth and sixth months . . . xx, 321, 322
„ remarks in the discussion on the use of forceps . . xxi, 171
„ a syphon douche . . . . . xxiii, 8
„ polypi uteri . . . . . xxiii, 205
„ epithelioma of cervix with pregnancy . . . xxiii, 264
„ microscopical section illustrating case of malignant disease of the cervix . . . . . xxiv, 298
„ epithelioma of the cervix uteri, complicating pregnancy; Cæsarean section, recovery of mother, child living . . xxiv, 304
„ dermoid cyst . . . . . xxv, 66
„ arrested development of one twin; double placenta . . xxv, 213
„ vaginal extirpation of cancerous uterus . . . xxvii, 2

ELASTICITY of the uterus (J. Matthews Duncan) . . xxviii, 115

ELDER (GEORGE), sarcoma of the ovary . . . xxv, 130

ELECTRICAL INSTRUMENTS in use in obstetric medicine (W. E. Steavenson) . . . . . xxix, 298

ELECTRICAL LIGHT (Heywood Smith) . . . xxvii, 3

ELECTRICITY, disintegration of organic tissue by high tension discharges (J. Inglis Parsons) . . . xxxvii, 124

ELECTROLYSIS in gynæcological practice (W. E. Steavenson, Lovell Drage, R. A. Gibbons, and John Shaw) . . xxx, 229
„ on the induced current during parturition (W. Kilner) . xxvi, 93

ELEPHANTIASIS of the vulva (W. S. Playfair) . . xix, 184

ELKINGTON (FRANCIS), polypus of the uterus, with clinical observations . . . . . i, 112
ELLINGTON (FRANCIS), spontaneous inversion of the uterus . xix, 50
ELLIS (RICHARD), a rare form of twin monstrosity, with notes by D. EMBLETON . . . . . vii, 160

ELLIS (ROBERT), cauterisation by electric heat in the treatment of certain diseases of women . . . . iii, 424
„ practical inquiry into the properties of nitrate of silver, with an account of a new instrument for its use in uterine disease iv, 116
„ anæsthesia by mixed vapours . . . . viii, 224
„ new expanding speculum for operations on the cervix uteri . ix, 86
„ a self-retaining tenaculum for operations on the cervix uteri ix. 88
„ carbolised sponge tents. On the defects of ordinary sponge tents and an improved method for their manufacture . ix, 121

EMBEDDING, intra-mural, of placenta shown in incomplete tubal abortion (C. Lockyer) . . . . xlv, 191

EMBOLIA in lying-in women (R. Barnes) . . . iv, 30

EMBOLISM, fatal, of the right heart and pulmonary artery nineteen years days after delivery (G. Roper) . . xxi, 74
„ — of the pulmonary artery after ovariotomy (E. Parson) . vii, 8
„ — pulmonary, occurring twenty-four days after delivery (H. Williamson) . . . . . xlv, 189
„ — puerperal (W. F. Wade) . . . . vi, 255

EMBRYO, blighted and atrophied (G. E. Herman) . xxiii, 204, 259
„ — blighted (L. Remfry) . . . . xxxv, 153
„ early human obliteration of the central canal of the spinal cord in (C. B. Lockwood) . . . . xxx, 470
„ early, in its amniotic sac retained in the uterus for eight months in a case of mixed abortion (W. Duncan) . xxxvii, 196
„ three weeks, and ruptured tube from the sac of an old pelvic hæmatocele (C. J. Cullingworth) . . xxxviii, 122
„ carneous mole retained *in utero* five months after death of, showing proliferation of epithelium of villi as a syncytium forming reticulating processes (A. L. Galabin) . . xlv, 240
„ escape of the body of, through the fimbriated opening, shown in a tubal mole, with retention of the head and amniotic cavity in the tube (J. S. Fairbairn) . . xliii, 211
„ retroflexion of, with absence of the spinal medulla and imperfection of the vertebral column (C. B. Lockwood) . xxix, 234
„ see also *Fœtus.*

EMBRYOMA of anterior mediastinum in a male adult (J. Ritchie) xlv, 25
„ malignant, of ovary (H. T. Hicks and J. H. Targett) . xlvii, 287

EMBRYOTOMY in a case of ascites and distension of the bladder in a fœtus (A. L. Galabin) . . . . xix, 119
„ new method of (R. Barnes) . . . . xi, 126

EMMET'S OPERATION, or trachélo-raphé (W. S. Playfair) . xxiv, 54

EMOTION, strong mental, affecting pregnant women, as a cause of idiocy in the offspring (Sir A. Mitchell) . . . xxvi, 124

EMPYEMA in children, treatment of (W. S. Playfair) . . xiv, 4
„ — two forms of apparatus for use in (W. B. Woodman) . xv, 2

ENCEPHALOCELE (H. Smith) . . . . ix, 243
„ fœtus with (H. G. Times) . . . . xiii, 51
„ in fœtus of four and a half months (A. W. Edis) . . xi, 173
„ large, photographs and casts, and description of *post mortem* (Clement Godson and F. S. Eve) . . xxii, 131, 132

ENDOMETRITIS, cervical, periodical discharge of membrane in (A. L. Galabin) . . . . . xxiii, 207
„ chronic, with microscopic sections (P. Horrocks) . . xxix, 298
„ exfoliativa (C. Lockyer) . . . . xliii, 205
„ fundal (C. H. F. Routh) . . . . xii, 136
„ polyposa with blighted ovum (A. H. N. Lewers) . . xxxiii, 197
„ purulent senile, specimens from a case of (G. E. Herman) . xxxii, 196
„ senile, difficulty of diagnosis between this disease and cancer of the uterine body (G. E. Herman) . . xxxiii, 31
„ microscopic sections of uterine mucous membrane (A. L. Galabin) . . . . . xxii, 47
„ see *Endometrium.*

ENDOMETRIUM, corporeal, fibroids of the uterus complicated by cancer of (J. Bland-Sutton) . . . . xlviii, 140
„ unusual thickening of in case of fibroids (A. W. Addinsell) . xli, 231

ENDOMETRIUM (*continued*)—
„ Fallopian tube, ovary, and pelvic peritoneum, the relations to each other of inflammation of (Alban Doran) . . xxvii, 164
„ villous degeneration of the (D. C. MacCallum) . . xxiii, 37
„ uterus removed for (?) malignant overgrowth of (V. Bonney) . xlvii, 191
„ small round-celled sarcoma of (A. L. Galabin) . . xlv, 184
ENDOTHELIOMA of uterus (M. A. D. Scharlieb) . . xlvii, 281
„ supposed, of the cervix (H. Russell Andrews) . . xlviii, 283
ENUCLEATION for removal of fibroid of the broad ligament weighing 44½ lb. (Alban Doran) . . . xli, 173
„ uterine fibroids removed by, fifteen days after delivery (R. Boxall) . . . . . xxxvi, 64
„ spontaneous, of fibroma (Amand Routh) . . . xxxv, 409
„ for removal of large fibro-myoma of cervix, followed by vaginal hysterectomy (W. W. H. Tate) . . . . xlii, 161
„ remarks on, in connection with a case of fibro-myoma of the uterus in a patient aged 23 (A. E. Giles) . . . xlii, 299
„ and sub-total hysterectomy for the removal of an intra-ligamentous, fibro-cystic tumour of the uterus weighing about 30 lb. (T. W. Eden and F. L. Provis) . . . xlviii, 264
EPILEPSY, imperfectly developed internal generative organs in a patient subject to (C. Lockyer) . . . xlviii, 75
„ uterus unicornis and right appendages removed from a woman subject to (G. F. Blacker) . . . . xlviii, 82
EPISPADIAS, complete, in male infant (H. E. Eastlake) . ix, 63
EPITHELIOMA of lip treated by injection of bromine (A. W. Williams) . . . . . xiii, 97
„ of the cavity of the uterus, case of extirpation for (J. Knowsley Thornton) . . . . . xxv, 9
„ of the body of the uterus, primary squamous-celled (A. Doran) . . . . . xlv, 374
„ of the cervix uteri (C. H. Carter) . . xxx, 82
„ — of the anterior lip of (A. L. Galabin) . . . xxi, 312
„ — columnar (Graily Hewitt) . . . . xxix, 510
„ — extirpation of the entire uterus for (Wm. Duncan) . xxvii, 8, 93
„ — fœtus from a woman suffering with (Clement Godson) . xix, 40
„ — and of the os (W. Newman) . . . . xvii, 213
„ — removed by the écraseur, in which local anæsthesia by the ether spray was employed (E. Parson) . . . ix, 47
„ — removed by écraseur wire during pregnancy without causing abortion (Clement Godson) . . . xxv, 18
„ — pregnancy, parturition, death of mother from pyæmia (A. W. Edis) . . . . . xvii, 344
„ — complicating pregnancy (A. L. Galabin) . . xviii, 242
„ — — Cæsarean section (A. W. Edis) . . . xxiv, 304
„ — — pregnancy (C. T. Savory) . . . . xvii, 82
„ — with pregnancy (A. W. Edis) . . . . xxiii, 264
„ of the cervix, uterus showing rapidly growing; death from recurrence five months after removal (C. Lockyer) . xliv, 284
„ squamous, of cervix uteri, three months' gravid uterus removed by vaginal hysterectomy for (W. Duncan) . . xliv, 297
„ — of the cervix uteri in a very early stage (W. S. A. Griffith) xlii, 210
„ — invading surrounding tissues like a columnar-celled variety (W. S. A. Griffith) . . . . xlii, 210
„ — of cervix uteri; removed in 1895; no recurrence in 1901 (A. H. N. Lewers) . . . . . xliii, 266

EPITHELIOMA (*continued*)—
„ of vagina, primary (C. Hubert Roberts) . . xxxviii, 381
„ of the vulva, list of ovariotomies in women over 80; a case aged 83, complicated by (L. Remfry) . . xxxvii, 155
„ — with after-histories (A. H. N. Lewers) . . . xlviii, 163
„ — and cyst of ovary (Heywood Smith) . . xxi, 313; xxii, 3
EPITHELIUM, chorionic, partially differentiated into cells, showing syncytium derived from, in a vesicular mole (A. L. Galabin) xlv, 240
„ ciliated, drawings of microscopic sections of a uterine polypus showing (H. Gervis) . . . . . xxviii, 240
ERGOT OF RYE for fibrous enlargement of the uterus (J. Brunton) xiii, 282
„ during labour, inquiry into effect on the life of the child (R. U. West) . . . . . iii, 222
„ the effect of, on the involution of the uterus (G. E. Herman and C. O. Fowler) . . . . . xxx, 85
„ liquid extract of, Martindale's (A. Wiltshire) . . xviii, 2
ERGOTININE, the hypodermic injection of, in cases of post-partum hæmorrhage (C. Chahbazian) . . . . xxiv, 286
EROSIONS of the cervix uteri, pathological anatomy of (A. L. Galabin) . . . . . xxii, 156
ERYSIPELAS, symmetrical, followed by premature labour, eclampsia post-partum (J. B. Hurry) . . . xxxii, 309
Ettles (W. J. McC.), case of cyclops . . . xxxvi, 149
Eve (Fred. S.), description of a double-headed human female monster born at the full term of gestation, shown by C. Godson for G. E. Yarrow . . . . xxii, 74
„ *post-mortem* of C. Godson's case of large encephalocele . xxii, 132
EWES, death in, during and after parturition, report on certain causes of (J. Hutchinson) . . . . xviii, 88
EXAMINATION, bimanual, tubal abortion produced by (A. L. Galabin) . . . . . xlvii, 332
EXFOLIATION of vesical mucous membrane (Alban Doran) . xxiii, 2
EXOMPHALOS, in which the gravid uterus formed the hernial mass (G. C. P. Murray) . . . . . i, 77
EXPANSION of the uterus (J. Matthews Duncan) . . xxviii, 91
EXPULSION, spontaneous (C. Berkeley) . . . xliv, 320
EXTENSIONS of the fœtus during pregnancy (J. Matthews Duncan and J. B. Hurry) . . . . . xxvi, 206
EXTIRPATION of the uterus, entire (Wm. Duncan) . xxvii, 8, 93
„ — for cancer (W. Duncan) . . . . xxxiii, 157
„ — with both ovaries (Thomas Chambers) . . . xxiii, 12
„ — and ovaries with large fibrous tumours (I. B. Brown) . vi, 249
„ — vaginal, two cases of (A. L. Galabin) . . . xxix, 300
„ — — for cancer (A. W. Edis) . . . xxvii, 2
„ — — for primary cancer of the body (Wm. Duncan) . xxxii, 306
„ — — for primary carcinoma of the body (A. H. N. Lewers) . xxx, 218
„ — — in "grape-like" sarcoma of the cervix uteri, fungating into and infiltrating the walls of the vagina in a child aged 12 months (H. J. Curtis) . . . . xlv, 320
„ — — sarcoma of the body of the uterus removed by (W. S. Playfair) . . . . . xxxvii, 200
„ — see also *Hysterectomy*.
EXTROVERSION of the bladder (F. H. Champneys) . . xxiv, 240

EXTRUSION, spontaneous, of a large uterine fibroid (W. S. A. Griffith) . . . . . xxxv, 38
EYES, colour of, in newly-born infants (A. Wiltshire) . . xx, 79

FACE, persistent mento-posterior position of, in which the child was delivered alive by the axis-traction forceps (A. H. N. Lewers) . . . . . xli, 280
FAIRBANK (THOMAS), fracture of the pelvis, with injury to the uterus in the sixth month of pregnancy; recovery; death at a subsequent delivery . . . . . ix, 1
FAIRBAIRN (J. S.), and C. J. CULLINGWORTH, large inflamed cyst (? ovarian) communicating with an inflamed Fallopian tube . xlii, 96
„ carcinomatous tumour of ovary . . . . xliii, 208
„ tubal mole, showing escape of the body of the embryo through the fimbriated opening, with retention of the head and amniotic cavity in the tube . . . . xliii, 211
„ unilocular ovarian cyst containing solid masses undergoing necrotic change . . . . . xliv, 126
„ five specimens of fibroid tumour of the ovary, with observations on their pathological anatomy . . . xliv, 177
„ fibroid tumour of the uterus, wholly cervical, forming an abdominal tumour, and characterised by profuse hæmorrhage xlv, 178
„ necrobiotic fibroid removed from a recently delivered patient, aged 22 . . . . . xlvi, 194
„ large fibrotic uterus, with calcification of the arteries . xlvii, 299
FALLOPIAN PREGNANCY, see *Pregnancy*, extra-uterine.
FALLOPIAN TUBES, adherent to the opposite ovary in a case of ovarian tumour (J. Knowsley Thornton) . . . xxiii, 258
„ anatomy of the pregnant (H. R. Andrews) . . . xlv, 197
„ accessory, cyst in connection with the right, arising probably from an (R. H. Bell) . . . . . xlvi, 21
„ — hydrosalpinx of an, due to twisting of the pedicle (W. S. Handley) . . . . . xlv, 157
„ primary cancer of, glandular structure in the substance of a (Alban Doran) . . . . . xxx, 194
„ — (A. Routh) . . . . . xxxi, 200
„ unreported case of primary cancer of, in 1847, with notes on primary tubal cancer (Alban Doran) . . xxxviii, 322
„ tables of cases of primary cancer of, reported up to present date (April, 1898) (A. Doran) . . . . xl, 197
„ primary cancer of (Alban Doran) . . . xlii, 6
„ — (J. Bland-Sutton) . . . . . xliv, 311
„ — of right; right ovary normal (H. Briggs) . . xlvi, 60
„ second case of primary carcinoma of (C. Hubert Roberts) . xli, 129
„ primary carcinoma of (C. J. Cullingworth) . . xxxvi, 307
„ — (C. Hubert Roberts) . . . . . xl, 189
„ — (H. R. Andrews) . . . . . xlv, 54
„ after-history of a case of cystic fibroid, with carcinoma of the left ovary and right (R. Boxall) . . . xlviii, 136
„ carcinoma of (C. J. Cullingworth) . . . xlvii, 263
„ cystic fibroid with carcinoma of left ovary and right (R. Boxall) xliii, 71
„ cyst of (A. Meadows) . . . . . viii, 139
„ dermoid cyst in (C. J. Ritchie) . . . . vii, 254
„ dilatation of, uterine appendages showing cystic growths and (T. C. Hayes) . . . . . xxxiii, 4

FALLOPIAN TUBES (*continued*)—
„ primary hydatid disease (echinococcus) of (T. W. Eden) . xlvi, 243
„ an undescribed disease of (Lawson Tait) . . . xxv, 249
„ disease of both; macerated fœtus (A. D. Leith Napier) xxxiii, 461
„ endometrium, ovary, and pelvic peritoneum, the relations to each other of inflammation of (Alban Doran) . . xxvii, 164
„ glands of, and their function (J. Bland-Sutton) xxx, 207; xxxii, 189
„ showing glands, microscopical sections of (W. S. A. Griffith) . xxx, 195
„ hæmatosalpinx in a chronically inflamed (A. W. W. Lea) . xli, 140
„ from a case of ruptured tubal gestation, complicated by a large hæmatosalpinx on the opposite side (C. J. Cullingworth) . xxxii, 273
„ hæmorrhage from, without evidence of tubal gestation (A. Doran) . . . . . xl, 180
„ distended by hæmorrhage in a parovarian cyst (A. D. Leith Napier) . . . . . xxxiv, 124
„ hydrocele of the canal of Nück, containing a portion of the left (L. Remfry) . . . . . xl, 6
„ left, and left broad ligament, sac formed by, in a case of extra-uterine pregnancy (C. J. Cullingworth) . . . xxx, 480
„ enlarged, and cystic ovary (A. D. Leith Napier) . . xxxiv, 126
„ both attached to a unilocular ovarian cyst (J. Knowsley Thornton) . . . . . xxi, 119
„ microscopical section of, from an early tubal fœtation (A. L. Galabin) . . . . . xxx, 195
„ on closure of the ostium in inflammation and allied diseases of (Alban Doran) . . . . . xxxi, 344
„ malformations of (Alban Doran) . . xxviii, 171; xxix, 186
„ the frequency of pathological conditions of (A. H. N. Lewers) xxix, 199
„ in cases of phthisis, tuberculosis of (P. D. Turner) . . xli, 359
„ torsion of the pedicle in hydrosalpinx and other morbid conditions of (R. H. Bell) . . . . . xlvi, 152
„ double tuberculous pyosalpinx with intercommunication of (A. L. Galabin) . . . . . xlii, 173
„ enormous distension of, in a case of double pyosalpinx (C. H. Roberts) . . . . . xl, 121
„ rupture of right, uterus and appendages of a woman who died from (Aust Lawrence) . . . . . xx, 292
„ rupture of (Clement Godson) . . . xxii, 2, 82
„ — (J. Knowsley Thornton) . . . . xxxi, 198
„ tubal abortion with rupture of (A. Routh) . . . xliii, 294
„ tubal mole, showing escape of the body of the embryo through the fimbriated opening, with retention of the head and amniotic cavity in . . . . . xliii, 211
„ tuberculosis of (W. S. A. Griffith) . . . xxviii, 66
„ tuberculous disease of cervix and (W. W. H. Tate) . . xlvi, 138
„ tubo-ovarian cysts (W. S. A. Griffith) . xxix, 273, 302; xxx, 3
„ ruptured towards its fimbriated end in two places (Amand Routh) . . . . . xliv, 131
„ ovarian tumour with greatly enlarged (P. Horrocks) . xxxvi, 185
„ with a large inflamed cyst (? ovarian) communicating with an inflamed (C. J. Cullingworth and J. S. Fairbairn) . . xlii, 96
„ solid tumour of the left ovary with an attached cyst communicating with the left (W. F. V. Bonney) . . xliv, 92
„ great distension of, from tubercle in fibroid tumours of the uterus (P. Horrocks) . . . . . xlii, 166
„ hypertrophy of, and cystic ovaries (John Phillips) . . xxxi, 332
„ retained menses *in utero* and (C. H. F. Routh) . . xii, 34

FALLOPIAN TUBES (*continued*)—
„ papilloma of, and the relation of hydroperitoneum to tubal disease (Alban Doran) . . . xxviii, 229, 243
„ and ovaries, diseased (C. H. Carter) . . . xxxii, 136
„ — dilated (T. C. Hayes) . . . . xxxvi, 185
„ — and cystic ovaries (W. Duncan) . . xxxvii, 150
„ — distended with blood (Wm. Duncan) . . . xxxii, 306
„ — from a case of persistent chronic ovaritis (J. D. Malcolm) . xxviii, 278
„ — from a case of tubal gestation (Wm. Duncan) . . xxxi, 165
„ — tubercular disease of (A. W. W. Lea) . . . xlv, 133
„ and ovary, microscopical sections of tuberculosis of (C. H. Roberts) . . . . . xlv, 92
„ — removed by oöphorectomy (J. Knowsley Thornton) . xxiv, 137
„ — with papilloma (Wm. Duncan) . . . xxxii, 346
„ — and uterus from a case of Cæsarean section (C. J. Cullingworth) . . . . . xxxi, 308
„ uterus and appendages with ruptured pregnant (A. W. Addinsell) . . . . . xli, 172
„ see *Hæmatosalpinx*, *Hydrosalpinx*, *Pyosalpinx*, *Salpingitis*, *Uterine appendages*.

FARADISATION, galactagogue properties of (T. Skinner) . v, 94

FARRAR (JOSEPH), a new and speedy method of dilating a rigid os in parturition . . . . . xxxvi, 321

FARRE (ARCHER), spontaneous salivation associated with pregnancy xv, 222

FARRE (ARTHUR), remarks in the discussion on puerperal fever . xvii, 178
„ *Honorary President*, accepting the office of . . . xvii, 302
„ a brief description of a series of casts, showing the condition of the uterus at various periods after labour, varying from the time of delivery to fifteen days after that event . xviii, 84

FAT, infiltration of broad ligament with, in a case of ovarian dermoid (J. Bland-Sutton) . . . . xxxiv, 7
„ pellets of, in a dermoid cyst (A. C. Butler-Smythe) . xxxvii, 15

FATTY CHANGES, alleged, of the uterus, sections at different periods of the puerperium showing complete absence of (W. S. A. Griffith) . . . . . xxxi, 308

FATTY DEGENERATION of placenta, see *Placenta*, fatty degeneration of.

FEEDING BOTTLE, Marshall's patent sectional (Clement Godson) xxiii, 166
„ Perrett's (J. B. Hicks) . . . . . xi, 169

FEET, deformity of (A. E. Giles) . . . . xxxiv, 129
„ talipes varus of both (H. Madge) . . . ix, 158

FEMALE PRACTITIONERS, see *Women*.

FEMORA, the pressure of the, and its influence on the shape of the pelvis (F. H. Champneys) . . . . xxv, 70
„ endosteal sarcoma of, showing syncytial structures (F. W. Andrewes) . . . . . xlv, 237

FEVER, enteric, slough forming a complete cast of the vagina from a case of (W. S. Playfair) . . . xxxviii, 33

FEVER IN CHILDBED. Part I.—General hygiene and antisepsis (R. Boxall) . . . . . xxxii, 219, 275
„ Part II.—The relation of external meteorological conditions to the incidence of febrile illness in childbed (R. Boxall) . xxxv, 340

FIBRIN, placenta with deposits of (J. Brunton) . . x, 20

FIBRINOUS POLYPUS (W. S. A. Griffith) . . . xxv, 165
FIBRO-ADENOMA removed from the cervix (G. F. Blacker) . xli, 374
FIBRO-CYST of ovary (W. A. Meredith) . . xxix, 248, 513
„ of the uterus (J. Knowsley Thornton) . . . xxxi, 199
FIBRO-CYSTIC DISEASE of the uterus (Thos. Chambers) xxii, 159, 187
„ — (Heywood Smith) . . . . . xxvi, 58
„ — weighing 14 lb. (Thos. Chambers) . . . xx, 32, 54
„ — and both ovaries; extirpation; recovery (T. Bryant) . xiv, 79
FIBRO-ENCHONDROMATOUS TUMOUR complicating pregnancy; safe delivery (A. Wiltshire) . . . . xii, 376
FIBROID TUMOURS, see *Tumours*, fibroid.
FIBROMA (J. D. Malcolm) . . . . xxix, 249, 515
„ subperitoneal (W. Duncan) . . . . xliii, 228
„ spontaneously enucleated (Amand Routh) . xxxv, 409; xxxvi, 2
„ of the abdominal wall; increase during pregnancy (Alban Doran) . . . . . xxxix, 42
„ of broad ligament weighing 44 lb. 8 oz., successfully removed from a woman aged 28 (Alban Doran) . . . xl, 295
„ of both ovaries (C. J. Cullingworth) . . . xxi, 276
„ of the ovary, sections of (H. T. Rutherfoord) . . xxxiv, 88
„ — (J. Crawford) . . . . . xxxvi, 190
„ (?) — (P. Horrocks) . . . . . xxxvi, 192
„ — (M. Handfield-Jones) . . . . xxxvi, 343
„ — undergoing calcareous degeneration (C. Hubert Robert) . xxxix, 8
„ — impaction; ascites; removal (Alban Doran) . . xxxix, 37
„ — (C. J. Cullingworth) . . . . . xxxix, 279
„ pure, of ovary (A. Doran) . . . . xliv, 172
„ of ovary one third of an inch in diameter (A. Doran) . xliv, 173
„ — (F. N. Boyd) . . . . . xliv, 176
„ — (A. E. Giles) . . . . . xliv, 360
„ — with fibro-myoma of uterus, and with extensive carcinoma of body of uterus (W. W. H. Tate) . . . xlvi, 139
„ — (F. E. Taylor) . . . . . xlvi, 280
„ — weighing 17 lb.; under observation for ten years (A. Doran) xlvii, 421
„ — (A. Routh) . . . . . xlviii, 133
„ — and ovarian ligament removed by operation; with a series of after-histories of cases reported in the 'Transactions' since 1879 (Alban Doran) . . . . xxxviii, 187
„ calcified ovarian (M. Handfield-Jones) . . . xlviii, 332
„ of the ovarian ligament (Alban Doran) . . . xxxi, 200
„ of the uterus (Heywood Smith) . . . . xxiii, 262
„ and other morbid conditions of the uterus, treated by Apostoli's method (J. Inglis Parsons) . . . xxxiv, 22
„ uteri, small, showing sarcomatous changes (J. M. Munro Kerr) xliv, 129
„ on intermittent contractions of uterine, and in pregnancy in relation to diagnosis (J. B. Hicks) . . . xxxvi, 188
„ multiple, of uterus, with carcinoma of body, removed by abdominal pan-hysterectomy (J. H. Dauber) . . xxxix, 321
„ two, removed by intra-peritoneal hysterectomy (H. Macnaughton-Jones) . . . . . xxxix, 321
FIBRO-MYOMA and abscess (Wm. Duncan) . . . xxxi, 332
„ calcified uterine, removed piecemeal for hæmorrhage fourteen years after oöphorectomy (H. R. Spencer) . . xlix, 271
„ subperitoneal (A. L. Galabin) . . . . xliii, 225
„ sessile, from the supra-vaginal portion of cervix uteri which had obstructed labour (Wm. Duncan) . . . xxxv, 296

FIBRO-MYOMA (*continued*)—
„ solid mesenteric tumour, weighing 30 lb. (A. Doran) . xlvi, 145
„ spontaneously enucleated during labour (W. R. Dakin) . xli, 105
„ of broad ligament (W. A. Meredith) . . xxix, 249, 514
„ — (M. Handfield-Jones) . . . . xxxv, 239
„ — soft (R. Boxall) . . . . . xxxv, 410
„ and cancer co-existing in the body of the uterus (M. Handfield-Jones) . . . . . xlvi, 305
„ cystic, of the uterus, removed by posterior colpotomy (H. R. Spencer) . . . . . xliii, 110
„ — complicating pregnancy; removal at four and a half months (J. Dysart McCaw) . . . . . xl, 256
„ degenerated, weighing over 17 lb., enucleated from the broad ligament nine hours before delivery at term (H. R. Spencer) . xlvi, 122
„ weighing 14 lb., large, soft, broad ligament (Ewen Maclean) . xl, 134
„ of uterus, œdematous subperitoneal, in right broad ligament, removed by abdominal hysterectomy (C. J. Cullingworth) . xl, 302
„ pedunculated, of the broad ligament, with twisted pedicle (C. J. Cullingworth) . . . . xxxvii, 222
„ of right ovary removed by abdominal section (C. H. Carter) . xxix, 190
„ of the ovary (H. R. Andrews) . . . . xliii, 231
„ — (A. J. Sturmer) . . . . xlv, 335, 370
„ of the intra-abdominal portion of the round ligament of the uterus (H. R. Spencer) . . . . xlvi, 26
„ large, of cervix, removed by enucleation, followed by vaginal hysterectomy (W. W. H. Tate) . . . . xlii, 161
„ of the cervix uteri removed by abdominal pan-hysterectomy (W. A. Meredith) . . . . xlvi, 12
„ of cervix treated by abdominal hysterectomy (W. W. H. Tate) xlv, 173
„ cystic, of the cervix uteri (C. H. Roberts) . . . xlii, 211
„ of uterus (R. Barnes) . . . . . xxv, 68
„ — (J. Knowsley Thornton) . . . . xxv, 67
„ — attached to fundus of an irreducible inverted uterus (P. Horrocks) . . . . . xxx, 196, 228
„ — degenerating, associated with a case of hæmatometra, treated by supra-vaginal hysterectomy (W. A. Meredith) . xxix, 422
„ — from a case of Cæsarean section (P. Horrocks) . . xxix, 98
„ — removed by hysterectomy (W. Walter) . . . xxvi, 326
„ — vascular (J. Knowsley Thornton) . . . xxvi, 269
„ — with axial rotation (W. A. Meredith) . . . xxx, 80
„ — removed by operation from women under twenty-five years of age (H. R. Spencer) . . . . . xl, 228
„ — removed by operation (W. W. H. Tate) . . . xlviii, 183
„ — associated with large cavity containing retained menses communicating with uterine canal (W. Tate) . . xlvii, 360
„ — with extensive carcinoma of body of uterus, and fibroma of ovary (W. W. H. Tate) . . . . xlvi, 139
„ — showing marked cystic degeneration, removed from a patient aged 63, from whom both ovaries had been removed eleven years before (W. W. H. Tate) . . . xliii, 26
„ — relations of organic affections of the heart to (T. Wilson) . xlii, 176
„ — double pyosalpinx associated with (W. S. Playfair) . xxxiii, 497
„ — complicated with double salpingitis and carcinoma of cervix (W. W. H. Tate) . . . . . xliii, 270
„ — gangrene of an interstitial (C. J. Cullingworth) . . xxxix, 281
„ — incarcerated, in an unusually young subject (C. J. Cullingworth) . . . . . xlii, 132

FIBRO-MYOMA OF UTERUS (*continued*)—
„ — early ectopic gestation (? tubo-uterine), complicated by (C. J. Cullingworth) . . . . . xxxix, 284
„ — complicating early ectopic gestation (? tubo-uterine) (C. J. Cullingworth) . . . . . xl, 285
„ — complicating rupture of an early tubal gestation (fifteenth day) (E. Rumley Dawson) . . . . xl, 155
„ multiple (Leith Napier) . . . . xxxv, 3
„ large multiple, removed by hysterectomy (A. D. Leith Napier) xxxiv, 159
„ multiple, complicating a twin pregnancy (John Phillips) . xxviii, 138
„ — of the uterus (C. J. Cullingworth) . . xxxviii, 6
„ of the uterus causing intestinal obstruction and death two years after the menopause (C. J. Cullingworth) . . xxxix, 282
„ — in a patient aged 23, with remarks on enucleation and myomectomy (A. E. Giles) . . . . xlii, 299
„ — pedunculated subserous, which had undergone myxomatous and cystic degeneration (A. F. Stabb) . . . xlii, 133
„ — with sarcomatous degeneration (P. Horrocks) . . xl, 178
„ — undergoing sarcomatous degeneration (P. Horrocks) . xlvi, 184
„ — undergoing sarcomatous change (W. S. A. Griffith and H. Williamson) . . . . . xlviii, 22
„ — sloughing, occurring in a patient twenty years after the menopause (W. W. H. Tate) . . . . xl, 303
„ — with sloughing of the central part shortly after delivery (J. D. Malcolm) . . . . . xlvi, 15
„ — projecting into vagina, removed by abdominal hysterectomy (W. W. H. Tate) . . . . . xl, 159
„ and myoma of the uterus and allied tumours of the ovary (Alban Doran) . . . . . xxx, 410
„ and sarcoma of uterus, further history of a case of degenerating (R. Hamilton Bell). . . . . xlviii, 199
„ necrobiotic uterine, occurring in pregnancy (F. E. Taylor) . xlvii, 333
„ removed by abdominal myomectomy in second month of pregnancy; labour at term (A. Doran) . . . xlvii, 426
„ degenerating, and sarcoma of uterus (W. W. H. Tate) . xlvii, 358
„ of vaginal wall (with microscopical slide (John Phillips) . xl, 130
„ of the vagina (J. M. Munro Kerr) . . . xliv, 130
„ — (anterior wall) (J. Bland-Sutton) . . . xli, 100
„ of the vestibule (J. Inglis Parsons) . . . xlviii, 184
„ and cystic disease co-existing in the same ovary (W. W. H. Tate) . . . . . xlvi, 273

FIBRO-SARCOMA of chorion (A. L. Galabin) . . . xxvii, 107
„ of the ovaries (W. A. Meredith) . . . . xxxi, 225
„ of the right ovary (M. Handfield-Jones) . . . xxxi, 126

FIBROUS POLYPUS, see *Polypus*, fibrous.

FIBROUS TUMOURS, see *Tumours*, fibrous.

Fielden (W. E.), see *Galabin, A. L.*

FILLET, or loop, as an obstetric aid, new modification of (R. E. Wilmot) . . . . . xv, 172
„ steel (G. R. Sheraton) . . . . . viii, 259

FINGERS, webbed, in an infant (A. Wiltshire) . . xii, 329

FISTULA, recto-vaginal, caused by retention of a Zwancke's pessary (T. Churton) . . . . . xvi, 223

FISTULA (*continued*)—
„ recto-vaginal, caused by retention of a Zwancke's pessary for six years (A. L. Galabin) . . . . xix, 201
„ vesico-uterine, description of a new operation for (F. H. Champneys) . . . . . xxx, 348
„ vesico-utero-vaginal, case of (C. J. Cullingworth) . . xxxi, 320
„ vesico-vaginal treatment of, by a new method (R. Battey) . i, 275
„ — the mode of operating, and the results obtained in fifty-five cases at the London Surgical Home . . . v, 25
„ — new method of treating cases of (A. Meadows) . . vi, 107
„ — left fourteen years after lithotomy, cured by plastic operations (Lawson Tait) . . . . . xviii, 209
„ — curved needle made to revolve, for cases of (J. H. Aveling) xix, 66
„ — instruments for (N. Bozeman) . . . . xix, 96
„ — caused by a calculus (Clement Godson) . . xxvi, 181
„ — and recto-vaginal (T. E. Jones) . . . xv, 185

Fitzpatrick (J.), large uterine mole . . . . xx, 170
„ uterus with its contents at full term . . . xxi, 37

Fitzpatrick (Thomas), early ovum, funis tightly encircling the left thigh of fœtus . . . . . x, 141

FIXATION OF UTERUS, see *Uterus*.

FLEXIONS OF UTERUS, see *Uterus*, displacements of.

FŒTUS, elongation of head of, as a cause of difficulty in the application of the ordinary forceps (W. G. Hewitt) . . iii, 180

FŒTAL HEAD, lateral obliquity of, in normal labour (A. L. Galabin) . . . . . xvii, 283
„ normal asymmetry of (A. Wiltshire) . . . xx, 78
„ plaster casts of (J. Brunton) . . . . xxiii, 206
„ revolutions of, in passing through a brim contracted only in the conjugate diameter (J. Matthews Duncan) . . xx, 151
„ showing furrowing from pressure against sacrum (G. Roper) . xxii, 84
„ varieties of form imparted to, by the various modes of birth (R. Barnes) . . . . . vii, 171

FŒTAL SCALP, sloughing of, as the result of tedious labour (W. O. Priestley) . . . . . i, 323

FŒTAL MONSTROSITY (Maitland Coffin) . . . xxiv, 98
„ (C. H. F. Routh) . . . . . xxiv, 75
„ (J. Phillips) . . . . . xxxix, 44
„ see also *Monster*.

FŒTAL MOVEMENTS, on recording, by means of a gastrograph (J. Braxton Hicks) . . . . . xxii, 134

FŒTATION, see *Pregnancy*.

FŒTUS, abnormal condition of, obstructing labour (J. B. Hicks) . v, 285
„ in case of abortion (Graily Hewitt) . . . xxxiii, 461
„ absence of occipital bone (R. Barnes) . . xvi, 100, 127
„ acardiac acephalic, anatomy and nature of two (A. Keith) . xlii, 99
„ acardiac, acephalous, anencephalous, dicephalous, mylacephalous, etc., see also *Monsters*.
„ anatomical relations between mother and (H. Madge) . viii, 348
„ anencephalic, completely cleft spine associated with an unusual visceral malformation in (Thomas G. Stevens) xxxviii, 346
„ skull of an anencephalic (Amand Routh) . . xxxvii, 219

FŒTUS (*continued*)—
„ anencephalic (H. Macnaughton-Jones) . . . . xlvii, 307
„ anencephalic di-prosopia, see also *Monsters.*
„ anencephalous (Mr. Sass) . . . . xi, 31
„ — (D. Carlyle) . . . . xi, 35
„ — with spina bifida (E. Jones) . . . . xi, 209
„ acephalous acardiac (M. Handfield-Jones) . . . xxxiv, 84
„ amorphous acardiac (G. E. Herman for *G. Mallack Bluett*) . xxxiii, 493
„ enclosed in amniotic sac only (C. E. Purslow) . . xli, 168
„ with anasarca and large placenta (R. Boxall) . . xlii, 98
„ arrest of development of genito-urinary tract in a female (Alban Doran) . . . . xxiii, 107
„ ascitic, complication in the delivery of (J. A. Thompson) . xvii, 4
„ with ascites and distension of the bladder, necessitating embryotomy (A. L. Galabin) . . . . xix, 119
„ ascites and œdema of (H. R. Andrews) . . . xliii, 166
„ the subject of atresia ani vesicalis (W. R. Dakin) . . xxxii, 368
„ compressus s. papyraceus (F. C. Bottomley) . . xxxix, 134
„ compressus (E. A. Barton) . . . . xlv, 417
„ death of, at the eighth month after spurious labour, in a case of extra-uterine gestation, abdominal section two months later (A. Doran) . . . . xlii, 213
„ abdominal pregnancy secondary to partial rupture of tubal gestation sac; abdominal section fifteen months after conception and eight months after death of (J. B. Hellier) . xlv, 366
„ death of, at end of eighth month in a case of extra-uterine pregnancy and operation a month later (A. E. Giles) . xlvii, 114
„ death of, an acoustic sign heard after the (Robert Harvey) . xxi, 273
„ significance of adhesions of the wall of the gestation sac to the dead, in extra-uterine fœtation (J. D. Malcolm) . xlv, 421
„ death and decomposition of, in a case of rupture of the uterus (R. Greenhalgh) . . . . xi, 9
„ born dead, with knot on funis (W. Sankey) . . iii, 413
„ deformed, with adherent placenta, intestines uncovered and presenting; with description of the delivery (D. Johnson) . xiii, 53
„ — (F. R. Hogg). Report on by J. H. Aveling and A. W. Edis xiii, 263
„ — (J. L. Worship) . . . . xiv, 139
„ — (G. Roper) . . . . xviii, 295
„ — with cystic tumour of neck (A. H. N. Lewers) . xxxviii, 106
„ — (F. C. Bottomley) . . . . xxxix, 134
„ — (A. Burton) . . . . xl, 217; xli, 339
„ deformity of (A. W. Addinsell) . . . xxxvii, 204
„ development of, to the full time in the peritoneal cavity, still retaining its amniotic covering, in a case of ectopic pregnancy (Lawson Tait) . . . . xxxiv, 192
„ delivered by cephalotribe (J. B. Hicks) . . . xi, 1
„ dilatation and hypertrophy of the bladder in (F. A. T. O'Meara) . . . . xxix, 54
„ discharged in the membranes entire at six months and three weeks (H. T. Barton) . . . . xxix, 189
„ distension of the uterus in, impeding labour (H. Gervis) . v, 284
„ dropsy of, case of general (Lawson Tait) . . . xvii, 307
„ — in a case of abortion at six and a half months (Protheroe Smith) . . . . xvii, 303
„ — with hypertrophy of the placenta (J. Bassett) . . xix, 261
„ from a woman suffering with extensive epithelioma of the cervix (Clement Godson) . . . . xix, 40

FŒTUS (*continued*)—
„ case of exomphalic (A. E. Giles) . . . . xxxvi, 174
„ extensions or retroflexions of, especially of the trunk, during pregnancy (Matthews Duncan and J. B. Hurry) . . xxvi, 206
„ extra-uterine, skeleton of (L. B. Aldrich-Blake) . . xlix, 269
„ five fœtal sacs from the peritoneal cavity of a rabbit (M. S. Pembrey) . . . . . xl, 253
„ five months', with intense congestion of head and neck (W. F. Cleveland) . . . . . xvi, 2
„ five and a half months' (Butler Willing) . . xvi, 85, 97
„ four and a half months', with encephalocele (A. W. Edis) . xi, 173
„ at fourth month enclosed in a perfect sac (H. Smith) . xiv, 66
„ of four months' development contained within an unruptured amnial sac with placenta prævia attached (A. D. Leith Napier) . . . . . xxxiv, 158
„ head of, on the occurrence in normal labour of lateral obliquity of (A. L. Galabin) . . . . . xvii, 283
„ with hernia umbilicalis congenita and spina bifida lumbo-sacralis (Amand Routh) . . . . xxxv, 102
„ hydrocephalic (A. W. Edis) . . . . xi, 173
„ — which had presented by the breech and impeded delivery (A. W. Edis) . . . . . xvii, 302
„ — female, orbital tumour in, with tumour of cheek, mal-development of neck, associated with hydramnios, necessitating interference with the pregnancy at the seventh month (H. S. Stannus) . . . . . xliii, 304
„ *in utero*, influence of maternal impressions on the (A. Meadows) . . . . . vii, 84
„ inflammatory disease of the skin of the head and upper part of the body of an eight months', with exudation of plastic lymph (G. D. Gibb) . . . . . iii, 442
„ inquiry into the best mode of delivering the head of, after perforation (J. B. Hicks) . . . . vi, 263
„ laceration of the integument of, occurring during delivery (R. K. Peirce) . . . . . vii, 74
„ living and viable, abolition of craniotomy from obstetric practice in all cases where (W. T. Smith) . . . i, 21
„ living, extracted by cœliotomy after term in a case of tubo-abdominal pregnancy (J. Bland-Sutton) . . . xl, 308
„ malformation of (W. Sedgwick) . . . . i, 239
„ — (P. Horrocks) . . . . . xxvii, 131
„ malformed (Amand Routh) . . . . xxxiv, 463
„ malpositions of, in labour, systematic examination of abdomen for rectifying (A. W. Edis) . . . . xiv, 331
„ macerated; double tubal disease (A. D. Leith Napier) . xxxiii, 461
„ — removed from the abdominal cavity two months after spurious labour (Alban Doran) . . . . xlii, 8
„ — bones of, from an extra-uterine gestation retained seven years (J. D. Malcolm) . . . . . xli, 223
„ partially macerated, from an extra-uterine fœtation retained in the body about a year after its death (J. D. Malcolm) . xli, 222
„ matured and putrid, attempted extrusion near the umbilicus in a case of extra-uterine gestation (A. M. Sheild) . . xxxiii, 148
„ mechanical obstruction in growth of (W. B. Owen) . . viii, 4
„ monstrous (R. Barnes) . . . . . vii, 227
„ mummified, expelled after birth of full-term child (R. Barnes) viii, 108
„ myxoma in, impeding delivery (T. C. Hayes) . . xviii, 83

FŒTUS (*continued*)—
„ note on some difficult cases of fronto-anterior positions of the head of (George Roper) . . . . xl, 271
„ antero-posterior positions of the fœtal head as a cause of difficult labour (R. G. McKerron) . . . xli, 142
„ notes on a (H. S. Wilson) . . . . xxi, 58
„ premature expulsion of (A. Ball) . . . . i, 315
„ in peritoneal cavity, question of abdominal gestation, with a summary of reported cases of primary abdominal and ovarian pregnancy (Alban Doran) . . . . xxxv, 222
„ peritonitis of (W. A. Hunt) . . . . ix, 15
„ retained *in utero* for some weeks after its death and decomposition (W. Newman and G. Harley) . . . ii, 251
„ retention of the ovum within the uterus, and growth of membranes for a period of five months after the death of, in a case of abortion (W. G. Hewitt) . . . . iii, 411
„ retention of, in the abdomen forty-three years (R. W. Watkins) viii, 106
„ retained, and placenta (E. Porter) . . . xiii, 129
„ dead, retained *in utero* for four years (A. Halley) . . ix, 90
„ retroflexion of, and ectopia viscerum (W. R. Dakin) xxxi, 308; xxxii, 200
„ — — (J. Phillips) . . . . . xxxiii, 490
„ at seven months, illustrating celosoma with retroflexion, meningocele, and talipes varus (Leith Napier) . . xxxvi, 116
„ retroflexion of (L. Remfrey) . . . . xxxvi, 227
„ on revolutions of the (Matthews Duncan) . . . xxvi, 171
„ from a ruptured tubal fœtation (A. H. N. Lewers) . . xxviii, 207
„ sac, and pelvic viscera from a case of extra-uterine pregnancy (Alban Doran) . . . . . xxix, 491
„ shrivelled, of the fifth month utero-gestation (E. Clapham) . xxxi, 202
„ six months', which lived for twenty-one hours (C. H. Carter) xvi, 226, 253
„ spontaneous evolution of, *in utero*; the head changed for the feet (R. Hodges) . . . . . ii, 303
„ stillborn, from a syphilitic patient with fatty placenta (T. C. Hayes) . . . . . xvii, 275
„ structure of the ripe placenta, and the changes which occur in placentæ retained *in utero* after the death of (T. W. Eden) xxxviii, 360
„ teratoma of head of (Hugh S. Stannus) . . . xliv, 78
„ thoracopagus (Amand Routh) . . . . xlii, 29
„ three months', flattened and curved laterally (Heywood Smith) . . . . . xvi, 2
„ three quarters of an inch in length, in perfect preservation in specimen of tubal mole (A. Doran) . . . xlii, 134
„ two, in connection with the same tube (N. J. Haydon) . v, 280
„ upper portion of trunk and head of, where the arm, face, and foot had presented (R. Barnes) . . . xvi, 100, 127
„ extracted by vaginal incision in a case of ectopic (intra-ligamentous) gestation at the seventh month (A. Donald) xli, 7
„ volvulus in (R. D. Maxwell) . . . . xlviii, 277
„ *in utero*, radiograph of (Heywood Smith) . . . xlviii, 44
„ with a peculiar growth from the mouth (Mr. Greives) xiv, 139, 210
„ with absence of urethra and ascites obstructing delivery (T. G. Stevens) . . . . xxxvii, 5
„ with diaphragmatic hernia (H. Smith) . . . xv, 162
„ with encephalocele (H. G. Times) . . . xiii, 51
„ with outgrowth from end of coccyx (Heywood Smith) . xxv, 2
„ with rent near the anus, through which the intestines protruded (H. Smith) . . . . . x, 198

FŒTUS (*continued*)—
„ and placenta of extra-uterine gestation removed by abdominal section (G. E. Herman) . . . . xxviii, 141
„ — from a case of extra-uterine gestation (C. J. Cullingworth) xxxii, 135
„ — removed by laparotomy from a case of extra-uterine gestation (W. Duncan). . . . xxxvi, 146
„ — in extra-uterine fœtation (W. R. Jordan) . . xv, 124
„ — removed six months after spurious labour in a case of abdominal pregnancy (E. J. Maclean) . . . xlviii, 129
„ — successfully removed in a case of tubal pregnancy (G. E. Herman) . . . . . xxx, 123
„ — of about five months; funis knotted round neck of child (W. F. Cleveland) . . . . . xiii, 1
„ — funis obliterated by twisting (A. Rasch) . . x, 94
„ with placenta attached to the head (E. J. Tilt) . . xvi, 124
„ — attached, showing a knot in the umbilical cord (C. Godson) . . . . . xxv, 66
„ placenta, membranes, and Fallopian tube, from a case of ruptured tubal gestation, complicated by a large hæmato-salpinx on the opposite side (C. J. Cullingworth) . . xxxii, 273
„ — and membranes delivered entire, concealed accidental hæmorrhage (W. R. Dakin) . . . . xxxvi, 315
„ — cord, and membranes (Robert Wise) . . xxxviii, 166
„ papyraceus (H. J. Ilott). . . . . xxxvii, 7
„ — (W. Rivers Pollock) . . . xxxviii, 320
„ growth of the placenta after death of, in ectopic gestation (Lawson Tait and C. Martin) . . . . xxxiv, 206
„ five months, and placenta, from a case of twin pregnancy, in which the second child was delivered alive at or near full term, along with the dead fœtus (G. G. Genge) . xxxviii, 5
„ and membranes from a case of missed abortion (Alban Doran) xxvii, 224
„ on sacs containing, and lying free in the peritoneal cavity of a rabbit (M. S. Pembrey and G. Bellingham Smith) . xlvi, 283
„ twin, smallpox in (H. Madge) . . . . iii, 173
„ see *Embryo.*

FONTANELLE, posterior, of a child (H. E. Eastlake) . . ix, 243
„ posterior variation of the, in children (A. W. Sikes) . xlvi, 272
„ sagittal, in the heads of infants at birth (A. W. W. Lea) . xl, 263

FOOT and hand, deformity of, in a child (John Phillips) . xxviii, 89

FORCEPS, aseptic (P. Horrocks) . . . . xxxiv, 460
„ Aveling's, presentation of . . . . xviii, 2
„ axis-traction, used for delivery of a child in a case of persistent mento-posterior position of the face (A. H. N. Lewers) . xli, 280
„ bent as a sound for the introduction of laminaria tents (— Coley) . . . . . xx, 170
„ in breech presentations (T. W. Agnew) . . . xix, 217
„ brephotome, and blunt hook . . . xxxvii, 243
„ craniotomy (R. Barnes) . . . . . v, 277
„ — (J. H. Davis) . . . . . vi, 123
„ — (J. Matthews) . . . . . ix, 29
„ — new (G. Roper) . . . . . xix, 136
„ delivery by, in face presentation in the mento-lateral position (J. B. Hicks) . . . . . xv, 39
„ depression of child's head by (C. Godson) . . . xxiii, 161
„ designed to allow the direction of traction to be that of the axis of the pelvis (A. L. Galabin) . . . xix, 227

FORCEPS (*continued*)—
„ discussion on the use of, and of its alternatives in lingering labour . . . . xxi, 121, 141, 171, 201
„ introductory paper by Robert Barnes . . . xxi, 121
„ remarks by W. S. Playfair . . . xxi, 141, 235
„ — George Kidd . . . . . xxi, 141
„ — John Thorburn . . . . . xxi, 146
„ — William Stephenson . . . . . xxi, 150
„ — William Newman . . . . . xxi, 153
„ — Edward Malins . . . . . xxi, 155
„ — F. H. Alderson . . . . . xxi, 158
„ — J. Lucas Worship . . . . . xxi, 159
„ — A. W. Edis . . . . . xxi, 171
„ — Lombe Atthill . . . . . xxi, 178
„ — A. H. McClintock . . . . . xxi, 185
„ — John Bassett . . . . . xxi, 192
„ — Henry Bennet . . . . . xxi, 193
„ — John J. Cranny . . . . . xxi, 194
„ — Henry Savage . . . . . xxi, 196
„ — George Roper . . . . . xxi, 201
„ — J. Braxton Hicks . . . . . xxi, 218
„ — W. F. Cleveland . . . . . xxi, 226
„ — F. H. Daly . . . . . xxi, 227
„ — Graily Hewitt . . . . . xxi, 229
„ — J. G. Swayne . . . . . xxi, 233
„ — in reply, Robert Barnes . . . . xxi, 238
„ head said to have been ruptured by the use of (R. Cory) . xx, 81
„ long, advantages of the early use of the (F. H. Daly) . xii, 3
„ — delivery by, in labour complicated with a fibrous tumour of uterus (W. O. Priestley) . . . . i, 217
„ — delivery of a very large living child effected by (C. Waller) i, 309
„ in modern midwifery (A. W. Edis) . . . xix, 69
„ Marshall's new midwifery, each blade rotating on its axis by means of a pivot joint (R. Barnes) . . . xxi, 90
„ Hasland's midwifery (R. Paramore) . . . xxix, 190
„ midwifery, the curves of, their origin and uses (J. H. Aveling) xx, 130
„ — (J. H. Aveling) . . . . x, 40
„ more frequent use of, as a means of lessening both maternal and fœtal mortality (P. H. Harper) . . . i, 142
„ ovum (F. C. Cory) . . . . . viii, 5
„ — improvement in the joint of (Heywood Smith) . . xxii, 46
„ — modification of (Heywood Smith) . . . xx, 170
„ for removal of an ovum or retained portion of placenta (J. Hickinbotham) . . . . . xxi, 22
„ on rotatory action in using the (William Stephenson) . xxii, 217
„ possible results of the use of; pulsating swelling beneath a gap or fracture of the right frontal eminence (G. E. Herman) xx, 190
„ "rat-trap" to aid in the removal of uterine growths, or as vulsella in ovariotomy (Heywood Smith) . . . xvi, 229
„ Tarnier's, modifications in (A. Wiltshire) . . . xix, 223
„ — — (A. W. Edis) . . . . . xx, 163
„ use of, typically indicated in a case of protracted labour (G. Roper) xx, 75
„ vulsellum, new axis-traction (R. Barnes) . . . xxv, 68
„ volsella, for the soft dilated cervix (R. Wise) . . xliii, 233
„ with a spring racket (W. Gayton) . . . vi, 249
„ with simple method of increasing its compressive power (J. Thorburn) . . . . . xxi, 162

FORCEPS (*continued*)—
„ and version, incarcerated ovarian dermoid ruptured during delivery by (H. R. Spencer) . . . . . xl, 331
FOREIGN BODY (hair-pin) in bladder of young girl (T. C. Hayes). xxxv, 185
„ in the vagina, removed after four years, and after-results (C. H. Carter and F. H. Daly) . . . . . xxii, 34
„ — large, for two years, perforating wall of bladder; its removal and closure of fistulous opening (C. H. Carter) . xxii, 38
FORMALIN, specimen of an early gestation in both horns of the uterus of a bitch, displaying the allantoid vessels in their natural colour preserved in (Amand Routh) . . xli, 5
Fothergill (W. E.), decidual uterine cast expelled after eight weeks' amenorrhœa, together with an ovum of about five days' growth . . . . . xliii, 162
Foulerton (A. G. R.), acute general gonococcic peritonitis . xlvii, 185
„ and W. F. Victor Bonney, primary infection of the puerperal uterus by *Diplococcus pneumoniæ* . . . xlv, 128
„ — an investigation into the causation of puerperal infections xlvii, 11
Fowler (Charles Owen), double monster of dicephalous type . xl, 119
„ and G. E. Herman, on the effect of ergot on the involution of the uterus . . . . . xxx, 85
Fox (W. Tilbury), phlegmasia dolens . . . ii, 201
„ pathological lesion of phlegmasia dolens . . . ii, 222
„ puerperal fever . . . . . iii, 368
„ vessels concerned in the production of phlegmasia dolens . iv, 144
„ imperforate rectum; attempt at relief by operation; death . iv, 195
„ influence of mother's health on the production of rickets . iv, 260
FRACTURE of cranium in a new-born child (S. W. Poole) . xx, 105
„ of the pelvis, with injury to the uterus in the sixth month of pregnancy; recovery; death occurring at a subsequent delivery (T. Fairbank). . . . . ix, 1
Freeman (H. L.), polypus uteri complicating labour removed by ligature two days after delivery. . . . v, 42
FRIABILITY of the placenta (J. Brunton) . . . xvii, 175
FROG, oviduct of, microscopical sections of (W. S. A. Griffith) . xxx, 196
FRONTAL BONE, depression of, in two infants (C. Godson) . xxiii, 32
FROZEN SECTIONS of a uterus at the tenth week of pregnancy showing hæmorrhages into the placenta, decidua reflexa and decidua vera, from a patient who died of heart disease (G. F. Blacker) . . . . . xlii, 235
Fulcher (Dr.), communicated by C. Godson, two cases of extra-uterine fœtation . . . . . xxii, 153
Fuller (H. Roxburgh), case of spurious labour . . xxvii, 326
FUNIS, abnormal umbilical (H. Williamson) . . . xliv, 141
„ umbilical knotted, and placenta (J. A. Tapson) . . xi, 242
„ — placenta, fœtus, and membranes (R. Wise) . xxxviii, 166
„ complex twistings of (M. Handfield-Jones) . . xxxi, 164
„ "cork-screw" (J. G. Westmacott) . . . xiii, 51
„ insertion of, and implantation of the placenta, the relation between (F. H. Champneys) . . . . xxix, 337
„ insertio velamentosa (G. M. Bluett) . . . xxix, 511
„ instrument for dividing (H. Smith) . . . xv, 86
„ knotted (J. B. Curgenven) . . . . xiii, 187

FUNIS (*continued*)—
„ knot in, causing death of fœtus (C. Godson) . . xxv, 66
„ — on, in a case in which the fœtus was born dead (W. Sankey) . . . . . iii, 413
„ prolapsed portion of, with complicated knot (H. Madge) . xii, 133
„ obliterated by twisting (A. Rasch) . . . x, 94
„ on the expression of the (J. Matthews Duncan) . . xxi, 302
„ presentations (H. G. Trend) . . . . x, 1
„ prolapse of, during labour (G. Roper) . . . xvii, 318
„ short, in a case of twins (J. Braxton Hicks) . . xxiii, 253
„ the shortness of, as a cause of obstruction to the natural progress of labour (J. Matthews Duncan) . . . xxiii, 243
„ thick gelatinous, illustrating the necessity for more than ordinary care in tying (W. F. Cleveland) . . . xxi, 313
„ tightly encircling left thigh of fœtus (T. Fitzpatrick) . x, 141
„ vascular (erectile) tumour in the sheath of, in a newborn infant (F. Lawton) . . . . vii, 210
„ see *Navel-ill, Umbilical cord.*

Fussell (E. F.), cauliflower excrescence of the uterus . . vi, 102

Galabin (A. L.), case of extra-uterine pregnancy in which a communication existed between the cyst and the uterus . xvii, 170
„ — *report* on ditto by committee (W. S. Playfair, John Williams, and A. L. Galabin) . . . . . xvii, 384
„ on the occurrence in normal labour of lateral obliquity of the fœtal head . . . . . xvii, 283
„ new form of pessary for treatment of anteversion or anteflexion . . . . . xviii, 176
„ two cases of pregnancy complicated by extensive malignant disease of the cervix uteri . . . . xviii, 239
„ case of Cæsarean section performed on account of cicatricial obliteration of the vagina . . . . xviii, 252
„ — — extensive malignant disease of the cervix uteri . xviii, 286
„ fœtus in which ascites was combined with distension of the bladder, necessitating embryotomy . . . xix, 119
„ — *report* on ditto by committee (John Williams and A. L. Galabin) . . . . . xix, 120
„ case of suppuration of the uterine cavity resulting from occlusion of the cervix . . . . . xix, 176
„ — *report* on ditto by committee (G. Roper and A. L. Galabin) xix, 177
„ a Zwancke's pessary, retained for six years, producing recto-vaginal and vesico-vaginal fistulæ with phosphatic calculi . xix, 201
„ forceps designed to allow the direction of traction to be precisely that of the axis of the pelvis where the centre of the head was situated . . . . xix, 227
„ on the choice of the leg which should be seized in version for presentation of the upper extremity . . . xix, 239
„ modified form of Peaslee's metrotome . . . xx, 53
„ two cancerous polypi, with microscopic sections . . xx, 82
„ myxoma of both ovaries, associated with leukæmia . . xx, 123
„ pessary for prolapse of the uterus . . . xx, 169
„ two cases of rupture of the vagina during labour . xx, 295
„ microscopic sections of a medullary sarcoma of the cervix . xx, 323
„ ovary of a healthy woman murdered by a stab which divided the femoral artery . . . . . xxi, 23

GALABIN (*continued*)—
„ a Greenhalgh's pessary removed with difficulty from the vagina . . . . . xxi, 49
„ origin of ovarian cystoma from Graafian follicles, and presence of limpid fluid in true ovarian cysts . . . xxi, 288
„ microscopic section of menstrual decidua passed on the first day of menstruation . . . . . xxi, 312
„ section from the anterior lip of the cervix uteri from a case of deep bilateral laceration with ectropion . . . xxi, 312
„ microscopic sections of the uterine mucous membrane in endometritis . . . . . xxii, 47
„ multiple vesical calculi, the sequel of prolapsus uteri . xxii, 106
„ pathological anatomy of erosions of the cervix uteri . . xxii, 156
„ ladies' sanitary towels . . . . . xxii, 188
„ case of pyometra, microscopic sections of the uterine wall . xxii, 239
„ microscopic sections from Clement Godson's case of ruptured tubal fœtation . . . . . xxii, 241, 242
„ for *John Bassett*, placenta from a case of triplets . . xxiii, 129
„ — abnormal attachment of placenta . . . xxiii, 130
„ case of extra-uterine, associated with intra-uterine fœtation, in which abdominal section was performed . . . xxiii, 141
„ histology of cancer of the body of the uterus . . xxiii, 161
„ case of pregnancy complicated by cancer of the cervix uteri, followed by pyæmia associated with symptoms simulating diphtheria . . . . . xxiii, 186
„ periodical discharge of membrane in cervical endometritis, microscopical sections of . . . . . xxiii, 207
„ for *Alfred Gillingham*, fibroid tumour of the uterus . . xxiv, 4
„ microscopic section of the septum in a doubtful case of double vagina . . . . . xxiv, 20
„ retention of menstrual fluid in one half of a double uterus . xxiv, 21
„ histological results of laceration of the cervix; microscopic sections shown . . . . . xxiv, 53
„ tumour of the placenta . . . xxiv, 241; xxvii, 107
„ the causation of lateral obliquity of the fœtal head . . xxv, 252
„ for *W. E. Fielden*, cyst removed from the vulva . . xxvi, 56
„ distension of uterus from partial obstruction of cervix . xxvii, 81
„ fibro-sarcoma of chorion . . . . xxvii, 107
„ for *Lewis Jones*, female twin monster . . . xxvii, 305
„ cancer (?) of body of uterus removed by enucleation . . xxviii, 4
„ myxo-fibroma of cervix uteri in a girl aged 17 . . xxviii, 178
„ retro-peritoneal cyst associated with solid malignant (?) intra-cystic growth . . . . . xxviii, 179
„ condition of placenta in uterus removed by Porro's operation . xxix, 98
„ two uteri removed by vaginal extirpation . . . xxix, 300
„ microscopical section of tube from an early tubal fœtation . xxx, 195
„ case of Porro's operation . . . . xxxi, 57
„ inaugural address as President . . . . xxxi, 88
„ annual address as President . . . . xxxii, 86
„ dermoid cyst . . . . . xxxiv, 441
„ fœtation in a rudimentary horn of uterus . . xxxvii, 225
„ improved sanitary towels . . . xxxvii, 227
„ œdematous fibroid tumour of uterus associated with pregnancy . . . . . xxxvii, 286
„ extra-uterine fœtation not primarily tubal. . . xxxviii, 91
„ intra-ligamentous gestation retained for twenty-one years xxxviii, 38
„ tubal gestation ruptured at the sixth week . xxxviii, 39

GALABIN (A. L.) (*continued*)—
„ ovarian tumour containing corpus luteum . . xxxviii, 101
„ uterine fibroid associated with carcinoma . . xxxviii, 102
„ myxo-sarcoma of urethra in a child . . xxxviii, 120
„ sarcoma of cervix uteri . . . xxxviii, 120
„ microscopic sections of tissue removed from the uterus xxxviii, 121
„ rapidly growing fibroid in a patient aged 63 . . xxxix, 229
„ tubal abortion . . . . . xli, 170
„ double tuberculous pyosalpinx with inter-communication of the tubes . . . . . xlii, 173
„ sarcoma of uterus . . . . . xliii, 226
„ subperitoneal fibro-myoma . . . . xliii, 225
„ papillomatous cyst of an accessory ovary . . . xliii, 267
„ partial vesicular degeneration of the placenta . . xlv, 100
„ fibroid tumour of the uterus with cancer . . . xlv, 102
„ three fibroid tumours of cervix uteri . . . xlv, 175
„ small round-celled sarcoma of endometrium . . xlv, 184
„ carneous mole retained *in utero* five months after death of embryo, showing proliferation of epithelium of villi as a syncytium forming reticulating processes . . . xlv, 240
„ vesicular mole showing syncytium derived from chorionic epithelium partially differentiated into cells . . xlv, 240
„ myxoma of fundus uteri following vesicular mole; ? a myxoma of chorionic villi engrafted upon uterus . . . xlv, 241
„ and THOMAS G. STEVENS, chorion-epithelioma . . xlv, 241
„ dermoid cyst of ovary with minute pedicle produced by torsion of mesovarium only . . . . xlvii, 331
„ tubal abortion produced by bimanual examination . . xlvii, 332
„ specimen of tubal mole associated with (?) sarcoma of the ovary of the same side . . . . xlviii, 19

GALACTAGOGUE, on the use of cotton-leaf tea as a, in Jamaica (Izett W. Anderson) . . . . . xxii, 31

GALACTORRHŒA, case of unilateral (R. A. Gibbons) . xxix, 59, 108
„ case of, during a first pregnancy (W. S. A. Griffith) . . xxxiv, 491

GALTON (J. H.), on the treatment of anteflexion of the uterus without intra-uterine stem . . . . xvi, 171
„ uterine fibroid . . . . . xxxvi, 318

GALVANO-CAUTERY KNIFE (H. R. Spencer) . . . xlvi, 353

GANGLION CERVICALE UTERI, the normal and pathological anatomy of (N. W. Jastreboff) . . . . xxiii, 266

GANGRENE of the bladder from retroversion of the gravid uterus (Ad. Rasch) . . . . . xxxi, 129
„ of an interstitial fibro-myoma of the uterus (C. J. Cullingworth) . . . . . xxxix, 281
„ of ovarian tumours from their axial rotation, successful ovariotomy in (Lawson Tait) . . . . xxii, 86
„ of the thigh during the seventh month of pregnancy (J. G. Swayne) . . . . . xxv, 215
„ spontaneous, of upper part of vagina, with vaginal portion of cervix uteri and base of bladder (G. E. Herman) . . xxix, 244
„ of the vulva, acute, in an adult (G. E. Herman) . . xxv, 141
„ idiopathic, of the uterus (Lawson Tait) . . . xxv, 248

GANGRENOUS FIBROID, uterus showing the effects of (J. Bland-Sutton) . . . . . xxxii, 171

GANT (F. J.), *post-mortem* examination of a woman at the full period of gestation and the first stage of natural labour; death by accidental hæmorrhage, chiefly internally . vi, 214

GARMENT, ladies', suspender, of elastic webbing (E. J. Tilt) . xvi, 202

GÄRTNER'S DUCT, on cases of associated parovarian and vaginal cysts, formed from a distended (Amand Routh) . . xxxvi, 152

GASTROGRAPH, on recording the fœtal movements by means of a (J. Braxton Hicks) . . . . . xxii, 134

GASTROTOMY, extra-uterine fibroid successfully removed by (C. H. F. Routh) . . . xvii, 216; xviii, 5, 145
„ for extra-uterine gestation in which the placenta never came away (J. Braithwaite) . . . . . xxviii, 33
„ for supposed extra-uterine gestation (A. Meadows) . . xv, 145
„ successfully performed in extra uterine pregnancy . . xv, 130
„ for removing the fœtus in extra-uterine gestation and the mode of dealing with the placenta (R. Barnes) . . xiv, 325
„ large conglomerate of colloid tumours removed by (R. Barnes) xvii, 216; xviii, 193

GAYTON (W.), forceps with a spring racket . . . vi, 249
„ case of monstrosity . . . . . vii, 56

GENERATIVE ORGANS, female, hypertrophy of lupus of the (J. Matthews Duncan) . . . . . xxvii, 230
„ — ulceration of lupus of the (J. Matthews Duncan) . . xxvii, 139
„ two cases of imperfectly developed internal, the patient in one case being an epileptic subject (C. Lockyer) . . xlviii, 75
„ see *Pudendum*.

GENGE (G. G.), five months' fœtus and placenta, from a case of twin pregnancy in which the second child was delivered alive at or near full term along with the dead fœtus . xxxviii, 5

GENITAL CANAL, cancerous disease of, in pregnancy, its treatment (G. E. Herman) . . . . . xx, 191

GENITAL ORGANS, two cases of congenital malformation of (H. Macnaughton-Jones) . . . . . xlii, 92

GENITO-URINARY ORGANS of a hermaphrodite (J. Chalmers) . xxiv, 239
„ spurious (J. Chalmers) . . . . . xxv, 162

GENITO-URINARY TRACT in a female fœtus, arrest of development in (Alban Doran) . . . . xxiii, 107
„ and the rectum, pelvic viscera showing congenital communication between (Alban Doran) . . . . xxii, 79

GERVIS (FRED. H.), report of a case of complete inversion of the uterus occurring immediately after labour . . xvii, 278

GERVIS (H.), variety of chronic pain in the back . . v, 76
„ distension of the uterus in a fœtus, impeding labour, with report on specimen . . . . . v, 284
„ distension of ureters, pelvis of kidney, etc., in an infant . vi, 221
„ rare form of monstrosity . . . . viii, 135
„ monstrosity, one of twins, the other well formed . . x, 113
„ double monster . . . . . x, 197
„ large polypus uteri . . . . . xi, 4
„ cases of retroversion of the gravid uterus . . xvi, 232, 255
„ specimen of retention of a pessary . . . xvii, 274
„ case of puerperal septicæmia . . . xviii, 160, 184

GERVIS (H.) (*continued*)—
„ case of double vagina and uterus . . . xix, 271
„ cystic disease of the fœtal kidney . . . xx, 84
„ modification of Hodge's pessary . . . xxiii, 33
„ case of transverse septum in the vagina . . . xxiv, 210
„ inaugural address as President . . . xxv, 47
„ specimens of myo-fibromata of the uterus . . . xxv, 108
„ submucous fibroid of the uterus . . . xxv, 161
„ annual address as President . . xxvi, 33; xxvii, 64
„ case of cystic degeneration of the cervix uteri . . xxvi, 144
„ pessaries made of glycerine and gelatine . . . xxviii, 163
„ drawings of microscopical sections of a uterine polypus showing ciliated epithelium . . . xxviii, 240
„ see *J. B. Hicks.*

GIANT CELLS in a section of the wall of an ovarian dermoid (H. Williamson) . . . . . xlvi, 299

GIBB (G. D.), case illustrating the fatal influence of grief during the puerperal state . . . . . i, 75
„ pelvic cellulitis after a first pregnancy, followed by suppuration at back and front parts of vagina . . . ii, 324
„ inflammatory disease of the skin of the head and upper part of the body of an eight months' fœtus, with exudation of plastic lymph . . . . . iii, 442

GIBBONS (HENRY), Cæsarean section . . . . xiii, 131

GIBBONS (R. A.), case of galactorrhœa (unilateral) . xxix, 59, 108
„ electrolysis in some chronic uterine affections, with illustrative cases . . . . . xxx, 242, 260, 265

GILES (ARTHUR E.), malformation of rectum and bladder, congenital absence of both kidneys and ureters, imperforate anus, absence of right hypogastric artery, and deformed feet xxxiv, 129
„ case of congenital diaphragmatic hernia . . . xxxiv, 132
„ on the lochia . . . . . xxxv, 190
„ the longings of pregnant women . . . . xxxv, 242
„ observations on the ætiology of the sickness of pregnancy . xxxv, 303
„ and R. J. PROBYN WILLIAMS, a case of exophthalmic fœtus . xxxvi, 174
„ temperature immediately after delivery in relation to the duration and other characteristics of labour . . xxxvi, 238
„ uterus didelphys, with observations on the clinical importance of this malformation . . . . xxxvii, 300
„ cyclical or wave theory of menstruation, with observations on the variations in pulse and temperature in relation to menstruation . . . . . xxxix, 115
„ molluscum fibrosum of the labium majus . . . xxxix, 231
„ and EWEN J. MACLEAN, two unusual cases of tubal gestation: the one causing chronic intestinal obstruction, and accompanied by a hæmatosalpinx of the non-gravid tube; the other simulating retroversion of the gravid uterus . . xxxix, 232
„ note on a case of fibro-myoma of the uterus in a patient aged 23, with remarks on enucleation and myomectomy . . xlii, 299
„ fibroma of the ovary . . . . . xliv, 360
„ extra-uterine pregnancy: death of fœtus at end of eighth month, and operation a month later . . . xlvii, 114

GILFORD (HASTINGS), uterine appendages of the left side showing evidences of the rupture of the sac of an ovarian pregnancy . xliii, 24

GILLINGHAM (ALFRED), see *Galabin, A. L.*

GLANDS of the Fallopian tubes, sections of (W. S. A. Griffith) . xxx, 195
„ — and their function (J. Bland-Sutton) . . xxx, 207; xxxii, 189
„ iliac, and uterus removed by abdominal hysterectomy for cancer of cervix (T. V. Dickinson) . . . xlviii, 15
„ lymphatic, of the uterus, the comparative anatomy of (G. Hoggan) . . . . . xxiii, 4
„ — chorio-epithelioma with secondary growths in vagina, kidney, pancreas, lungs, and (C. Lockyer) . . xlv, 245
„ — (iliac and lumbar), secondary deposits of deciduoma malignum *without* syncytium in (P. Horrocks) . . xlv, 243

GLAND, mammary, of new-born infant (C. N. Longridge) . xlix, 273

GLANDULAR STRUCTURE in the substance of a primary cancer of the Fallopian tube (Alban Doran) . . . xxx, 194

GLUTEUS MAXIMUS, remarks on fœtal retroflexion: report of a specimen showing origin of, from occipital bone (L. Remfry) xxxvi, 227

GLYCERINE, the effect of, on the quantity of secretions poured into the vagina (G. E. Herman) . . . . xxx, 452

GLYCOSURIA in a patient with gangrenous sarcoma of uterus removed by abdominal hysterectomy (W. W. H. Tate) . xliv, 165
„ of pregnancy, three cases of (W. H. B. Brook) . . xlviii, 192

Goddard (Eugene), successful case of ovariotomy during pregnancy, with remarks on the treatment of ovarian tumours complicating pregnancy . . . . . xiii, 275

Godfrey (B.), syphilitic disease of placenta . . xiv, 137, 211

Godson (Charles), see *Godson, Clement.*

Godson (Clement), twin abortion, one emaciated and the other without trace of head or upper extremity . . . xvi, 100
„ — *report* on ditto by committee (John Williams and Clement Godson) . . . . . xvi, 121
„ drawing of the breasts of a girl with dark crescentic pigmentation round both nipples . . . . xvii, 343
„ midwifery statistics of thirty-five years' practice from the records of Charles Godson . . . . xviii, 223
„ fœtus from a woman at term suffering from extensive epithelioma of the cervix . . . . . xix, 40
„ cases of inversion of the uterus, from notes by *W. H. Maberly* xix, 51
„ ring pessary of wood which had been worn for twenty-six years xix, 203
„ epithelial cancer of the uterus . . . . xx, 29
„ for *J. C. Eaton*, double monster, a case of conjoined twins . xx, 171
„ — — dissection of . . . . . xxi, 88
„ placenta to which the umbilical vessels were peculiarly distributed (insertio velamentosa) . . . . xx, 324
„ polypus removed from a woman aged 60 . . . xxi, 57
„ set of pocket instruments contained within an ordinary cylindrical speculum . . . . . xxi, 90
„ for *J. Kingston Barton*, rupture of Fallopian tube . . xxii, 2
„ — *report* on ditto by committee (John Williams, Clement Godson, and A. L. Galabin) . . . . xxii, 82
„ for *G. E. Yarrow*, double monster . . xxii, 73, 74
„ for *James Murphy*, double monster . . . xxii, 109
„ removal of fibrous outgrowth from the fundus uteri. . xxii, 111
„ large encephalocele . . . . . xxii, 131

GODSON (CLEMENT) (*continued*)—
„ uterus and appendages showing rupture of tubal fœtation . xxii, 186
„ — *report* on ditto by committee (John Williams, A. L. Galabin, and Clement Godson) . . . . xxii, 242
„ depression of the frontal bone in two infants . . xxiii, 32
„ for *John Dewar*, interstitial fibroid causing retroflexion . xxiii, 63
„ for *T. Hopcroft*, Fallopian gestation . . . xxiii, 109
„ Leiter's temperature regulator . . . . xxiii, 131
„ depression of child's head by forceps . . . xxiii, 161
„ Marshall's patent sectional feeding bottle . . . xxiii, 166
„ for *H. G. Cronk*, a malformed heart . . . xxiii, 178
„ umbilical cord in a state of cystic degeneration . . xxiii, 180
„ for *Arnold Thomson*, surgical pocket case . . . xxiii, 180
„ the treatment of spasmodic dysmenorrhœa and sterility by dilatation of the cervical canal with graduated metallic bougies, with notes of five successful cases xxiii, 277; xxiv, 6
„ uterus removed by Porro's operation . . . xxiv, 299
„ epithelioma of cervix, removed by écraseur wire during pregnancy without causing abortion . . . . xxv, 18
„ fœtus with placenta attached showing a knot in the umbilical cord . . . . . xxv, 66
„ myxomatous degeneration of uterine fibroids . . xxv, 140
„ vesical calculus . . . . . xxvi, 181
„ pessary for retroversion and prolapse . . . xxvi, 272
„ large fibrous polypus . . . . . xxvi, 328
„ cancerous cervix . . . . . xxvii, 6
„ female twin monster . . . . . xxviii, 68
„ case of extra-uterine fœtation . . . . xxix, 499
„ Auvard's nipple shield . . . . . xxx, 198
„ living female child with three lower limbs . . . xxxii, 132

GONORRHŒA, ætiology of (Frederick J. McCann) . xxxviii, 225

GOODHART (J. F.), see *Hicks, J. Braxton.*

GOW (W. J.), sarcoma of the uterus removed by vaginal hysterectomy . . . . . xxxii, 374
„ a note on vaginal secretion . . . . xxxvi, 52
„ on the relation of heart disease to menstruation . xxxvi, 126
„ uterus from a case of Porro's operation with intra-peritoneal treatment of the stump . . . . xxxix, 7
„ cystic intra-ligamentous myoma with double uterus . xl, 134

GRAAFIAN FOLLICLE in pre-menstrual life, fate of ovum and (T. G. Stevens) . . . . . xlv, 465
„ mounted specimens, showing the development and retrogressive changes in (W. Hunter) . . . . xl, 327
„ ovarian cystoma from (A. L. Galabin) . . . xxi, 288
„ hæmatocele from ruptured (W. Duncan) . . . xxviii, 210

GRACE (HENRY), Fallopian pregnancy . . . ii, 49
„ double uterus with simultaneous gestation . . iv, 138

GRANVILLE (A. B.), phenomena, facts, and calculations connected with the power and act of propagation in females of the industrial classes in the metropolis; derived from eleven years' experience of two lying-in institutions . . ii, 139

GRANVILLE (J. M.), application of extreme cold as an anodyne in the pain attendant on parturition . . . vi, 105

GRAPPLING IRON for use in hysterotomy (Heywood Smith) . xxii, 45

GRAVID UTERUS, see *Uterus*, gravid.

GRAY (ROBERT), separation of the greater portion of the cervix uteri during labour . . . . . xvi, 128

GREENE (W. T.), remarks in the discussion on puerperal fever xvii, 253, 260
„ double or dicotyledonous placenta . . . xviii, 68
„ synopsis of one thousand five hundred consecutive labours . xix, 204

GREENHALGH (R.), interstitial fœtation . . . . v, 154
„ treatment of mechanical dysmenorrhœa and sterility, with a description of a new metrotome . . . . v, 164
„ diseased cervix uteri . . . . . v, 199
„ hypertrophy of cervix removed by the wire-rope écraseur . vi, 75
„ amputation of cervix uteri . . . . . vi, 102
„ practical remarks upon the treatment of placenta prævia, with illustrative cases . . . . . vi, 140
„ and J. BRAXTON HICKS, report on tumour exhibited by Mr. Harper . . . . . vi, 181
„ pelvimeter . . . . . vi, 186
„ discussion of paper on placenta prævia . . . vi, 188
„ removal of polypus . . . . . vii, 25
„ new form of laminaria tent . . . . . vii, 72
„ extreme distortion of the pelvis; craniotomy; cephalotripsy; Cæsarean section . . . . . vii, 220
„ growth from cervix uteri . . . . . vii, 255
„ large fibrous polypus . . . . . vii, 256
„ comparative merits of the Cæsarean operation and craniotomy in cases of extreme distortion of the pelvis . . vii, 270
„ mechanical dysmenorrhœa . . . . viii, 142
„ medicated cotton wool . . . . . viii, 217
„ uterus after Cæsarean section . . . . ix, 241
„ hypertrophied nympha . . . . . x, 57
„ elastic spring pessary for retroversion of uterus . . x, 93
„ rupture of the uterus (?), death and decomposition of the fœtus, blood poisoning; puncture of the membranes; recovery of the patient . . . . . xi, 9
„ metrometer sound . . . . . xiii, 169

GRIEF, fatal influence of, during the puerperal state (G. D. GIBB) i, 75

GRIEVES (Mr.), fœtus with peculiar growth from the mouth xiv, 139, 210

GRIFFITH (G. DE G.), curious monstrosity . . . xi, 5
„ remarks in the discussion on puerperal fever . . xvii, 261
„ case of hæmatocephalus . . . . . xviii, 214

GRIFFITH (W. S. A.), uterus just before menstruation, with microscopic sections . . . . . xxiv, 138
„ perimetric abscess . . . . . xxiv, 299
„ notes of a specimen of anteflexion of the uterus . . xxv, 3
„ specimen of a recto-uterine perimetric abscess . . xxv, 18
„ fibrinous polypus . . . . . xxv, 165
„ oblique rachitic pelvis . . . . . xxv, 232
„ uterine cyst . . . . . xxvi, 229
„ pelvis deformed by mollities ossium . . . xxvi, 230
„ prolapsed adherent ovaries . . . . xxvi, 270
„ serous perimetritis . . . . . xxvii, 168
„ note of a specimen of pseudo-osteo-malacic pelvis of Naegele . xxvii, 186
„ broad ligament cyst with septa . . . . xxvii, 251
„ extra-uterine gestation . . . . . xxvii, 304
„ sarcoma of vagina and uterus, secondary deposits in lungs . xxviii, 38

GRIFFITH (W. S. A.) (*continued*):—
„ tuberculosis of Fallopian tube . . . . xxviii, 66
„ notes of a specimen of the oblique pelvis of Naegele . xxviii, 83, 84
„ myxo-carcinoma of abdominal wall and ovaries . . xxviii, 180
„ anterior perimetritis and anterior parametritis . . xxix, 147
„ tubo-ovarian cysts . . . . xxix, 273, 302
„ segment of uterus after Cæsarean section . . . xxix, 298
„ hæmatoma and hæmatosalpinx . . . . xxix, 397
„ pyometra . . . . . xxix, 398
„ specimen of tubo-ovarian cyst . . . . xxx, 3
„ specimen of cystic adenoma of the cervix . . . xxx, 4
„ parametritis dextra, purulent . . . . xxx, 5
„ hyperplasia of chorion stems with partial cystic degeneration (myxoma fibrosum of Virchow?) . . . xxx, 82
„ microscopical sections of a Fallopian tube showing glands . xxx, 195
„ — of the oviduct of the frog . . . . xxx, 196
„ sections of solid non-malignant tumours of the ovary and uterus . . . . . xxx, 302, 409
„ acephalous acardiac monster from the museum of St. Bartholomew's Hospital . . . . . xxxi, 2
„ anencephalic fœtus . . . . . xxxi, 134
„ case of retention of urine caused by pressure of a dermoid ovarian cyst . . . . . xxxi, 135
„ sections of uterus at different periods of the puerperium, showing complete absence of the alleged fatty changes . xxxi, 308
„ case of extra-uterine gestation, the sac being situated in the right broad ligament; pregnancy advanced to the early part of the fourth month . . . . . xxxiii, 126
„ case of obstructed labour, in which a large fibroma of the ovary occupying the pelvis was mistaken for the head of an extra-uterine fœtus . . . . . xxxiii, 140
„ specimen of double hydrosalpinx . . . . xxxiii, 158
„ on specimen of hæmatosalpinx, shown by W. S. Playfair . xxxiv, 467
„ case of galactorrhœa during a first pregnancy . . xxxiv, 491
„ case of abortion . . . . . xxxv, 37
„ spontaneous extrusion of a large uterine fibroid . . xxxv, 38
„ note on the importance of a decidual cast as evidence of extra-uterine gestation . . . . . xxxvi, 335
„ patient after symphysiotomy . . . . xxxvii, 13
„ and T. G. STEVENS, notes on the variation in height of the fundus uteri above the symphysis during the puerperium, the conditions which influence this, and the practical conclusions which may be drawn from such observations . xxxvii, 246
„ see *Stabb, A. F.*
„ and ARNOLD W. W. LEA, breech presentation with extended legs . . . . . xxxix, 13
„ and T. W. EDEN, notes of a case of puerperal eclampsia, with a description of a five weeks' ovum removed in a subsequent pregnancy . . . . . xli, 151
„ sarcoma of the uterus . . . . . xli, 232
„ primary solid carcinoma of the ovary . . . xlii, 34
„ squamous-celled epithelioma invading surrounding tissues like a columnar-celled variety . . . . xlii, 210
„ — — of the cervix uteri in a very early stage . . xlii, 210
„ person aged 26; uncertain sex . . . . xliii, 298
„ two cases of calcified uterine fibroids in elderly women removed by abdominal section . . . . . xlviii, 17

GRIFFITH (W. S. A.) (*continued*)—
„ and H. WILLIAMSON, fibro-myoma of the uterus undergoing sarcomatous change . . . . . xlviii, 22
— chorion-epithelioma complicated by hæmatometra . xlix, 241
GRIGG (W. C.), hydrocephalus . . . . xvi, 246
„ modification of Albert Smith's pessary by narrowing of the shaft . . . . . xvi, 247
„ rapid dilator, after Ellinger's . . . . xvi, 248
„ cyst (tubo-ovarian) . . . . . xxxiii, 75
„ double pyosalpinx with tubo-ovarian cysts . . xxxiii, 75
„ matted appendages . . . . . xxxiii, 75
„ pyosalpinx complicating pregnancy . . . xxxiii, 75
GROGONO (A. W.), see *Herman, G. E.*
GROVES (ERNEST W. HEY), pathology and treatment of puerperal eclampsia, with special reference to the use of saline transfusion (with notes of two cases) . . . xliii, 117
„ adjourned discussion on. . . . . xliii, 148
„ fibroid tumour of uterus which developed after both ovaries and tubes had been removed for independent disease (dermoid cyst) . . . . . xlv, 136
„ uterus affected with adeno-carcinoma of the body in an early stage, with microscopical sections . . . xlv, 138
„ new operation for the cure of vaginal cystocele . . xlvii, 65
„ co-existent intra- and extra-uterine pregnancy . . xlvii, 428
GRÜN (E. F.), supposed extra-uterine gestation with birth through uterus . . . . . xxvii, 226
„ — *report* on ditto by committee (G. E. Herman and Alban Doran) . . . . . xxvii, 306
"GUIDE-HOOK," a new obstetric instrument (S. Newham) . vi, 7
GYNÆCOLOGICAL PRACTICE, electrolysis in (W. E. Steavenson, Lovell Drage, R. A. Gibbons, and John Shaw) . xxx, 229—265
GYNÆCOLOGY in relation to surgery, inaugural address by Alban Doran . . . . . xli, 107
GYNÆCOMETER (J. H. Aveling) . . . . xiii, 265

HADDEN (JOHN), see *Wiltshire, Alfred.*
HÆMATEMESIS in a newly-born infant (H. C. Hodges) . xxxi, 365
HÆMATOMA and hæmatocele; a study of two cases of early tubal pregnancy (A. Doran) . . . . xlvi, 206
„ and hæmatosalpinx (W. S. A. Griffith) . . . xxix, 397
„ pelvic, following delivery (R. Boxall) . . . xxxi, 303
„ — or retro-uterine hæmatocele, with remarks—especially as to the source of the hæmorrhage (T. S. Beck) . . xiv, 260
HÆMATOMETRA, associated with a degenerating fibro-myoma, treated by supra-vaginal hysterectomy (W. A. Meredith) . xxix, 422
„ case of double uterus with double, and complete absence of the vagina (A. H. N. Lewers) . . . xxxviii, 327
„ complicating chorion-epithelioma (W. S. A. Griffith and H. Williamson) . . . . . xlix, 241
HÆMATOCELE and hæmatoma; a study of two cases of early tubal pregnancy (A. Doran) . . . . xlvi, 206
„ of doubtful origin (W. R. Rogers) . . . xvi, 177, 274
„ from ruptured Graafian follicle (Wm. Duncan) . . xxviii, 210

HÆMATOCELE (*continued*)—
„ treated by operation (John Phillips) . . . xxix, 384
„ intra-peritoneal (W. S. Playfair) . . . xxxi, 130, 162
„ — from rupture of a varicose vein (C. J. Cullingworth) . xxxi, 257
„ — bursting into the peritoneal cavity (R. Barnes) . . xiii, 191
„ "paratubal" (R. H. Bell) . . . . xliv, 322
„ — (W. S. Handley) . . . . . xliv, 325
„ pelvic, with special reference to its diagnosis and treatment (A. Meadows) . . . . . xiii, 140, 170
„ retro-uterine (Dr. Philip) . . . . x, 57
„ — with remarks on the source of the hæmorrhage (T. S. Beck) . . . . . xiv, 260
„ ruptured tube and three weeks' embryo from the sac of an old pelvic (C. J. Cullingworth) . . . xxxviii, 122
„ tubal mole with encysted (W. S. Handley). . . xliii, 255
„ uterine (H. Madge) . . . . . iii, 79
„ the result of malignant disease (W. S. Playfair) . . xxvi, 6
HÆMATOCEPHALUS, case of (G. de G. Griffith) . . xviii, 214
HÆMATOSALPINX and hæmatoma (W. S. A. Griffith) . . xxix, 397
„ (C. J. Cullingworth) . . . . . xxxi, 226
„ (E. Malins) . . . . . xxxiv, 466
„ in a chronically inflamed Fallopian tube (A. W. W. Lea) . xli, 140
„ double: suspected early tubal gestation on both sides (A. Doran) . . . . . xxxiii, 112
„ hydro- (G. Ernest Herman) . . . . xxxiii, 453
„ of the non-gravid tube, two unusual cases of tubal gestation: the one causing chronic intestinal obstruction and accompanied by; the other simulating retroversion of the gravid uterus (Arthur E. Giles and Ewen J. Maclean) . . xxxix, 232
„ an unusual case of (recurrent hæmatosalpinx) (R. L. Knaggs) xxxv, 213
„ uterine appendages showing a (Amand Routh) . . xl, 306
„ and small ovarian cyst (W. S. Playfair) . . xxxi, 130, 162
„ with papillomatous ovarian cyst (J. Knowsley Thornton) . xxvi, 4
„ with hæmorrhagic and cystic ovaries (A. D. Leith Napier) . xxxiv, 439
„ complicating ovarian tumour (John Phillips) . . xxviii, 89
„ and pyosalpinx (Wm. Duncan) . . . . xxxi, 332
„ on the opposite side to, and complicating, a ruptured tubal gestation (C. J. Cullingworth) . . . . xxxii, 273
„ ruptured tubal pregnancy with, of opposite side (A. H. N. Lewers) . . . . . xxxix, 189
„ from rupture of a varicose vein (C. J. Cullingworth) . xxxi, 257
„ see *Uterine Appendages.*

HÆMORRHAGE, accidental death by (F. J. Gant) . . vi, 214
„ accidental, placenta from a case of (R. D. Muir) . . xxxv, 338
„ concealed accidental, at the latter end of pregnancy and during labour (J. B. Hicks) . . . . ii, 53
„ fatal case of concealed accidental, occurring at the eighth month of pregnancy (R. Dunn) . . . . viii, 285
„ amputation of inverted uterus, by écraseur on account of (J. H. Davis). . . . . xiv, 104
„ in labour, internal and concealed, produced by early and entirely detached placenta (J. T. Mitchell) . . viii, 282
„ concealed accidental; fœtus, placenta, and membranes delivered entire (W. R. Dakin) . . . . xxxvi, 315
„ severe, concealed accidental, abdominal hysterectomy for (J. H. Targett) . . . . . xlvii, 147

HÆMORRHAGE (*continued*)—
„ fatal, from traumatic aneurysm of the uterine artery (W. G. Hewitt) . . . . . ix, 246
„ fatal in forty minutes (J. H. Houghton) . . . xi, 81
„ cerebral, rapidly fatal, in a case of pregnancy complicated with multiple fibroids (Wm. Duncan) . . . xxxii, 2
„ fatal umbilical, in an infant (W. G. Hewitt) . . vi, 65
„ fourteen years after oöphorectomy, calcified uterine fibromyoma removed piecemeal for (H. R. Spencer) . . xlix, 271
„ improved anti-hæmorrhagic case (R. Barnes) . . xii, 271
„ into the pelvis, uterus, and ovaries from a woman who had died from (Heywood Smith) . . . . xvii, 56
„ intra-peritoneal, chorio-endothelioma of uterus; hysterectomy; death (G. Bagot Ferguson) . . . . xlix, 57
„ intra-venous injection of saline solution in cases of severe (P. Horrocks) . . . . . xxxv, 430
„ placenta with (H. A. Des Vœux) . . xxxvii, 9
„ into the placenta, decidua reflexa, and decidua vera, from a patient who died of heart disease, frozen sections of a uterus at the tenth week of pregnancy showing (G. F. Blacker) . xlii, 235
„ placental, abortion showing recent (R. Wise) . . xl, 257
„ post-partum, cases of, in the Montreal University Lying-in Hospital (D. C. McCallum) . . . . xx, 40
„ — on plugging the uterus in severe cases of (A. H. N. Lewers) xxxii, 356
„ — on administering iron during pregnancy as a preventive of (J. Bassett) . . . . xvi, 111
„ — apparatus for injecting the uterus in cases of (J. B. Potter) xxi, 29
„ — the treatment of, by hypodermic injection of ergotinine (C. Chahbazian) . . . . . xxiv, 286
„ — case of central choroido-retinitis occurring after (H. Macnaughton-Jones) . . . . . xxxii, 134
„ — in a case of occurrence of pregnancy after the removal of an intra-uterine tumour (Wynn Williams) . . xvi, 183
„ — uterus of a woman who died from (G. E. Harman) . xx, 2
„ — uterus and adherent placenta from patient dying of (John Phillips) . . . . . xxxii, 195
„ — caused by peritoneal adhesions of the gravid uterus (W. G. Hewitt) . . . . . xi, 108
„ — Mr. de Berdt Hovell's uterine truss for arresting (R. Barnes) xiii, 129
„ — treatment by the intra-uterine injection of perchloride of iron (H. Smith) . . . . . xv, 44, 65
„ — distension of the bladder as a cause of (J. L. Earle) . v, 291
„ uterine, post-partum treatment of, with perchloride of iron (W. F. Cleveland) . . . . . xi, 242
„ after labour (R. Barnes) . . . . xi, 219
„ secondary puerperal (C. S. Redmond) . . . . xix, 258
„ due to retained placenta, supposed to be the placenta of a previous abortion (A. W. Williams) . . . viii, 317
„ during convalescence after an operation for extra-uterine fœtation between the third and fourth months of gestation (J. D. Malcolm) . . . . . xlv, 382
„ from the Fallopian tube without evidence of tubal gestation (Alban Doran) . . . . . xl, 180
„ in tubal gestation: incomplete tubal abortion; operation; recovery (A. C. Butler-Smythe) . . . . xl, 298
„ diffuse meningeal, in an infant after normal labour (A. W. Sikes) . . . . . xlv, 44

HÆMORRHAGE (*continued*)—
„ profuse, in a fibroid tumour of the uterus, wholly cervical, forming an abdominal tumour and characterised by profuse (J. S. Fairbairn) . . . . . xlv, 178
„ from retained placenta after abortion, terminating fatally (G. Lowe) . . . . . xii, 323
„ prolonged, after delivery and abortion, the relation between, and backward displacements of the uterus (G. E. Herman) xxxiv, 14
„ extensive, into the broad ligament in a broad ligament cyst with torsion of the pedicle (F. J. McCann) . . xlviii, 179
„ into the internal capsule in a case of ingravescent hemiplegia during pregnancy and parturition (P. Horrocks) . . xxxiii, 201
„ cystic ovary, the seat of (M. Handfield-Jones) . . xxxiii, 27
„ calcified, after the menopause in three cases of myomatous uteri (H. R. Spencer) . . . . . xlviii, 333
„ chronic retro-uterine, the effects of, in a case of tubal gestation (Alban Doran) . . . . . xxi, 169
„ uterine, and injection of perchloride of iron, uterus from a case of (R. Cory) . . . . . xxi, 51
„ — treatment of certain forms of, by means of the sponge tent, with reference to women residing in tropical climates (G. G. Bantock) . . . . . xiv, 84
„ — mucous membrane of the uterus of an infant suffering from (S. W. Wheaton) . . . . xxxiv, 190
„ from the uterine mucous membrane of an infant (C. H. James) . . . . . xxxii, 66
„ free, intra-peritoneal, in fibro-cystic tumour of the uterus, laceration on its surface (A. H. N. Lewers) . . xlvii, 261
„ source of, in pelvic hæmatoma or retro-uterine hæmatocele (T. S. Beck) . . . . . xiv, 260
„ transfusion of blood, its history and application in cases of severe (C. Waller) . . . . . i, 61
„ vaginal, during parturition, a diagnostic sign of (P. Budin) . xix, 232
„ see *Hæmatemesis.*
„ visceral, in stillborn children (Herbert R. Spencer) . . xxxiii, 203

HÆMORRHAGIC EFFUSION into an ovarian cyst due to twisting of the pedicle (R. Barnes) . . . . xxv, 160
„ — parametritis (J. Matthews Duncan) . . . xxix, 191

HEGEDORN'S SURGICAL NEEDLES and holder (G. G. Bantock) . xxvi, 271

HAILEY (HAMMETT), anencephalic fœtus . . . vii, 78

HAIR-PIN, extraction of, from the bladder of a female (P. Smith) x, 59
„ in bladder of young girl (T. C. Hayes) . . . xxxv, 115

HALL (ARCHIBALD), puerperal convulsions complicated with mania; apparent recovery; sudden decease . . iv, 222
„ monstrosity . . . . . ix, 271

HALLEY (A.), retention *in utero* of the greater portion of a dead fœtus for a period of four years . . . . ix, 90

HAND and arms, deformity of (J. Shortt) . . . vi, 205
„ and foot, deformity of, in a child (John Phillips) . . xxviii, 89

HANDFIELD-JONES (M.), Porro's operation . . . xxvii, 4
„ case of double-bodied uterus . . . . xxix, 146
„ fibro-sarcoma of the right ovary . . . . xxxi, 126
„ vaginal cysts . . . . . xxxi, 129

HANDFIELD-JONES (M.) (*continued*)—
„ complex twistings of the funis . . . . xxxi, 164
„ chorea in pregnancy . . . . xxxi, 243
„ cystic ovary, the seat of hæmorrhage . . . xxxiii, 27
„ supposed myxomatous degeneration of a fibroid . xxxiii, 461
„ acephalous acardiac fœtus . . . . xxxiv, 84
„ tubo-ovarian cyst . . . . xxxiv, 85
„ specimen of calcification occurring in a fibroid of the uterus . xxxv, 2
„ fibro-myoma of the broad ligament . . . xxxv, 239
„ fibroma of ovary . . . . xxxvi, 343
„ cancer of the body of the uterus . . . . xl, 34
„ Bossi's dilator . . . . xlv, 103
„ two specimens of extra-uterine fœtation . . . xlvi, 88
„ cancer and fibro-myoma coexisting in the body of the uterus. xlvi, 305
„ fibroid of the uterus with cystic degeneration of the surrounding tissues . . . . . xlvi, 307
„ fibroid and cancer in the same uterus . . . xlvii, 337
„ myxoma of the labium majus . . . . xlvii, 362
„ ovarian fibroma . . . . xlviii, 332

HANDLEY (W. S.), tubal mole with encysted hæmatocele . xliii, 255
„ on paratubal hæmatocele . . . . xliv, 325
„ (with CUTHBERT LOCKYER), solitary interstitial fibroid removed by abdominal myomectomy . . . xlv, 51
„ hydrosalpinx of an accessory Fallopian tube due to twisting of the pedicle . . . . . xlv, 157

HANKS (H.), united children or double monstrosity . . iii, 414

HANNAM (MISS), honorarium in recognition of services . . xlix, 136
„ pension to be given in lieu of honorarium . . . xlix, 276

HARDEY (ROBERT), special position and the obstetric binder as aids in the treatment of impeded parturition . . ii, 79
„ abnormal gestation . . . . . ii, 307
„ acephalo-cyclopean monstrosity . . . . iv, 213
„ three cases of retroversion of uterus . . . v, 267

HARLEY (G.), tubal pregnancy, with fibrous tumours of the uterus, which occurred in the practice of J. A. Magrath, M.D., Kingston, Jamaica . . . . . i, 101
„ and W. NEWMAN, fœtus retained *in utero* for some weeks after its death and decomposition . . . . ii, 251
„ and T. H. TANNER, report on a twin (?) abortion exhibited by Dr. Langmore . . . . . iv, 165
„ case in which air was expelled from the vagina . . iv, 173

HARPER (P. H.) the more frequent use of the forceps as a means of lessening both maternal and fœtal mortality . . i, 142
„ ovarian (?) tumour, with report by Drs. Greenhalgh and B. Hicks . . . . . vi, 181

HARRIS (A.), hydro-encephalocele . . . . vi, 115
„ membrane expelled from uterus a few days before delivery at full term . . . . . vii, 47
„ *report* on above by Drs. G. Hewitt and A. Meadows . vii, 48

HARRIS (Dr.), of Philadelphia, a refutation of the marvellous account given by Professor Gardien, of Paris, in 1866, to the effect that the Princess Pauline de Schwartzenburg was delivered of a living fœtus some time after she was burnt to death . . . . . xxii, 103

HARRIS (ROBERT P.), of Philadelphia, a plea for the practice of symphysiotomy, based upon its record for the past eight years . . . . . xxxvi, 117
„ Cæsarean section . . . . . xv, 166
HARRIS (W. H.), segment of large tumour (?) ovarian . . xv, 58
HARVEY (ROBERT), note on an acoustic sign heard after the death of the fœtus . . . . . xxi, 273
„ rupture of the uterus . . . . . xxvii, 190
„ *report* on ditto by committee (F. H. Champneys and Alban Doran) . . . . . xxvii, 228
HARVEY (SIDNEY), ruptured abdominal gestation cyst . . xxx, 2
„ *report* on ditto by committee (J. Braxton Hicks, Sidney Harvey, and W. S. A. Griffith) . . . . xxx, 166
HASLAM (W. D.), see *Paramore, Richard.*
HATHERLEY (N. C.), pelvic cellulitis after second pregnancy, followed by suppuration in left groin and left antero-superior femoral region . . . . . iii, 286
HAULTAIN (F. W. N.), uterus removed by vaginal hysterectomy, showing nodule of chorion-epithelioma . . . xlv, 242
HAYDON (N. J.), tubular fœtation with twins . . . . v, 75
„ extra-uterine fœtation in which two fœtuses were found in connection with the same tube . . . . v, 280
„ *report* on the specimen (W. T. Smith and J. B. Hicks) . v, 281
HAYES (T. C.), removal of a Hodge's lever pessary which had ulcerated into wall of vagina after being worn five years . xvi, 30
„ carcinomatous tumour originating in the broad ligament . xvi, 101
„ pelvic tumour regarded as cancerous, commencing in the outer ligamentous cellular tissue of the broad ligament . xvi, 102
„ *report* on ditto (Heywood Smith) . . . . xvi, 127
„ macerated os innominatum of case of malignant disease . xvi, 174
„ uterus and appendages from a patient who died from congenital heart disease . . . . . xvi, 174
„ fatty placenta from a patient who had in succession twelve still-born children, and who suffered from frequent hæmorrhages in her pregnancies . . . . . xvi, 175
„ uterus and appendages connected by adhesions to the large intestine . . . . . xvii, 45
„ placental polypus . . . . . xvii, 177
„ fatty placenta and a still-born fœtus from a syphilitic patient xvii, 275
„ for *B. White*, specimen of myxoma in a fœtus impeding delivery . . . . . xviii, 83
„ new form of tube for injecting the uterus after labour or abortion . . . . . xx, 58
„ uterus and appendages enveloped in a large amount of blood-clot and false membrane . . . . xx, 119
„ uterus and appendages in a case of cancer . . . xx, 293
„ anteflexed uterus . . . . xxii, 82; xxiii, 109
„ sub-peritoneal pedunculated fibroid tumour of the uterus xxxiii, 74
„ uterine appendages showing cystic growths and tubal dilatation . . . . . xxxiii, 4, 107
„ two sessile fibroid polypi . . . xxxiii, 6
„ an intra-uterine sessile polypus . . . xxxiii, 73
„ two dermoid cysts . . . . xxxiii, 389
„ large soft polypus . . . . xxxiii, 389
„ foreign body (hair-pin) in bladder of young girl . . xxxv, 185

HAYES (T. C.) (*continued*)—
„ soft fibroid tumour of uterus . . . . xxxv, 186
„ hydrosalpinx . . . . . xxxv, 410
„ dilated Fallopian tube and ovary . . . xxxvi, 185

HEAD, depression of child's, by forceps (Clement Godson) . xxiii, 161
„ antero-posterior positions of, as a cause of difficult labour (R. G. McKerron) . . . . . xli, 142
„ fœtal, showing furrowing from pressure against sacrum (G. Roper) . . . . . xxii, 84
„ — the causation of lateral obliquity of (A. L. Galabin) . xxv, 252
„ — plaster cast of (J. Brunton) . . . . xxiii, 206
„ depression of frontal bone of, the result of pressure from the sacral promontory (Clement Godson) . . . xxiii, 32

HEADS, locked, difficult labour from (H. Raynes) . . iv, 19

HEAPE (WALTER), the menstruation of *Semnopithecus entellus* . xxxvi, 213
„ menstruation and ovulation of monkeys and the human female . . . . . xl, 161

HEART, disease of, uterus and appendages from a patient who died of (T. C. Hayes) . . . . . xvi, 174
„ — on the relation of, to menstruation (W. J. Gow) . xxxvi, 126
„ — frozen sections of a uterus at the tenth week of pregnancy, showing hæmorrhages into the placenta, decidua reflexa, and decidua vera, from a patient who died of (G. F. Blacker) . xlii, 234
„ relations of organic affections of, to fibro-myoma of the uterus (T. Wilson) . . . . . xlii, 176
„ fatal embolism of right side of, nineteen days after delivery (G. Roper) . . . . . xxi, 74
„ escape of, into left pleural cavity, through incomplete pericardial sac (R. Boxall) . . . . xxviii, 209
„ malformed (H. Smith) . . . . . xii, 116
„ — (R. J. Probyn-Williams) . . . . xxxvi, 3
„ malformation of (Clement Godson) . . . xxiii, 178
„ from a case of puerperal septicæmia (Wm. Duncan) . xxxi, 202
„ and large vessels of a dicephalous fœtus (John Phillips) . xxix, 55
„ and lungs of an infant who died when 14 days old (A. W. Williams) . . . . . xi, 242
„ rupture of, in a still-born infant (C. N. Longridge) . . xlix, 214
„ sounds, fœtal, muscular susurrus in relation to (J. B. Hicks) xv, 187
„ univentricular, of child that lived 9 months (W. S. Playfair) . xii, 163
„ — by Dr. Elliot (A. Wiltshire) . . . . xii, 164
„ see *Valves*.

HEATH (W. LENTON), notes on the dissection of a malformed child (see vol. xxii, p. 237) . . . . xxiii, 195

HECKFORD (N.), medullary growth in vagina of infant . . x, 224

HELLIER (J. B.), deciduoma malignum (malignant hydatid mole) xlv, 242
„ abdominal pregnancy secondary to partial rupture of tubal gestation sac; abdominal section fifteen months after conception and eight months after death of fœtus . . xlv, 366
„ chorion-epithelioma . . . . . xlvii, 310
„ see *Targett, J. H.*

HELME (T. A.), deciduoma malignum . . . xlv, 243

HEMIPLEGIA occurring nine days after parturition; death; partial *post-mortem* examination (E. F. Scougal) . . xxx, 214

HEMIPLEGIA (*continued*)—
„ brain showing thromboses in the cerebral veins in a case of ingravescent (Peter Horrocks) . . . . xxxiii, 201

HERMAN (G. E.), uterus of a woman who died from post-partum hæmorrhage . . . . . xx, 2
„ unicorned uterus . . . . . xx, 60
„ bicorned uterus and double vagina . . . xx, 123
„ child showing one of the possible results of the use of forceps xx, 190
„ on the treatment of pregnancy complicated with cancerous disease of the genital canal . . . . xx, 191
„ missed abortion with slight cystic degeneration of the chorion xxii, 44
„ fibroid tumour of the vagina . . . . xxii, 44
„ specimen of apoplectic ovum . . . . xxii, 45
„ follicular hypertrophy of the cervix . . . xxii, 270
„ blighted and atrophied embryo . . . . xxiii, 204
„ — microscopical preparations from ditto . . . xxiii, 259
„ on the relation of anteflexion of the uterus to dysmenorrhœa xxiii, 209
„ uterine fibroid . . . . . xxiv, 52
„ on the relation between backward displacements of the uterus and painful menstruation . . . . xxiv, 161
„ hypertrophy of the placenta . . . . xxiv, 189
„ two cases of labour complicated with cancer of the cervix uteri . . . . . xxiv, 308
„ case of acute gangrene of the vulva in an adult, with remarks xxv, 141
„ inverted uterus . . . . . xxvii, 83
„ atrophy of chorion . . . . . xxvii, 195
„ chancre on the cervix uteri . . . . xxvii, 252
„ on the suppuration and discharge into mucous cavities of dermoid cysts of the pelvis . . . . xxvii, 254
„ on the production of the shape of the oblique pelvis of Naegele . . . . . xxviii, 6
„ fœtus and placenta of extra-uterine gestation, removed by abdominal section . . . . . xxviii, 141
„ note on one of the causes of difficulty in turning, with remarks on the practice of amputating the procident arm . . xxviii, 150
„ case of chronic abscess of the female urethra . . xxviii, 181
„ case of lupus stricture and atresia of the female urethra . xxviii, 267
„ stricture of the urethra in women . . . xxix, 27
„ and G. M. Bluett, microscopical sections of tumours of fœtal membranes . . . . . xxix, 243
„ — *report* on ditto by committee (A. L. Galabin, G. E. Herman, and Alban Doran . . . . . xxix, 512
„ spontaneous gangrene of upper part of vagina, with vaginal portion of cervix uteri and base of bladder . . xxix, 244
„ on delivery by the vagina in extra-uterine gestation . xxix, 429
„ case of eclampsia of pregnancy with observations on the state of the renal function . . . . . xxix, 517
„ case of Bright's disease during pregnancy . . xxix, 539
„ — sequel to ditto . . . . . xxx, 478
„ and C. OWEN FOWLER, on the effect of ergot on the involution of the uterus . . . . . xxx, 85
„ fœtus and placenta successfully removed in a case of tubal pregnancy . . . . . xxx, 123
„ inversion of the uterus by a gangrenous fibroid . . xxx, 226
„ on the effect of glycerine on the quantity of secretions poured into the vagina . . . . . xxx, 452

HERMAN (G. E.) (*continued*)—
„ contribution to the anatomy of the pelvic floor . . xxxi, 263
„ on the changes in the pelvic floor which accompany the slighter degrees of prolapse . . . . xxxi, 276
„ cases of puerperal eclampsia, especially illustrating the temperature and urine in this disease . xxxii, 17; xxxiii, 315
„ the change in size of the chest and abdomen during the lying-in period, and the effect of the binder upon them . . xxxii, 108
„ case of cancer of upper part of cervix extending into body of uterus; vaginal hysterectomy; recovery; recurrence of disease; death thirteen months afterwards . . xxxii, 137
„ specimens from a case of purulent senile endometritis . xxxii, 196
„ decidua vera and reflexa from a very early abortion . xxxii, 272
„ tubal gestation removed before rupture . . xxxii, 307
„ four cases of pregnancy with Bright's disease . xxxii, 320, 349
„ case of submucous fibroid presenting at the os uteri ten days after delivery; labour normal . . . . xxxiii, 30
„ cancer of the uterine body, illustrating the difficulty of diagnosis between this disease and senile endometritis . xxxiii, 31
„ five more cases of puerperal eclampsia, especially illustrating the temperature and urine in this disease . . xxxiii, 315
„ hydro-hæmatosalpinx . . . . . xxxiii, 453
„ hypertrophy of decidua . . . . . xxxiii, 456
„ ruptured uterus . . . . . xxxiii, 491
„ for *G. Mallack Bluett*, amorphous acardiac fœtus . . xxxiii, 493
„ on the relation between backward displacement of the uterus, sterility and abortion . . . . . xxxiii, 499
„ *report* on specimen of amorphous acardiac twin, shown by him on December 2nd, 1891 ('Transactions,' vol. xxxiii, p. 493) . . . . . xxxiv, 11
„ on the relation between backward displacements of the uterus and prolonged hæmorrhage after delivery and abortion . . . . . xxxiv, 14
„ on menstruation in cases of backward displacement of the uterus . . . . . xxxiv, 225
„ on the frequency of the local symptoms associated with backward displacement of the uterus . . . xxxv, 8
„ inaugural address as President . . . . xxxv, 111
„ six more cases of pregnancy and labour with Bright's disease . . . . . xxxvi, 9
„ for *A. W. Grogono*, acephalous acardiac fœtus . . xxxvi, 65
„ annual address as President . . . . xxxvi, 75
„ on the change in size of the cervical canal during menstruation . . . . . xxxvi, 250
„ annual address as President . . . xxxvii, 42
„ specimen of ectopic pregnancy going nearly to term in the peritoneal cavity, the placenta being attached to the top of the uterus . . . . . xxxix, 135
„ two cases in which life appeared to have been saved by anti-streptococcic serum . . . . . xli, 346
„ on subcutaneous symphysiotomy . . . . xlii, 282
„ sarcoma of the stomach . . . . xliii, 2
„ leukæmia and pregnancy . . . . xliii, 234
„ and H. Russell Andrews, contribution to the natural history of dysmenorrhœa . . . . . xliv, 371
„ introduction to a discussion on ventral fixation of the uterus and its alternatives . . . . . xlvii, 429

HERMAN (G. E.) (*continued*)—
„ a case showing (*a*) uterine contraction without retraction, (*b*) prolonged high temperature of nervous origin . xlviii, 204
„ see *Wilson, H. S.*
HERMAPHRODITISM, two cases of pseudo- (J. H. Targett) . xxxvi, 272
„ true unilateral, with ovotestis occurring in man, with a summary and criticism of the recorded cases of true hermaphroditism (G. F. Blacker and T. W. P. Lawrence) . xxxviii, 265
HERMAPHRODITE, spurious (Fancourt Barnes) . . xxiv, 188
„ (J. Chalmers) . . . . . xxv, 129, 162
„ four cases of, in one family (John Phillips) . . xxviii, 158
„ genito-urinary organs of (J. Chalmers) . . . xxiv, 239
HERNIA cerebri and hernia umbilicalis, with attachment of the fœtal membranes to the scalp (T. H. Tanner) . . vii, 109
„ ?, congenital, of the liver (A. Meadows) . . . ii, 199
„ diaphragmatic, in a new-born baby (C. N. Longridge) . xlix, 272
„ congenital diaphragmatic, three cases of (H. R. Spencer) . xxxii, 132
„ — — (H. R. Spencer) . . . . . xxxiii, 34
„ — — (A. E. Giles) . . . . . xxxiv, 132
„ — ventral, in a fœtal monster (J. Brunton) . . xxi, 118
„ umbilicalis congenita and spina bifida lumbo-sacralis (Amand Routh) . . . . . xxxv, 102
„ diaphragmatic, fœtus with (H. Smith) . . . xv, 162
„ double, case of congenital inguino-ovarian, two ovaries from (T. Chambers) . . . . xxi, 92, 256, 269
„ exomphalos, in which the gravid uterus formed the (G. C. P. Murray) . . . . . i, 77
„ of a fibro-myoma of the uterus (J. Knowsley Thornton) . xxv, 67
„ inguinal, of the right ovary, successfully removed (A. Meadows) . . . . . iii, 438
„ the relation of prolapse of the vagina to (A. Doran) . xxvi, 88
„ umbilical (J. Thompson) . . . . x, 9
HEWITT (W. GRAILY), new method of examination of the tumour in cases of suspected cystic disease of the ovary; with description of an instrument for effecting the same . . i, 55
„ hydatidiform or vesicular mole, its nature and mode of origin i, 249
„ — degeneration of the ovum . . . . ii, 112
„ enormous fibrous tumour connected with the uterus, in the practice of Dr. R. Uvedale West . . . ii, 240
„ unusual elongation of the fœtal head as a cause of difficulty in the application of the ordinary forceps, with a description of a modified form of instrument . . . iii, 180
„ polypus of the uterus, pendulous in the vagina, removed by the écraseur . . . . . iii, 350
„ abortion; retention of the ovum within the uterus and growth of membranes for a period of five months after the death of the fœtus . . . . . iii, 411
„ spina bifida . . . . . iv, 5
„ uterine douche as a therapeutic agent; with exhibition of a new instrument . . . . . iv, 27
„ fibrous polypus of the uterus . . . . v, 123
„ description of the conditions of the parts involved in Mr. Marshall's case of tubal gestation . . . v, 154
„ fatal umbilical hæmorrhage in an infant . . . vi, 65
„ apparatus for the performance of transfusion . . vi, 136
„ Sims' modification of Chassaignac's écraseur . . vi, 254

HEWITT (W. GRAILY) (*continued*)—
„ anteflexion of gravid uterus . . . . vii, 170
„ disease of the placenta . . . . viii, 137
„ uterus during menstruation . . . . viii, 220
„ menstruation during pregnancy . . . viii, 221
„ acephalous monstrosity; absence of abdominal covering . viii, 316
„ deciduous membrane . . . . ix, 55
„ pessary for anteflexion and version . . ix, 63
„ traumatic aneurysm of the uterine artery; fatal hæmorrhage ix, 246
„ puerperal fever in the British Lying-in Hospital, with remarks on the treatment of puerperal fever . . . x, 69
„ pessaries for flexions and displacements . . x, 223
„ inaugural address as President . . . . xi, 27
„ twins, together with secundines, from a case of hydrops amnii xi, 37
„ peritoneal adhesions of the gravid uterus as a cause of post-partum hæmorrhage . . . . . xi, 108
„ President's address . . . . . xii, 16
„ mass of hydatids expelled from uterus . . . xii, 135
„ hydatids of the uterus . . . . . xii, 237
„ President's address . . . . . xiii, 5
„ child, arm amputated *in utero* . . . . xiii, 94
„ vomiting of pregnancy, its causes and treatment . . xiii, 103
„ remarks in the discussion on puerperal fever . . xvii, 156
„ — in the discussion on the use of forceps . . xxi, 229
„ report on sixty-seven cases of uterine distorsion or displacement, treated during seven years at All Saints' Institution for ladies suffering from illness . . . xxii, 173, 188
„ and A. Q. SILCOCK, general and considerable congestive hypertrophy of the uterus with acute anteflexion and presence of an ovarian cyst . . . . . xxv, 131
„ and S. G. SHATTOCK, specimen of spondylolisthesis . xxvi, 149, 151
„ on the severe or so-called "uncontrollable" vomiting of pregnancy . . . . . xxvi, 273, 331
„ columnar epithelioma of cervix uteri, removed by écraseur . xxix, 510
„ the invalid's compendium . . . . xxx, 198
„ instruments for antiseptic irrigation in childbed . . xxxi, 202
„ case of abortion in which there occurred separate primary and complete expulsion of the unbroken amnion, enclosing a fœtus of about four months' gestation . . . xxxiii, 461
„ vote of condolence on death of . . . . xxxv, 336
„ see *Williams, A. W.*
HICKINBOTHAM (JAMES), case of rupture of the uterus . . xx, 96
„ forceps for removal of an ovum or retained portion of placenta xxi, 22
„ notes on a case of placenta prævia complicated by a large myoma . . . . . xxiii, 167
HICKMAN (WILLIAM), two cases of inversio uteri . . xix, 49
HICKS (H. T.) and J. H. TARGETT, two cases of malignant embryoma of the ovary. . . . . xlvii, 287
„ carcinoma of the body of the uterus, with secondary growth in both ovaries . . . . . xlviii, 196
„ primary embolic chorion-epithelioma of the vagina . . xlix, 224
HICKS (J. BRAXTON), concealed accidental hæmorrhage at the latter end of pregnancy and during labour . . ii, 53
„ new instrument for removal of uterine polypi . . iii, 346
„ five cases of vaginal closure . . . . iv, 228
„ combined external and internal version . . v, 219

Hicks (J. Braxton) *continued*—
„ combined external and internal version, appendix to ditto . v, 265
„ three cases of labour obstructed by abnormal condition of the fœtus, with some other points of interest . . v, 285
„ and H. Gervis, report on the neck-tumour of the fœtus obstructing labour . . . . . v, 290
„ anencephalous monster . . . . . vi, 226
„ inquiry into the best mode of delivering the fœtal head after perforation . . . . . vi, 263
„ two cases of face presentation in the mento-posterior position, with remarks . . . . . vii, 57
„ improvement on the mode of fastening the rope in an écraseur . . . . . vii, 71
„ a rare form of extra-uterine fœtation . . . vii, 95
„ — report on ditto by Drs. Barnes and Hicks . . vii, 100
„ large fibrous tumours of uterus; spontaneous sloughing; death from peritonitis . . . . . vii, 110
„ polypus weighing 2¼ lb. . . . . vii, 253
„ echinococcus discharged from the vagina . . viii, 109
„ the use of fused anhydrous sulphate of zinc to the canal of the cervix uteri . . . . . viii, 220
„ cephalotribe . . . . . viii, 275
„ pathology of puerperal eclampsia . . . . viii, 323
„ intermural fœtation . . . . . ix, 57
„ extra-uterine fœtation treated by abdominal section; recovery ix, 93
„ condition of the uterus in obstructed labour, and an enquiry as to what is intended by the terms "cessation of labour pains," "powerless labour," and "exhaustion." With appendix of quotations from other writers on the subject . ix, 207
„ Cæsarean section . . . x, 45; xi, 99; xx, 106
„ face presentation in which delivery was affected by the cephalotribe . . . . . x, 144
„ fœtus delivered by cephalotribe . . . . xi, 1
„ remarks on the cephalotribe . . . . xi, 43
„ Perrett's new feeding bottle . . . . xi, 169
„ pregnancy associated with ovarian cystic disease . . xi, 263
„ contribution to our knowledge of puerperal diseases, being a short report of eighty-nine cases, with remarks . . xii, 44
„ fibrous tumour of cervix, obstructing labour, removed by enucleation . . . . . xii, 273
„ inaugural address . . . . . xiii, 27
„ and J. J. Phillips, remarks on tables of mortality after obstetric operations . . . . . xiii, 55
„ contractions of the uterus throughout pregnancy, their physiological effects and their value in the diagnosis of pregnancy . . . . . xiii, 216
„ President's annual address . . . . xiv, 25
„ fibro-cystic disease of the uterus . . . . xiv, 66
„ anatomy of the human placenta . . . . xiv, 149
„ President's address . . . . . xv, 16
„ delivery by the forceps in face presentation in the mento-lateral position . . . . . xv, 39
„ cephalotripsy, with short remarks . . . xv, 41
„ note on the muscular susurrus in relation to the fœtal heart sounds . . . . . xv, 187
„ report of three cases of cephalotripsy (with two casts) . xvii, 49
„ remarks in the discussion on puerperal fever xvii, 108, 148, 195, 209

HICKS (J. BRAXTON) (*continued*)—
„ note on a dissection of a uterus, pregnant about three and a half months, the placenta being prævia and fibroids extensively developed in the walls of the uterus . . xvii, 298
„ the uterus of Harriet Lane referred to at the trial of Wainwright, with statistics of measurements of nulliparous and multiparous uteri . . . . . xviii, 70
„ and J. F. GOODHART, on the displacements of the uterus by the distension of the bladder, as shown by experiments on the dead body . . . . . xviii, 194
„ phantom employed for class purposes in midwifery . . xix, 231
„ for *F. Ogston*, unilateral uterus and solitary kidney with two ureters . . . . . xxi, 57
„ remarks in the discussion on the use of forceps . . xxi, 218
„ photographs of a dwarf upon whom Cæsarean section had been performed . . . . . xxi, 253
„ on recording the fœtal movements by means of a gastrograph xxii, 134
„ case of extra-uterine fœtation about the seventh month of pregnancy; urgent symptoms; removal of fœtus by abdominal section; death . . . . . xxii, 141
„ case of congenital abnormality of the uterus simulating retention of menses . . . . . xxii, 260
„ case of pregnancy with double uterus and vagina . . xxiii, 23
„ vertical septum in lower part of vagina impeding labour . xxiii, 24
„ twins, short funis in both . . . . xxiii, 253
„ on the behaviour of the uterus in puerperal eclampsia, as observed in two cases . . . . . xxv, 118
„ watch-spring Hodge pessaries . . . . xxx, 227
„ case of inversio uteri; reduction; recovery; remarks . xxxi, 340
„ a case showing the behaviour of the pregnant uterus in chorea . . . . . xxxiii, 486
„ further contribution to the clinical knowledge of puerperal diseases . . . . . xxxv, 412
„ on intermittent contractions of uterine fibromata and in pregnancy in relation to diagnosis . . . . xxxvi, 188
„ list of published writings, arranged chronologically (C. J. Cullingworth) . . . . . xl, 102
„ see *Smith, W. T.*

HIGH TENSION DISCHARGES, see *Electricity*.

HILLIARD (HARVEY), one-headed twin monster . . xxii, 3

HINE (S. D.), case of obstructed labour in which spontaneous version followed an unsuccessful attempt to deliver by the crotchet after craniotomy . . . . xxvii, 293

HINDS (FRANK) and JOHN D. S. NODES, fatal rupture of an aneurysm of the splenic artery immediately after labour . xlii, 305

HIP-JOINT, destructive inflammation of, in a puerperal woman (T. W. Nunn) . . . . . vi, 116

HIPS, congenital dislocation of both (S. W. Poole) . . xxii, 214

HISTOLOGY of cancer of the body of the uterus (A. L. Galabin) . xxiii, 161
„ of lupus, observations and remarks on (G. Thin) . . xxvii, 315

HISTORY, natural, of dysmenorrhœa (G. Ernest Herman and H. Russell Andrews) . . . . . xliv, 371

HODDER (E. M.), ovariotomy . . . . xii, 308

HODGE'S PESSARY, modification of (H. Gervis) . . xxiii, 33

HODGES (H. C.), notes on a case of hæmatemesis in a newly-born infant . . . . . xxxi, 365

HODGES (RICHARD), hysteria simulating in the most perfect degree natural labour . . . . . i, 339

„ spontaneous evolution of the fœtus *in utero*, the head changed for the feet . . . . . ii, 303

„ presentation of the right arm and shoulder; delivery by spontaneous evolution . . . . . iv, 140

HOGG (F. R.), deformed fœtus . . . . xiii, 243

„ — *report* on ditto (Drs. Aveling and Edis) . . xiii, 263

„ description of Military Lying-in Hospital, Woolwich . xiv, 35

HOGGAN (GEORGE), the structure of the decidua . . xvi, 228

„ diagrams and microscopic specimens illustrating the nature, cause, and treatment of membranous dysmenorrhœa . xvi, 250

„ the comparative anatomy of the lymphatics of the uterus . xxiii, 4

HOLMAN (C.), letter read in the discussion on puerperal fever . xvii, 218

HOOK, blunt, of Lazarewitch, considerably modified . . xviii, 190

HOPCROFT (THOMAS), see *Godson, Clement*.

HORNIBLOW (R. E. B.), monstrosity . . . . xii, 247

HORROCKS (P.), wooden ring pessary worn for six years, with the lumen entirely filled up by deposit . . . xxvi, 54

„ case of rupture of the uterus and vagina . . xxvi, 119, 260

„ placenta and membranes from a case of triplets . . xxvi, 160

„ dicephalous fœtus . . . . . xxvi, 326

„ malformed fœtus . . . . . xxvii, 131

„ two cases of imperforate rectum . . . . xxvii, 135

„ microscopic sections of cancer of the neck of the uterus . xxviii, 240

„ large tumour at the end of the spine, supposed spina bifida . xxix, 57

„ fibro-myoma from a case of Cæsarean section . . xxix, 98

„ specimen of chronic endometritis with microscopic sections . xxix, 298

„ irreducible inverted uterus with a fibro-myoma, removed by amputation . . . . . xxx, 196

„ — *report* on ditto by committee (Alban Doran and P. Horrocks) xxx, 228

„ rupture of uterus . . . . . xxxi, 228

„ multilocular ovarian cyst and fibroma (?) of the opposite ovary . . . . . xxxiii, 200

„ brain showing thromboses in the cerebral veins and hæmorrhage into the internal capsule in a case of ingravescent hemiplegia during pregnancy and parturition . . xxxiii, 201

„ cancerous uterus removed by vaginal hysterectomy . xxxiv, 85

„ asceptic instruments . . . . . xxxiv, 460

„ transfusion apparatus . . . . . xxxiv, 460

„ intra-venous injection of saline solution in cases of severe hæmorrhage . . . . . xxxv, 430

„ ovarian tumour with greatly enlarged Fallopian tube . xxxvi, 185

„ large fibroid tumour of the uterus . . . xxxvi, 193

„ fibroma (?) of the ovary . . . . xxxvi, 192

„ large sarcoma of the ovary . . . . xxxvi, 192

„ simple maieutic for the induction of miscarriage or premature labour . . . . . xxxviii, 168

„ fibro-myoma of the uterus with sarcomatous degeneration . xl, 178

„ large fibroid tumour of the uterus undergoing cystic degeneration . . . . . xl, 227

HORROCKS (P.) (*continued*)—
„ fibroid tumours of the uterus with great distension of the Fallopian tubes from tubercle . . . . . xlii, 166
„ pregnant uterus and fibroid tumour removed by abdominal hysterectomy . . . . . xlii, 242
„ inaugural address as President . . . . . xliii, 79
„ deciduoma malignum . . . . xliii, 109; xliii, 283
„ annual address as President . . . . xliv, 53
„ sarcoma of ovary . . . . . xliv, 94
„ tubercle of the uterus . . . . . xliv, 141
„ extra-uterine fœtation . . . . . xliv, 228
„ annual address as President . . . . xlv, 61
„ deciduoma malignum *without* syncytium; secondary deposits in vagina, lymphatic glands (iliac and lumbar), and lungs after hydatidiform degeneration of the chorion . . xlv, 243
„ twin monster . . . . . xlvi, 183
„ fibro-myoma of the uterus undergoing sarcomatous degeneration . . . . . xlvi, 184
„ see *Stevens, T. G.*

HOUGHTON (J. H.), hæmorrhage, fatal, in forty minutes . xi, 81

HUGHES (R.), history of a specimen of carneous mole . . xviii, 3
„ — *report* on ditto by committee (John Williams and W. B. Woodman) . . . . . xviii, 311

HUNT (W. A.), fœtal peritonitis (*in utero*) . . . ix, 15

HUNTER (WILLIAM), mounted specimens, showing the development and retrogressive changes in the Graafian follicle . xl, 327

HUNTLEY (R. E.), remarks in discussion on puerperal fever . xvii, 151

HURRY (J. B.), and J. MATTHEWS DUNCAN, on extensions or retroflexions of the fœtus, especially of the trunk, during pregnancy . . . . . xxvi, 206
„ case of symmetrical erysipelas, followed by premature labour; eclampsia on the nineteenth day post partum; no renal disease; recovery . . . . . xxxii, 309

HUTCHINSON (JONATHAN), remarks in the discussion on puerperal fever . . . . . xvii, 116
„ report on certain causes of death in ewes during and after parturition, with notes on "navel-ill" in lambs . . xviii, 88

HYDATID DISEASE, primary (echinococcus), of the Fallopian tube (T. W. Eden) . . . . . xlvi, 243
„ mole expelled from the uterus immediately after a living fœtus and its placenta, at about six months' gestation (J. H. Davis) . . . . . iii, 177
„ — the degenerated ovum of a twin conception (J. H. Davis) . iii, 177

HYDATIDIFORM DEGENERATION, early placenta with localised (R. Boxall) . . . . . xxxiii, 494
„ — see *Degeneration.*
„ mole (John Williams) . . . . . xvii, 2
„ — (Wm. Duncan) . . . . . xxv, 162, 233
„ — followed by chorio-epithelioma in a patient with bilateral ovarian cysts (J. D. Malcolm, R. H. Bell, and C. Lockyer) . xlv, 483
„ vesicles attached to a portion of placenta (A. W. Williams) . x, 93

HYDATIDS in the bony pelvis (J. H. Targett) . . . xxxvi, 344
„ of the mesentery (E. Malins) . . . . xxix, 245
„ in omentum, simulating an ovarian tumour (W. Newman) iv, 169

HYDATIDS (*continued*)—
„ of, or connected with, both ovaries, right broad ligament, liver, omentum, mesentery, and other parts (C. J. Cullingworth and H. H. Clutton) . . . . . xlvi, 254
„ expelled from uterus (W. G. Hewitt) . . . xii, 135
„ of the uterus (W. G. Hewitt) . . . . xii, 237
HYDRAMNION in cases of uniovial or homologous twins (T. Wilson) . . . . . xli, 235
HYDRAMNIOS, orbital tumour in a hydrocephalic female fœtus, with tumour of cheek, maldevelopment of neck, associated with (H. S. Stannus) . . . . . xliii, 304
HYDRENCEPHALOCELE, large, in a female child (W. F. Cleveland) . . . . . xxii, 157
HYDROCELE of the canal of Nück containing a portion of the left Fallopian tube (L. Remfry) . . . . xl, 6
„ ovarian, containing papillomata (J. Bland-Sutton) . . xxxiv, 215
HYDROCEPHALIC head of a child (B. Spaull) . . xiii, 214
HYDROCEPHALUS (W. C. Grigg) . . . . xvi, 246
„ associated, and spina bifida (W. Leishman) . . v, 198
„ association of spina bifida with (R. Barnes) . . v, 172
„ spina bifida followed by (D. Richards) . . . iv, 191
„ with spina bifida (R. J. Probyn-Williams) . . xxxvi, 4
„ as a complication of labour (J. S. Swayne) . . . xxix, 405
„ chronic (H. Madge) . . . . . v, 201
„ congenital, complicating labour (G. M. Bluett) . . xxix, 396
„ in fœtus which had presented by the breech and impeded delivery (A. W. Edis) . . . . . xvii, 302
„ with stumps of arms and deformity of lower limbs in a child (J. Matthews Duncan) . . . . . xxii, 237
„ — dissection of ditto (W. L. Heath) . . . xxiii, 195
HYDRO-ENCEPHALOCELE (A. Harris) . . . vi, 115
HYDRO-HÆMATOSALPINX (G. Ernest Herman) . . xxxiii, 453
HYDROMETRA in new-born children, congenital tumour at the internal os uteri causing (H. R. Spencer) . . . xl, 332
HYDRONEPHROSIS of the fœtal kidneys; impeding labour (H. M. Madge) . . . . . xi, 55
„ of the left kidney (J. Sidney Turner) . . xxxviii, 103
HYDROPERITONEUM, the relation of, to tubal disease (Alban Doran) . . . . . xxviii, 229, 243
HYDROSALPINX, removal of the uterine appendages for (Lawson Tait) . . . . . xxiv, 157
„ case of (G. G. Bantock) . . . . . xxv, 38
„ — (Lawson Tait) . . . . . xxv, 111
„ — (Wm. Duncan) . . . . . xxxi, 332
„ double (C. H. Carter) . . . . . xxx, 3
„ — (W. S. A. Griffith) . . . . . xxxiii, 158
„ — without salpingitis (A. Doran) . . . xli, 379
„ (T. C. Hayes) . . . . . xxxv, 410
„ undergoing spontaneous cure (J. Bland-Sutton) . . xxxiv, 9
„ and small ovarian cyst removed by anterior colpotomy (Amand Routh) . . . . . xxxviii, 185
„ of an accessory Fallopian tube due to twisting of the pedicle (W. S. Handley) . . . . . xlv, 157

HYDROSALPINX (*continued*)—
„ torsion of the pedicle in, and other morbid conditions of the Fallopian tube (R. H. Bell) . . . . xlvi, 152
„ — of (H. Williamson) . . . . . xlvii, 5
„ see *Uterine appendages.*

HYGIENE AND ANTISEPSIS in fever in childbed (R. Boxall) xxxii, 219, 275

HYMEN, imperforate, case of so-called (J. Matthews Duncan) . xxiv, 212
„ — with retained menstrual fluid (E. Copeman) . . x, 246
„ obstructed labour from the presence of (S. Palmer) . . iv, 211

HYPERPLASIA of chorion stems with partial cystic degeneration (myxoma fibrosum of Virchow ?) (W. S. A. Griffith) . xxx, 82

HYPERPYREXIA, puerperal, bed for cases of, requiring continuous application of cold (W. S. Playfair) . . xx, 171

HYPERTROPHY of the bladder in a fœtus (F. A. T. O'Meara) . xxix, 54
„ of the breasts (J. A. M. Moullin) . . . xxv, 212
„ symmetrical, of clitoris (J. H. Aveling) . . . xvi, 1
„ of decidua (G. E. Herman) . . . . xxx, 456
„ blighted ovum with fleshy decidual (J. Phillips) . . xxxiii, 35
„ Fallopian tubes and cystic ovaries (John Phillips) . . xxxi, 332
„ of labium (A. Meadows) . . . . viii, 257
„ of lupus of the female generative organs (J. Matthews Duncan) xxvii, 230
„ of left nympha (Fancourt Barnes) . . . xxv, 165
„ of the placenta (G. E. Herman) . . . . xxiv, 189
„ — and general dropsy in a fœtus (J. Bassett) . . xix, 261
„ of spleen and liver in a child, aged 9 (J. W. J. Oswald) . xviii, 191
„ of the uterus with anteflexion and presence of an ovarian cyst (Graily Hewitt and A. Q. Silcock) . . . xxv, 131
„ cancerous, of the body of the uterus (J. Matthews Duncan) . xx, 27
„ follicular, of the cervix uteri (G. E. Herman) . . xxii, 270

HYPOSPADIAS, extreme, in a child brought up at a girls' school as a female (H. C. Rose) . . . . xviii, 256

HYSTERECTOMY, uterus and appendages removed by (Heywood Smith) . . . . . xxi, 313; xxii, 3
„ in chorio-endothelioma of uterus; intra-peritoneal hæmorrhage; death (A. Doran for the late *Dr. G. Bagot Ferguson*) . xlix, 57
„ for removal of fibroid tumours of the uterus (G. G. Bantock) . xxvi, 119
„ for fibro-myomatous uterine tumours, on the advisability of removing the cervix in performing (J. D. Malcolm) . xlix, 148
„ for sarcoma of the uterus (Wm. Duncan) . . . xxxi, 2
„ abdominal, two cases of (Lawson Tait) . . . xxxiv, 199
„ — for cancer of cervix, uterus and iliac glands removed by (T. V. Dickinson) . . . . . xlviii, 15
„ — — associated with pregnancy (D. Drew) . . xlviii, 202
„ — for epithelioma of the cavity (J. Knowsley Thornton) . xxv, 9
„ — for the removal of fibroid of the uterus (G. G. Bantock) . xxiv, 301
„ — two cases of, for fibroids, complicated by pregnancy; with specimens (F. N. Boyd) . . . . xlvi, 106
„ — large œdematous fibroid of the uterus removed by (C. J. Cullingworth) . . . . . xxxv, 38
„ — fibroid tumours removed by (G. G. Bantock) . . xxv, 38
„ — for large fibroid tumour (J. Knowsley Thornton) . xxv, 163
„ — for removal of soft fibroid tumour of uterus (T. C. Hayes) xxxv, 186
„ — — gangrenous uterine fibroid (W. Duncan) . . xxxvi, 181
„ — case of locked fibroid treated by (W. A. Meredith) . xxx, 442

HYSTERECTOMY (*continued*)—
„ abdominal, Doyen's method, in case of large uterus with cervical fibroid (H. R. Spencer) . . . . xliii, 5
„ — for removal of a decomposing fibroid tumour with micrococci in its substance (S. W. Wheaton) . . . xxxiv, 187
„ — for removal of uterine fibroids and ovarian cysts (J. Knowsley Thornton) . . . . . xxvi, 55
„ — for fibroid obstructing labour, uterus removed at eight and a half months of gestation by (A. Routh) . . xliv, 41
„ — for severe concealed accidental hæmorrhage (J. H. Targett) xlvii, 147
„ — for removal of gangrenous sarcoma of uterus from a patient suffering from glycosuria (W. W. H. Tate). . . xliv, 165
„ — sloughing fibroid removed by (W. Duncan) . . xxxvii, 197
„ — fibroids removed by intra-abdominal (W. Duncan) . xxxix, 89
„ — for removal of fibroids and large fibro-cystic tumour (J. Knowsley Thornton) . . . . . xxvi, 3
„ — for removal of fibro-cystic disease (Heywood Smith) . xxvi, 58
„ — for fibro-cystic disease of the uterus (T. Chambers) xxii, 159, 187
„ — for removal of a large uterine fibro-myoma (J. Knowsley Thornton) . . . . . xxv, 67
„ — for removal of fibro-myoma of uterus (W. Walter) . xxvi, 326
„ — in a case of suppuration in fibro-myoma uteri following premature delivery (W. W. H. Tate) . . . xlix, 54
„ — for removal of vascular fibro-myoma of uterus and cystic tumours of ovaries (J. Knowsley Thornton) . . xxvi, 269
„ — case of hæmatometra associated with a degenerating fibro-myoma, treated by (W. A. Meredith) . . . xxix, 422
„ — in two cases of fibro-myoma of cervix (W. W. H. Tate) . xlv, 173
„ — for fibro-myoma of uterus projecting into the vagina (W. W. H. Tate) . . . . . xl, 159
„ — for œdematous subperitoneal fibro-myomata of uterus in right broad ligament (C. J. Cullingworth) . . xl, 302
„ — for myoma of the uterus: with brief notes of twenty-eight cases (J. Bland-Sutton) . . . . xxxix, 292
„ — ruptured uterus treated by (John Phillips) . . xxxix, 260
„ — ruptured uterus at term through scar of old Cæsarean section (J. H. Targett) . . . . . xlii, 242
„ — pregnant uterus and fibroid tumour removed by (P. Horrocks) xlii, 242
„ — total, and Cæsarean section for fibroids complicating labour near term in a patient who had recovered without operation from ruptured tubal pregnancy . . . . xlviii, 240
„ — total, for removal of a degenerated uterine fibroid (H. R. Spencer) . . . . . xlv, 378
„ — uterus with fibroid tumour undergoing mucoid change, successfully removed by, with intra-peritoneal treatment of the stump (A. H. N. Lewers) . . . . xlii, 94
„ — with intra-peritoneal treatment of the stump, with notes of eight cases (Harrison Cripps) . . . xxxviii, 41, 107
„ abdomino-vaginal, for removal of supposed myxo-sarcoma of uterus (Amand Routh) . . . . . xli, 367
„ combined vaginal and abdominal, for a pregnancy of four and a half months, complicated by cancer of the cervix (R. Sanderson) . . . . . xliii, 312
„ two fibromata removed by intra-peritoneal (H. Macnaughton-Jones) . . . . . xxxix, 321
intra-peritoneal, large multiple fibro-myoma removed by (A. D. Leith Napier) xxxiv, 159

HYSTERECTOMY (*continued*)—
„ intra-peritoneal, abdominal, uterus with submucous and interstitial myoma removed by (W. Duncan) . . xxxix, 290
„ — for removal of uterine fibroids (W. Duncan) . . xliii, 76
„ — in a case of contracted pelvis, uterus removed at full term by (W. Duncan) . . . . . xliii, 9
„ Cæsarean, three cases of Porro's operation, with intra-peritoneal treatment of the stump (H. R. Spencer) . xxxviii, 389
„ Porro-Cæsarean, with retro-peritoneal treatment of the stump in a case of fibroids obstructing labour; with remarks upon the relative advantages of the modern Porro operation over the Sänger-Cæsarean in most other cases requiring abdominal section (Amand Routh) . . . . xlii, 244
„ puerperal, uterus from a case of Porro's operation with intra-peritoneal treatment of the stump (W. J. Gow) . . xxxix, 7
„ abdominal, sub-total, for removal of an intra-ligamentous, fibro-cystic tumour of the uterus weighing about 30 lbs. (T. W. Eden and F. L. Provis) . . . . xlviii, 264
„ sub-total after-histories of sixty cases (A. Doran) . . xlvii, 363
„ supra-vaginal, monster of seventh month removed by (H. Macnaughton-Jones) . . . . . xlvii, 302
„ vaginal, two uteri removed by (A. L. Galabin) . . xxix, 300
„ — for cancer (W. S. Playfair) . . . . xxxi, 227
„ — four cases of, for cancer (C. J. Cullingworth) . xxxii, 136, 141, 174
„ — vaginal, note supplementary to a paper read before the Society on April 2nd, 1890, giving the subsequent history of the cases (C. J. Cullingworth) . . . . xxxv, 25
„ — for removal of cancerous uterus (W. Duncan) . . xxvi, 27
„ — for cancer of cervix extending into body of uterus (G. E. Herman) . . . . . xxxii, 137
„ — — supposed recurrence after (C. Hubert Roberts) . xlix, 114
„ — cancerous uterus removed by (P. Horrocks) . . xxxiv, 85
„ — for removal of cancerous uterus and parovarian cyst (A. Routh) . . . . . xxxvii, 8
„ — cancerous uterus removed by (Amand Routh) . . xxxiv, 87
„ — — (R. T. Rutherfoord) . . . . xxxiii, 28
„ — two uteri removed by, for cancer of the cervix, the disease being apparently at the same stage in each (A. H. N. Lewers) xxxviii, 164
„ — for carcinoma of the corpus uteri invading a myoma (J. M. Munro Kerr) . . . . . xlvii, 191
„ — carcinoma of the cervix complicating labour at term; Cæsarean section followed by (J. M. Munro Kerr) . xlvii, 194
„ — in a case of primary carcinoma of the body of the uterus (A. H. N. Lewers) . . . . . xxxvi, 374
„ — removal of three months' gravid uterus for squamous epithelioma of cervix by (W. Duncan) . . . xliv, 297
„ — after removal of large fibro-myoma of the cervix by enucleation (W. W. H. Tate) . . . . . xlii, 161
„ — for inversion (J. A. M. Moullin) . . . xxvi, 158
„ — in a case of irreducible inverted uterus with a fibro-myoma (P. Horrocks) . . . . xxx, 196, 228
„ — for malignant disease (F. A. Purcell) . . . xxvii, 5
„ — for primary malignant disease of the body (A. H. N. Lewers) . . . . . xxviii, 67, 206
„ — recovery in villous tumour of the body of the uterus in a woman, aged 84 (J. Bland-Sutton) . . . xlix, 46

HYSTERECTOMY (*continued*)—
„ vaginal, for procidentia (E. Malins) . . . xxvi, 148
„ — sarcoma of the uterus removed by (W. J. Gow) . . xxxii, 374
„ — for removal of sarcomatous tissue (W. R. Dakin) . . xxxii, 139
„ — case of primary sarcoma of the body of the uterus ("deciduoma malignum") in a patient, aged 24, treated by (A. H. N. Lewers) . . . . . xxxix, 246
„ — in the puerperium for sepsis due to suppuration of myoma (A. W. W. Lea) . . . . . xlvii, 1
„ — for primary tuberculosis of the cervix simulating cancer (A. H. N. Lewers) . . . . . xliv, 144
„ — for primary tuberculosis of the cervix uteri (W. H. B. Brook) xlv, 185
„ — for removal of uterus, showing nodule of chorio-epithelioma (F. W. N. Haultain) . . . . xlv, 242
„ — — fourteen days after the operation of curetting and steaming had been performed (G F. Blacker) . . xlv, 80
„ see *Extirpation, Porro's operation.*

HYSTERIA, excision of the clitoris as a cure for (T. H. Tanner) . viii, 360
„ simulating in the most perfect degree natural labour (R. Hodges) . . . . . i, 339

HYSTEROPEXY, two uteri with "fundal ligament" after (F. E. Taylor) . . . . . xlix, 265

HYSTEROTOME, new (J. H. Aveling) . . . vii, 155

HYSTEROTOMY, anterior, and anterior vaginal cœliotomy and replacement, with recovery, for complete inversion of seven months' duration after failure of elastic pressure with repositors (J. W. Taylor) . . . . xliv, 299
„ grappling iron for use in (Heywood Smith) . . xxii, 45
„ for removal of soft myoma of the uterus (J. H. Aveling) . xxvi, 270

ICTERUS NEONATORUM (A. W. Sikes) . . . xliv, 369

IDIOCY, two cases of (A. Wiltshire) . . . xviii, 280
„ in children, strong mental emotion during pregnancy as a cause of (Sir A. Mitchell) . . . . xxvi, 124
„ the obstetrical aspects of (J. L. Down) . . . xviii, 296

Ilott (H. J.), fœtus papyraceus . . . xxxvii, 7, 16

IMPACTION and rotation of a myomatous uterus (J. Bland-Sutton) . . . . . xli, 296

IMPERFORATE anus, in which the child lived upwards of ten weeks without relief from the bowel after two unsuccessful operations (W. F. Cleveland) . . . . ix, 203
„ anus, etc., congenital absence of nose, right palpebral fissure, and right ear (W. Duncan) . . . . xxxvii, 16
„ bowel; operation; death (A. Meadows) . . . vii, 53
„ hymen, case of so-called (J. Matthews Duncan) . . xxiv, 212
„ — with retained menstrual fluid (E. Copeman) . . x, 246
„ rectum; attempt at relief by operation; death (W. T. Fox) . iv, 195
„ — two cases of (P. Horrocks) . . . xxvii, 135
„ — and congenital prolapse of the uterus (H. R. Andrews) . xlii, 169
„ vagina, congenital, four cases, and one case of congenital phimosis occurring in the same family (H. Madge) . xi, 213

IMPREGNATION, effects of lactation on menstruation and (Leonard Remfry) . . . . xxxviii, 22

IMPREGNATION (*continued*)—
„ two cases involving the question of the site of (H. Cripps and H. Williamson) . . . . . xlvi, 89
INCANDESCENT CARBON LAMP, modification of Swan's, for gynæcological examinations and operations (J. H. Aveling) . xxiv, 301
INCARCERATION of the retro-displaced gravid uterus in three cases, and one of extra-uterine pregnancy simulating that condition (J. M. Munro Kerr) . . . . xlii, 146
INCISION, vaginal, for extraction of the fœtus in a case of ectopic (intra-ligamentous) gestation at the seventh month (A. Donald) . . . . . xli, 7
INCONTINENCE OF URINE, complete, cured by ventro-fixation of the uterus (H. Macnaughton-Jones) . . . xl, 226
INCUBATOR, Auvard's (J. Matthews Duncan) . . xxvi, 25
INDUCED CURRENT during parturition, on the benefits derived from (W. Kilner) . . . . . xxvi, 93
INDUCTION of abortion as a therapeutic measure (Sir W. O. Priestley) . . . . . xxii, 271
„ — performed in a patient labouring under cancerous disease of the uterus and rectum; with observations upon the justifiability of the operation in such cases and the best mode of performing it (F. W. Mackenzie) . . . i, 11
„ of premature labour in a case of distorted pelvis (J. H. Trouncer) . . . . . i, 236
„ — indications and operations for (R. Barnes) . . iii, 107
„ — on the methods adopted by Keiller and others for the (J. Watt Black) . . . . . xxxv, 95
„ of miscarriage of premature labour, a simple maieutic for (Peter Horrocks) . . . . xxxviii, 168
INDURATION, diffused subcutaneous, in an infant (A. L. Smith) xli, 103
INFANT, anatomy of, presenting some rare deformities (C. Singer) . . . . . xlvii, 250
„ newly born, cases of cholera in (J. C. Lucas) . . xxi, 250
„ remarkable development of (Dr. Cameron) . . xviii, 115
„ distension of vagina and uterus with muco-puriform fluid in an (W. McAdam Eccles) . . . . xxxiv, 250
„ of doubtful sex (W. F. Cleveland) . . . ix, 29
„ sagittal fontanelle in the heads of, at birth (A. W. W. Lea) . xl, 263
„ food (C. H. F. Routh) . . . . . ix, 29
„ newly born, case of hæmatemesis in (H. C. Hodges) . xxxi, 365
„ — acute contagious pemphigus in (G. J. Maguire) . xlv, 429
„ hæmorrhage from the uterine mucous membrane of (C. H. James) . . . . . xxxii, 66
„ diffused subcutaneous induration in (A. L. Smith) . . xli, 103
„ suffering from uterine hæmorrhage, mucous membrane of the uterus of (S. W. Wheaton) . . . xxxiv, 190
„ Mortality Committee, report of . . . . xi, 132
„ — concluding report . . . . . xii, 388
„ new-born, mammary gland of (C. N. Longridge) . . xlix, 273
„ still-born, dilated ureters in (C. N. Longridge) . . xlix, 215
„ — rupture of heart in (C. N. Longridge) . . xlix, 214
„ intra-uterine peritonitis in an (D. C. McCallum) . . xviii, 116
„ with prolapse of Meckel's diverticulum, forming an umbilical tumour (S. W. Wheaton) . . . . xxxiv, 184

INFANT (*continued*)—
„ retroflexion of the uterus in a new-born (Herbert R. Spencer) xxxiv, 25
„ rules for the general management of . . . xii, 395
„ fatal rupture of an ovarian cyst in an (Alban Doran) . xxxiv, 24
„ syphilis in (T. H. Tanner) . . . . i, 132
„ with marks and boy with webbed fingers (A. Wiltshire) . xii, 329

INFECTION, chronic septic, of the uterus and its appendages (A. Donald) . . . . . xlix, 6
„ puerperal, investigation into the causation of (A. G. R. Foulerton and V. Bonney) . . . . . xlvii, 11
„ secondary, of the perivascular lymphatics of the uterine wall, to bilateral primary tuberculous salpingitis (C. Lockyer) . xlix, 141
„ of the cyst five days after labour in ovarian cystoma complicating pregnancy (H. Macnaughton-Jones) . . xlii, 140

INFECTIVE DISEASES and pyæmia, discussion on the relation of puerperal fever to the . . . xvii, 90, 131, 178, 217

INFLAMMATION of the breast and milk abscess; with analysis of 72 cases (T. W. Nunn) . . . . . iii, 197
„ of the Fallopian tube, on closure of the ostium in (Alban Doran) . . . . . xxxi, 344
„ of lupus of the pudendum (J. Matthews Duncan) . . xxvii, 310
„ three cases of pelvic, attended with abscess of the ovary, with clinical remarks (C. J. Cullingworth) . . xxxvi, 277
„ uterine, diagnosis of the least known varieties of (E. J. Tilt) xiii, 197
„ chronic papillary, of the vulva (Sir W. O. Priestley) . xxvi, 156

INFLUENZA POISON, note on the effect of the, upon the lying-in woman (A. W. Addinsell) . . . . xxxv, 333

INHALER for chloroform alone or with alcohol or ether (H. W. Liddard) . . . . . xvi, 88

INHIBITION OF THE UTERUS (J. Matthews Duncan) . xxviii, 91

INJECTION of saline fluid, transfusion bottle, etc., for (H. R. Spencer) . . . . . xxxv, 428
„ intra-venous, of saline solution in cases of severe hæmorrhage (P. Horrocks) . . . . . xxxv, 430
„ vaginal, simple instrument for (A. Rasch) . . vi, 224

INJECTION TUBE, glass (R. Barnes) . . . xxvi, 232

INJURY, intra-uterine, on the head of a new-born child (W. O. Priestley) . . . . . i, 60

INSANITY in a case of deficient development of the uterus, atresia of the os externum, and atrophy of the ovaries (A. Doran) . . . . . xxi, 253
„ puerperal, cases of, in the Montreal University Lying-in Hospital (D. C. McCallum) . . . . xx, 46
„ — (Robert Jones) . . . . . xlv, 2

INSERTIO VELAMENTOSA, placenta to which the umbilical vessels were peculiarly distributed (C. Godson) . . xx, 324
„ specimen of (G. M. Bluett) . . . . xxix, 511

INSTRUMENTS, aseptic (P. Horrocks) . . . xxxiv, 460
„ for the operations of atresia vaginæ and vesico-vaginal fistula (N. Bozeman) . . . . . xix, 96
„ for dividing funis (H. Smith) . . . . xv, 86
„ blunt-pointed hook, crooked trephine, cranioclast (C. Braun) xv, 58

INSTRUMENTS (*continued*)—
„ pocket, set contained within an ordinary cylindrical speculum (C. Godson) . . . . . xxi, 90
„ received from J. Lazarewitch (A. Meadows) . . xi, 78
INSUFFLATOR, vaginal and uterine (H. Macnaughton-Jones) xxxvii, 81
INTERMENSTRUAL PAIN (Mittelschmerz) (A. W. Addinsell) . xl, 137
INTESTINE, large, uterus and appendages connected by adhesions to (T. C. Hayes) . . . . . xvii, 45
„ supposed invagination of, in a child (T. Ballard) . . i, 137
„ complete obliteration of the canal of the small, by fœtal peritonitis (R. Druitt) . . . . . ii, 135
„ death from obstruction of (J. Knowsley Thornton) . . xxi, 163
„ chronic obstruction of, caused by an unusual case of tubal gestation (A. E. Giles and E. J. Maclean) . . xxxix, 232
„ double obstruction of, following ovariotomy (J. H. Targett) . xl, 175
„ three cases of obstruction of, following operations for fibroid tumour of uterus, with special reference to the choice of operation (W. W. H. Tate) . . . . xlvi, 391
„ small, taken from an infant (G. Roper) . . . xx, 35
„ — loop of, found adherent to the pedicle six months after ovariotomy (H. J. Paterson) . . . xlvii, 316
„ volvulus in a fœtus (R. D. Maxwell) . . . xlviii, 277
INTRA-MURAL TUMOURS, see *Tumours*.
INTUSSUSCEPTION, ileo-cæcal, in an infant of eight months (H. M. Madge) . . . . . xvi, 219
INVAGINATION, supposed, of the intestine in a child aged 20 months successfully treated (T. Ballard) . . i, 137
INVOLUTION OF THE UTERUS in the absence of the ovaries (John Williams) . . . . . xxvi, 203
„ the effect of ergot on (G. E. Herman and C. O. Fowler) . xxx, 85
IRON, the administration of, during pregnancy as a preventive of post-partum hæmorrhage (J. Bassett) . . xvi, 111
„ apparatus for injecting, in post-partum hæmorrhage (W. F. Cleveland) . . . . . xi, 242
„ perchloride of, case of use of saturated solution of, in post-partum hæmorrhage (G. E. Herman) . . . xx, 2
„ — intra-uterine injection of, for post-partum hæmorrhage (H. Smith) . . . . . xv, 44, 65
„ — or iodine, tubes for injection of, into uterus (F. Barnes) . xx, 60
„ — injection, in a case of severe uterine hæmorrhage (R. Cory) xxi, 51
„ sesquichloride of, in puerperal fever complicated with diphtheria (R. Druitt) . . . . . iii, 30
„ salts in anæmia complicated with pregnancy (W. B Woodman) . . . . . xii, 33
IRRIGATION, antiseptic, in childbed, instruments for (Graily Hewitt) . . . . . xxxi, 202
„ sublimate, mercurialism in lying-in women undergoing (W. R. Dakin) . . . . . xxviii, 281
IRRIGATOR, marine vaginal (H. Smith) . . xiii, 190

JACKSON (J.), midwifery in the East ii, 37
„ see *Spencer, Herbert R.*
JÄGER (HAROLD), see *Phillips, John.*

JALLAND (R.), vaginal thrombus . . . . xiv, 43
JAMES (C. H.), uterus and appendages of an infant; hæmorrhage from the uterine mucous membrane . . . xxxii, 66
JAMES (W. CULVER), anencephaloid monster . . . xxii, 241
JASTREBOFF (N. W.), on the normal and pathological anatomy of the ganglion cervicale uteri . . . . xxiii, 266
JAY (F. F.), double monstrosity . . . . vi, 222
JEJUNUM and ovaries (Wm. Duncan) . . . xxx, 82
JENNINGS (C. E.), new cephalotribe . . . . xxiv, 238
„ transfusion apparatus . . . . xliii, 146
JESSOP (Thomas R.), case of extra-uterine gestation; removal of living fœtus by abdominal section; recovery of both mother and child . . . . . xviii, 261
JOHNSON (DAVID), deformed fœtus, with placenta adherent to it, intestines uncovered and presenting, with description of the delivery . . . . . xiii, 53
JOINTS, enormous enlargement of, in an infant aged five months (A. Wiltshire) . . . . . xx, 84
JONES (EDWARD), anencephalous fœtus with spina bifida . xi, 209
JONES (H. MACNAUGHTON), case of central choroido-retinitis occurring after labour and post-partum hæmorrhage . xxxii, 134
„ vaginal and uterine polyptome . . . xxxvii, 80
„ vaginal and uterine insufflator . . . xxxvii, 81
„ vaginal and uterine stem . . . xxxvii, 80
„ self-retaining glass retractors . . . xxxviii, 345
„ note on the ætiology of eclampsia . . . xxxix, 12
„ case of double pyosalpinx with enlarged bladder and secondary renal complication . . . xxxix, 319
„ two fibromata removed by intra-peritoneal hysterectomy . xxxix, 321
JONES (LEWIS), see *Galabin, A. L.*
JONES (ROBERT), puerperal insanity . . . xlv, 2
JONES (SYDNEY), for *Lawson Tait*, tubal fœtation removed by abdominal section . . . . . xxvi, 268
JONES (T. EYTON), vesico-vaginal and recto-vaginal fistula . xv, 185
JORDAN (W. ROSS), fœtus and placenta in extra-uterine fœtation xv, 124
„ extra-uterine pregnancy; gastrotomy successfully performed xv, 130
„ on a new pessary and intra-uterine stem for the relief of flexions and displacements of the uterus . . xvi, 125
JUNKER (F. E.), instrument for local applications to uterus . xii, 244

KEITH (Arthur), anatomy and nature of two acardiac acephalic fœtuses . . . . . xlii, 99
KELSON (W. H.) (introduced by Alban Doran), acardiacus acephalus . . . . . xxxiii, 195
KERR (J. M. MUNRO), three cases of incarceration of the retro-displaced gravid uterus, and one of extra-uterine pregnancy simulating that condition . . . . xlii, 146
„ dermoid cyst of ovary obstructing labour; displacement of the tumour from the true pelvis and extraction of the child with forceps; removal of tumour five weeks later; recovery xliii, 145

KERR (J. M. MUNRO) (*continued*)—
„ small fibroma uteri showing sarcomatous changes . . xliv, 129
„ fibro-myoma of the vagina . . . . xliv, 130
„ chorion-epithelioma . . . . . xlv, 244
„ certain details regarding the operation of Cæsarean section in cases of contracted pelvis, based upon a series of thirty cases . . . . . xlvi, 309
„ carcinoma of the corpus uteri invading a myoma; hysterectomy . . . . . xlvii, 191
„ carcinoma of the cervix complicating labour at term; Cæsarean section, followed by vaginal hysterectomy . xlvii, 194
KESTEVEN (W. H.), see *Barnes, Robert.*
KIDD (CHARLES), value of anæsthetic aids in midwifery . ii, 340
„ further observations on the use of anæsthetics in midwifery v, 125
KIDD (GEORGE), remarks in the discussion on the use of forceps xxi, 141
KIDD (G. H.), cephalotribe . . . . xii, 1
KIDNEYS (G. C. P. Murray) . . . . viii, 5
KIDNEY, accessory adrenal bodies in the broad ligaments (J. H. Targett) . . . . . xxxix, 157
„ adrenal tumour of, malignant vaginal polypus secondary to (A. Doran) . . . . . xlix, 182
„ chorio-epithelioma with secondary growths in (C. Lockyer) . xlv, 245
„ fœtal cystic disease of (H. Gervis) . . . xx, 84
„ from a case of eclampsia (L. Cutler) . . . xxxvi, 176
„ function of, in a case of eclampsia of pregnancy (G. E. Herman) . . . . . xxix, 517
„ hydronephrosis of the left (J. Sidney Turner) . xxxviii, 103
„ microscopical sections of, from a fatal case of puerperal eclampsia (H. R. Andrews) . . . . xliii, 114
„ pelvis of, and ureters in an infant, distension of (H. Gervis) . vi, 221
„ fatal wasting of, in a case of prolapsus uteri (J. J. Phillips) . xii, 276
„ double pyosalpinx with enlarged bladder and secondary complication of (H. Macnaughton-Jones) . . xxxix, 319
„ uterus and rectum from a woman who died of uræmia (Wm. Duncan) . . . . . xxxi, 255
„ and ureters with uterus, from a case of Cæsarean section (Wm. Duncan) . . . . . xxxiv, 127
„ — congenital absence of (A. E. Giles) . . . xxxiv, 129
„ solitary, with two ureters (J. Braxton Hicks) . . xxi, 57
KILNER (WALTER), upon the benefits derived from the induced current during parturition . . . . xxvi, 93
KING'S COLLEGE HOSPITAL, history of the Florence Nightingale Lying-in Ward (C. C. Rowling) . . . . x, 50
KNAGGS (R. LAWFORD), an unusual case of hæmatosalpinx [recurrent hæmatosalpinx] . . . . . xxxv, 213
KNITTING-NEEDLE used to procure abortion (W. Duncan) . xxxiv, 223
KNOT ON FUNIS in a case in which the fœtus was born dead (W. Sankey) . . . . . iii, 418
KONRÁD (MARK), prolapsus of the female genital organs . xiii, 251
KYPHOTIC PELVIS, description of a, with remarks on Breisky's description (F. H. Champneys) . . . . xxiv, 242
„ the obstetrics of (F. H. Champneys) . xxv, 166; xxviii, 253
KURZ NEEDLE-HOLDER (H. R. Spencer) . . . xlv, 51

LABIA MINORA, cysts from (A. Wiltshire) . . . xxiii, 206
LABIUM, adenoma of (H. Williamson) . . . xlviii, 235
„ angioma of (J. Matthews Duncan) . . . xxvi, 118
„ fibro-cellular tumour of (J. B. Potter) . . xxvi, 228
„ hypertrophy of (A. Meadows) . . . viii, 257
„ lipoma removed from the left (C. H. Carter) . xxxii, 6
LABIUM MAJUS, fibroid tissue formed around a needle and removed from the left (H. Briggs) . . . xlix, 223
„ — molluscum fibrosum of (A. E. Giles) . . xxxix, 231
„ — myxoma of (M. Handfield-Jones) . . . xlvii, 362
LABOUR, see *Parturition*.
LACERATION of the cervix, histological results of (A. L. Galabin) xxiv, 53
„ of the integument of the fœtus occurring during delivery (R. K. Peirce) . . . . . vii, 74
„ of the uterus (T. Radford) . . . . viii, 150
„ of the vagina in labour (J. Matthews Duncan) . . xxxi, 236
LACTATION, effects of, on menstruation and impregnation (L. Remfry) . . . . . xxxviii, 22
LALLEMAND'S PORTE-CAUSTIQUE, modification of (R. Barnes) xiii, 96
LAMBS, notes on "navel-ill" in (J. Hutchinson) . . xviii, 88
LAMINARIA spiralis, uterine tent (R. Greenhalgh) . . vii, 72
„ tents, the use of (W. Sinclair) . . . xlviii, 185
LAMP, modification of Swan's incandescent carbon, for gynæcological examinations and operations (J. H. Aveling) . xxiv, 304
LANE (W. ARBUTHNOT), what are the chief factors which determine the differences which exist in the form of the male and female pelves? . . . . . xxix, 351
LANGMORE (J. C.), twin (?) abortion . . . . iv, 133
„ — *report* on (G. Harley and T. H. Tanner) . . iv, 165
LANGSTON (THOMAS), monstrosity . . . . x, 37
LAPAROTOMY, primary, in cases of extra-uterine gestation (F. H. Champneys) . . . . . xxix, 456
„ in a case of repeated ectopic gestation in the same patient (A. H. N. Lewers) . . . . xlii, 324
„ removal of uterine fibroids by (J. Knowsley Thornton) . xxii, 114
„ fœtus and placenta removed by (W. Duncan) . xxxvi, 146
„ calcified tumour of uncertain origin removed by, from Douglas' pouch (A. H. N. Lewers) . . . xlvii, 151
„ immediate, in a case of ovarian tumour (W. Duncan) . xxxvi, 312
„ see *Abdominal section*.
LARYNX, cyst of the, removed post mortem from an infant (A. W. Edis) . . . . . xviii, 2
LAWRENCE (AUST), placenta with unusual arrangement of vessels xviii, 118
„ uterus and appendages of a woman who died from rupture of the right Fallopian tube . . . . xx, 292
„ extra-uterine fœtation . . . . . xxx, 122
„ — *report* by committee (Alban Doran, G. E. Herman, and F. H. Champneys) . . . . . xxx, 302
„ vesical calculi from a case of procidentia . . xxx, 227
„ sponge-tents . . . . . xxxi, 333
„ cystic disease of the chorion . . . xxxii, 64
„ polypoid myoma of the uterus . . . xxxii, 366
„ vesical calculi . . . . . xxxii, 366

LAWRENCE (AUST) (*continued*)—
„ cast of a large vesical calculus . . . . xxxii, 366
„ note on the operation for restoring the perineal body in complete rupture of the female perineum . . . xxxii, 377
„ ruptured tubal pregnancy . . . . xxxiv, 439

LAWRENCE (T. W. P.), redescription of the specimen of spondylolithesis in the museum of University College . . xlii, 75
„ and G. F. BLACKER, case of true unilateral hermaphroditism with ovotestis occurring in man, with a summary and criticism of the recorded cases of true hermaphroditism xxxviii, 265

LAWS of the Society, alteration of, respecting the Board for the Examination of Midwives . . . xxvi, 23; xxvii, 58
„ — on the mode of election of ordinary Fellows . . xxii, 48
„ — respecting the eligibility of medical practitioners to the Fellowship of the Society . . . . xxi, 4
„ — respecting the ordinary meetings . . xxii, 50; xxix, 84
„ — respecting the officers of the Society . . . xxvii, 58
„ — respecting the Society's property . . . xxxii, 106
„ — respecting the Referees . . . . xxvii, 59
„ — respecting the duties of the Trustees . . xix, 16; xxxii, 106
„ respecting contributions of Fellows . . xli, 48; xliii, 33
„ respecting election of Fellows and papers read before the Society . . . . . xliv, 51
„ respecting election of Officers and Council xxxvii, 288; xxxix, 53
„ — contributions of Fellows and papers read before the Society . . . . . xlvi, 64, 65

LAWTON (FRED.), vascular (erectile) tumour in the sheath of the funis in a new-born infant . . . . vii, 210
„ — microscopical examination of the above by Dr. J. B. Hicks vii, 213

LAZAREWITCH (J.), induction of premature labour by injection to the fundus of the uterus . . . . ix, 161
„ puerperal convulsions in the ninth month of pregnancy; accouchement forcé; expansion of cervix by Barnes' dilators and incision; delivery of fœtus with parallel forceps; child stillborn; recovery . . . . . xv, 59
„ new constrictor for removal of tumours of the uterus . xv, 63
„ the blunt hook of, considerably modified . . . xviii, 190
„ see *Meadows, A.*

LEA (A. W. W.), parovarian cyst with acute axial rotation . xxxix, 8
„ microscopic sections of uterine mucous membrane . . xxxix, 322
„ the sagittal fontanelle in the heads of infants at birth . xl, 263
„ tumour expelled from the uterus during natural labour . xli, 2
„ hæmatosalpinx in a chronically inflamed Fallopian tube . xli, 140
„ myxo-sarcoma of the vagina in a child aged two and a half years . . . . . xlii, 143
„ sarcoma of uterus . . . . . xliii, 73
„ adeno-carcinoma of both ovaries . . . . xliv, 225
„ tubercular disease of the Fallopian tubes and ovaries . xlv, 133
„ abscess of the uterus developing during the puerperium; rupture into the peritoneal cavity; abdominal section; recovery . . . . . xlvi, 7
„ vaginal hysterectomy in the puerperium for sepsis due to suppuration of myoma . . . . xlvii, 1
„ see *Griffith, W. S. A.*

LEAD-POISONING, influence of, in producing abortion and menorrhagia (B. Baker) . . . . . viii, 41

LEDIARD (H. A.), fibro-cystic myoma of uterus; septicæmia . xxvi, 193
„ secondary abdominal pregnancy; septic peritonitis; evacuation *per rectum*; recovery . . . . . xli, 276
„ see *Duncan, J. Matthews.*
„ see *Duncan, William.*

LEICESTER (J. C. HOLDICH), chyluria with pregnancy . . xlvii, 108
„ eclampsia; septic peritonitis; splenic abscess; death on sixteenth day after delivery . . . . xlvii, 271
„ ectopic gestation which apparently ruptured twice . . xlvii, 321

LEISHMAN (W.), associated hydrocephalus and spina bifida . v, 198
„ remarks in the discussion on puerperal fever . . xvii, 101

LEITER'S TEMPERATURE REGULATOR (C. Godson) . . xxiii, 131

LETTER OF CONDOLENCE on the death of Sir Thomas Spencer Wells from the "Gesellschaft für Geburtshülfe und Gynäkologie in Berlin" . . . . . xxxix, 87
„ reply . . . . . xxxix, 125

LEUKÆMIA associated with myxoma of both ovaries (A. L. Galabin) . . . . . xx, 123
„ and pregnancy (G. E. Herman) . . . . xliii, 234

LEVER, Dr. Boddaert's (R. Barnes) . . . . xiii, 213

LEWERS (A. H. N.), double pyosalpinx with rupture of the tubes xxvii, 298
„ uterus removed entire for primary malignant disease of the body . . . . . xxviii, 67
„ — microscopic sections of ditto . . . . xxviii, 206
„ case of circumscribed sarcoma of the vagina and uterus . xxviii, 78
„ fœtus from a ruptured tubal fœtation . . . xxviii, 207
„ on the frequency of pathological conditions of the Fallopian tubes . . . . . xxix, 199
„ fibroid tumours of the vagina . . . . xxix, 299
„ note on the post-mortem appearances of a phlegmon of the broad ligament . . . . . xxx, 7
„ carcinomatous cervix removed (with a portion of the peritoneum forming Douglas' pouch) by supra-vaginal amputation, from a patient in whom abortion had been induced at the fourth month . . . . . xxx, 81
„ case of extirpation of the uterus for primary carcinoma of the body . . . . . xxx, 218
„ case of lupus of the vulva . . . . . xxxi, 326
„ three specimens showing removal of cervix uteri for malignant disease . . . . . xxxii, 136
„ on plugging the uterus in severe cases of post-partum hæmorrhage, with notes of a successful case . . . xxxii, 356
„ endometritis polyposa with blighted ovum . . xxxiii, 197
„ microscopic specimens of cervix uteri removed by supra-vaginal amputation for cancer . . . . xxxiii, 301
„ six cases of craniotomy, with remarks on the relative position of craniotomy and Cæsarean section . . . xxxiv, 161
„ cancer of the body of the uterus . . . . xxxiv, 213
„ papillomatous ovarian cyst . . . . xxxiv, 462
„ case of symphysiotomy . . . . . xxxv, 408
„ fibro-cystic tumour of the uterus removed by abdominal section . . . . . xxxvi, 270

LEWERS (A. H. N.) (*continued*)—
„ a case of primary carcinoma of the body of the uterus in which vaginal hysterectomy was performed, and more than two years have elapsed without recurrence; with a table of five other cases of vaginal hysterectomy for cancer of the body of the uterus . . . . . xxxvi, 374
„ tubal mole removed by abdominal section . . . xxxvii, 78
„ tubal gestation of three months operated on before rupture xxxvii, 151
„ specimens of cervix uteri removed by the supra-vaginal amputation for cancer . . . . . xxxvii, 201
„ cancerous uterus with pyometra . . . . xxxviii, 14
„ chorionic villi from a tubal mole removed by abdominal section . . . . . xxxviii, 106
„ deformed fœtus with cystic tumour of neck . xxxviii, 106
„ two uteri removed by vaginal hysterectomy for cancer of the cervix, the disease being apparently at the same stage in each . . . . . xxxviii, 164
„ case of double uterus with double hæmatometra and complete absence of the vagina . . . . xxxviii, 327
„ monster, with skiagraph . . . . . xxxix, 131
„ uterus removed by pan-hysterectomy . . . xxxix, 131
„ ruptured tubal pregnancy with hæmatosalpinx of opposite side . . . . . xxxix, 189
„ primary sarcoma of the body of the uterus ("deciduoma malignum") in a patient twenty-four years of age, treated by vaginal hysterectomy . . . . . xxxix, 246
„ primary sarcoma of the body of the uterus (deciduoma malignum) . . . . . xl, 225
„ large solitary subperitoneal fibroid tumour of the uterus, and uterus with multiple fibroids . . . . xl, 327
„ three uteri removed by pan-hysterectomy . . . xli, 275
„ persistent mento-posterior position of the face, in which the child was delivered alive by the axis-traction forceps . xli, 280
„ uterus with fibroid tumour undergoing mucoid change, successfully removed by abdominal hysterectomy with intra-peritoneal treatment of the stump . . . xlii, 94
„ ruptured uterus with dermoid ovarian cyst the size of a child's head . . . . . xlii, 95
„ repeated ectopic gestation in the same patient; laparotomy on each occasion . . . . . xlii, 324
„ uterus with squamous epithelioma of cervix; removed in 1895; no recurrence in 1901 . . . . xliii, 266
„ two uteri removed by abdominal pan-hysterectomy for cancer of the body . . . . . xliv, 10
„ primary tuberculosis of the cervix simulating cancer, and treated by vaginal hysterectomy . . . xliv, 144
„ cancer of the cervix from eight cases treated by the supra-vaginal amputation, in which from four to fifteen years had elapsed without recurrence . . . . xlix, 221
„ uterus removed by abdominal pan-hysterectomy for primary carcinoma of the body . . . . xliv, 290
„ pyosalpinx with twisted pedicle . . . . xliv, 362
„ fibroid of the broad ligament weighing four and a half pounds, with twisted pedicle . . . . xliv, 364
„ keratinising carcinoma of the body of the uterus . . xlv, 97
„ deciduoma malignum . . . . . xlv, 245
„ tubal mole complicating carcinoma of the cervix . . xlv, 335

LEWERS (A. H. N.) (*continued*)—
„ repeated ectopic gestation in the same patient . . xlv, 418
„ uterus with carcinoma of the body and multiple fibroids . xlvi, 266
„ pregnancy in a rudimentary uterine cornu . . xlvii, 111
„ calcified tumour of uncertain origin removed by laparotomy from Douglas' pouch . . . . . xlvii, 151
„ fibro-cystic tumour of the uterus, laceration on its surface; free intra-peritoneal hæmorrhage . . . xlvii, 261
„ three cases of epithelioma of the vulva, with after-histories . xlviii, 163
„ two specimens of large uterine fibroids undergoing necrobiosis or red degeneration . . . . xlviii, 173
„ two specimens from cases of cancer of the cervix, the patients remaining free from recurrence twenty and eleven years respectively after operation . . . . xlix, 179
„ two specimens of fibroid associated with bleeding after the menopause . . . . . xlix, 270

LIDDARD (H. W.), inhaler for chloroform, alone or in combination with alcohol or ether . . . . xvi, 88

LIEBMAN (CHARLES), clinical notes on the early course of cancer of the cervix uteri . . . . . xvii, 66

LIFE appeared to have been saved by antistreptococcic serum in two cases (G. E. Herman) . . . . xli, 346

LIGAMENT, round, of the uterus, fibro-myoma of the intra-abdominal portion of (H. R. Spencer) . . . xlvi, 26
„ see *Broad Ligament.*

LIGATURE, changes in the pedicle of an ovarian tumour when treated by (G. G. Bantock) . . . . xiv, 2
„ discharged after an abdominal section (W. S. Playfair) . xxxiii, 386
„ of the pedicle in ovariotomy (Alban Doran) . . xxxv, 131
„ and division of the upper part of both broad ligaments, and the result as compared with that following removal of the uterine appendages (L. Remfry) . . . xxxvi, 202

LIP, epithelioma of, treated by injection of bromine (A. W. Williams) . . . . . xiii, 97

LIPOMA removed from left labium majus (C. H. Carter) . xxxii, 6
„ of the lumbar region, four pounds in weight, and of twenty years' growth (Alban Doran) . . . . xxxix, 40
„ retro-peritoneal, weighing thirteen pounds twelve ounces (A. Doran) . . . . . xliv, 265

LIQUOR AMNII, long delay of labour after discharge of (J. M. Duncan) . . . . . xiv, 216

LITHOPÆDION (W. J. Potts) . . . . xlviii, 338
„ so-called, being a supplement to a paper on so-called "missed labour" (R. Barnes) . . . . . xxiii, 170
„ of fourteen years' duration successfully removed (H. C. Bartlett) . . . . . xlvi, 200
„ retained in patient for sixteen years (W. W. H. Tate) . xliv, 95

LITHOTOMY, vaginal (J. H. Aveling) . . . v, 1
„ — for stone in the female bladder (I. Baker Brown) . v, 217
„ vesico-vaginal fistula left after, cured by plastic operation (Lawson Tait) . . . . . xviii, 209

LITTLEWOOD (H.) and G. P. ANNING, primary ovarian pregnancy, with rupture fourteen days after last menstruation . xliii, 14

LITTLE (W. J.), influence of abnormal parturition, difficult labour, premature birth, and asphyxia neonatorum, on the mental and physical condition of the child, especially in relation to deformities . . . . . iii, 293
LIVER, cancer of, complicating pregnancy (John Phillips) . xxix, 378
„ chorionepithelioma of uterus, with secondary growths in (G. F. Blacker) . . . . . xlvi, 55
„ secondary growths of chorionepithelioma malignum in (J. H. Teacher, for Prof. Sutherland and Dr. Buist) . . xlv, 252
„ congenital hernia (?) of (A. Meadows) . . . ii, 199
„ hydatids of, or connected with (C. J. Cullingworth and H. H. Clutton) . . . . . xlvi, 254
„ hypertrophy of, in a child nine years old (J. W. J. Oswald) . xviii, 191
LOCHIA, on the (A. E. Giles) . . . . xxxv, 190
LOCKWOOD (C. B.), retroflexion of an early human embryo associated with absence of the spinal medulla and imperfection of the vertebral column . . . . xxix, 234
„ obliteration of the central canal of the spinal cord in an early human embryo . . . . . xxx, 470
LOCOCK (Sir CHARLES) Baudelocque cephalotribe presented by . vii, 208
„ *Honorary President*, allusion to the death of . . xvii, 273
LOCKYER (CUTHBERT), multilocular cyst of the oöphoron . xlii, 37
„ congenital cœlomic cyst . . . . xliii, 7
„ endometritis exfoliativa . . . . xliii, 205
„ and A. DORAN, sloughing fibroid of the left uterine cornu; abnormal relations . . . . . xliii, 272
„ septicæmic uteri with bacteriological investigation . xliii, 304
„ chorio-epithelioma with pulmonary metastases . . xliv, 24
„ uterus showing rapidly growing epithelioma of the cervix; death from recurrence five months after removal . . xliv, 284
„ (with W. S. HANDLEY), solitary interstitial fibroid removed by abdominal myomectomy . . . . xlv, 51
„ incomplete tubal abortion showing intra-mural embedding of the placenta . . . . . xlv, 191
„ chorio-epithelioma with secondary growths in vagina, kidney, pancreas, lungs, and ? lymphatic glands . . . xlv, 245
„ tubal gestation in which the ovum continued to grow for about four weeks after rupture, the gestation sac becoming implanted on the omentum . . . . xlv, 400
„ uniovular twins . . . . . xlvi, 191
„ primary carcinoma of both ovaries . . . xlvi, 229
„ carcinoma in the muscular wall of the uterus secondary to cancer of both ovaries . . . . xlvi, 302
„ carcinoma of the ovary of unusual type . . . xlvi, 349
„ multilobular papilloma of the urethra . . . xlvii, 122
„ the corpus luteum; compound lutein cystomata found in association with vesicular mole and chorio-epithelioma . xlvii, 157
„ two cases of imperfectly developed internal generative organs, the patient in one case being an epileptic subject . . xlviii, 75
„ three cases of adeno-myoma uteri . . . xlviii, 84
„ *report* on Amand Routh's specimen of fibro-myoma uteri . xlix, 3
„ *report* on the late G. Bagot Ferguson's specimens of chorio-endothelioma of uterus . . . . xlix, 60
„ bilateral primary tuberculous salpingitis, with secondary infection of the perivascular lymphatics of the uterine wall xlix, 141
„ see *Malcolm, J. D.*

LONGINGS of pregnant women (A. E. Giles) . . . xxxv, 242
LONGRIDGE (C. NEPEAN), eclampsia, with two special details of treatment . . . . . xlvii, 353
„ sixty-four cases of contracted pelvis . . . xlviii, 226
„ rupture of the heart in a still-born infant . . . xlix, 214
„ dilated ureters in still-born infants . . . xlix, 215
„ diaphragmatic hernia in a new-born baby . . . xlix, 272
„ mammary gland of new-born infant . . . xlix, 273
LOOP of small intestine found adherent to the pedicle six months after ovariotomy (H. J. Paterson) . . . xlvii, 316
„ saw (J. H. Aveling) . . . . . xv, 221
„ whalebone, use of, in delivery (J. G. Westmacott) . . xi, 177
LOWE (GEORGE), case of atresia of the uterine cervical canal; distension of the uterus; escape of the menstrual fluid between the walls of the vagina . . . xxix, 401
„ hæmorrhage from retained placenta after abortion, terminating fatally . . . . . xii, 323
LOWNDES (F. W.), statistics of still-births . . . xiv, 283
LUCAS (JOHN C.), cholera in the newly born . . . xxi, 250
LUNGS, chorio-epithelioma with secondary growths in (C. Lockyer) . . . . . xlv, 245
„ chorionepithelioma of uterus with secondary growths in (G. F. Blacker) . . . . . xlvi, 55
„ secondary deposits of deciduoma malignum *without* syncytium in (P. Horrocks) . . . . . xlv, 243
„ showing secondary deposits of deciduoma malignum (F. J. McCann) . . . . . xlv, 248
„ secondary nodule in, in a case of chorionepithelioma malignum (J. H. Teacher) . . . . . xlv, 253
„ — deposits of sarcoma in (W. S. A. Griffith) . . xxviii, 38
„ notes of a case of malignant disease of the uterus with numerous deposits in, and death following an abortion (J. D. Malcolm) . . . . . xxxviii, 125
LUPOUS STRICTURE and atresia of the female urethra (G. E. Herman) . . . . . xxviii, 267
LUPUS, histological observations and remarks on (G. Thin) . xxvii, 315
„ hypertrophy of, of the female generative organs (J. Matthews Duncan) . . . . . xxvii, 230
„ inflammations of, of the pudendum (J. Matthews Duncan) . xxvii, 310
„ ulceration of, of the female generative organs, including perforations, pits, and excavations (J. Matthews Duncan) . xxvii, 139
„ of the vulva, case of (A. H. N. Lewers) . . . xxxi, 326
LYING-IN, see *Childbed, Lying-in Women, Puerperal, Puerperium.*
„ Hospital (British), puerperal fever in (W. G. Hewitt) . x, 69
„ — Melbourne, Australia, short account of (R. T. Tracy) . xii, 349
„ — (Military) at Woolwich, account of (F. R. Hogg) . xiv, 35
„ — University, Montreal, report of the (D. C. MacCallum) . xx, 35
„ hospitals, the mortality in (A. L. Galabin) . . xxxi, 92
„ — in the north of Europe, notes of a visit to some, and on the advantages of the antiseptic system in obstetric practice (Sir W. O. Priestley) . . . . . xxvii, 197
„ Ward of the Cincinnati Hospital, mortality in (G. Mendenhall) . . . . . xii, 357
„ — (Florence Nightingale), King's College Hospital, history of (C. C. Rowling) . . . . . x, 50

LYING-IN (*continued*)—
„ woman, note on the effect of the influenza poison upon the (A. W. Addinsell) . . . . . xxxv, 333
„ women, broncho-pneumonia of (R. Barnes) . . iv, 55
„ — mercurialism in, undergoing sublimate irrigation (W. R. Dakin) . . . . . xxviii, 281
„ — the conditions which favour mercurialism in, with suggestions for its prevention (R. Boxall) . . . xxx, 304
„ — thrombosis and embolia of (R. Barnes) . . iv, 30

LYMPHANGITIS mammæ: an affection of the breast arising about the tenth day of the puerperium with well-marked clinical features (R. H. Vincent) . . . xliv, 158
„ in pelvic pathology (E. J. Tilt) . . . . xvi, 130

LYMPHATICS of the uterus, the comparative anatomy of (G. Hoggan) . . . . . xxiii, 4
„ perivascular, of the uterine wall, bilateral primary tuberculous salpingitis, with secondary infection of (C. Lockyer) . xlix, 141

LYMPHATIC VARIX, the artificial production of so-called (F. H. Champneys) . . . . . xxviii, 144
„ case of phlegmasia dolens with (J. Matthews Duncan) . xxiii, 132

MABERLEY (W. H.), two specimens of placentæ in which the blood-vessels ran along the membranes for some distance from the edge of the placenta, and then united to form the umbilical cord . . . . . xix, 65
„ see *Godson, Clement.*

MACCALLUM (D. C.), two cases of extra-uterine fœtation . xv, 248
„ case of intra-uterine peritonitis . . . . xviii, 116
„ report of the University Lying-in Hospital, Montreal, from October 1st, 1867, to October 1st, 1875 . . . xx, 35
„ description of the conjoined twins Marie-Rosa Drouin . xx, 120
„ case of villous degeneration of the endometrium . . xxiii, 37

MCCANN (FREDERICK JOHN), chorea gravidarum . xxxiii, 413, 466
„ tuberculous salpingitis . . . . xxxiii, 496
„ ætiology of gonorrhœa . . . . xxxviii, 225
„ malignant adenoma (carcinoma) of the cervix uteri . xl, 2
„ uterine myoma . . . . . xl, 3
„ tubal mole removed by colpotomy . . . xliv, 133
„ squamous carcinoma of the cervix uteri . . . xliv, 136
„ "deciduoma malignum" after the menopause . xliv, 294
„ deciduoma malignum . . . . xlv, 247, 248
„ — with secondary deposit in vagina; lungs showing secondary deposits . . . . . xlv, 248
„ cervical fibroid . . . . . xlviii, 178
„ broad ligament cyst with torsion of the pedicle and extensive hæmorrhage into the broad ligament . . . xlviii, 179
„ primary carcinoma of the vagina . . . xlviii, 181
„ myoma of the vagina . . . . xlviii, 182
„ and W. A. TURNER, on the occurrence of sugar in the urine during the puerperal state . . . . xxxiv, 473

MCCAW (J. DYSART), cystic fibro-myoma of the uterus complicating pregnancy; removal at four and a half months . xl, 256

MCILROY (A. LOUISE), primary cancer of the ovary . . xlviii, 251

Mackenzie (F. W.), induction of abortion in cancerous disease of the uterus and rectum, with observations . . i, 11
„ craniotomy, in which delivery was readily effected by turning after perforation, when instrumental extraction was found impossible, with observations upon the substitution of this mode of delivery in certain cases . . . i, 267
McKeown (David), the prevention of ophthalmia neonatorum and of its ravages . . . . . xxvii, 49
Mackinder (Draper), sudden death from occlusion of the pulmonary arteries seventeen days after parturition . . i, 213
„ obstetrical register . . . . . ix, 268
McKerron (Robert G.), for *William Stephenson*, peculiar mucous polypus of the cervix uteri . . . xxxix, 314
„ obstruction of labour by ovarian tumours in the pelvis . xxxix, 334
„ antero-posterior positions of the head as a cause of difficult labour . . . . . xli, 142
„ adjourned discussion on paper on the obstruction of labour by ovarian tumours in the pelvis . . . xl, 8
„ suppression of urine after labour . . . xliv, 97
McLaurin (Dr.), see *Chalmers, John.*
Maclean (Campbell), see *Tilt, E. J.*
Maclean (E. J.), tubo-ovarian gestation . . . xxxv, 106
„ large soft broad ligament fibro-myoma, weighing fourteen pounds . . . . . xl, 134
„ a case of abdominal pregnancy; spurious labour at term; fœtus and placenta removed six months later . . xlviii, 129
„ and Arthur E. Giles, two unusual cases of tubal gestation: the one causing chronic intestinal obstruction, and accompanied by a hæmatosalpinx of the non-gravid tube; the other simulating retroversion of the gravid uterus . xxxix, 232
M'Clintock (A. H.), clinical memoir on turning in cases of disproportion . . . . . iv, 175
„ remarks in the discussion on the use of forceps . . xxi, 185
„ motion of condolence on the death of . . . xxiii, 240
Macnaughton-Jones (H.), uterine fibroid with anomalous ovarian tumour . . . . . xl, 154
„ complete incontinence of urine cured by ventro-fixation of the uterus . . . . . xl, 226
„ two cases of congenital malformation of the genital organs . xlii, 92
„ ovarian cystoma complicating pregnancy; infection of the cyst five days after labour; operation on the forty-third day; extensive peritoneal and bowel adhesions; recovery . xlii, 140
„ monster of seventh month removed by hysterectomy . xlvii, 302
„ anencephalic fœtus . . . . . xlvii, 307
Madge (H. M.), uterine hæmatocele. . . . . iii, 79
„ smallpox in twin fœtuses . . . . iii, 173
„ idiopathic pericarditis in a child two and a half years old . iii, 176
„ large fibrous tumour impeding delivery . . . iv, 129
„ chronic hydrocephalus . . . . . v, 201
„ lesion (rupture ?) of the placenta . . . vi, 1
„ fibrous tumour of uterus . . . . viii, 105
„ anatomical relations between mother and fœtus . . viii, 348
„ spina bifida, with talipes varus of both feet . . ix, 158
„ ruptured uterus . . . . . x, 97
„ hydronephrosis of the fœtal kidneys impeding labour . xi, 55

MADGE (H. M.) (*continued*)—
„ four cases of congenital imperforate vagina, and one case of congenital phymosis, occurring in same family . . xi, 213
„ prolapsed portion of funis, with complicated knot . . xii, 133
„ inversio uteri . . . . . xii, 347
„ uterine fibroids complicating pregnancy . . . xiv, 227
„ case of ileo-cæcal intussusception in an infant of eight months . . . . . xvi, 219
„ case of labour complicated by pelvic tumour and convulsions xvii, 20

MAGUIRE (GEORGE J.), acute contagious pemphigus in the newly born . . . . . xlv, 429

MAIEUTIC, simple, for the induction of miscarriage or premature labour (P. Horrocks) . . . . xxxviii, 168

MALCOLM (JOHN D.), for *J. Knowsley Thornton*, ovaries and tubes from a case of persistent chronic ovaritis . . xxviii, 278
„ — tumour showing that it is, in some cases, impossible to make a differential diagnosis between uterine and ovarian neoplasms . . . . . xxix, 249
„ — *report* on ditto by committee (A. L. Galabin, G. E. Herman, and Alban Doran) . . . . xxix, 515
„ pair of incipient ovarian cysts . . . . xxxiii, 29
„ papillomatous ovarian cystoma removed after double ovariotomy fifteen years previously . . . . xxxv, 36
„ uterine fibroids . . . . . xxxvi, 200
„ notes of a case of malignant disease of the uterus with numerous deposits in the lungs, and death following an abortion . . . . . xxxviii, 125
„ two solid ovarian tumours . . . xxxviii, 166
„ large solid ovarian tumour . . . xxxviii, 167
„ solid ovarian tumour . . . . xxxviii, 167
„ partially macerated fœtus from an extra-uterine fœtation retained in the body about a year after its death . . xli, 222
„ macerated bones of a fœtus from an extra-uterine gestation retained seven years . . . . . xli, 223
„ tumour closing simulating a papillomatous ovarian cystoma attached to the front of the bladder and quite separate from both ovaries . . . . . xli, 226
„ double pyosalpinx in which the tubal sacs communicated . xlii, 10
„ operation between the third and fourth months of extra-uterine gestation, with removal of a living fœtus, and much trouble from hæmorrhage during convalescence . . xlv, 382
„ extra-uterine fœtation; death after operation from septicæmia; remarks on the significance of adhesions of the wall of the gestation sac to the dead fœtus . . . xlv, 421
„ sloughing of the central part of a uterine fibro-myoma shortly after delivery . . . . . xlvi, 15
„ abscess in a corpus luteum . . . . xlvii, 8
„ cancerous uterus . . . . . xlvii, 10
„ peritonitis and the *Staphylococcus albus* . . . xlviii, 97
„ on the advisability of removing the cervix in performing hysterectomy for fibro-myomatous uterine tumours . xlix, 148
„ R. HAMILTON BELL, and CUTHBERT LOCKYER, chorio-epithelioma following hydatidiform mole in a patient with bilateral ovarian cysts, with pathological report and references to the literature on kindred cases . . . xlv, 483

MALFORMATIONS, absence of occipital bone in a fœtus (R. Barnes) . . . . . xvi, 100
„ child born with amputated extremities (I. B. Brown) . viii, 102
„ case of cyclops (W. Y. McC. Ettles) . . . xxxvi, 149
„ dissection of a case of spina bifida (T. W. Eden) . . xxxv, 336
„ of the Fallopian tube (Alban Doran) . xxviii, 171; xxix, 186
„ of the fœtus (W. Sedgwick) . . . . i, 239
„ of fœtus (G. Roper) . . . . . xviii, 295
„ — (P. Horrocks) . . . . . xxvii, 131
„ — outgrowth from end of coccyx (Heywood Smith) . xxv, 2
„ — (Amand Routh) . . . . . xxxiv, 463
„ — with hernia umbilicalis congenita and spina bifida lumbo-sacralis (Amand Routh) . . . . xxxv, 102
„ deformed fœtus (F. C. Bottomley) . . . xxxix, 134
„ fœtus compressus s. papyraceus (F. C. Bottomley) . . xxxix, 134
„ in an anencephalic fœtus, completely cleft spine associated with an unusual visceral (T. G. Stevens) . xxxviii, 346
„ fœtus with absence of urethra and ascites obstructing delivery (T. G. Stevens) . . . xxxvii, 5
„ fœtus at seven months illustrating celosoma with retroflexion, meningocele, and talipes varus (Leith Napier) . . xxxvi, 116
„ of the genital organs in a child (H. C. Rose) . . xv, 85, 125
„ — two cases of congenital (H. Macnaughton-Jones) . xlii, 92
„ heart (R. J. Probyn-Williams) . . . . xxxvi, 3
„ of heart (Clement Godson) . . . . xxiii, 179
„ — of a dicephalous fœtus (John Phillips) . . xxix, 55
„ congenital diaphragmatic hernia, three cases of (H. R. Spencer) . . . . . xxxii, 132
„ — (A. E. Giles) . . . . . xxxiv, 132
„ complete epispadias in male infant (H. E. Eastlake) . ix, 63
„ hypospadias, extreme, in a child brought up as a female (H. C. Rose) . . . . . xviii, 256
„ of pelvis, induction of premature labour in a case of (J. H. Trouncer) . . . . . i, 236
„ — case of Cæsarean section for (J. W. J. Oswald) . . xvii, 378
„ living female child with three lower limbs (Clement Godson) xxxii, 132
„ singular (J. Neale) . . . . . viii, 259
„ of rectum and bladder, congenital absence of both kidneys and ureters, imperforate anus, absence of right hypogastric artery, and deformed feet (A. E. Giles) . . . xxxiv, 129
„ double vagina and uterus (H. Gervis) . . . xix, 271
„ uterus didelphys, with observations on the clinical importance of this (A. E. Giles) . . . xxxvii, 301
„ see *Deformity, Hermaphrodite, Monster, Spondylolisthesis.*

MALIGNANT DISEASE, congenital, of the forehead and neck (John Phillips) . . . . xxx, 301, 334
„ producing hæmatocele (W. S. Playfair) . . . xxvi, 6
„ uterus removed entire for (A. H. N. Lewers) . xxviii, 67, 206
„ — the body of which was the seat of (Heywood Smith) . xx, 4
„ of the cervix uteri (G. Roper) . . . . xxii, 85
„ — (A. W. Edis) . . . . . xxiv, 298
„ — three specimens of (A. H. N. Lewers) . . . xxxii, 136
„ — Cæsarean section performed on account of (A. L. Galabin) xviii, 286
„ — two cases of pregnancy complicated by (A. L. Galabin) . xviii, 239
„ vaginal hysterectomy for (F. A. Purcell) . . . xxvii, 5

MALIGNANT GROWTHS, see *Tumours*, malignant.

MALIGNANT TUMOUR, see *Tumours*, malignant.

MALINS (EDWARD), remarks in the discussion on the use of forceps . . . . . xxi, 155
„ extirpation of the uterus for procidentia . . . xxvi, 148
„ pyosalpinx . . . . . xxvi, 228
„ broad ligament cysts . . . . . xxvi, 228
„ double pyosalpinx . . . . . xxvii, 137
„ case of hydatids of the mesentery . . . xxix, 245
„ case of extra-uterine gestation . . . . xxxiv, 181
„ hæmatosalpinx . . . . . xxxiv, 466
„ Inaugural Address as President . . . . xlv, 109
„ Annual Address . . . . xlvi, 67; xlvii, 82

MAMMA, glandular cystic tumour of (W. Squire) . . iii, 213

MAMMARY GLANDS, see *Breasts*.

MAMMARY REGION, see *Breasts*.

MANIA, complicating puerperal convulsions; apparent recovery; sudden decease (A. Hall) . . . . iv, 222

MARE, cyst of the ovary of (C. S. Pollock) . . xxxi, 234, 253

MARLEY (RICHARD), action of belladonna upon the mammary glands . . . . . ii, 29
„ on pertussis: its causes, symptoms, and treatment . . v, 300

MARSHALL (JOHN), tubal gestation; death . . . v, 154
„ disease of the placenta . . . . . viii, 137
„ placenta with fibrinous deposits . . . . ix, 242
„ child born with amputated arm . . . . x, 94

MARSHALL (W. E.), see *Williams, John*.

MARTIN (A. E.), remarks on the pelvis collection and on pelvimetry in the Royal University Maternity of Berlin . xiv, 71
„ cephalotribe . . . . . xiv, 65

MARTIN (CHRISTOPHER), see *Tait, Lawson*.

MARTIN (L. J.), hard fibrous tumour of the ovary removed by ovariotomy; recovery . . . . . xii, 302

MARTYN (W.), face presentation; delivery by forceps; subsequent sloughing and separation of the mucous lining of the bladder and expulsion of the same . . . v, 186
„ tedious labour; delivery by forceps and death of the patient on the third day, probably from thrombosis of right heart and pulmonary arteries . . . . x, 263
„ extra-uterine pregnancy, terminating in sudden death . xi, 57
„ — *report* on . . . . . xi, 62
„ triplets at upwards of eight months of pregnancy . . xi, 208
„ management of childbed, with a view to promote successful suckling . . . . . xii, 339

MATERNAL IMPRESSIONS to which congenital deformity of two children was attributed (A. Thompson) . . . xix, 94
„ case of fright by a monkey (Heywood Smith) . . xxii, 242

MATHIESON (J. H.), case of extra-uterine gestation; delivery of living child *per vaginam*; removal of placenta; recovery . xxvi, 132

MATTHEWS (J.), new craniotomy forceps . . . ix, 29

MAXWELL (JAMES L.), notes on two fatal cases of pernicious vomiting in pregnancy . . . . . xliii, 288

MAXWELL (J. PRESTON), on spontaneous rupture of the uterus in placenta prævia . . . . . xliii, 217

MAXWELL (R. D.), volvulus in a fœtus . . . xlviii, 277

MAYO (CHARLES), presentation of right shoulder and arm; spontaneous evolution . . . . . iii, 105

MEADOWS (A.), twins, one blighted, the other anencephalous . i, 51
„ congenital hernia (?) of the liver . . . ii, 199
„ idiopathic pericarditis in a child two years old . iii, 144
„ inguinal hernia of the right ovary, successfully removed . iii, 438
„ monstrosity . . . . . iv, 255
„ new method of treating cases of vesico-vaginal fistula . vi, 107
„ bandage after labour . . . . . vi, 125
„ imperforate bowel; operation; death . . . vii, 53
„ monstrosity, with remarks on the influence of maternal impressions on the fœtus *in utero* . . . . vii, 84
„ amputation of cervix uteri . . . . viii, 39
„ intra-uterine stem . . . . viii, 135
„ cyst of the Fallopian tube; remarks . . . viii, 139
„ hypertrophy of labium . . . . viii, 257
„ cauliflower excrescence of posterior lip . . . viii, 258
„ écraseur with single steel wire . . . ix, 111
„ and A. J. BANNISTER, *report* on monstrosity . . ix, 112
„ monstrosity with caudal appendage . . . ix, 112
„ uterine sound with metroscope . . . . ix, 242
„ tumour from anterior wall of vagina . . . x, 141
„ flexions of the uterus . . . . . x, 204
„ medicated pessaries . . . . . x, 224
„ new vaginal speculum . . . . . xi, 3
„ instruments received from Prof. Lazarewitch, hysteroper, two intra-uterine stems and uterine sound . . . xi, 78
„ amputation of cervix uteri . . . . xi, 102
„ large fibroid polypus removed by single-wire écraseur . xi, 241
„ two new forms of vaginal speculum . . . xii, 134
„ pelvic hæmatocele, with special reference to its diagnosis and treatment . . . . . xiii, 140, 170
„ extra-uterine gestation, with remarks on its treatment . xiii, 268
„ probable origin of certain forms of cystic disease of the ovary xiv, 39
„ remarks on the treatment of some forms of extra-uterine gestation, with a case . . . . . xiv, 309
„ gastrotomy for supposed extra-uterine gestation . . xv, 145
„ specimen of membrane passed in so-called membranous dysmenorrhœa . . . . . xvi, 230
„ — *report* on ditto by committee (J. H. Aveling and John Williams) . . . . . xvi, 251
„ note on the *post-mortem* diagnosis of a nulliparous uterus xvii, 355; xviii, 69
„ for *T. N. Moore*, case of Fallopian pregnancy; rupture and death about the fifth month . . . . xviii, 258
„ pessaries of xylonite . . . . . xxiii, 131
„ ovarian tumour and fibroid of uterus . . . xxv, 161
„ subperitoneal uterine fibroids . . . . xxv, 232
„ and W. WILLIAMS and J. H. AVELING, report on a case of extra-uterine fœtation. . . . . xiii, 268

MEATUS URINARIUS EXTERNUS, adenoma of (H. R. Spencer) . xli, 383

MECHANICAL ACTION of pessaries (John Williams) . . xviii, 126

MECHANISM OF LABOUR, more especially with reference to Naegele's obliquity and the influence of the lumbo-sacral curve (R. Barnes) . . . . . xxv, 258
„ of the third stage of (F. H. Champneys) xxix, 117, 151, 264, 317, 337, 346
MECKEL'S DIVERTICULUM, prolapse of, in an infant, forming an umbilical tumour (S. W. Wheaton) . . . . xxxiv, 184
MEDICAL CONGRESS of Philadelphia, report of delegate (R. Barnes) . . . . . xix, 2
MEDICAL COUNCIL (General), direct representation of obstetrics at . . . . . xvi, 21; xxiii, 46
„ resolution for a memorial to the Home Secretary, etc., for the direct representation of obstetrics in the . . . . xi, 14
„ particulars of, with text of memorial . . . xi, 123–5
MEDICAL PRACTITIONERS, alteration of the laws respecting the eligibility of, to the Fellowship of the Society . . xxi, 4
MEDULLA, spinal, absence of (C. B. Lockwood) . . xxix, 234
MEDULLARY GROWTHS in vagina of infant (N. Heckford) . x, 224
MEETINGS, ordinary, of the Society, alteration of laws respecting the . . . . . xxii, 50; xxix, 84
MEDIASTINUM, embryoma of anterior, in a male adult (J. Ritchie) . . . . . xlv, 250
MELBOURNE (Australia) Lying-in Hospital, short account of (R. T. Tracy) . . . . . xii, 349
MEMBRANE from female bladder (J. H. Aveling) . . xxv, 33
„ deciduous (W. G. Hewitt) . . . . ix, 55
„ — expelled from a double uterus (W. F. Cleveland) . xxvi, 184
„ dysmenorrhœal (Wynn Williams) . . . xxv, 233
„ exfoliation of vesical mucous (Alban Doran) . . xxiii, 2
„ expelled from uterus a few days before delivery at full term (A. Harris) . . . . . vii, 47
„ passed in a case of membranous dysmenorrhœa (A. Meadows) xvi, 230, 251
„ periodical discharge of, in cervical endometritis (A. L. Galabin) . . . . . xxiii, 207
„ fragment of, passed from the uterus (Alban Doran) xxxi, 229, 310
„ mucous, of the uterus in endometritis (A. L. Galabin) . xxii, 47
MEMBRANES, diseased fœtal, in early pregnancy (John Phillips) xxxi, 52, 161
„ fœtal, attachment of, to the scalp in case of hernia cerebri and hernia umbilicalis (T. H. Tanner) . . . vii, 109
„ fœtus discharged in the, entire at six months and three weeks (H. T. Barton) . . . . . xxix, 189
„ and fœtus from a case of missed abortion (Alban Doran) . xxvii, 224
„ and placentæ from a case of triplets (P. Horrocks) . . xxvi, 160
„ placenta, cord, fœtus, and (Robert Wise) . . xxxviii, 166
„ some causes of retention of the (F. H. Champneys) . . xxix, 317
„ separation and expulsion of the (F. H. Champneys) . . xxix, 264
„ from a case of ruptured tubal gestation, complicated by a large hæmato-salpinx on the opposite side (C. J. Cullingworth) . . . . . xxxii, 273
„ of a twin ovum of ten weeks' gestation (J. Hall Davis) . x, 57
„ tumours of fœtal (G. M. Bluett and G. E. Herman) xxix, 243, 512
„ see *Amnion, Chorion, Decidua.*
MEMBRANOUS CROUP (R. U. West) . . . i, 53

MEMORIAL presented to the General Council of Medical Education and Registration by the Council of the Obstetrical Society of London . . . . . ii, 3

MENDENHALL (GEORGE), mortality in the lying-in ward of the Cincinnati Hospital . . . . . xii, 357

MENINGITIS, primary, pneumococcus, simulating puerperal eclampsia (T. Wilson) . . . . . xliv, 5

„ tubercular, uterus and ovaries of child who died of (F. Beach) xv, 57

MENINGOCELE, case of, complicating labour (S. W. Poole) . xix, 268

„ spinal (John Phillips) . . . . . xxix, 188

„ see *Malformations*.

MENOPAUSE, "deciduoma malignum" after the (F. J. McCann) . xliv, 294

„ changes in fibroid tumours after (J. Bland-Sutton) . . xlv, 105

„ fibroid associated with bleeding after (A. H. N. Lewers) . xlix, 270

„ sloughing fibro-myoma of uterus occurring in a patient twenty years after the (W. W. H. Tate) . . . xl, 303

„ fibro-myomata of the uterus causing intestinal obstruction and death two years after the (C. J. Cullingworth) . . xxxix, 282

„ three cases of myomatous uteri bleeding after the (H. R. Spencer) . . . . . xlviii, 333

MENORRHAGIA, influence of lead-poisoning in producing (B. Baker) . . . . . viii, 41

„ treated by injection, or the removal of the uterine mucous membrane by the gouge, or both means combined (C. H. F. Routh) . . . . . ii, 117

„ treatment of certain forms of, by means of the sponge tent, with reference to women residing in tropical climates (G. G. Bantock) . . . . . xiv, 84

MENSES, escape of, between the walls of the vagina in a case of atresia of the cervix uteri (G. Lowe) . . . xxix, 401

„ retained, in large cavity, communicating with uterine canal in a case of fibro-myoma of uterus (W. W. H. Tate) . . xlvii, 360

„ — *in utero* and Faliopian tubes, in case of absence of vagina (C. H. F. Routh) . . . . . xii, 34

„ — of two years' duration, caused by atresia vaginæ (I. B. Brown) . . . . . iv, 21

„ — sequel to case of, caused by atresia vaginæ (I. B. Brown) . v, 162

„ retention of, after difficult labour (J. H. Davis) . . iv, 91

„ — congenital abnormality of uterus simulating (J. Braxton Hicks) . . . . . xxii, 260

„ — with distension of uterus, in a case of absence of vagina (C. H. Carter) . . . . . xxii, 251

„ — in one half of a double uterus (A. L. Galabin) . . xxiv, 21

„ — for more than two years, in a married woman (W. Chapman) . . . . . iv, 251

„ — subsequent to case of occluded vagina after delivery (S. Craddock) . . . . . xiii, 101

MENSTRUAL FLUID, retained in a case of imperforate hymen (E. Copeman) . . . . . x, 246

MENSTRUATION, cyclical or wave theory, with observations on the variations in pulse and temperature in relation to (A. E. Giles) . . . . . xxxix, 115

„ on the change in size of the cervical canal during (G. E. Herman) . . . . . xxxvi, 250

„ decidua passed on the first day of (A. L. Galabin) . . xxi, 312

MENSTRUATION (*continued*)—
„ painful, on the relation between backward displacements of the uterus and (G. E. Herman) . . . . xxiv, 161
„ in cases of backward displacement of the uterus (G. E. Herman) xxiv, 225
„ effects of lactation on impregnation and (Leonard Remfry) xxxviii, 22
„ fate of ovum and Graafian follicle prior to (T. G. Stevens) . xlv, 465
„ on the age at which it commences (W. Rigden) . . xi, 243
„ treatment of sickness in diseases of (E. J. Tilt) . . iii, 15
„ on the relation of heart disease to (W. J. Gow) . . xxxvi, 126
„ the relation of scarlatina to (R. Boxall) . . . xxx, 55
„ primary ovarian pregnancy with rupture fourteen days after last (G. P. Anning and H. Littlewood) . . . xliii, 14
„ during pregnancy (W. G. Hewitt) . . . viii, 221
„ and pregnancy, influence of purpura hæmorrhagica upon (John Phillips) . . . . . xxxiii, 390
„ uterus during (W. G. Hewitt) . . . . viii, 220
„ — just before, with microscopic sections (W. S. A. Griffith) . xxiv, 138
„ microscopical section of uterus from a subject who died the day of commencement of (R. Cory) . . . xx, 104
„ and ovulation of monkeys and the human female (W. Heape) xl, 161
„ and chlorosis, the relation between (W. Stephenson) . xxxi, 104
„ of *Semnopithecus entellus* (W. Heape) . . . xxxvi, 213

MENTAL EMOTION, strong, affecting pregnant women as a cause of idiocy in the offspring (Sir A. Mitchell) . . xxvi, 124

MERCURIALISM in lying-in women, the conditions which favour, with suggestions for its prevention (R. Boxall) . . xxx, 304
„ — undergoing sublimate irrigation (W. R. Dakin) . . xxviii, 281

MERCURY, acid nitrate of, case of death following vaginal injection of (John Phillips) . . xxxii, 308; xxxiii, 180
„ — death following vaginal injection (J. Phillips) . . xxxiii, 180
„ perchloride of, pellets of (F. H. Champneys) . . xxviii, 66
„ — its use as an antiseptic (A. L. Galabin) . . xxxi, 98

Meredith (W. A.), large fibroid tumour of the uterus . . xxiv, 79
„ fibro-cyst of ovary . . . . . xxix, 248
„ — *report* on ditto by committee (A. L. Galabin, G. E. Herman, and Alban Doran) . . . . . xxix, 513
„ solid pelvic tumour . . . . . xxix, 249
„ — *report* on ditto by committee (A. L. Galabin, G. E. Herman, and Alban Doran) . . . . . xxix, 514
„ case of hæmatometra associated with a degenerating fibro-myoma, treated by supra-vaginal hysterectomy . . xxix, 422
„ fibro-myomata of uterus with axial rotation of the tumours . xxx, 80
„ case of locked fibroid treated by supra-vaginal hysterectomy . xxx, 442
„ solid tumours of ovary . . . . . xxxi, 225
„ papillomatous ovarian cysts removed during the fourth month of pregnancy . . . . . xxxii, 374
„ two cases of double ovariotomy during pregnancy . . xxxiv, 239
„ fibro-myoma of the cervix uteri, removed by abdominal pan-hysterectomy . . . . . xlvi, 12

MESENTERY, large chylous cyst of (Ad. Rasch) . . xxxi, 311
„ hydatids of the (E. Malins) . . . . xxix, 245
„ — or connected with (C. J. Cullingworth and H. H. Clutton) xlvi, 254

MESOCÆCUM, ovarian cyst which had made its way between the layers of the mesosigmoid, both broad ligaments, and the (W. H. B. Brook) . . . . . xlv, 415

MESOMETRIUM, tumour of, weighing 22 lb. (J. Bland-Sutton) . xli, 298
MESOSIGMOID, both broad ligaments, and mesocæcum, ovarian cyst which had made its way between the layers of (W. H. B. Brook) . . . . . xlv, 415
MESOVARIUM, torsion of, producing minute pedicle in dermoid cyst of ovary (A. L. Galabin) . . . . . xlvii, 331
METASTASES, pulmonary, chorio-epithelioma with (C. Lockyer) . xliv, 24
METEOROLOGICAL CONDITIONS, external, the relation of, to the incidence of febrile illness in childbed (R. Boxall) . . xxxv, 340
METRITIS, chronic infective (A. W. Addinsell) . . xlviii, 144
„ — pathology of (W. F. Shaw) . . . . xlix, 19
METROMETER SOUND (R. Greenhalgh) . . . xiii, 169
METRORRHAGIA, dysmenorrhœa, ovaritis, and sterility, depending upon a peculiar formation of the cervix uteri (R. Barnes) vii, 120
METROSCOPE, uterine sound with (A. Meadows) . . ix, 242
METROTOME, bilateral (R. Greenhalgh) . . . v, 164
„ Peaslee's, modified form of (A. L. Galabin) . . xx, 53
MICROCOCCI in the substance of a decomposing fibroid tumour (S. W. Wheaton) . . . . . xxxiv, 187
MICRO-ORGANISMS of obstetrical and gynæcological interest (G. D. Robinson) . . . . . xxxvii, 263
MICROSCOPIC SECTIONS of tumour expelled from the uterus during natural labour (A. W. W. Lea) . . . xli, 2
MICROSCOPICAL SLIDES from a case of inter-menstrual pain (Mittelschmerz) (A. W. Addinsell) . . . xli, 3
MIDWIFERY, the use of antiseptics in (A. L. Galabin) . . xxxi, 92
„ and diseases of women, a century's progress in (P. Horrocks) xliii, 79
„ anæsthesia in (T. Skinner) . . . . iv, 116
„ further observations on the use of anæsthetics in (C. Kidd) . v, 125
„ value of anæsthetic aid in (C. Kidd) . . . ii, 340
„ among the Burmese (T. F. Pedley) . . . xxix, 5
„ in the East (J. Jackson) . . . . ii, 37
„ old books on, exhibition of (A. Wiltshire) . . . xvi, 245
„ consultation in private practice, statistical and practical remarks on (E. Copeman) . . . . xvi, 103
„ the curriculum in the medical schools, relative to (W. S. Playfair) . . . . . xxi, 32
„ examiners in, at the Royal College of Surgeons, vote of thanks to Drs. Farre, Barnes, and Sir W. O. Priestley, on their resignation as . . . . . xviii, 112
„ modern, the forceps in (A. W. Edis) . . . xix, 69
„ phantom for obstetric classes, designed by Budin and Pinard (F. Barnes) . . . . . xix, 239
„ — employed for class purposes in (J. Braxton Hicks) . xix, 231
„ statistics of (H. W. Bailey) . . . . i, 279
„ — from the records of private practice (R. Dunn) . . i, 279
„ — in general practice (H. C. Rose) . . . xviii, 146
„ — of thirty-five years' practice (Clement Godson) . . xviii, 223
„ — in private practice (George Rigden) . . . xxiii, 151
„ synopsis of one thousand five hundred consecutive labours (W. T. Greene) . . . . . xix, 204
„ see also *Obstetrics*.

MIDWIVES, education, examination, and registration of . xvi, 22; xvii, 33; xix, 136; xx, 12; xxiii, 75; xxviii, 55; xxxii, 87, 365
„ alteration of laws respecting the Board for the Examination of . . . . . xxvi, 23; xxvii, 58
„ examinations—Chart 1872 to 1904 . . . xlvii, 78
„ — table showing result of, for each year since institution in 1872 . . . . . xlvii, 80
„ registration of, and proposal to petition for a select committee on . . . . . xxxiv, 34
„ notice of the prospects of legislation relative to . . xxi, 5
„ rules and regulations for . . . . xl, 367
MILK, effects of, when injected into the vascular system of animals (E. A. Schäfer) . . . . . xxi, 320
„ secretion of, in a new-born male child (W. Duncan) . xxx, 226
„ abscess (T. W. Nunn) . . . . . iii, 197
„ see *Galactorrhœa.*
Milligan (W. A.), pyelonephritis of pregnancy . . xlviii, 1
Milne (C. W.), variola in the fifth month, with consequent delivery at full term of a dead child . . . ix, 110
Milward (J.), cases in practice: monstrosities . . xiv, 140
MISCARRIAGE at the fourth month, case in which the uterus was plugged for hæmorrhage after (A. H. N. Lewers) . . xxxii, 356
„ see *Abortion.*
MISSED ABORTION (H. C. Pope) . . . . xxiv, 139
„ fœtus and membranes from a case of (Alban Doran) . xxvii, 224
„ case of, in which an early embryo in its amniotic sac was retained in the uterus for eight months (W. Duncan) xxxvii, 196
„ see *Abortion.*
MISSED LABOUR, so-called, with a case in illustration (R. Barnes) . . . . . xxiii, 81, 110
„ case of extra-uterine pregnancy simulating (A. Rasch) . xxv, 113
„ (five months); abdominal section and removal of sac; recovery in a full-term pregnancy in a rudimentary horn of uterus (J. H. Targett) . . . . . xlii, 276
„ see *Lithopædion.*
Mitchell (Sir Arthur), strong mental emotion affecting pregnant women as a cause of idiocy in the offspring . . xxvi, 124
Mitchell (J. T.), some of the exigencies connected with preternatural labour . . . . . ii, 257
„ nature and treatment of puerperal peritonitis . . iv, 96
„ early and entirely detached placenta in labour, producing internal and concealed hæmorrhage, of which the patient died soon after delivery . . . . viii, 282
„ ruptured uterus in about the seventh month of pregnancy . xi, 204
„ exhaustion and convulsions arising from protracted labour of more than six days' duration; craniotomy; recovery . xii, 368
„ necessity of adopting laws by which the wives of the labouring classes and the poor shall have secured to them in their labours the attendance of qualified accoucheurs, female as well as male . . . . . xv, 3
MITRAL VALVE, stenosis of, case of labour in a primipara suffering from (G. Coates) . . . . . xxviii, 108
MITTELSCHMERZ, intermenstrual pain (A. W. Addinsell) . xl, 137
„ microscopical slides from a case of intermenstrual pain (A. W. Addinsell) . . . . . xli, 3

MOLE, carneous or fleshy (W. B. Woodman and R. Hughes) . xviii, 3
„ — retained *in utero* five months after death of embryo, showing proliferation of epithelium of villi as a syncytium forming reticulating processes (A. L. Galabin) . . xlv, 240
„ early tubal (H. Briggs) . . . . . xlix, 223
„ or blighted ovum from supposed three months' pregnancy (A. W. Williams) . . . . . xiii, 95
„ hydatidiform, or vesicular, its nature and mode of origin (W. G. Hewitt) . . . . . i, 249
„ — case of (John Williams) . . . . xvii, 2
„ — (Wm. Duncan) . . . . xxv, 162, 233
„ — followed by chorio-epithelioma in a patient with bilateral ovarian cysts (J. D. Malcolm, R. H. Bell, and C. Lockyer) . xlv, 483
„ malignant hydatid—deciduoma malignum (J. B. Hellier) . xlv, 242
„ removed by abdominal section, chorionic villi of a tubal (A. H. N. Lewers) . . . . xxxviii, 106
„ tubal (A. H. N. Lewers). . . . xxxviii, 87
„ — removed by abdominal section (A. H. N. Lewers). xxxvii, 78
„ in case of tubal abortion, in process of extrusion at the time of operation (J. Bland-Sutton) . . . . xlii, 311
„ tubal, showing escape of the body of the embryo through the fimbriated opening, with retention of the head and amniotic cavity in the tube (J. S. Fairbairn) . . . xliii, 211
„ — with encysted hæmatocele (W. S. Handley) . . xliii, 255
„ — removed by colpotomy (J. McCann) . . . xliv, 133
„ — complicating carcinoma of the cervix (A. H. N. Lewers) . xlv, 335
„ associated with (?) sarcoma of the ovary of the same side (A. L. Galabin) . . . . . xlviii, 19
„ — (C. E. Purslow) . . . . . xlvi, 271
„ large uterine (T. Fitzpatrick) . . . . xx, 170
„ vesicular, and chorio-epithelioma found in association with compound lutein cystomata (C. Lockyer) . . . xlvii, 157
„ — showing syncytium derived from chorionic epithelium partially differentiated into cells (A. L. Galabin) . . xlv, 240
„ — (?) preceded by myxoma of fundus uteri: a myxoma of chorionic villi engrafted upon uterus (A. L. Galabin) . xlv, 241
„ treatment of, and premature expulsion of the fœtus (A. Ball) . . . . . i, 315

MOLLITIES OSSIUM: death (G. H. Pedler) . . . xiii, 123
„ pelvis deformed by (W. S. A. Griffith) . . . . xxvi, 230

MOLLITIES OSSIUM, see *Osteomalacia*.

MOLLUSCUM FIBROSUM, see *Tumours*.

MONKEYS, menstruation and ovulation of, and the human female (W. Heape) . . . . . xl, 161

MONSTER (A. Meadows) . . . . . iv, 255
„ (W. Gayton) . . . . . vii, 56
„ rare form of (H. Gervis) . . . . viii, 135
„ (A. Hall) . . . . . ix, 271
„ *report* on (A. Meadows and A. J. Bannister) . . ix, 112
„ with specimen (T. Langston) . . . . x, 37
„ two cases of (D. L. Roberts) . . . . x, 269
„ curious (G. de G. Griffith) . . . . xi, 5
„ (J. Oswald) . . . . . xii, 115
„ (R. E. B. Horniblow) . . . . . xii, 247
„ case of (F. Wallace) . . . . xvii, 176, 277

MONSTER (*continued*)—
„ (C. H. F. Routh) . . . . . xxiv, 75
„ (Maitland Coffin) . . . . . xxiv, 98
„ with skiagraph (A. H. N. Lewers) . . . xxxix, 131
„ acardiac, notes on, in the museums of London hospitals (Alban Doran) . . . . . xxxi, 4
„ acardiacus from a cow (J. Bland-Sutton) . . . xli, 97
„ amorphus acardiac fœtus (G. E. Herman for *G. M. Bluett*) . xxxiii, 493
„ — acephalus (F. E. Cockell) . . . . xxv, 110
„ — — from the museum of St. Bartholomew's Hospital (W. S. A. Griffith) . . . . . xxxi, 2
„ — — of six months' gestation, with rudimentary heart (Woodley Slyman) . . . . . xxxi, 258
„ — — (W. H. Kelson) . . . . . xxxiii, 195
„ — — twin (A. Routh) . . . . . xxxii, 347
„ anatomy and nature of two acardiac acephalic fœtuses (A. Keith) . . . . . xlii, 99
„ mylacephalous acardiac twin (H. E. Trestrail) . . xxxi, 2
„ — dissection of ditto (Alban Doran) . . . xxxi, 4
„ — acardiac twin (H. Page) . . . . xxxiii, 302
„ acardiacus mylacephalus (Alban Doran) . . xxxvii, 209
„ acephalous (W. Graily Hewitt) . . . . viii, 316
„ — (J. Milward) . . . . . xiv, 140
„ — embryo (Clement Godson) . . . xvi, 100, 121
„ — acardiac fœtus (M. Handfield-Jones) . . xxxiv, 84
„ — — — (G. E. Herman) . . . xxxvi, 65
„ acephalo-cyclopean (R. Hardey) . . . . iv, 213
„ anencephalian (R. U. West) . . . . i, 105
„ anencephalous fœtus (A. Meadows) . . . i, 51
„ — — (H. L. Sequeira) . . . . v, 195
„ — — (J. B. Hicks) . . . . . vi, 226
„ — — specimen of (O. Barber) . . . . xvii, 341
„ — — (W. Culver James) . . . . xxii, 241
„ — — (H. C. Pope) . . . . . xxiii, 178
„ — — with spina bifida (F. Wallace) . . . xxiii, 204
„ — — at the eighth month (H. R. Spencer) . . xxx, 408
„ — — (Alban Doran) . . . . xxxi, 52
„ — — (W. S. A. Griffith) . . . . xxxi, 134
„ — — (A. Perigal) . . . . . xxxi, 165
„ — — (W. Duncan) . . . . . xxxi, 202
„ anencephalic fœtus (H. Hailey) . . . . vii, 78
„ — — (H. S. Ballance) . . . . xxxv, 297
„ — — (Amand Routh) . . . . xxxv, 241
„ — — skull of (Amand Routh) . . xxxvii, 219
„ — completely cleft spine associated with an unusual visceral malformation in (T. G. Stevens) . . xxxviii, 346
„ — — di-prosopus anencephalicus (Amand Routh) . xxxviii, 92
„ — di-prosopia fœtus (Amand Routh) . . xxxvii, 162
„ child born with amputated extremities (I. B. Brown) . viii, 102
„ with caudal appendage (A. Meadows) . . . ix, 112
„ cyclopean (J. A. Thompson) . . . . xv, 35
„ the delivery of a (R. H. A. Schofield) . . . xxi, 71
„ deformed fœtus with cystic tumour of neck (A. H. N. Lewers) xxxviii, 106
„ fœtus papyraceus (W. Rivers Pollock) . . xxxviii, 320
„ — — (H. J. Hott) . . . . xxxvii, 7
„ dicephalous fœtus (P. Horrocks) . . . . xxvi, 326
„ — — (John Phillips) . . . . . xxviii, 278

MONSTER (*continued*)—
„ dicephalous fœtus, heart and large vessels of (John Phillips) . xxix, 55
„ two fœtal (T. H. Tanner) . . . . ii, 247
„ fœtus at seven months illustrating celosoma with retroflexion, meningocele, and talipes varus (Leith Napier) . . xxxvi, 116
„ monstrous fœtus (R. Barnes) . . . . vii, 227
„ fœtal (John Phillips) . . . . . xxxix, 44
„ of seventh month removed by hysterectomy (H. Macnaughton-Jones) . . . . . xlvii, 302
„ two-headed, with the bodies united from the breast downwards (G. G. Bantock) . . . . . xviii, 223
„ — and three arms (J. Palfrey) . . . xix, 40, 97
„ double, united children (H. Hanks) . . . iii, 414
„ — (F. F. Jay) . . . . vi, 222
„ — with account of the delivery (W. Wills) . . vii, 6
„ — (J. G. Swayne) . . . ii, 320; viii, 1
„ — (H. Gervis) . . . . x, 197
„ — (J. F. Rogers) . . . . xi, 128
„ — (Clement Godson and F. S. Eve) . . xxii, 73, 74
„ — (Clement Godson) . . . . xxii, 109
„ — (Charles Wenyon) . . . . xxxiii, 384
„ mechanism and management of delivery in cases of double (W. S. Playfair) . . . . viii, 300
„ conjoined twins (thoracopagus) (W. Duncan) . xxxvii, 198
„ — case of (Clement Godson) . . . xx, 171; xxi, 88
„ — — — Marie- Rosa Drouin (D. C. MacCallum) . . xx, 120
„ — — — Rozalie and Josepha Blazet (W. S. Playfair) . xxii, 265
„ — — — (Percy Boulton) . . . xxiii, 260
„ rare form of twin (R. Ellis) . . . . vii, 160
„ twin (P. Horrocks) . . . . xlvi, 183
„ double, of dicephalous type (C. O. Fowler) . . xl, 119
„ one of twins (H. Gervis) . . . . x, 113
„ twin, one-headed (Harvey Hilliard) . . . xxii, 3
„ — in its seventh month (J. Chalmers) . . . xxii, 155
„ — female (A. L. Galabin) . . . . xxvii, 305
„ — (Clement Godson and D'Arcy Power) . . xxviii, 68
„ — ischiopagus parasiticus (J. Chalmers) . . . xxv, 111
„ which lived for some time after birth (W. Ross) . . ix, 31
„ sireniform, skiagram of (Herbert Spencer) . . xxxviii, 118
„ living female child with three lower limbs (Clement Godson) xxxii, 132
„ with congenital ventral hernia (J. Brunton) . . xxi, 118
„ with remarks on the influence of maternal impressions on the fœtus *in utero* (A. Meadows) . . . . vii, 84
„ resulting from amniotic adhesion to skull (John Phillips) xl, 130; xxxviii, 388

MOODELLY (P. S. M.), ovariotomy . . . . x, 115

MOORE (T. N.), see *Meadows, A.*

MORISON (J. RUTHERFORD), a case of deciduoma malignum occurring in England . . . . xxxviii, 130
„ secondary growth from vagina of deciduoma malignum . xlv, 249
„ deciduoma malignum of uterus . . . . xlv, 249

MORPHIA, in relief of the pain in pelvic cancer (F. H. Champneys) . . . . . xxii, 5

MORSE (THOMAS H.), case of dermoid ovarian cyst impacted in the pelvis which was removed by abdominal section during the ninth month of pregnancy . . . xxxviii, 221

MORTALITY in childbed both in hospital and in general practice (R. Boxall) . . . . . xlvii, 196
„ in lying-in hospitals (A. L. Galabin) . . . xxxi, 92
„ maternal and fœtal, the more frequent use of the forceps as a means of lessening (P. H. Harper) . . . i, 142
„ after obstetric operations, remarks on tables of (J. B. Hicks and J. J. Phillips) . . . . . xiii, 55
„ causes of, in ovariotomy (W. T. Smith) . . . iii, 41
„ among infants, notice of the Special Committee on . . xi, 24
„ Report of the Infant Mortality Committee . . xi, 132

Moullin (J. A. Mansell), case of extra-uterine fœtation . xxv, 103
„ case of hypertrophy of the breasts . . . xxv, 212
„ inversion of uterus . . . . . xxvi, 158

Mowat (George), case of apparent absence of uterus . . xx, 289

MUCOUS MEMBRANE, ovarian cysts with (J. Bland-Sutton) . xxx, 339
„ of uterus, hæmorrhage from, in an infant (C. H. James) . xxxii, 66
„ — of an infant suffering from uterine hæmorrhage (S. W. Wheaton) . . . . . xxxiv, 190

Muir (R. D.), placenta from a case of accidental hæmorrhage . xxxv, 338

MULTIPAROUS UTERUS, measurements of, as compared with the nulliparous (J. Braxton Hicks and A. W. Edis) . xviii, 70, 74

MÜNCHMEYER'S TRANSFUSION APPARATUS (J. Matthews Duncan) . . . . . xxxii, 5

Murphy (James), sequel to a case of ovariotomy . . xxvii, 108

Murray (G. C. P.), exomphalos, in which the gravid uterus formed the hernial mass . . . . i, 77
„ ascites with ovarian disease . . . . v, 190
„ fibrous tumour of the cervix uteri . . . vi, 184
„ two large kidneys . . . . viii, 5
„ ovariotomy trocar and cannula . . . . viii, 313
„ ulceration of os and allongement of cervix uteri . . ix, 30
„ new pelvimeter by Dr. Byford, of Chicago . . x, 39
„ peculiar knotted cord . . . . xi, 54
„ intra-uterine fibroid removed by single-wire écraseur . xi, 78
„ specimen of fibroid uterus, showing the three forms of the disease—subperitoneal, interstitial, and submucous - xvi, 248
„ flexible vertebrated uterine sound . . . xviii, 140

Murray (John), pocket chloroform inhaler . . . x, 95

Murphy (J.), see *Godson, Clement.*

MUSCLES of the female pelvis and perineum, dissection of (Alban Doran) . . . . . xxviii, 274
„ ossification of (E. H. M. Sell) . . . . xv, 125

Musgrave (J. T.), case of abortion followed by septicæmia and fatal cardiac thrombosis . . . . xxi, 81

MYO-FIBROMA of the uterus, three specimens of (H. Gervis) . xxv, 108

MYOMA, large, of left broad ligament (Wm. Duncan) . . xxxi, 309
„ uterine, four cases of removal of large, by abdominal section (Lawson Tait) . . . . . xix, 274
„ — note on its pathology and treatment (Lawson Tait) . xxv, 194
„ — and polypus, ovarian cyst (J. Crawford) . . xxxiii, 74

MYOMA (*continued*)—
„ uterine, abdominal hysterectomy for; with brief notes of twenty-eight cases (J. Bland-Sutton) . . . xxxix, 292
„ — (F. J. McCann) . . . . xl, 3
„ degenerating uterine (W. Duncan) . . xxxvii, 147
„ uterine, diffuse (non-capsulated) (C. J. Cullingworth) xxxvii, 143
„ — large gangrenous interstitial (C. J. Cullingworth) . xxxvi, 268
„ — soft, showing early cystic degeneration (J. H. Aveling) . xxvi, 270
„ cystic, of uterus weighing over 15 lb. (Alban Doran) xxxviii, 164
„ cystic intra-ligamentous, with double uterus (W. J. Gow) . xl, 134
„ fibro-cystic, of the uterus (J. Knowsley Thornton) . . xxvi, 54
„ — of uterus with septicæmia (H. A. Lediard) . . xxvi, 193
„ large fibro-cystic, growing from the cervix uteri (C. J. Cullingworth) . . . . xxxviii, 8
„ and fibro-myoma of the uterus and allied tumours of the ovary (Alban Doran) . . . . xxx, 410
„ of uterus, œdematous (W. Duncan) . . xxxvii, 148
„ œdematous (R. H. O'Callaghan) . . . xxxvii, 201
„ polypoid, of the uterus (Aust Lawrence) . . . xxxii, 366
„ submucous and interstitial, removed by hysterectomy, uterus with (W. Duncan) . . . . xxxix, 290
„ necrotic change in a small uterine, occurring in a young subject (C. J. Cullingworth) . . . xxxvii, 284
„ uterine, undergoing red degeneration (W. F. V. Bonney) . xlv, 464
„ carcinoma of the corpus uteri invading, hysterectomy (J. M. Munro Kerr) . . . . xlvii, 191
„ of the cervix uteri (C. J. Cullingworth) . . xxxiv, 223
„ of the neck of the uterus (J. Bland-Sutton) . xxxix, 161
„ pure, of ovary, with a microscopic section (A. Doran) . xliv, 168
„ placenta prævia complicated by a large (J. Hickinbotham) . xxiii, 167
„ of the vagina (F. J. McCann) . . . xlviii, 182
„ vaginal hysterectomy in the puerperium for sepsis due to suppuration of (A. W. W. Lea) . . . xlvii, 1
„ see *Fibro-myoma.*

MYOMECTOMY, abdominal, for the removal of a solitary interstitial fibroid (W. S. Handley and C. Lockyer) . . xlv, 51
„ — in second month of pregnancy, for fibro-myoma; labour at term (A. Doran) . . . . xlvii, 426
„ remarks on, in connection with a case of fibro-myoma of the uterus in a patient aged 23 (A. E. Giles) . . . xlii, 299
„ during pregnancy and labour at term in an elderly primipara, with notes on similar cases (A. Doran) . . . xlviii, 303

MYXO-CARCINOMA of abdominal wall and ovaries (W. S. A. Griffith) . . . . . xxviii, 180

MYXO-FIBROMA of cervix uteri (A. L. Galabin) . . xxviii, 178

MYXOMA of the labium majus (M. Handfield-Jones) . . xlvii, 362
„ of chorion not discharged till the seventh month (C. H. Roberts) . . . . . xlii, 168
„ of chorionic villi engrafted upon uterus; myxoma of fundus uteri following vesicular mole (?) (A. L. Galabin) . . xlv, 241
„ of fundus uteri following vesicular mole (?) a myxoma of chorionic villi engrafted upon uterus (A. L. Galabin) . xlv, 241
„ in a fœtus impeding delivery (T. C. Hayes) . . xviii, 83
„ of both ovaries, associated with leukæmia (A. L. Galabin) . xx, 123

MYXOMA FIBROSUM of Virchow (?) (W. S. A. Griffith) . xxx, 82

MYXOMATOUS DEGENERATION, see *Degeneration.*

MYXOMATOUS GROWTH of the peritoneum (John Williams) . xxiv, 93

MYXO-SARCOMA of urethra in a child (A. L. Galabin) . xxxviii, 120
„ of the uterus removed by pan-hysterectomy (Amand Routh) . xli, 139
„ — supposed, removed by abdomino-vaginal method (Amand Routh) . . . . . xli, 367
„ of vagina in a child aged 2½ (A. W. W. Lea) . . xlii, 143

NAEGELE, pelvis of, remark on (F. H. Chamyneys) . . xxiv, 191
„ pelvis (J. H. Targett) . . . . . xli, 231
„ oblique pelvis of, on the production of the shape of (G. E. Herman) . . . . . xxviii, 6
„ — notes of a specimen of (W. S. A. Griffith) . xxviii, 83, 84
„ — and the influence of the lumbo-sacral curve in the mechanism of labour (R. Barnes) . . . . xxv, 258
„ pseudo-osteo-malacic pelvis of (W. S. A. Griffith) . . xxvii, 186

Napier (A. D. Leith), specimen of axial rotation of a right-sided parovarian cyst with attached right ovary and Fallopian tube distended by hæmorrhage . . xxxiv, 124
„ — of cystic ovary and enlarged tube; abdominal section; history of pregnancy within two months . . xxxiv, 126
„ fœtus of four months' development contained within an unruptured amnial sac with placenta prævia attached . xxxiv, 158
„ large multiple fibro-myoma removed by hysterectomy . xxxiv, 159
„ successful case of Cæsarean section . . . xxxiv, 105
„ — adjourned discussion . . . . xxxiv, 138
„ hæmatosalpinx, hæmorrhagic and cystic ovaries . . xxxiv, 439
„ multiple fibro-myoma . . . . . xxxv, 3
„ needles, needle-holder, and self-retaining speculum . . xxxv, 3
„ large dermoid cyst with dentigerous plate . . . xxxv, 429
„ solid tumour . . . . . xxxvii, 283
„ — tumours . . . . . xxxviii, 29
„ fœtus at seven months illustrating celosoma with retroflexion, meningocele, and talipes varus . . . . xxxvi, 116
„ suppurating dermoid cyst . . . . xxxiii, 460
„ macerated fœtus; double tubal disease . . . xxxiii, 461
„ habitual abortion . . . . . xxxii, 389
„ case of trismus nascentium . . . . xix, 5

Napper (Albert), defective formation of skin round the umbilicus; plastic operation . . . . . iii, 65
„ amputation of the arm in pregnancy . . . vii, 12

Nash (W. G.), needle, "grip-eyed" (H. J. Paterson) . . xlvii, 250
„ repeated tubal gestation: removal of unruptured tube; recovery . . . . . xlvii, 408

NAVEL, case of exomphalic fœtus (A. E. Giles and R. J. Probyn-Williams) . . . . . xxxvi, 174

NAVEL CORD of a young infant, note on a condition observed in (John Williams) . . . . . xxvi, 199

NAVEL-ILL in lambs, notes on (J. Hutchinson) . . xviii, 88

Neale (J.), singular malformation . . . . viii, 259

NECROBIOSIS or red degeneration of large uterine fibroids (A. H. N. Lewers) . . . . . xlviii, 173

NECROSIS of pubic bones following delivery (W. S. Playfair) . xv, 219
„ of central portion of sarcoma of ovary lying in an abscess cavity containing offensive pus (W. W. H. Tate) . xli, 373
„ of solid masses in unilocular ovarian cyst (J. S. Fairbairn) . xliv, 126

NEEDLE, curved, made to revolve, for cases of vesico-vaginal fistula (J. H. Aveling) . . . . . xix, 66
„ fibroid tissue formed around a, removed from the left labium majus (H. Briggs) . . . . . xlix, 223

NEEDLE-HOLDER, Kurz (H. R. Spencer) . . . xlv, 51
„ Hagedorn's surgical (G. G. Bantock) . . . xxvi, 271
„ and self-retaining speculum (Leith Napier) . . xxxv, 3

NEOPLASMS, uterine and ovarian, tumour showing the impossibility, in some cases, to diagnose between (J. D. Malcolm) . xxix, 249

NEUGEBAUER (FRANZ LUDWIG), specimens illustrating spondylolisthesis . . . . . xxvi, 84
„ — *report* on ditto by committee (R. Barnes, W. Adams, Noble Smith, and Alban Doran) . . . . xxvi, 186

NEUROSIS, removal of the uterine appendages in cases of functional (W. S. Playfair) . . . . xxxiii, 7

NEWHAM (SAMUEL), description of the "guide-hook," a new obstetric instrument . . . . . vi, 7

NEWMAN (W.), patient who in eighteen pregnancies gave birth to only seven living children, the eleven others having been expelled dead at various periods of gestation . . iii, 408
„ enormous development of hydatids in omentum, simulating an ovarian tumour . . . . . iv, 169
„ Cæsarean section; recovery of mother; child not viable . viii, 343
„ — in 1866; subsequent pregnancy and delivery *per vias naturales*; recovery . . . . . xiv, 142
„ remarks in the discussion on puerperal fever . . xvii, 105
„ uterus with extensive epithelial disease of the os and cervix uteri . . . . . xvii, 213
„ remarks in the discussion on the use of forceps . . xxi, 153
„ case of inversion of uterus of sixteen months' standing; replacement; recovery . . . . . xxxi, 166
„ see *Harley, G.*

NIGHTDRESS for ladies during and after childbirth (— Stewart) xvi, 87

NIPPLES, eczema of, in both breasts (Thos. Chambers) . . xxii, 266
„ three cases of three, in the human subject—one case hereditary (W. B. Woodman) . . . . ix, 50
„ sore, treatment of (H. C. Rose) . . . . iv, 135
„ see *Breasts.*

NIPPLE SHIELD, Auvard's (Clement Godson) . . xxx, 198
„ (F. Taylor) . . . . . iv, 228
„ and the treatment of sore nipples (H. C. Rose) . . iv, 135

NITRATE OF SILVER, properties of, with an account of a new instrument for its use in uterine disease (R. Ellis) . . iv, 116

NODES (John D. S.) and FRANK HINDS, fatal rupture of an aneurysm of the splenic artery immediately after labour . xlii, 305

NODULE, sarcomatous, in the centre of a fibroid of uterus (Amand Routh) . . . . . xlix, 1

NORTON (SELBY), teething . . . . . xi, 183

NOSE, congenital absence of, right palpebral fissure and right ear; imperforate anus, etc. (W. Duncan) . xxxvii, 16

NÜCK, hydrocele of the canal of, containing a portion of the left Fallopian tube (L. Remfry) . . . . . xl, 9

NULLIPAROUS UTERUS, note on the *post-mortem* diagnosis of (A. Meadows) . . . . . xvii, 355; xviii, 69
„ measurements of, as compared with the multiparous (J. Braxton Hicks and A. W. Edis) . . xviii, 70, 74

NUNN (T. W.), inflammation of the breast and milk abscess, with an analysis of seventy-two cases . . . . iii, 197
„ destructive inflammation of the hip-joint in a puerperal woman . . . . . vi, 116

NYMPHA, hypertrophied (R. Greenhalgh) . . . x, 57
„ hypertrophied (Fancourt Barnes) . . . xxv, 165
„ and clitoris, hypertrophied (W. Duncan) . . xxxvi, 3, 149

OBLIQUITY, lateral, of the fœtal head, the causation of (A. L. Galabin) . . . . . xxv, 252
„ of pelvis, see *Pelvis*.

OBSTETRIC binder and special position as aids in the treatment of impeded parturition (R. Hardey) . . . ii, 79

OBSTETRICS, memorial *re* representation on General Medical Council of . . . . . xi, 124
„ anæsthetics in practice of (A. E. Sansom) . . . x, 121
„ the advantages of antiseptics in practice of (W. O. Priestley) . xxvii, 197
„ direct representation of, at the General Medical Council xvi, 21; xxiii, 46
„ electrical instruments in use in (W. E. Steavenson) . xxix, 298
„ of the kyphotic pelvis (F. H. Champneys) xxv, 166; xxviii, 253
„ studies in (C. F. Ponder) . . . . xl, 339
„ see also *Midwifery*.

O'CALLAGHAN (R. H.), œdematous myoma . . xxxvii, 201

OCCIPUT, serous tumour in region of (W. B. Woodman) . vii, 158

OCCLUSION of the pulmonary arteries seventeen days after parturition (D. Mackinder) . . . . i, 213
„ complete, of the os uteri, with retention of menses after difficult labour (J. H. Davis) . . . . iv, 91
„ of the vagina in a case of absence of the uterus (F. Bousquet) xxvii, 123

ŒDEMA of the lower half of the body, after a fall in the seventh month of pregnancy; premature labour; recovery (A. Rasch) vii, 80
„ two cases of fœtal ascites and (H. R. Andrews) . . xliii, 166

OFFICERS of the Society, alteration of laws respecting the xxvii, 58; xxxvii, 288; xxxix, 53

OGSTON (F.), see *Hicks, J. Braxton*.

OLDHAM (H.), retroflexion of the gravid uterus during labour at term . . . . . i, 317
„ fibroid polypus removed by Hicks' instrument . . iii, 349
„ presidental address . . . . vi, 14; vii, 19
„ ovarian tumour . . . . . vi, 75

O'Meara (F. A. T.), case of dilatation and hypertrophy of the bladder in a fœtus . . . . . xxix, 54

OMENTUM, colloid tumours, large conglomerate of, grown from the (R. Barnes) . . . . . xvii, 216; xviii, 193
„ cyst of the great (Alban Doran) . . . . . xxiii, 164
„ tubal gestation in which the ovum continued to grow for about four weeks after rupture, the gestation sac becoming implanted on (C. Lockyer) . . . . . xlv, 400
„ hydatids in, simulating an ovarian tumour (W. Newman) . iv, 169
„ malignant tumour of (G. D. Brown) . . . . xviii, 24
„ hydatids of, or connected with (C. J. Cullingworth and H. H. Clutton) . . . . . xlvi, 254
„ cystic sarcoma of, simulating ovarian tumour; removal; recovery (W. Duncan) . . . . . xxxvi, 264

OÖPHORECTOMY, calcified uterine fibro-myoma removed piecemeal for hæmorrhage fourteen years after (H. R. Spencer) . xlix, 271
„ ovaries and Fallopian tubes removed by (J. Knowsley Thornton) . . . . . xxiv, 137
„ uterus with fibroid tumours and carcinoma of the cervix removed *post mortem* from a patient on whom eight years previously had been performed the operation of (G. F. Blacker) . . . . . xxxvii, 213

OÖPHORITIS, see *Ovaries*.

OÖPHORON, multilocular cyst of (Cuthbert Lockyer) . . xlii, 37

OPERATIONS, obstetric, remarks on tables of mortality after (J. B. Hicks and J. J. Phillips) . . . . . xiii, 55

OPHTHALMIA NEONATORUM, the prevention of, and of its ravages (D. McKeown) . . . . . xxvii, 49
„ — and treatment of, by Crédé and others (J. Watt Black) . xxxv, 88
„ its ætiology and prevention (S. Stephenson) . . xlv, 337

OS INNOMINATUM, macerated, from case of malignant disease (T. C. Hayes) . . . . . xvi, 174

OSSIFICATION, spinal column exhibiting want of, in the interarticular portion of the lumbar vertebræ (G. F. Blacker) . xlii, 90

OSTEOMALACIA, abstract of a memoir on, by Dr. Gaetana Casati, of Milan (R. Barnes) . . . . . xiii, 244
„ ovaries removed from a case of (A. Rasch) . . xxxiv, 462
„ cured by excision of the ovaries (A. Rasch) . . xxxv, 39
„ on the influence of the removal of the ovaries on metabolism in connection with (J. E. Curatulo) . . xxxviii, 17
„ pelvis deformed by (W. S. A. Griffith) . . . xxvi, 230

OSTIUM, on closure of, in inflammation and allied diseases of the Fallopian tube (Alban Doran) . . . . xxxi, 344

OS UTERI, occlusion of (J. H. Davis) . . . iv, 91
„ see also *Uterus*, os uteri.

OS VAGINÆ, see *Vagina*, os vaginæ.

Oswald (J.), monstrosity . . . . . xii, 115

Oswald (J. W. J.), case of suppurating tumour of left ovary . xvii, 168
„ — Cæsarean section for deformed pelvis . . . xvii, 378
„ cancer of ovary extending to uterus and rectum . . xviii, 122
„ case of hypertrophy of spleen and liver in a child, aged 9 . xviii, 191
„ see *Routh, C. H. F.*

OUTHWAITE (WILLIAM), placenta of, double ovum . . xxiv, 3

OVARIAN TUMOURS (P. Smith) . . . . xiii, 98
„ and treatment of pedicle by acu-pressure needle (A. Wiltshire) . . . . . xii, 31
„ changes in pedicle of, when treated by ligature (G. G. Bantock) . . . . . xiv, 2
„ grappling iron for use in removal of (Heywood Smith) . xxii, 45

OVARIES, abscess of; peritonitis; death (A. W. Edis) . . xiii, 99
„ — (Heywood Smith) . . . . . xxxiv, 3
„ multiple abscesses of, with pyosalpinx (C. J. Cullingworth) . xxxix, 47
„ three cases of pelvic inflammation attended with abscess of the (C. J. Cullingworth) . . . . xxxvi, 277
„ inoperable papilloma of, pelvic organs of a case (A. Routh) . xlix, 216
„ absence of, note on the involution of the puerperal uterus in the (John Williams) . . . . . xxvi, 203
„ and uterus absent in three sisters (C. E. Squarey) . . xiv, 212
„ after attempt at abortion (T. Ballard) . . . xii, 3
„ unusual example of rupture of an ovarian adenoma (J. Bland-Sutton) . . . . . xli, 98
„ adeno-carcinoma of both (W. W. Lea) . . . xliv, 225
„ — (F. N. Boyd) . . . . . xlix, 50
„ removed by abdominal section, adeno-carcinoma of uterus and left (W. Duncan) . . . . . xxxix, 289
„ apoplexy of, cystic dilatation without rupture (A. Doran) . xxxii, 119
„ — double, from a case of acute peritonitis (H. A. DesVoeux) . xxxiv, 214
„ atrophy of, and deficient development of the uterus (A. Doran) . . . . . xxi, 253
„ — with collapse (cirrhosis), fibroid degeneration, and angioma of (J. Braithwaite) . . . . . xxxvi, 325
„ containing a calcareous ball, probably a large calcified corpus fibrosum (J. Bland-Sutton) . . . . xl, 223
„ blood concretions in (A. Doran) . . . . xl, 214
„ cancer of, extending to uterus and rectum (J. W. J. Oswald) . xviii, 122
„ case of supposed cancer of both (J. L. Worship) . . xix, 235
„ cancer of both, primary to carcinoma in the muscular wall of the uterus (C. Lockyer) . . . . xlvi, 302
„ primary cancer of (A. L. McIlroy) . . . xlviii, 251
„ carcinoma of (C. J. Cullingworth) . . . xxxii, 199
„ — of unusual type (C. Lockyer) . . . . xlvi, 349
„ — (W. W. H. Tate) . . . . . xlviii, 96
„ primary carcinoma of both (C. Lockyer) . . . xlvi, 229
„ — solid (W. S. A. Griffith) . . . . xlii, 34
„ carcinoma of the body of the uterus with secondary growth in both (H. T. Hicks) . . . . . xlviii, 196
„ — with cystic fibroid (R. Boxall) . . . . xlviii, 136
„ — hæmorrhagic (C. J. Cullingworth) . . . xxxiii, 445
„ carcinomatous tumour of (J. S. Fairbairn) . . . xliii, 208
„ chorion-epithelioma of the uterus; lutein cysts in both (G. F. Blacker) . . . . . xlix, 104
„ new method of examination of the tumour in cases of suspected cystic disease of (W. G. Hewitt) . . . i, 55
„ cyst of, co-existing with pregnancy, which ruptured spontaneously ten days after labour (C. Clay) . . . i, 226
„ — (A. W. Edis) . . . . . xiii, 41
„ — complicating labour (A. H. Brewer) . . . xx, 184

OVARIES (*continued*)—
„ cystic disease of, complicating pregnancy (J. B. Hicks) . xi, 263
„ — probable origin of (A. Meadows) . . . . xiv, 39
„ — both (C. H. Carter) . . . . . xxv, 109
„ — — in its earliest stage (R. Barnes) . . . xxvi, 157
„ — — (F. A. Purcell) . . . . . xxvii, 5
„ — — removed for dysmenorrhœa (W. Duncan) . . xxviii, 211
„ — — and hypertrophied Fallopian tubes (John Phillips) . xxxi, 332
„ cystic, the seat of hæmorrhage (M. Handfield-Jones) . xxxiii, 27
„ cyst of, highly congested from twisting of pedicle (J. Knowsley Thornton) . . . . . xxv, 164
„ — (W. Duncan) . . . . . xxxi, 255
„ — in connection with uterine fibroid (F. H. Daly) . xvi, 122, 202
„ — with fibroid of the uterus, and ascitic fluid from peritonitis (A. W. Edis) . . . . . xx, 164
„ — presence of limpid fluid in (A. L. Galabin) . . xxi, 288
„ — in a case of hypertrophy and anteflexion of the uterus (Graily Hewitt and A. Q. Silcock) . . . xxv, 131
„ — giving rise to a hæmatocele (W. Duncan) . . xxviii, 210
„ — with mucous membrane (J. Bland-Sutton) . . xxx, 339
„ — and hæmatosalpinx (W. S. Playfair) . . xxxi, 130, 162
„ — ruptured secondary, in the wall of a multilocular tumour of (A. Doran) . . . . . xxvi, 118
„ hæmorrhagic and cystic (A. D. Leith Napier) . . xxxiv, 439
„ cyst, pair of incipient (J. D. Malcolm) . . . xxxiii, 29
„ — uterine myoma and polypus (J. Crawford) . . xxxiii, 74
„ — fatal rupture in an infant (A. Doran) . . . xxxiv, 24
„ — sarcoma, anterior serous perimetritis simulating (A. Doran) . . . . . xxxiii, 185
„ — suppurating, treatment by drainage (J. J. Phillips) . xiv, 340
„ — — (C. J. Cullingworth) . . . . xxxiii, 446
„ — uterus and appendages from patient with (P. Smith) . xiii, 126
„ — and enlarged tube (A. D. Leith Napier) . . xxxiv, 126
„ multilocular cyst of left, removed six years after removal of right ovary (T. Spencer Wells) . . . . x, 19
„ cyst, multilocular (John Williams) . . . xxiv, 77
„ — — (W. Duncan) . . . . xxv, 212, 234
„ — — (J. Knowsley Thornton) . . . . xxvi, 55
„ — — (W. Walter) . . . . . xxvi, 148
„ — — and fibroma (?) of the opposite (P. Horrocks) . . xxxiii, 200
„ multilocular tumour of (W. Duncan) . . . xxvi, 229
„ papillomatous cysts of, removed during the fourth month of pregnancy (W. A. Meredith) . . . . xxxii, 374
„ — cyst of both, causing profuse ascitic effusion (A. Doran) . xxxiv, 149
„ — cyst of (A. H. N. Lewers) . . . . xxxiv, 462
„ tumour closely simulating a papillomatous ovarian cystoma attached to the front of the bladder and quite separate from both (J. D. Malcolm) . . . . . xli, 226
„ papillomatous accessory (A. L. Galabin) . . . xliii, 267
„ cystoma, papillomatous, removed after double ovariotomy fifteen years previously (J. D. Malcolm) . . . xxxv, 36
„ — from Graafian follicles, and limpid fluid in true ovarian cysts (A. L. Galabin) . . . . . xxi, 288
„ piliferous cyst of (R. Barnes) . . . . vi, 249
„ cyst of (T. W. Eden) . . . . . xxxv, 408
„ two cirrhotic and cystic, with microscopical section of same (L. Remfry) . . . . . xxxvi, 184

OVARIES (*continued*)—
„ dilated tubes and cystic (early stage of tubo-ovarian cysts) (W. Duncan) . . . . xxxvii, 150
„ cyst of, and hydrosalpinx removed by anterior colpotomy (Amand Routh) . . . . xxxviii, 185
„ cystic (G. Drummond Robinson) . . . . xxxix, 130
„ tubo-ovarian cyst (W. S. A. Griffith) . xxix, 273, 302; xxx, 3
„ only congested and inflamed in two cases of parovarian cyst with twisted pedicle (H. R. Spencer) . . . xlii, 333
„ right, inguinal hernia of, successfully removed (A. Meadows) iii, 438
„ pregnancy after removal of both, for cystic tumour (A. Doran) . . . . . xliv, 231
„ tumour of, complicating pregnancy; cyst ruptured during examination; immediate laparotomy; recovery (W. Duncan) xxxvi, 312
„ unilocular, pathology of certain so-called . . . xv, 105
„ unilocular cyst involving both, and with both Fallopian tubes attached (J. Knowsley Thornton) . . . xxi, 119
„ — — containing solid masses undergoing necrotic change (J. S. Fairbairn) . . . . . xliv, 126
„ dermoid cyst of right; *post-mortem* (W. B. Woodman) . vii, 158
„ — — (J. Knowsley Thornton) . . xxiii, 104; xxvii, 46
„ — — (G. G. Bantock) . . . . xxv, 38
„ — — (Heywood Smith) . . . . xxvi, 57
„ — — (C. H. Carter) . . . xxvi, 86, xxxii, 6
„ — — microscopic sections of (A. Doran) . . . xxiii, 105
„ — — myxomatous growth of the peritoneum (John Williams) xxiv, 93
„ — — twisting of pedicle in (A. Doran) . . . xxiv, 133
„ — — sarcomatous (J. Knowsley Thornton) . . xxvii, 194
„ — — pressure of, causing retention of urine (W. S. A. Griffith) xxxi, 135
„ — — in a mare (C. S. Pollock) . . . xxxi, 234, 253
„ — — containing three (S. W. Wheaton) . . . xxxiii, 28
„ — — (J. Mackenzie) . . . . xxxiii, 461
„ — — (A. C. Butler-Smythe) . . . xxxiii, 463
„ — — (J. Bland-Sutton) . . . . xxxiv, 5
„ — — infiltration of broad ligament with fat (J. Bland-Sutton) . . . . . xxxiv, 7
„ — — of right; twisted pedicle (W. Duncan) . . xxxvi, 267
„ — — impacted in the pelvis, which was removed by abdominal section during the ninth month of pregnancy (T. H. Morse) . . . . . xxxviii, 221
„ — — of size of a child's head, in case of ruptured uterus (A. H. N. Lewers) . . . . . xlii, 95
„ — — obstructing labour; displacement of the tumour from the true pelvis and extraction of the child with forceps; removal of tumour five weeks later; recovery (J. M. Munro Kerr) . xliii, 145
„ — — removed by posterior colpotomy (A. Routh) . . xliv, 38
„ — — removed by abdominal section five years after causing obstruction to labour (W. W. H. Tate) . . . xlvi, 344
„ — — with minute pedicle produced by torsion of mesovarium only (A. L. Galabin) . . . . . xlvii, 331
„ — tumour of (J. Knowsley Thornton) . . . xxiv, 80
„ — — bony girdle from (S. W. Wheaton) . . . xxxv, 4
„ — — dentigerous bony plates from (A. Doran) . . xxxi, 86
„ — — (Wm. Duncan) . . . . xxxi, 255
„ — — (J. Bland-Sutton) . . . . xxxi, 338
„ — — of both; twisted pedicle (R. Boxall) . . xli, 5
„ disease (J. L. Worship) . . . . xi, 76

OVARIES (*continued*)—
„ disease of, with ascites (G. C. P. Murray) . . . v, 190
„ — complicating puerperal peritonitis, followed by febrile diseases of the puerperal state (R. U. West) . . . i, 187
„ — both, the right ovary forming a communication with the cæcum and externally; the left tumour emptying itself into the rectum; death, and *post-mortem* results (H. C. Rose) . ix, 44
„ — two cases of malignant embryoma of (H. T. Hicks and J. H. Targett) . . . . . xlvii, 287
„ — fibro-cystic disease of uterus mistaken for (C. H. F. Routh) . . . . . viii, 122
„ — — extirpation; recovery (T. Bryant) . . . xiv, 79
„ — labour complicated with (R. T. Warn) . . . xi, 198
„ — complicating pregnancy (T. Spencer Wells) . . xi, 251
„ — (V. Saboia) . . . . . xii, 312
„ large fibrous tumour of, removed by ovariotomy (L. J. Martin) xii, 302
„ fibroid tumour of the right (C. H. Carter) . . . xxiv, 139
„ — — removed by abdominal section (John Williams) . xxv, 35
„ — — with a papilliferous cyst (John Williams) . xxix, 247, 513
„ — — five specimens of, with observations on their pathological anatomy (J. S. Fairbairn) . . . . xliv, 177
„ fibro-cyst of (W. A. Meredith) . . . xxix, 248, 513
„ fibro-sarcoma of the right (M. Handfield-Jones) . . xxxi, 126
„ — — (W. A. Meredith) . . . . xxxi, 225
„ fibroma of, mistaken for the head of an extra-uterine fœtus in a case of obstructed labour (W. S. A. Griffith) . . xxxiii, 140
„ — (H. T. Rutherford) . . . . xxxiv, 88
„ fibroma of both (C. J. Cullingworth) . . . xxi, 276
„ — the ligament of (A. Doran) . . . xxxi, 200
„ — (J. Crawford) . . . . xxxvi, 190
„ — (?) of (P. Horrocks) . . . . xxxvi, 192
„ — (M. Handfield-Jones) . . . xxxvi, 343
„ — and ovarian ligament removed by operation (A. Doran) xxxviii, 187
„ — ligament of, removed by operation (A. Doran) . xxxviii, 8
„ — undergoing calcareous degeneration (C. Hubert Roberts) . xxxix, 8
„ — impaction; ascites; removal (A. Doran) . . xxxix, 37
„ — (C. J. Cullingworth) . . . . xxxix, 279
„ — pure (A. Doran) . . . . xliv, 172
„ — one third of an inch in diameter (A. Doran) . . xliv, 173
„ — (F. N. Boyd) . . . . xliv, 176
„ — (A. E. Giles) . . . . xliv, 360
„ — with fibro-myoma of uterus with extensive carcinoma of body of uterus (W. W. H. Tate) . . . xlvi, 139
„ — (F. E. Taylor) . . . . xlvi, 280
„ — weighing 17 lb.; under observation for ten years (A. Doran) xlvii, 421
„ — (A. Routh) . . . . . xlviii, 133
„ — (M. Handfield-Jones) . . . xlviii, 332
„ fibro-myoma of the right, removed by abdominal section (C. H. Carter) . . . . . xxix, 190
„ — and myoma of the uterus, and allied tumours of the (A. Doran) . . . . . xxx, 410
„ — (A. J. Sturmer) . . . . xlv, 335, 370
„ — and cystic disease co-existing in the same (W. W. H. Tate) xlvi, 273
„ hydatids of, or connected with, both (C. J. Cullingworth and H. H. Clutton) . . . . . xlvi, 254
„ hydrocele of, containing papillomata (J. Bland-Sutton) . xxxiv, 215
„ pure myoma of, with a microscopic section (A. Doran) . xliv, 168
„ myxo-carcinoma of (W. S. A. Griffith) . . . xxviii, 180

OVARIES (*continued*)—
„ myxoma of both, associated with leukæmia (A. L. Galabin) . xx, 123
„ fungating papillomata of both (J. Knowsley Thornton) . xxviii, 38
„ removal of both, during pregnancy (J. Knowsley Thornton) xxvii, 46; xxviii, 41
„ removed from a case of osteomalacia (A. Rasch) . . xxxiv, 462
„ osteomalacia cured by excision of (A. Rasch) . . xxxv, 39
„ on the influence of the removal of, on metabolism in connection with osteomalacia (J. E. Curatulo) . . xxxviii, 17
„ acute torsion of an ovarian pedicle, from a case where there was chronic torsion of the pedicle of a tumour of the opposite (A. Doran) . . . . . xliii, 12
„ prolapsed adherent (W. S. A. Griffith) . . . xxvi, 270
„ non-malignant tumours of, sections of (W. S. A. Griffith) xxx, 302, 409
„ suppurating tumour of left (J. W. J. Oswald) . . xvii, 168
„ treatment of ovarian prolapse by shortening the ovarian ligament (V. Bonney) . . . . . xlviii, 339
„ sarcoma of (G. Elder) . . . . . xxv, 130
„ — anterior serous perimetritis simulating (A. Doran) xxxi, 217; xxxiii, 185
„ — both (J. A. Shaw-Mackenzie) . . . . xxxiv, 2
„ — large (?) of (P. Horrocks) . . . . xxxvi, 192
„ — (A. Doran) . . . . . xl, 296
„ — (W. R. Dakin) . . . . . xxxvi, 313
„ — showing necrosis of central portion lying in an abscess cavity containing offensive pus (W. W. H. Tate) . . xli, 373
„ — primary melanotic (H. R. Andrews) . . . xliii, 228
„ — (P. Horrocks) . . . . . xliv, 94
„ — unusual case of (J. Inglis Parsons) . . . xlv, 48
„ — associated with tubal mole of the same side (A. L. Galabin) . . . . . xlviii, 19
„ tumours of, axial rotation of, leading to their strangulation and gangrene (Lawson Tait) . . . . xxii, 86
„ — the right, with the Fallopian tube adherent to the opposite ovary (J. Knowsley Thornton) . . . . xxiii, 258
„ — complicated by a hæmatosalpinx (John Phillips) . . xxviii, 89
„ — with twisted pedicle (R. Barnes) . . . xxvi, 59
„ — and fibroid of uterus (A. Meadows) . . . xxv, 161
„ — cystic of both (J. Knowsley Thornton) . . . xxvi, 269
„ — solid (Leith Napier) . . . . xxxviii, 29, 32
„ — removed from a woman, aged 36 (A. W. Addinsell) . xlii, 139
„ acute suppuration and sloughing of, after parturition (J. H. Targett) . . . . . xxxvii, 216
„ of a healthy woman murdered by a stab which divided the femoral artery (A. L. Galabin) . . . . . xxi, 23
„ from a case of congenital inguino-ovarian hernia (T. Chambers) . . . . . xxi, 92, 256, 269
„ and jejunum (W. Duncan) . . . . . xxx, 82
„ and Fallopian tubes, removed by oöphorectomy (J. Knowsley Thornton) . . . . . xxiv, 137
„ — endometrium, and pelvic peritoneum, the relation to each other of inflammation of (A. Doran) . . . xxvii, 164
„ — diseased (C. H. Carter) . . . . xxxii, 136
„ and Fallopian tubes, from a case of persistent chronic ovaritis (J. D. Malcolm) . . . . . xxviii, 278
„ — — tubal gestation (W. Duncan) . . . xxxi, 165

OVARIES (*continued*)—
„ and Fallopian tubes and uterus from a case of Cæsarean section (C. J. Cullingworth) . . . . xxxi, 308
„ — distended with blood (W. Duncan) . . . xxxii, 306
„ — with papilloma (W. Duncan) . . . . xxxii, 346
„ — dilated (T. C. Hayes) . . . . xxxvi, 185
„ — greatly enlarged, with tumour of (P. Horrocks) . . xxxvi, 185
„ — microscopical sections of tuberculosis of (C. H. Roberts) . xlv, 92
„ — tubercular disease of (A. W. W. Lea) . . . xlv, 133
„ — right, cystic fibroid with carcinoma of left (R. Boxall) . xliii, 71
„ — — normal, in primary cancer of (H. Briggs) . . xlvi, 60
„ — left, solid tumour of, with an attached cyst communicating (W. F. V. Bonney) . . . . . xliv, 92
„ extirpation of both, with uterus (T. Chambers) . . xxiii, 12
„ and uterus, extirpation of, with large fibrous tumours (I. B. Brown) . . . . . vi, 249
„ — of a child who died of tubercular meningitis (F. Beach) . xv, 57
„ — of a woman who had died from hæmorrhage into the pelvis (Heywood Smith) . . . . . xvii, 56

OVARIOTOMY (P. S. M. Moodelly) . . . . x, 115
„ (E. M. Hodder) . . . . . xii, 308
„ five cases of (I. B. Brown) . . . . iii, 352
„ the mode of its performance and the results obtained at the London Surgical Home (I. B. Brown) . . . iv, 59
„ with cases and remarks on the different steps of the operation and the causes of its mortality (W. T. Smith) . . iii, 41
„ and reply to a statement respecting it made by Mr. Baker Brown . . . . . iv, 89
„ four additional cases of (W. T. Smith) . . . iv, 141
„ statistical and practical; also a successful case of entire removal of the uterus and its appendages (C. Clay) . v, 58
„ with remarks (T. Bryant) . . . . vi, 35
„ eight additional cases of (W. T. Smith) . . . vi, 66
„ belt for use after (Heywood Smith) . . . xxii, 45
„ specimen illustrating an operation for double (J. Scott) . xiii, 168
„ — *report* on ditto . . . . . xiii, 264
„ double (J. Matthews Duncan) . . . . xxiii, 6
„ — during pregnancy (J. Knowsley Thornton) xxvii, 46; xxviii, 41
„ — — two cases of (W. A. Meredith) . . . xxxiv, 239
„ — carcinomatous uterus removed eighteen and a half years subsequent to (A. C. Butler-Smythe) . . . xliii, 214
„ during pregnancy, with remarks on the treatment of ovarian tumours complicating pregnancy (E. Goddard) . . xiii, 275
„ performed during pregnancy, additional cases of (T. Spencer Wells) . . . . . xix, 185
„ double intestinal obstruction following (J. H. Targett) . xl, 175
„ embolism of the pulmonary artery after (E. Parson) . vii, 8
„ abdominal, during labour (H. R. Spencer) . . . xlviii, 37
„ during labour, in a case of incarcerated ovarian dermoid obstructing (H. R. Spencer) . . . . xl, 14
„ on ligature of the pedicle in (Alban Doran) . . xxxv, 131
„ new method of securing the pedicle in (I. B. Brown) . vii, 28
„ in which the pedicle was tied and returned, and the ligature removed in forty-eight hours (J. H. Aveling) . . vii, 229
„ loop of small intestine found adherent to the pedicle six months after (H. J. Paterson) . . . . xlvii, 316

OVARIOTOMY (*continued*)—
„ on the management of true and false capsules in (Alban Doran). . . . . xxxix, 265
„ for removal of ovarian tumour (T. Spencer Wells) . iii, 214, 285
„ four additional cases of (W. T. Smith) . . . iii, 215
„ large fibrous tumour of the ovary removed by (L. J. Martin) . xii, 302
„ for ovarian dropsy (I. B. Brown) . . . . v, 279
„ in ovarian dropsy; recovery (H. W. Sharpin) . . vii, 105
„ sequel to a case of (J. Murphy) . . . . xxvii, 108
„ three successful cases of, where axial rotation of ovarian tumours led to their strangulation and gangrene (Lawson Tait) . . . . . xxii, 86
„ trocar and cannula (G. C. P. Murray) . . . viii, 313
„ use of the actual cautery in (I. B. Brown) . . . viii, 109
„ vaginal, for removal of small ovarian tumour, from a patient who was about two months pregnant (J. W. Taylor) . xliv, 297
„ and posterior vaginal section during labour; ovarian tumour obstructing delivery; operation and delivery at one sitting; recovery (J. W. Taylor) . . . . xliv, 275
„ in women over eighty; a case, aged 83, complicated by epithelioma of the vulva (L. Remfry) . . xxxvii, 155

OVARITIS, persistent, chronic, ovaries and tubes from (J. D. Malcolm) . . . . . xxviii, 278
„ dysmenorrhœa, metrorrhagia and sterility, depending upon a peculiar formation of the cervix uteri (R. Barnes) . . vii, 120
„ sub-acute, diagnosis of (E. J. Tilt) . . . xv, 202

OVIDUCT of the frog, microscopical sections of (W. S. A. Griffith) xxx, 196

OVOTESTIS occurring in man, true unilateral hermaphroditism with (G. F. Blacker and T. W. P. Lawrence) . xxxviii, 265

OVULATION and menstruation of monkeys and the human female (W. Heape) . . . . . xl, 161

OVUM, aborted, showing cysts in the decidua vera (John Phillips) xxxi, 52, 161
„ — (Robert Wise) . . . . . xxxix, 259
„ apoplectic (G. E. Herman) . . . . xxii, 45
„ — (A. Routh) . . . . . xxxii, 194
„ — in a case of unruptured tubal gestation (C. J. Cullingworth) . . . . . xxxiv, 155, 182
„ blighted, protracted retention of (R. U. West) . . iv, 17
„ — report on specimen shown by Heywood Smith by Drs. Meadows and Phillips . . . . . xii, 329
„ — (John Phillips) . . . . . xxviii, 209
„ — with fleshy decidual hypertrophy (John Phillips) . xxxiii, 35
„ — with endometritis polyposa (A. H. N. Lewers) . . xxxiii, 197
„ early, with funis tightly encircling the left thigh of fœtus (T. Fitzpatrick) . . . . . x, 141
„ of about five days' growth, together with a decidual uterine cast, expelled after eight weeks' amenorrhœa (W. E. Fothergill) . . . . . xliii, 162
„ description of a five weeks', removed in a subsequent pregnancy in a case of puerperal eclampsia (W. S. A. Griffith and T. W. Eden) . . . . . xli, 151
„ on an early tubal (J. Bland-Sutton) . . . xxxvi, 195

OVUM (*continued*)—
„ thrown off at the second month, unusual and interesting appearance of (W. R. Rogers) . . . . xi, 80
„ of seven months expelled entire (W. M. Whitmarsh) . vi, 105
„ entire, expelled at the seventh month, the child rescued alive (J. Brunton) . . . . . xiii, 88
„ expelled about the eighth month, showing the villi of the chorion (A. W. Edis) . . . . . xvii, 48
„ containing fœtus three eighths of an inch long (H. Smith) . xii, 163
„ placenta of double (W. Outhwaite) . . . xxiv, 3
„ and Graafian follicle in pre-menstrual life, fate of (T. G. Stevens) . . . . . xlv, 465
„ *in ovo* (R. Barnes) . . . . iv, 87
„ twin, of ten weeks' gestation, membranes of (J. H. Davis) . x, 57
„ in twins, entire full-time (R. Wise) . . . xlix, 147
„ hydatidiform degeneration of (W. G. Hewitt) . . ii, 112
„ — — (C. H. F. Routh) . . . . . ii, 242
„ — — (W. A. Russell) . . . . . vii, 228
„ — — (F. Webb) . . . . . ix, 85
„ forceps (F. C. Cory) . . . . . viii, 5
„ — improvement in (H. Smith) . . . . xxii, 46
„ — modifications of (Heywood Smith) . . . xx, 170
Owen (W. B.), mechanical obstruction in growth of a fœtus . viii, 4

PAIN, intermenstrual, microscopical slides from a case of (A. W. Addinsell) . . . . . xli, 3

PAIN OF PARTURITION, and anæsthetics in obstetric practice (A. E. Sansom) . . . . . x, 121

PACKING with iodoform gauze in four cases of rupture of the uterus (H. R. Spencer) . . . . . xlii, 14

Page (H.) (introduced by H. Spencer), a mylacephalous acardiac twin . . . . . xxxiii, 302

Palfrey (James), monster with two heads and three arms . xix, 40
„ — *report* on ditto by committee (W. S. Playfair and T. C. Hayes) . . . . . xix, 97
„ — dissection of ditto (R. Brookes) . . . xix, 98
„ — note by J. G. Westmacott . . . . xix, 100

Palmer (Silas), obstructed labour from the presence of the hymen . . . . . iv, 211

PALPATION OF THE ABDOMEN, diagnosis of placenta prævia by (H. R. Spencer) . . . . . xxxi, 203

PANCREAS, chorio-epithelioma with secondary growths in (C. Lockyer) . . . . . xlv, 245

PAN-HYSTERECTOMY, uterus removed by (A. H. N. Lewers) . xxxix, 131
„ carcinoma of body and multiple fibromata of uterus removed by abdominal (J. H. Dauber) . . . . xxxix, 321
„ for removal of myxo-sarcoma of uterus (Amand Routh) . xli, 139
„ three uteri removed by (A. H. N. Lewers) . . . xli, 275
„ abdominal, for cancer of the body of uterus (A. H. N. Lewers) xliv, 10
„ — for primary carcinoma of the body of the uterus, removal by (A. H. N. Lewers) . . . . . xliv, 290

PAN-HYSTERECTOMY (*continued*)—
„ uterine fibroid removed by (W. C. Swayne) . . xlv, 140
„ abdominal, for removal of fibro-myoma of the cervix uteri (W. A Meredith) . . . . . xlvi, 12
„ during labour in the seventh month of a pregnancy in a uterus with fibroids (J. Bland-Sutton) . . . xlvi, 238
„ for removal of pregnant uterus with cancerous cervix (F. N. Boyd) . . . . . xlvi, 345

PAPILLARY INFLAMMATION, chronic, of the vulva (W. O. Priestley) . . . . . xxvi, 156

PAPILLOMA of the Fallopian tube and the relation of hydro-peritoneum to tubal disease (Alban Doran) . . xxviii, 229, 243
„ fungating, of both ovaries (J. Knowsley Thornton) . . xxviii, 38
„ inoperable, of the left ovary, pelvic organs from a case of (A. Routh) . . . . . xlix, 216
„ of ovary and tube (W. Duncan) . . . . xxxii, 346
„ ovarian hydrocele containing (J. Bland-Sutton) . . xxxiv, 215
„ malignant, of uterus (Amand Routh) . . . xxxix, 5
„ cyst of both ovaries causing profuse ascitic effusion containing (Alban Doran) . . . . xxxiv, 149
„ ovarian cyst containing (A. H. N. Lewers) . . . xxxiv, 462
„ multilobular, of the urethra (C. Lockyer) . . . xlvii, 122
„ ovarian cystoma removed after double ovariotomy fifteen years previously (J. D. Malcolm) . . . xxxv, 36

PAQUELIN'S THERMO-CAUTERY (G. Prevôt) . . . xviii, 180
„ three new points for (Heywood Smith) . . . xix, 41
„ regulator for (J. H. Aveling) . . . . xx, 293

PARALYSIS, see *Hemiplegia*.

PARAMETRITIS, anterior, and anterior perimetritis (W. S. A. Griffith) . . . . . xxix, 147
„ hæmorrhagic (J. Matthews Duncan) . . . xxix, 191
„ purulent (W. S. A. Griffith) . . . . xxx, 5

Paramore (Richard), for *W. D. Haslam*, midwifery forceps . xxix, 190

PARAPLEGIA occurring during pregnancy (P. Boulton) . ix, 12
„ parturition during, with cases (Amand Routh) . . xxxix, 191

PAROVARIAN CYST (Lawson Tait) . . . . xxv, 112
„ axial rotation of (Leith Napier) . . . . xxxiv, 124
„ removed *per vaginam* (Amand Routh) . . xxxvii, 8
„ with acute axial rotation (A. W. W. Lea) . . . xxxix, 8
„ with twisted pedicle, two cases of, in which the ovary only (and not the cyst) was congested and inflamed (H. R. Spencer) . . . . . xlii, 333

Parson (E.), embolism of the pulmonary artery after ovariotomy vii, 8
„ case where local anæsthesia by the ether spray was employed in the removal of epithelioma of the cervix uteri by the écraseur . . . . . ix, 47

Parsons (J. Inglis), twenty cases of fibroma and other morbid conditions of the uterus treated by Apostoli's method . xxxiv, 22
„ the disintegration of organic tissue by high tension discharges . . . . . xxxvii, 124
„ unusual case of sarcoma of the ovary . . . xlv, 48
„ a case of fibro-myoma of the vestibule . . . xlviii, 184

PARTURITION, abnormal, influence of, difficult labour, premature birth and asphyxia neonatorum on the mental and physical condition of the child, especially in relation to deformities (W. J. Little) . . . . . iii, 293
„ amaurosis observed eight times in succession after (H. E. Eastlake) . . . . . v, 79
„ cardiac apnœa after (W. S. Playfair) . . . . x, 21
„ application of extreme cold as an anodyne in the pain attendant on (J. M. Granville) . . . . . vi, 105
„ cast of antique group representing the circumstantials of, in very early times (S. H. Bibby) . . . . . xvi, 243
„ at term, degenerated fibro-myoma weighing over 17 lb. enucleated from the broad ligament nine hours before (H. R. Spencer) . . . . . xlvi, 415
„ — carcinoma of the cervix complicating; Cæsarean section, followed by vaginal hysterectomy (J. M. Munro-Kerr) . xlvii, 194
„ — fibro-myoma removed by abdominal myomectomy in second month of pregnancy (A. Doran) . . . xlvii, 426
„ — spurious, in a case of abdominal pregnancy; fœtus and placenta removed six months later (E. J. Maclean) . xlviii, 129
„ with atresia vaginæ (Fancourt Barnes) . . . xxv, 99
„ complicated by an ascitic fœtus (J. A. Thompson) . . xvii, 4
„ axis pressure binder for use during (J. L. A. Aymard) . xxxii, 173
„ bandage after (A. Meadows) . . . . vi, 125
„ acute bedsore following (G. F. Blacker) . . . xl, 247
„ breech presentation, new form of blunt hook and sling in cases of (J. G. Swayne) . . . . . xvii, 313
„ — with extended legs (W. S. A. Griffith and Arnold W. W. Lea) . . . . . xxxix, 13
„ with Bright's disease, six more cases of pregnancy and (G. E. Herman) . . . . . xxxvi, 9
„ two cases of, complicated with cancer of the cervix uteri (G. E. Herman) . . . . . xxiv, 308
„ complicated by cancer of the cervix in advanced pregnancy, the patients remaining well eleven, eight and a half, and eight years after high amputation of the cervix (H. R. Spencer) . . . . . xlvi, 355
„ caries of the pelvic bones following (W. S. Playfair) . xviii, 142
„ ancient Greek charm representing woman in (A. Doran for *Ernest Hart*) . . . . . xxxiii, 26
„ cicatrices from a burn requiring division during (E. F. Willoughby) . . . . . xii, 31
„ "couchaid" to assist and economise force during (A. W. Edis) xvii, 48
„ dermoid cyst of ovary, removed by abdominal section five years after causing obstruction to (W. W. H. Tate) . xlvi, 344
„ sudden death from occlusion of the pulmonary arteries seventeen days after (D. Mackinder) . . . . i, 213
„ sudden death during (R. Barnes) . . . . viii, 40
„ — after (W. S. Playfair) . . . . xiii, 192
„ death during, in which in a previous pregnancy there was fracture of the pelvis and injury to the uterus (T. Fairbank) . ix, 1
„ death in ewes during and after, report on certain causes of (J. Hutchinson) . . . . . xviii, 88
„ diabetes insipidus in (J. Matthews Duncan) . . xxix, 308
„ difficult, from locked heads (H. Raynes) . . . iv, 19
„ — on the management of, with a minor degree of contraction of brim (A. B. Steele) . . . . . xvi, 32

PARTURITION (*continued*)—
„ difficult case of, in a primipara who, barren for thirteen years, became pregnant after division of a deformed cervix uteri (G. Roper) . . . . . xix, 169
„ antero-posterior positions of the head as a cause of difficult (R. G. McKerron) . . . . . xli, 142
„ digital dilatation of the os in (J. Braithwaite) . . xxi, 38
„ the relation between backward displacements of the uterus and prolonged hæmorrhage after abortion and (G. E. Herman) . . . . . xxxiv, 14
„ distension of the uterus in a fœtus impeding (H. Gervis) . v, 284
„ eclampsia; septic peritonitis; splenic abscess; death on the sixteenth day after (J. C. H. Leicester) . . . xlvii, 271
„ case of, with extreme elongation of the cervix uteri (R. Barnes) . . . . . xviii, 293
„ fatal embolism of right heart and pulmonary artery nineteen days after (G. Roper) . . . . . xxi, 74
„ pulmonary embolism occurring twenty-four days after (H. Williamson) . . . . . xlv, 189
„ ergot of rye during, effect on the life of the child (R. U. West) iii, 222
„ extrusion of right arm of child through the anal orifice during (H. E. Eastlake) . . . . . viii, 320
„ in face presentation, effected by the cephalotribe (J. B. Hicks) x, 144
„ — by the forceps in the mento-lateral position (J. B. Hicks) . xv, 39
„ in a case of deformed fœtus with adherent placenta and the intestines uncovered and presenting (D. Johnson) . . xiii, 53
„ intra-peritoneal rupture of the bladder occurring during (C. R. Porter) . . . . . xlix, 170
„ pelvic hæmatoma following (R. Boxall) . . . xxxi, 303
„ concealed accidental hæmorrhage during (J. B. Hicks) . ii, 53
„ early and entirely detached placenta in, producing internal and concealed hæmorrhage (J. T. Mitchell) . . viii, 282
„ hæmorrhage after (R. Barnes) . . . . xi, 219
„ vaginal hæmorrhage during, a diagnostic sign of (P. Budin) . xix, 232
„ and post-partum hæmorrhage, case of central choroido-retinitis occurring after (H. Macnaughton-Jones) . . . xxxii, 134
„ diffuse meningeal hæmorrhage in infant after normal (A. W. Sikes) . . . . . xlv, 44
„ hemiplegia occurring nine days after (E. F. Scougal) . xxx, 214
„ ingravescent hemiplegia during (P. Horrocks) . . xxxiii, 201
„ impeded, treatment of, aided by special position and obstetric binder (R. Hardey) . . . . . ii, 79
„ — in a case of hydrocephalic fœtus with breech presentation (A. W. Edis) . . . . . xvii, 302
„ — by vertical septum in lower part of vagina (J. Braxton Hicks) . . . . . xxiii, 24
„ case of congenital hydrocephalus complicating (G. M. Bluett) . xxix, 396
„ — — (J. G. Swayne) . . . . . xxix, 405
„ natural, hysteria simulating in the most perfect degree (R. Hodges) . . . . . i, 339
„ induced after full period had elapsed in persistent sickness (A. W. Williams) . . . . . xii, 164
„ on the induced current during (W. Kilner) . . xxvi, 93
„ infection of ovarian cyst complicating pregnancy five days after (H. Macnaughton-Jones) . . . . . xlii, 140
„ injection of uterus after, apparatus for facilitating (R. Barnes) xix, 118
„ instrument to aid the abdominal muscles in (P. Smith) . xi, 169

PARTURITION (*continued*)—
„ two cases of inversion of the uterus after (W. T. Smith) . x, 30
„ inversion of the uterus occurring immediately after (F. H. Gervis) . . . . . xvii, 278
„ laceration of the integument of the fœtus occurring during (R. K. Peirce) . . . . . vii, 74
„ — of the vagina during (J. Matthews Duncan) . . xxxi, 236
„ lingering, use of forceps and its alternatives in (R. Barnes) . xxi, 121
„ management of the third stage of (H. E. Eastlake) . . vi, 226
„ — with a view to promote successful suckling (W. Martyn) . xii, 339
„ mechanical support during (W. Woodward) . . xi, 192
„ mechanism and management of, in cases of double monstrosity (W. S. Playfair) . . . . . viii, 300
„ the mechanism of, more especially with reference to Naegele's obliquity and the influence of the lumbo-sacral curve (R. Barnes) . . . . . xxv, 258
„ — of the third stage of (F. H. Champneys) xxix, 117, 151, 264, 317, 337, 346
„ at full term, membrane expelled from uterus a few days before (A. Harris) . . . . . vii, 47
„ complicated by a case of meningocele (S. W. Poole) . . xix, 265
„ missed (A. W. Williams) . . . . vi, 208
„ of double monster (W. Wills) . . . . vii, 6
„ myxoma in a fœtus impeding (T. C. Hayes) . . xviii, 83
„ nightdress for ladies during and after (— Stewart) . . xvi, 87
„ normal, on the occurrence of lateral obliquity of the fœtal head in (A. L. Galabin) . . . . xvii, 283
„ observations on the temperature, pulse, and respiration during (R. J. Probyn Williams and L. Cutler) . . xxxvii, 19, 152
„ three cases of obstructed (J. B. Hicks) . . . v, 285
„ report on one case (J. B. Hicks) . . . . v, 290
„ obstructed, from the presence of the hymen (S. Palmer) . iv, 211
„ — by fibroid tumour, situated in the anterior wall of the uterus (R. Barnes) . . . . . v, 171
„ — (S. Berry) . . . . . vii, 261
„ — condition of uterus in, and an inquiry as to what is intended by the terms "cessation of labour pains," "powerless labour," and "exhaustion" (J. B. Hicks) . . . . ix, 207
„ — in which spontaneous version followed an unsuccessful attempt to deliver by the crotchet after craniotomy (S. D. Hine) . . . . . xxvii, 293
„ — in which a large fibroma of the ovary occupying the pelvis was mistaken for the head of an extra-uterine fœtus (W. S. A. Griffith) . . . . . xxxiii, 140
„ obstruction of, by sessile fibro-myoma of the cervix uteri (W. Duncan) . . . . . xxxv, 296
„ — by ovarian tumours in the pelvis (R. G. McKerron) . xxxix, 334
„ fœtus with absence of urethra and ascites obstructing (T. G. Stevens) . . . . . xxxvii, 5
„ adjourned discussion on R. G. McKerron's paper on the obstruction of, by ovarian tumours in the pelvis . . xl, 8
„ incarcerated ovarian dermoid obstructing ovariotomy during (H. R. Spencer) . . . . . xl, 14
„ — — obstructing; manual elevation; removal seven months later (H. R. Spencer) . . . . . xl, 22
„ — — Cæsarean section and removal of tumour at the end of the first stage of (R. Boxall) . . . . xl, 25

PARTURITION (*continued*)—
„ suppurating ovarian cyst obstructing, removed by abdominal section eighteen months later (W. W. H. Tate) . . xlii, 164
„ dermoid cyst of ovary obstructing; displacement of the tumour from the true pelvis and extraction of the child with forceps; removal of tumour five weeks later; recovery (J. M. M. Kerr) . . . . . xliii, 145
„ uterus removed at eight and a half months of gestation by abdominal hysterectomy for fibroid obstructing (A. Routh) . xliv, 41
„ occlusion of the os uteri, with retention of menses after difficult (J. H. Davis) . . . . . iv, 91
„ occluded vagina after, followed by subsequent retention of menses (S. Craddock) . . . . . xiii, 101
„ ovarian cyst co-existing with pregnancy, which ruptured spontaneously ten days after (C. Clay) . . . i, 226
„ complicated with an ovarian cyst (A. H. Brewer) . . xx, 184
„ — with ovarian disease (R. T. Warn) . . . xi, 198
„ — by ovarian tumour (W. S. Playfair) . . . ix, 69
„ ovarian tumour obstructing; posterior vaginal section and ovariotomy during labour; operation and delivery at one sitting; recovery (J. W. Taylor) . . . xliv, 275
„ a second case of abdominal ovariotomy during (H. R. Spencer) xlviii, 37
„ pain of, and anæsthetics in obstetric practice (A. E. Sansom) . x, 121
„ in the seventh month, pan-hysterectomy during (J. Bland-Sutton) . . . . . xlvi, 238
„ during paraplegia, with cases (Amand Routh) . . xxxix, 191
„ complicated by acute peritonitis (without discovered cause) (John Phillips) . . . . . xli, 389
„ the value of pilocarpine in (John Phillips) . . . xxx, 354
„ polypus uteri complicating (H. L. Freeman) . . v, 42
„ natural, *post-mortem* examination of a woman at the first stage of (F. J. Gant) . . . . . vi, 214
„ *post-mortem*, with references to forty-four cases (J. H. Aveling) xiv, 240
„ premature followed by suppuration in fibro-myoma uteri treated by abdominal hysterectomy (W. W. H. Tate) . . xlix, 54
„ unsuspected pregnancy and (T. H. Tanner) . . iv, 113
„ premature, induction of, in a case of distorted pelvis (J. H. Trouncer) . . . . . i, 236
„ indications and operations for the induction of premature, and for the acceleration of (R. Barnes) . . . iii, 107
„ induction of premature, in an extra-uterine fœtation, followed by intra-uterine pregnancy (E. E. Day) . . . vi, 3
„ premature, induced for pelvic contraction from spondylolisthesis (R. Barnes) . . . . . vi, 78
„ — or natural, enlargements of the uterus following (T. S. Beck) . . . . . viii, 54
„ — induced by injection to the fundus of the uterus (J. Lazarewitch) . . . . . ix, 161
„ — in a case of symmetrical erysipelas, with eclampsia post-partum (J. B. Hurry) . . . . . xxxii, 309
„ — induction of, on the methods adopted by Keiller and others for the (J. Watt Black) . . . . xxxv, 95
„ preternatural, exigencies connected with . . . ii, 257
„ in primiparous women late in the reproductive period of life (G. Roper) . . . . . vii, 51
„ case of, in a primipara suffering from mitral stenosis (G. Coates) . . . . . xxviii, 108

PARTURITION (*continued*)—
„ prolapse of the funis during (G. Roper) . . . xvii, 318
„ protracted, of more than six days' duration (J. T. Mitchell) . xii, 368
„ — case of, in which the use of the forceps was typically indicated (G. Roper) . . . . . xx, 75
„ long delay of, after discharge of the liquor amnii (J. Matthews Duncan) . . . . . xiv, 216
„ necrosis of pubic bones following (W. S. Playfair) . . xv, 219
„ a new and speedy method of dilating a rigid os in (J. Farrar) xxxvi, 321
„ with the parallel forceps in a case of puerperal convulsions (J. Lazarewitch) . . . . . xv, 59
„ retroflexion of the gravid uterus during, at term (H. Oldham) i, 317
„ rupture of vagina during (J. H. Bell) . . . iv, 197
„ — with recovery (Heywood Smith) . . . xvii, 359
„ — spontaneous, with recovery (A. Wiltshire) . . xvii, 362
„ — two cases of (A. L. Galabin) . . . . xx, 295
„ ruptured vagina during (T. J. Walker) . . . viii, 109
„ incarcerated ovarian dermoid ruptured during (H. R. Spencer) xl, 329
„ by forceps and version, incarcerated ovarian dermoid ruptured during (H. R. Spencer) . . . . xl, 331
„ fatal rupture of an aneurysm of the splenic artery immediately after (J. D. S. Nodes and Frank Hinds) . . . xlii, 305
„ large ovarian tumour ruptured on the third day after (H. R. Spencer) . . . . . xliii, 224
„ rupture of an ovarian abscess twelve hours after (C. Berkeley) xliv, 73
„ — of uterus during (E. J. Asbury) . . . x, 40
„ — — occurring during, and after external violence (J. Phillips) xxxii, 375
„ uterus ruptured during unobstructed (with a microscopic section) (W. R. Dakin) . . . . . xl, 29
„ utero-vaginal rupture during (A. Wiltshire) . . xviii, 220
„ scale for calculating onset of (W. S. Playfair) . . xxviii, 68
„ effect of the scarlatinal poison on the course of (R. Boxall) . xxx, 68
„ separation of the greater portionof cervix uteri during (R. Gray) xvi, 128
„ the shortness of the cord as a cause of obstruction to the natural progress of (J. Matthews Duncan) . . xxiii, 243
„ sloughing of the central part of a uterine fibro-myoma shortly after (J. D. Malcolm) . . . . . xlvi, 15
„ spurious, macerated fœtus removed from the abdominal cavity two months after (A. Doran) . . . . xlii, 8
„ suppression of urine after (R. G. McKerron) . . xliv, 97
„ acute suppuration and sloughing of ovaries after (J. H. Targett) . . . . . xxxvii, 216
„ synopsis of 1500 consecutive cases of (W. T. Greene) . xix, 204
„ tedious, sloughing of fœtal scalp, as the result of (W. O. Priestley) . . . . . i, 323
„ — displacement of the bladder as a cause of (W. H. Broadbent) v, 44
„ — delivery by forceps; death on third day from thrombosis (W. Martyn) . . . . . x, 263
„ temperature immediately after, in relation to the duration and other characteristics of (A. E. Giles) . . . xxxvi, 238
„ case of triplets and complete placenta prævia in which the children were delivered alive through a perforation in the first placenta (H. R. Spencer) . . . . xxxv, 107
„ complicated with a fibrous tumour of the uterus; delivery by long forceps, and subsequent removal of tumour (W. O. Priestley) . . . . . i, 217
„ fibroid tumour complicating (W. S. Playfair) . xix, 101; xxiii, 25

PARTURITION (*continued*)—
„ fibroid tumours complicating pregnancy and (A. Donald) . xliii, 180
„ uterine fibroids removed by enucleation fifteen days after (R. Boxall) . . . . . xxxvi, 64
„ fibroid tumour of uterus complicating, treated by enucleation (W. Hankes Day) . . . . . xxvii, 158
„ Porro-Cæsarean hysterectomy with retro-peritoneal treatment of the stump in a case of fibroids obstructing, with remarks upon the relative advantages of the modern Porro operation over the Sänger-Cæsarean in most other cases requiring abdominal section (A. Routh) . . . . . xlii, 244
„ complicated near term by fibroids, for which Cæsarean section and total abdominal hysterectomy had been performed in a patient who had recovered without operation from ruptured tubal pregnancy (H. R. Spencer) . . . xlviii, 240
„ fibroid showing cystic degeneration removed three weeks after (H. R. Andrews) . . . . . xlviii, 247
„ fibro-myoma spontaneously enucleated during (W. R. Dakin) xli, 105
„ tumours of the pelvis obstructing (E. Copeman) . . xii, 313
„ complicated by pelvic tumour and convulsions (H. M. Madge) xvii, 20
„ tumour, calcareous intra-mural, impeding (Wynn Williams) . xvii, 172
„ tumour protruded from the rectum during (R. Barnes) . xxi, 28
„ — expelled from the uterus during natural (A. W. W. Lea) . xli, 2
„ — — after (F. H. Daly) . . . . xxviii, 170
„ submucous fibroid presenting at the os uteri ten days after (G. E. Herman) . . . . . xxxiii, 30
„ turning in cases of contracted brim (P. L. Burchell) . xxv, 61
„ difficult position of the heads during twin (T. Pollock) . iii, 103
„ changes the tissues of the uterus undergo after (S. Beck) . xiii, 290
„ description of a series of casts showing the condition of the uterus at various periods after (Arthur Farre) . . xviii, 84
„ in a case of double uterus (J. Matthews Duncan) . . xxiii, 21
„ uterus torn out after (J. H. Walters) . . xxiv, 136; xxvi, 233
„ sections of uteri demonstrating the anatomical changes at the onset of, and after delivery (A. H. F. Barbour) . . xxviii, 73
„ connected with a non-evoluted and hypertrophied state of the cervix uteri (G. Roper) . . . . vii, 233
„ uterus and vagina with the child *in situ* in the second stage of (W. F. Victor Bonney) . . . . xliv, 292
„ through an imperforate vagina (Heywood Smith) . . xxiii, 117
„ see *Delivery, Missed Labour, Placenta, Presentations, Spurious Labour.*

PATERSON (HERBERT J.), a "grip-eyed" needle . . xlvii, 250
„ loop of small intestine found adherent to the pedicle six months after ovariotomy . . . . xlvii, 316
„ uterus bicornis . . . . . xlvii, 248
„ extra-uterine gestation; operation during the sixth month of pregnancy . . . . . xlvii, 326

PATHOLOGICAL CONDITIONS of the Fallopian tubes, the frequency of (A. H. N. Lewers) . . . . . xxix, 199

PATHOLOGY of chronic metritis (W. F. Shaw) . . xlix, 19
„ of puerperal eclampsia (J. B. Hicks) . . . viii, 323
„ and symptoms of hydatidiform degeneration of the chorion (H. Williamson) . . . . . xli, 303
„ and treatment of puerperal eclampsia, with special reference to the use of saline transfusion (with notes of two cases) (E. W. Hey Groves) . . . . . xliii, 117

PATHOLOGY COMMITTEE, REPORTS OF:
„ on Amand Routh's specimen of a fibro-myoma of the uterus with a sarcomatous nodule in the centre (J. S. Fairbairn, C. Lockyer, C. H. Roberts, C. Keep, and G. Blacker) . . xlix, 45
„ on J. Bland-Sutton's specimen of a villous tumour of uterus from a patient, aged 84 . . . . xlix, 93
„ on G. F. Darwall Smith's specimen of perithelioma of the uterus xlix, 136
„ on H. Russell Andrew's specimen of supposed sarcoma of cervix . . . . . xlix, 169
„ on May Thorne's specimen of uterus showing malignant villous tumour and a fibroid undergoing sarcomatous change xlix, 207
„ on Alban Doran's specimen of a malignant vaginal polypus secondary to an adrenal tumour . . . . xlix, 208
„ H. Briggs's specimen of ovarian pregnancy . . xlix, 255
„ on J. H. Dauber's specimen of fibro-myomatous uterus containing a calcified fibroid lying free in the uterine cavity . xlix, 256
„ on H. T. Hicks' specimen of primary vaginal embolic chorion-epithelioma . . . . . xlix, 256
For previous Pathology Committee Reports, see *Committees* . 38

PATIENT after symphysiotomy (W. S. A. Griffith) . . xxxvii, 13

PEASLEE'S METROTOME, modified form of (A. L. Galabin) . xx, 53

PEDICLE, twisting of, in an incipient dermoid ovarian cyst (Alban Doran) . . . . . xxiv, 133
„ of ovarian cyst (J. Knowsley Thornton) . . xxv, 164; xxviii, 46
„ in an ovarian tumour (R. Barnes) . . . xxvi, 59
„ of an ovarian tumour, changes in, when treated by ligature (G. G. Bantock) . . . . . xiv, 2
„ new method of securing in ovariotomy (I. B. Brown) . vii, 28
„ in a case of ovariotomy (J. H. Aveling) . . . vii, 229
„ on ligature of, in ovariotomy (Alban Doran) . . xxxv, 131
„ fibroid, of the broad ligament, weighing 4½ lb., with twisted (A. H. N. Lewers) . . . . xliv, 364
„ pedunculated fibro-myoma, of the broad ligament, with twisted (C. J. Cullingworth) . . . . xxxvii, 222
„ torsion of, in a broad ligament cyst and extensive hæmorrhage into broad ligament (F. J. McCann) . . . xlviii, 179
„ acute torsion of an ovarian; from a case where there was chronic torsion of the pedicle of a tumour of the opposite ovary (A. Doran) . . . . . xliii, 12
„ twisted, of an ovarian dermoid six inches in length (J. Bland-Sutton) . . . . . xlvi, 147
„ axial rotation of, of a right-sided parovarian cyst (Leith Napier) . . . . . xxxiv, 124
„ twisting of, in two cases of parovarian cyst, in which the ovary only (and not the cyst) was congested and inflamed (H. R. Spencer) . . . . . xlii, 333
„ twisted, in a parovarian cyst (C. Berkeley) . . xlvi, 242
„ of a hydrosalpinx, torsion of (H. Williamson) . . xlvii, 5
„ pyosalpinx with twisted (A. H. N. Lewers) . . xliv, 362
„ twisted, in dermoid cyst of right ovary (W. Duncan) . xxxvi, 267
„ — in dermoid tumours of both ovaries (R. Boxall) . . xli, 5
„ — in a ruptured ovarian cyst (V. Bonney) . . . xlvii, 190
„ hydrosalpinx of an accessory Fallopian tube due to twisting of (W. S. Handley) . . . . . xlv, 157
„ torsion of, in hydrosalpinx, and other morbid conditions of the Fallopian tube (R. H. Bell) . . . . xlvi, 152

PEDICLE (*continued*)—
„ loop of small intestine found adherent to, six months after ovariotomy (H. J. Paterson) . . . . xlvii, 316
„ minute, produced by torsion of mesovarium only in a dermoid cyst of ovary (A. L. Galabin) . . . . xlvii, 331
PEDLER (G. H.), deformed pelvis by mollities ossium . . xiii, 123
PEDLEY (T. F.), midwifery among the Burmese . . xxix, 5
PEIRCE (R. K.), laceration of the integument of the fœtus occurring during labour . . . . vii, 74
„ *report* on ditto by Drs. Harley and Meadows . . vii, 76
PELLETS of fat in a dermoid cyst (A. C. Butler-Smythe) xxxvii, 15
PELVIC CELLULITIS after a first pregnancy, followed by suppuration at back and front parts of vagina (G. D. Gibb) . ii, 324
PELVIC FLOOR, the anatomy of (G. E. Herman) . . xxxi, 263
„ the changes in, which accompany the slighter degrees of prolapse (G. E. Herman) . . . . . xxxi, 276
PELVIC ORGANS of a patient dying from vaginal injection of acid nitrate of mercury to produce abortion (John Phillips) xxxii, 308; xxxiii, 180
PELVIC PATHOLOGY, progress of, during the last twenty-five years (E. J. Tilt) . . . . . xv, 87
„ lymphangitis in (E. J. Tilt) . . . . xvi, 130
PELVIC PERITONITIS, the value of abdominal section in certain cases of (C. J. Cullingworth) . . . . xxxiv, 254
PELVIMETER, new (I. Lumley Earle) . . . iii, 145
„ (R. Greenhalgh) . . . . vi, 186
„ of Dr. Byford (G. C. P. Murray) . . . . x, 39
„ new portable, from Russia (Heywood Smith) . . xix, 41
PELVIMETRY (A. E. Martin) . . . . xiv, 71
PELVIS, caries of the bones of the, following delivery (W. S. Playfair) . . . . . xviii, 142
„ of a cat, with bladder, uterus, and rectum *in situ* (H. T. Rutherfoord) . . . . . xxxiv, 251
„ collection in the Royal University Maternity of Berlin (A. E. Martin) . . . . . xiv, 71
„ contracted brim of, in a minor degree, the management of difficult labour with (A. B. Steele) . . . xvi, 32
„ — — turning in cases of (P. L. Burchell) . . . xxv, 61
„ — in conjugate diameter, revolutions of the fœtal head in passing through the brim of (J. Matthews Duncan) . xx, 151
„ — obliquely, of a child with left sacro-iliac synostosis (F. H. Champneys) . . . . . xxiv, 191
„ — case of Cæsarean section for (F. H. Champneys) . . xxxi, 136
„ — Cæsarean section for (C. J. Cullingworth) . . xxxiv, 89
„ — — (J. Shaw) . . . . . xxxiv, 98
„ — — (Leith Napier) . . . . . xxxiv, 105
„ — uterus removed at full term by intra-peritoneal hysterectomy in a case of (W. Duncan) . . . . xliii, 9
„ — Cæsarean section in cases of (J. M. Munro Kerr) . . xlvi, 309
„ — sixty-four cases of (C. N. Longridge) . . . xlviii, 226
„ dermoid cysts of, the suppuration and discharge into mucous cavities of (G. E. Herman) . . . . xxvii, 254
„ — ovarian cyst impacted in, which was removed by abdominal section during the ninth month of pregnancy (T. H. Morse) . . . xxxviii, 221

PELVIS (*continued*)—
„ deformed, by mollities ossium (G. H. Pedler) . . xiii, 123
„ — — (W. S. A. Griffith) . . . . xxvi, 230
„ — case of Cæsarean section for (J. W. J. Oswald) . . xvii, 378
„ distorted, induction of premature labour in a case of (J. H. Trouncer) . . . . . i, 236
„ asymmetrical distortion of, the result of unequal length of legs (R. Barnes) . . . . . ii, 314
„ extreme distortion of; craniotomy; cephalotripsy; Cæsarean section . . . . . vii, 220
„ — comparative merits of the Cæsarean operation and craniotomy in (R. Greenhalgh) . . . . vii, 270
„ dissection of the muscles of the female (Alban Doran) . xxviii, 274
„ form of the male and female, what are the chief factors which determine the differences which exist in the (W. A. Lane) . xxix, 351
„ fracture of, with injury to the uterus in the sixth month of pregnancy (T. Fairbank) . . . . ix, 1
„ hydatids in the bony (J. H. Targett) . . . xxxvi, 344
„ kyphotic, with remarks on Breisky's description (F. H. Champneys) . . . . . xxiv, 242
„ — the obstetrics of (F. H. Champneys) . xxv, 166; xxviii, 253
„ of Naegele, remarks on (F. H. Champneys). . . . xxiv, 191
„ — oblique, on the production of the shape of (G. E. Herman) xxviii, 6
„ — notes of a specimen of (W. S. A. Griffith) . xxviii, 83, 84
„ — pseudo-osteo-malacic (W. S. A. Griffith) . . xxvii, 186
„ — obliquity of, and the influence of the lumbo-sacral curve in the mechanism of labour (R. Barnes) . . . xxv, 258
„ — (J. H. Targett) . . . . . xli, 231
„ oblique rachitic (W. S. A. Griffith) . . . xxv, 232
„ obstruction of labour by ovarian tumours in (R. G. McKerron) xxxix, 334
„ adjourned discussion on R. G. McKerron's paper on the obstruction of labour by ovarian tumours in . . xl, 8
„ the pressure of the femora and its influence on the shape of the (F. H. Champneys) . . . . xxv, 70
„ sexual differences of the fœtal (A. Thomson) . . xli, 279
„ tumours of, obstructing delivery (E. Copeman) . . xii, 313
„ see also *Spondylolisthesis.*

Pembrey (M. S.), five fœtal sacs from the peritoneal cavity of a rabbit . . . . . xl, 253
„ and G. Bellingham Smith, on sacs containing fœtuses and lying free in the peritoneal cavity of a rabbit . . xlvi, 283

PEMPHIGUS, acute contagious, in the new-born (G. J. Maguire) . xlv, 429

PENCIL, cedar, extracted from the bladder of a girl (J. J. Phillips) . . . . . xiv, 37

Penrose (F. G.), tubo-abdominal pregnancy . . . xxx, 124
„ — *report* on ditto by committee (Alban Doran, G. E. Herman, and F. H. Champneys) . . . . . xxx, 303

PENSION in lieu of honorarium to Miss Hannam . . xlix, 276

PERFORATION, best mode of delivering the fœtal head after (J. B. Hicks) . . . . . vi, 263

PERFORATOR, guarded, invented by Mr. Matthews (W. S. Playfair) . . . . . xii, 117
„ of the ordinary wedge-scissor's construction (W. F. Cleveland) ix, 56
„ protected, modifications of Oldham's and Simpson's (A. Wiltshire) . . . . . xvi, 88

PERICARDITIS, idiopathic, in a child aged 2 (A. Meadows) . iii, 144
„ — in a child aged 2½ (H. Madge) . . . iii, 176
PERICARDIUM, incomplete, escape of heart into left pleural cavity (R. Boxall) . . . . . xxviii, 209
PERIGAL (ARTHUR), anencephalous fœtus . . . xxxi, 165
PERIMETRIC ABSCESS (W. S. Griffith) . . . xxiv, 299
„ retro-uterine (W. S. A. Griffith) . . . . xxv, 18
PERIMETRITIS, anterior, and anterior parametritis (W. S. A. Griffith) . . . . . xxix, 147
„ — serous, simulating ovarian sarcoma (Alban Doran) xxxi, 217; xxxiii, 185
„ serous (W. S. A. Griffith) . . . . xxvii, 168
„ — (J. Williams) . . . . . xxvii, 169
„ — case of (A. Routh) . . . . xxviii, 131
„ see also *Peritoneum*, pelvic.
PERINEUM, dissection of the muscles of the female (Alban Doran) . . . . . xxviii, 274
„ rigid, treatment of, and the avoidance of its rupture (H. E. Trestrail) . . . . . xvii, 61
„ ruptured, and birth of the child between the os vaginæ and anus (I. Baker Brown) . . . . . ii, 197
„ rupture of, complete (C. R. Thompson) . . . xix, 265
„ — note on the operation for restoring the perineal body in (Aust Lawrence) . . . . . xxxii, 377
„ — the use of the purse-string suture in (P. Boulton) . xxxii, 380
„ prevention of (H. E. Trestrail) . . . . xvii, 61
„ on new methods of operation for repair of the (Lawson Tait) . xxi, 292
PERITHELIOMA of the uterus (G. F. Darwall-Smith) . . xlix, 97
PERITONEUM, adhesions of the gravid uterus as a cause of post-partum hæmorrhage (W. G. Hewitt) . . . xi, 108
„ fœtus in cavity of, question of abdominal gestation, with a summary of reported cases of primary abdominal and ovarian pregnancy (Alban Doran) . . . . xxxv, 222
„ myxomatous growth of (J. Williams) . . . xxiv, 93
„ pelvic, endometrium, Fallopian tube, and ovary, the relation to each other of inflammation of (Alban Doran) . . xxvii, 164
PERITONITIS in case of abscess of ovary (A. W. Edis) . . xiii, 99
„ acute general gonococcic (A. G. R. Foulerton) . . xlvii, 185
„ — double ovarian apoplexy from a case of (H. A. Des Vœux) xxxiv, 214
„ — (without discovered cause), complicating pregnancy and labour (John Phillips) . . . . . xli, 389
„ ascitic fluid from, in a case of double ovarian cysts and fibroid of the uterus (A. W. Edis) . . . . xx, 164
„ death from, in a case of fibrous tumour of uterus (J. B. Hicks) vii, 110
„ — — ruptured uterus (J. T. Mitchell) . . . xi, 204
„ — of a dwarf, three days after Cæsarean section (J. B Hicks) . . . . . xxi, 253
„ encysted tuberculous, and its effects upon the female pelvic viscera (J. H. Targett) . . . . xxxix, 126
„ fœtal, complete obliteration of the canal of the small intestine by (R. Druitt) . . . . . ii, 135
„ — (W. A. Hunt) . . . . . ix, 15
„ gonorrhœal pelvic (J. Bland-Sutton) . . . xliii, 251
„ intra-uterine, case of (D. C. MacCallum) . . . xviii, 116

PERITONITIS (*continued*)—
„ its nature and treatment (J. Shaw) . . xxxvii, 10
„ pelvic, the value of abdominal section in certain cases of (C. J. Cullingworth) . . . . xxxiv, 254
„ puerperal (J. T. Mitchell) . . . . iv, 96
„ — complicated with ovarian disease, followed by febrile diseases of the puerperal state, the probable consequences of infection (R. U. West) . . . . . i, 187
„ caused by escape of pus or putrilage from the Fallopian tube into the abdominal cavity, following on abortion artificially induced (R. Barnes) . . . . . iii, 419
„ septic, in secondary abdominal pregnancy (H. A. Lediard) . xli, 276
„ — splenic abscess; death on sixteenth day after delivery; eclampsia (J. C. Holdich Leicester) . . . xlvii, 271
„ and the *Staphylococcus albus* (J. D. Malcolm) . . xlviii, 97

PERTUSSIS; its causes, symptoms and treatment (R. Marley) . v, 300

PESSARIES, new form of, for treatment of anteversion or anteflexion (A. L. Galabin) . . . . xviii, 176
„ for anteflexion (W. S. Playfair) . . . . xv, 124
„ — and version (W. G. Hewitt) . . . . ix, 63
„ containing fluids (A. E. Sansom) . . . . x, 245
„ of glycerine and gelatine (H. Gervis) . . . xxvii, 163
„ Greenhalgh's, removed with difficulty from the vagina (A. L. Galabin) . . . . . xxi, 49
„ Hodge's, modification of (H. Gervis) . . . xxiii, 33
„ — — (J. Blake) . . . . . xiv, 137
„ — lever, removal of, which had ulcerated into the wall of the vagina after being worn five years (T. C. Hayes) . xvi, 30
„ — watch-spring (J. B. Hicks) . . . . xxx, 227
„ medicated (W. O. Priestley) . . . . vii, 208
„ — (A. Meadows) . . . . . x, 224
„ — in the treatment of uterine disease (T. H. Tanner) . iv, 205
„ mechanical action of (J. Williams) . . . xviii, 126
„ new (H. R. Davies) . . . . . xliii, 28
„ for prolapsus uteri (R. Barnes) . . . . xix, 119
„ — (A. L. Galabin) . . . . . xx, 169
„ retention of, for many years (H. Gervis) . . . xvii, 274
„ for retroversion and prolapse (C. Godson) . . . xxvi, 272
„ Albert Smith's, modification of (W. C. Grigg) . . xvi, 247
„ spring (Beverley Cole) . . . . xxiii, 238
„ elastic spring (R. Greenhalgh) . . . . x, 93
„ vulcanite stem, shield for supporting (A. W. Williams) . xv, 246
„ stem, a new form of (J. G. Swayne) . . . xxiv, 220
„ — flexible galvanic (R. Barnes) . . . . xix, 136
„ — intra-uterine, the necessity for caution in the employment of (A. W. Edis) . . . . . xvi, 3
„ — — (C. H. F. Routh) . . . . . xi, 53
„ — — treatment of anteflexion of the uterus without (J. H. Galton) . . . . . xvi, 171
„ — — (A. Meadows) . . . . . viii, 135
„ — — for the relief of flexions and displacements of the uterus (W. R. Jordan) . . . . . xvi, 125
„ — vaginal, and uterine (H. Macnaughton-Jones) . xxxvii, 80
„ — spring intra-uterine (G. Weir) . . . . viii, 218
„ for flexions and displacements of the uterus (W. G. Hewitt) . x, 223
„ for treatment of flexions of the uterus (A. W. Williams) . xiv, 308

PESSARIES (*continued*)—
„ stem, metallic, removed from a patient who had worn it for five years and a half (W. S. Playfair) . . . xxi, 50
„ — wooden ring, which had been worn for twenty-six years (C. Godson) . . . . . xix, 203
„ worn for six years, with the lumen entirely filled up by deposit (P. Horrocks) . . . . . xxvi, 54
„ Zwancke's, recto-vaginal fistula from retention of, for nearly two years (T. Churton) . . . . xvi, 223
„ — retained for six years, producing recto-vaginal and vesico-vaginal fistulæ with phosphatic calculi (A. L. Galabin) . xix, 201
„ combining Zwancke's and ordinary stem (W. S. Playfair) . xiii, 2
„ of xylonite (A. Meadows) . . . . xxiii, 131

PHANTOM, model, for obstetric classes, designed by Budin and Pinard (F. Barnes) . . . . . xix, 229
„ employed for class purposes in midwifery (J. B. Hicks) . xix, 231

Philip (Dr.), retro-uterine hæmatocele . . . x, 57

Phillips (J. J.), prolapsus uteri ending fatally by dilatation of the ureters and wasting of the kidneys . . . xii, 276
„ cedar pencil extracted from the bladder . . . xiv, 37
„ retro-flexion of the uterus as a frequent cause of abortion . xiv, 45
„ treatment of suppurating ovarian cysts by drainage . xiv, 340
„ see *Hicks, J. Braxton.*

Phillips (John), child with deformed hand and foot . . xxviii, 89
„ for *W. S. Playfair*, hæmatosalpinx complicating ovarian tumour . . . . . xxviii, 89
„ multiple fibro-myomata complicating a twin pregnancy . xxviii, 138
„ four cases of spurious hermaphroditism in one family . xxviii, 158
„ blighted ovum . . . . . xxviii, 209
„ case of dicephalous monstrosity . . . . xxviii, 278
„ — — heart and large vessels of . . . . xxix, 55
„ for *Reginald Clarke*, case of spinal meningocele . . xxix, 188
„ case of pregnancy complicated by secondary hepatic cancer . xxix, 378
„ — hæmatocele treated by operation . . . xxix, 384
„ congenital malignant disease (sarcoma) of the forehead and neck in a new-born infant . . . xxx, 301, 334
„ — *report* on ditto by committee (John Phillips and Alban Doran) . . . . . xxx, 335
„ on the value of pilocarpine in pregnancy, labour, and the lying-in state . . . . . xxx, 354
„ diseased fœtal membranes in early pregnancy, being an aborted ovum showing cysts in the decidua vera . . xxxi, 52
„ — *report* on ditto by committee (F. H. Champneys, John Phillips, and W. S. A. Griffith) . . . . xxxi, 161
„ on acute non-septic pulmonary disorders as complications of the puerperium . . . . . xxxi, 171
„ blue urine; cyanuria . . . . . xxxi, 256
„ cystic ovaries and hypertrophied Fallopian tubes . . xxxi, 332
„ cystic disease of the chorion, hydatiform degeneration . xxxii, 65
„ uterus and adherent placenta from patient dying of post-partum hæmorrhage . . . . . xxxii, 195
„ on a case of death following vaginal injection of acid nitrate of mercury to produce abortion . . xxxii, 308; xxxiii, 180
„ ruptured uterus occurring during labour and after external violence . . . . . xxxii, 375

PHILLIPS (JOHN) (*continued*)—
„ uterus and appendages from a patient dying during menstruation from purpura hæmorrhagica (Werlhof's) . . xxxiii, 2
„ blighted ovum with fleshy decidual hypertrophy . . xxxiii, 35
„ death following vaginal injection of acid nitrate of mercury . xxxiii, 180
„ influence of purpura hæmorrhagica upon menstruation and pregnancy . . . . . xxxiii, 390
„ retroflexion and ectopia viscerum . . . xxxiii, 480
„ case of extra-uterine gestation in which fœtal death probably occurred at the end of the sixth month, and abdominal section was performed two a half months later . . xxxv, 162
„ anterior colpotomy . . . . xxxviii, 213
„ monstrosity resulting from amniotic adhesion to skull xxxviii, 388
„ fœtal monstrosity . . . . . xxxix, 44
„ ruptured uterus treated by abdominal hysterectomy : xxxix, 260
„ placenta from a case of extra-uterine fœtation; the child at full term, and removed five months after death . . xl, 3
„ fibro-myoma of vaginal wall (with microscopical slide) . xl, 130
„ (for *Harold Jäger*), monstrosity resulting from amniotic adhesion to skull . . . . . xl, 130
„ tubal pregnancy (molar) complicated by suppurating ovarian cyst of the opposite side . . . . xli, 384
„ acute peritonitis (without discovered cause) complicating pregnancy and labour . . . . . xli, 389
„ extra-uterine gestation in which fœtal death occurred at term after spurious labour and abdominal section was performed four to five months later . . . . xlii, 121
„ a case of chorion-epithelioma . . . . xlviii, 45

PHIMOSIS, congenital, occurring in the same family as four cases of congenital imperforate vagina (H. M. Madge) . . xi, 213

PHLEBITIS of the umbilical vein producing pyæmia, two cases of death in new-born infants from (G. Roper) . . xix, 8

PHLEGMASIA ALBA DOLENS—on the common form of, after confinement (C. H. Roberts) . . . xxxvii, 163
„ (W. T. Fox) . . . . ii, 201
„ with lymphatic varix (J. Matthews Duncan) . . xxiii, 132
„ pathological lesion of (W. T. Fox) . . . ii, 222
„ vessels concerned in the production of (W. T. Fox) . . iv, 144
„ uterus and vessels concerned in (R. Barnes) . . x, 113
„ in a case of puerperal septicæmia (A. Wiltshire) . . xviii, 181

PHLEGMON of the broad ligament, *post-mortem* appearances of (A. H. N. Lewers) . . . . . xxx, 7

PHOTOGRAPHS from a case of primary cancer of the Fallopian tube (Alban Doran) . . . . . xlii, 6

PHTHISIS pulmonalis and uterine affections (R. F. Battye) . viii, 237
„ should pregnancy be terminated prematurely in cases of ? (W. Duncan) . . . . . xxxii, 7
„ tuberculosis of the Fallopian tubes and uterus in cases of (P. D. Turner) . . . . . xli, 359

PIGMENTATION, dark crescentic, round the nipple of both breasts (C. Godson) . . . . . xvii, 343

PILOCARPINE, the value of, in pregnancy, labour, and the lying-in state (John Phillips) . . . . . xxx, 354

PIRIE (WILLIAM), report on a peculiar mucous polypus of the cervix uteri shown by R. G. McKerron . . . xxxix, 314

PLACENTA, "abdominal" pregnancy successfully treated by removal of child and, three months after death of child at term (John W. Taylor) . . . . . xxxix, 178
„ abnormal attachment of (A. L. Galabin) . . . xxiii, 130
„ abscess in (R. Barnes) . . . . . viii, 149
„ absorption (?) of, in a case of gastrotomy from extra-uterine gestation, in which it never came away (J. Braithwaite) . xxviii, 33
„ adherent (Wynn Williams) . . . . xxiv, 300
„ — (R. Boxall) . . . . . xxvi, 58
„ — and uterus from patient dying of post-partum hæmorrhage (John Phillips) . . . . . xxxii, 195
„ anatomy of the human (J. B. Hicks) . . . . xiv, 149
„ attached to head of fœtus (E. J. Tilt) . . . . xvi, 124
„ attached to the top of the uterus in a specimen of ectopic pregnancy going nearly to term in the peritoneal cavity (G. E. Herman) . . . . . xxxix, 135
„ battledoor (R. U. West). . . . . vii, 257
„ double battledore, with a single umbilical cord, connected with one child (J. H. Davis). . . . . ii, 273
„ two specimens of, in which the blood-vessels ran along the membranes from the edge of the placenta and then united to form the umbilical cord (W. H. Maberly). . . . xix, 65
„ calcareous degeneration of (F. H. Champneys) . . xxiv, 190
„ cord, fœtus, and membranes (R. Wise) . . xxxviii, 166
„ cyst of (R. Boxall) . . . . . xxvi, 59
„ with cyst on the fœtal surface (John Williams) . . xxv, 69
„ partial vesicular degeneration of the (A. L. Galabin) . xlv, 100
„ on the development and normal structure of the human (T. W. Eden) . . . . . xxxvii, 205, 227
„ disease of (J. Marshall) . . . . . viii, 137
„ diseased, note on (Lawson Tait) . . . . . xvii, 326
„ double (J. C. Richardson) . . . . . viii, 337
„ — (W. G. Hewitt) . . . . . viii, 137
„ — or dicotyledonous (W. T. Greene) . . . . xviii, 68
„ — atrophied and flattened (Heywood Smith) . . xvi, 2
„ — in a case of arrested development of one twin (A. W. Edis) xxv, 213
„ early, with localised hydatidiform degeneration (R. Boxall) . xxxiii, 494
„ expression and extraction of, on the methods adopted by Credé and others for the (J. Watt Black) . . . xxxv, 75
„ expulsion of the (F. H. Champneys) . . . xxix, 151
„ fatty, from a patient who had twelve still-born children and frequent hæmorrhage in her pregnancies (T. C. Hayes) . xvi, 175
„ — and a still-born fœtus from a syphilitic patient (T. C. Hayes) xvii, 275
„ — degeneration and friability of the, with extreme dropsy (J. Brunton) . . . . . xvii, 175
„ the subject of extreme fatty degeneration (J. Brunton) . ix, 85
„ with fibrinous deposits (J. Marshall) . . . ix, 242
„ — — (J. Brunton) . . . . . x, 20
„ non-capsulated fibroids resembling retained (J. Braithwaite) . xxiii, 182
„ frozen sections of a uterus at the tenth week of pregnancy, from a patient who died of heart disease showing hæmorrhages into (G. F. Blacker) . . . . . xlii, 235
„ and fœtus of extra-uterine gestation removed by abdominal section (G. E. Herman) . . . . xxviii, 141
„ — funis obliterated by twisting (A. Rasch) . . x, 94
„ — of about five months, funis knotted round neck of child (W. F. Cleveland) . . . . . xiii, 1

PLACENTA (*continued*)—
„ and fœtus in extra-uterine fœtation (W. R. Jordan) . . xv, 124
„ — successfully removed in a case of tubal pregnancy (G. E. Herman) . . . . . xxx, 123
„ — removed by laparotomy from a case of extra-uterine gestation (W. Duncan) . . . . . xxxvi, 146
„ — removed six months after spurious labour in a case of abdominal pregnancy (E. J. Maclean) . . . xlviii, 129
„ fœtus, and membranes delivered entire; concealed accidental hæmorrhage (W. R. Dakin) . . . xxxvi, 315
„ and five months' fœtus, from a case of twin pregnancy in which the second child was delivered alive at or near full term along with the dead fœtus (G. G. Genge) . xxxviii, 5
„ with fœtus attached, showing a knot in the umbilical cord (C. Godson) . . . . . xxv, 66
„ with knotted cord (J. Brunton) . . . . xi, 54
„ and knotted cord (J. A. Tapson) . . . xi, 242
„ large, in a fœtus with anasarca (R. Boxall). . . xlii, 98
„ mode of dealing with, in gastrotomy, for removing the fœtus in extra-uterine gestation (R. Barnes) . . . xiv, 325
„ from a case of extra-uterine fœtation; the child at full term, and removed five months after death (John Phillips) . xl, 3
„ growth of, after death of the fœtus in ectopic gestation (Lawson Tait and C. Martin) . . . . xxxiv, 206
„ with hæmorrhage (H. A. Des Vœux) . . xxxvii, 9
„ from a case of accidental hæmorrhage (R. D. Muir) . . xxxv, 338
„ hypertrophy of (G. E. Herman) . . . . xxiv, 189
„ — with dropsy in a fœtus (J. Bassett) . . . xix, 261
„ implantation of, and the insertion of the cord, the relation between (F. H. Champneys) . . . . xxix, 337
„ incomplete tubal abortion showing intra-mural embedding of (C. Lockyer) . . . . . xlv, 191
„ in labour producing internal and concealed hæmorrhage (J. T. Mitchell) . . . . . viii, 282
„ lesion (rupture?) of the (H. M. Madge) . . . vi, 1
„ two, and membranes from a case of triplets (P. Horrocks) . xxvi, 160
„ of a double ovum (W. Outhwaite) . . . xxiv, 3
„ polypus of (T. C. Hayes) . . . . xvii, 177
„ prolapsed (C. Smuts) . . . . viii, 280
„ retained, hæmorrhage due to (A. W. Williams) . . viii, 317
„ — *in utero* two months (J. B. Walker) . . . xii, 338
„ hæmorrhage from retained, after abortion, terminating fatally (G. Lowe) . . . . . xii, 323
„ separation of the (F. H. Champneys) . . . xxix, 117
„ — and expulsion of, from the uterus (F. H. Champneys) xxv, 160; xxix, 151
„ structure of the ripe, and the changes which occur in placentæ retained *in utero* after the death of the fœtus (T. W. Eden) xxxviii, 360
„ succenturiata (F. H. Champneys) . . . xxv, 214
„ succenturiate, unusual form (A. W. Sikes) . . . xlv, 381
„ supplementary, the size of the palm of the hand (G. Roper) . xxii, 45
„ syphilitic disease of (B. Godfrey) . . . xiv, 137, 211
„ from a case of triplets (A. L. Galabin) . . . xxiii, 129
„ — ruptured tubal gestation, complicated by a large hæmatosalpinx on the opposite side (C. J. Cullingworth) . . xxxii, 273
„ tumour of (A. L. Galabin) . . xxiv, 241; xxvii, 107
„ — from a primipara (G Roper) . . . . xix, 256

PLACENTA (*continued*)—
„ with round tumour in centre (J. Brunton) . . . viii, 275
„ from twins, two cases of, prematurely expelled (A. W. Edis) xx, 321, 322
„ to which the umbilical vessels were peculiarly distributed (insertio velamentosa) (C. Godson) . . . xx, 324
„ in uterus removed by Porro's operation, condition of (A. L. Galabin) . . . . . xxix, 98
„ with unusual arrangement of vessels (Aust Lawrence) . xviii, 118
„ unusual size and shape of (R. Boxall) . . . xxxiv, 464
„ velamentosa and an abnormally large placenta (A. F. Stabb) xxxviii, 4

PLACENTA PRÆVIA, fourteen cases illustrating physiology and treatment of (R. Barnes) . . . . i, 83
„ practical remarks upon the treatment of (R. Greenhalgh) . vi, 140
„ discussion of paper on (R. Greenhalgh) . . . vi, 188
„ (G. Roper) . . . . . viii, 340
„ spontaneous separation of (J. M. Duncan) . . . xv, 189
„ and fibroids extensively developed in the walls of the dissected uterus pregnant about three and a half months (J. B. Hicks) . . . . . xvii, 298
„ with multiple fibroids (A. Wiltshire) . . . xxiii, 163
„ complicated by a large myoma (J. Hickinbotham) . . xxiii, 167
„ the diagnosis of, by palpation of the abdomen (H. R. Spencer) xxxi, 203
„ uterus showing (C. J. Cullingworth) . . xxxii, 67, 107
„ (W. R. Pollock) . . . . . xxxv, 241
„ attached to an unruptured amnial sac containing a fœtus of four months' development (A. D. Leith Napier) . . xxxiv, 158
„ associated with unusual size and shape of the placenta (R. Boxall) . . . . . xxxiv, 464
„ complete, in a case of triplets in which the children were delivered alive through a perforation in the first placenta (H. R. Spencer) . . . . . xxxv, 107
„ marginalis *in situ*, uterus with (G. F. Blacker) . . xxxvi, 194
„ treatment of, by Champetier de Ribes' bag (G. F. Blacker) . xxxix, 138
„ centralis, uterus with interstitial fibroid from a case of (R. Boxall) . . . . . xl, 338
„ spontaneous rupture of the uterus in (J. P. Maxwell) . xliii, 217

PLASTERS, ready-made (E. J. Tilt) . . . . v, 41

PLASTIC operation for defective formation of skin round the umbilicus (A. Napper) . . . . . iii, 65
„ operations, cases of vesico-vaginal fistula left after lithotomy, cured by (Lawson Tait) . . . . xviii, 209

Playfair (W. S.), extra-uterine fœtation . . . vii, 1
„ mechanism and management of delivery in cases of double monstrosity . . . . . viii, 300
„ treatment of labour complicated by ovarian tumour . . ix, 69
„ cardiac apnœa after delivery . . . . x, 21
„ malignant disease of the uterus complicated with pregnancy . x, 58
„ absorption of fibroid tumours of the uterus . . x, 102
„ carcinoma of body of uterus . . . xii, 116
„ guarded perforator invented by Mr. Matthews . . xii, 117
„ univentricular heart of child that lived nine months . xii, 163
„ pessary combining Zwancke's and ordinary stem . . xii, 2
„ irritable bladder in the latter months of pregnancy . . xiii, 42
„ sudden death after delivery . . . xiii, 192
„ treatment of empyema in children . . . xiv, 4

PLAYFAIR (W. S.) (*continued*)—
„ pessary for anteflexion . . . . . xv, 124
„ malignant sarcoma of the right broad ligament . . xv, 217
„ necrosis of pubic bones following delivery . . . xv, 219
„ on puerperal thrombosis . . . xvi, 42, 89
„ remarks in the discussion on puerperal fever . . xvii, 200
„ case of caries of the pelvic bones following delivery . xviii, 142
„ on fibroid tumour complicating delivery . . xix, 101; xxiii, 25
„ specimen of elephantiasis of the vulva . . . xix, 184
„ for *Gaillard Thomas*, model of bed for cases of puerperal hyperpyrexia requiring continuous application of cold . . xx, 171
„ inaugural address as President . . . . xxi, 29
„ metallic stem pessary removed from a patient who had worn it for five years and a half . . . . xxi, 50
„ remarks in the discussion on the use of forceps . xxi, 141, 235
„ pieces of uterine decidua illustrating the extent to which the ovum may be occasionally interfered with without abortion occurring . . . . . xxi, 290
„ for *T. G. Clabburn*, supposed super-fœtation . . xxii, 3
„ annual address as President . . . xxii, 55; xxiii, 46
„ the conjoined twins, Rozalie and Josepha Blazet, from Bohemia xxii, 265
„ notes on trachélo-raphé, or Emmet's operation . . xxiv, 54
„ hæmatocele, the result of malignant disease . . xxvi, 6
„ note on the absorption, with ultimate recovery, of thrombosis in the pulmonary artery in the puerperal state . . xxvi, 162
„ scale for calculating onset of labour . . . xxviii, 68
„ intra-peritoneal hæmatocele, small ovarian cyst and hæmatosalpinx . . . . . xxxi, 130
„ — *report* on ditto by committee (W. S. Playfair, Alban Doran, and W. S. A. Griffith) . . . . . xxxi, 162
„ intra-uterine polypus . . . . . xxxi, 132
„ cancerous uterus removed by vaginal operation . . xxxi, 227
„ on removal of the uterine appendages in cases of functional neurosis . . . . . xxxiii, 7
„ ligature discharged after an abdominal section . . xxxiii, 386
„ double pyosalpinx, associated with fibro-myoma of uterus . xxxiii, 497
„ specimen of probable superfœtation . . . xxxiii, 496
„ supposed unruptured tubal gestation sac . . xxxiv, 28, 465
„ — *report* of committee . . . . . xxxiv, 467
„ cancerous and gravid uterus removed *per vaginam* . xxxvii, 198
„ sarcoma of the body of the uterus removed by vaginal extirpation . . . . . xxxvii, 200
„ tubal abortion . . . . . xxxvii, 224
„ slough forming a complete cast of the vagina, from a case of enteric fever . . . . . xxxviii, 33
„ ruptured tubal gestation . . . . xxxviii, 34
„ carcinoma of uterus . . . . . xxxix, 288
„ see *Phillips, John.*

PLEURAL CAVITY, left, escape of heart into, through incomplete pericardial sac (R. Boxall) . . . . xxviii, 209

PLUGGING the uterus in severe cases of post-partum hæmorrhage (A. H. N. Lewers) . . . . . xxxii, 356

PNEUMOCOCCUS MENINGITIS, primary, simulating puerperal eclampsia (T. Wilson) . . . . . xliv, 5

PNEUMONIA causing death in a case of ovarian cyst; uterine myoma and polypus (J. Crawford) . . . xxxiii, 74

PNEUMONIA (*continued*)—
„ infantile interstitial (A. W. Sikes) . . . xlvii, 74
POCKET CASE, surgical (C. Godson) . . . . xxiii, 180
POLARITY of the uterus (J. Matthews Duncan) . . xxviii, 115
Pollock (C. Stewart), cyst of the ovary of a mare . . xxxi, 234
„ — *report* on ditto by committee (J. Bland-Sutton, C. Stewart Pollock, and Alban Doran) . . . . . xxxi, 253
Pollock (Timothy), difficult position of the heads during twin labour . . . . . iii, 103
Pollock (W. Rivers), placenta prævia . . . xxxv, 241
„ fœtus papyraceus . . . . xxxviii, 320
„ dermoid tumour of both ovaries, with very long ovarian ligament on the left side . . . . . xl, 119
„ the present position of external version in obstetrics with a suggestion of a new method of performing it . . xlviii, 319
POLYPI, two sessile fibroid (T. C. Hayes) . . . xxxiii, 6
„ of the uterus, instrument for the removal of (W. T. Smith) iii, 413
„ uterine, polyptrite for crushing the necks of (J. H. Aveling) . iv, 135
POLYPTOME, vaginal and uterine (H. Macnaughton-Jones) .xxxvii, 80
POLYPTRITE, a new instrument for crushing the necks of uterine polypi (J. H. Aveling) . . . . iv, 135
POLYPUS, adeno-myomatous, of the cervix (F. E. Taylor) . xlviii, 12
„ cancerous, with microscopic sections (A. L. Galabin) . xx, 82
„ peculiar cervical mucous (H. R. Spencer) . . . xli, 383
„ fibrinous (W. S. A. Griffith) . . . . xxv, 165
„ fibroid, attached to the fundus uteri removed by écraseur; recovery (D. L. Roberts) . . . . xi, 244
„ — of cervix (W. Duncan) . . . . xxxvi, 114
„ — pediculated at its base to posterior margin of os uteri, its neck protruded at vulva, removed by the single wire écraseur (J. H. Davis) . . . . . ix, 152
„ — removed by Hicks' instrument (H. Oldham) . . iii, 349
„ — large fibrous (R. Greenhalgh) . . . . vii, 256
„ — (C. Godson) . . . . xxvi, 328
„ — removal of (Heywood Smith) . . . . xxiii, 233
„ intra-uterine sessile (T. C. Hayes) . . . xxxiii, 73
„ large-sized mucous (A. W. Williams) . . . xiv, 135
„ large soft (T. C. Hayes) . . . . xxxiii, 389
„ peculiar mucous, of the cervix uteri (R. G. McKerron) . xxxix, 314
„ malignant vaginal, secondary to an adrenal tumour of the kidney (A. Doran) . . . . . xlix, 182
„ multiple, myxomatous, from cervix uteri (W. Duncan) xlii, 243; xliii, 75
„ placental (T. C. Hayes) . . . . . xvii, 177
„ — (Alban Doran) . . . . xxxvii, 229
„ removal of (R. Greenhalgh) . . . . vii, 25
„ urethral, removed from a woman aged 60 (C. Godson) . xxi, 57
„ of the uterus (J. H. Davis) . . . . i, 247
„ — with clinical observations (F. Elkington) . . i, 112
„ — (A. W. Edis) . . . . . xxiii, 205
„ — (W. S. Playfair) . . . . . xxxi, 132
„ — of large size (G. G. Bantock) . . . . xxii, 105
„ uteri (H. Gervis) . . . . . xi, 4
„ — complicating labour, removed by ligature two days after delivery (H. L. Freeman) . . . . . v, 42
„ — large fibroid, removed by single-wire écraseur (A. Meadows) xi, 241

POLYPUS (*continued*)—
„ fibrous, of the uterus (W. G. Hewitt) . . . v, 123
„ uterine, new instrument for removal of (J. B. Hicks) . iii, 346
„ of uterus, drawings of microscopic sections of, showing ciliated epithelium (H. Gervis). . . . . xxviii, 240
„ — pendulous in the vagina removed by the écraseur (W. G. Hewitt) . . . . . iii, 350
„ adherent to the vagina (J. B. Potter) . . . xxv, 138
„ weighing 2¼ lb. (J. B. Hicks) . . . . vii, 253
PONDER (C. F.), studies in obstetrics. . . . . xl, 339
POOLE (S. WORDSWORTH), case of meningocele complicating labour . . . . . xix, 265
„ case of fracture of the cranium in a new-born child, with a history of the case . . . . . xx, 105
„ case of so-called congenital dislocation of both hips in a girl aged 4 . . . . . xxii, 214
POPE (H. CAMPBELL), anencephaloid fœtus . . . xxiii, 178
„ missed abortion . . . . . xxiv, 139
„ notes of a case of gestation in one horn of a uterus bicornis unicollis . . . . . xxviii, 70
„ — *report* on ditto by committee (G. E. Herman, Alban Doran, and W. S. A. Griffith) . . . . . xxviii, 72
POPOW (W. A.), on the corpus luteum . . . xxiv, 100
PORRO MEDAL and report on Porro-Cæsarean section (H. R. Spencer) . . . . . xliv, 298
PORRO'S OPERATION, case of (A. L. Galabin) . . . xxxi, 57
„ — (M. Handfield-Jones) . . . . xxvii, 4
„ uterus removed by (C. Godson) . . . . xxiv, 299
„ — (Heywood Smith) . . . . . xxv, 2
„ — (C. J. Cullingworth) . . . . . xxxii, 135
„ condition of placenta in uterus removed by (A. L. Galabin) . xxix, 98
„ uterus and placenta removed from a rachitic woman by (W. Duncan) . . . . . xxx, 408
„ with intra-peritoneal treatment of the stump, three cases of (H. R. Spencer) . . . . . xxxviii, 389
„ uterus from a case of, with intra-peritoneal treatment of the stump (W. J. Gow) . . . . . xxxix, 7
PORRO-CÆSAREAN HYSTERECTOMY with retro-peritoneal treatment of the stump in a case of fibroids obstructing labour; with remarks upon the relative advantages of the modern Porro operation over the Sänger-Cæsarean in most other cases requiring abdominal section (Amand Routh) . . xlii, 244
„ presentation of report on (H. R. Spencer) . . . xliv, 298
PORTER (C. R.), intra-peritoneal rupture of the bladder occurring during labour . . . . . xlix, 170
PORTER (E.), retained fœtus and placenta . . . xiii, 129
PORTIO VAGINALIS UTERI, adenoma of, forming a depressed sore or ulcer (J. Braithwaite) . . . . xxxvi, 208
POST-MORTEM PARTURITION, with references to forty-four cases (J. H. Aveling) . . . . . xiv, 240
POTASSIUM, bromide of, in puerperal mania (J. B. Curgenven) . ix, 155
POTTER (J. B.), ovarian tumour from the body of a woman who died from a severe burn . . . . xii, 246

Potter (J. B.) (*continued*)—
„ case of pregnancy complicated with malignant growths in the vagina and rectum . . . . . xx, 110
„ pocket case containing apparatus for injecting the uterus in cases of post-partum hæmorrhage . . . xxi, 29
„ polypus adherent to vagina . . . . xxv, 138
„ fibro-cellular tumour of labium . . . . xxvi, 228
„ inaugural address as President . . . . xxvii, 85
„ annual address as President . . xxviii, 52; xxix, 86
Potts (W. J.) (introduced by Dr. Stevens), lithopædion . xlviii, 338
Power (D'Arcy), dissection of female twin monster . . xxviii, 68
POZZI MEDAL (C. J. Cullingworth) . . . . xlviii, 271
PRACTICE, cases in (E. Copeman) . . . . xiii, 232
PREGNANCY, abortion with albuminuria and convulsions in six successive cases of (W. H. Broadbent) . . . i, 108
„ abnormal (R. Hardey) . . . . . ii, 307
„ amputation of the arm in (A. Napper) . . . vii, 12
„ Bright's disease during (G. E. Herman) xxix, 539; xxx, 478; xxxii, 320, 349
„ co-existing tubal and uterine, abdominal section; subsequent delivery at term (W. Tate) . . . . xlix, 51
„ in a rudimentary uterine horn (H. R. Andrews) . . xlix, 209
„ in a woman barren for thirteen years, after bilateral division of a deformed cervix uteri (G. Roper) . . . xix, 169
„ in the right cornu of a fibroid uterus (F. N. Boyd) . . xlix, 49
„ irritable bladder in the latter months of (W. S. Playfair) . xiii, 42
„ natural, and delivery subsequent to Cæsarean section (W. Newman) . . . . . xiv, 142
„ complicated by cancer of the cervix, followed by pyæmia and symptoms simulating diphtheria (A. L. Galabin) . . xxiii, 186
„ — with cancerous disease of the genital canal, its treatment (G. E. Herman) . . . . . xx, 191
„ — by secondary hepatic cancer (John Phillips) . . xxix, 378
„ advanced, cancer of the cervix complicating labour in (H. R. Spencer) . . . . . xlvi, 355
„ multiple medullary cancer complicated with (T. H. Tanner) . iv, 243
„ changes the tissues of the uterus undergo during (S. Beck) . xiii, 290
„ on some changes in the uterus resulting from (John Williams) xx, 172
„ chorea in (R. Barnes) . . . . . x, 147
„ — (M. Handfield-Jones) . . . . xxxi, 243
„ — successfully treated by dilatation of the os uteri (W. F. Wade) . . . . . xxii, 244
„ — (J. B. Hicks) . . . . . xxxiii, 486
„ combination of chorea with (W. B. Woodman) . . xii, 102
„ with chyluria (J. C. Holdich Leicester) . . . xlvii, 108
„ contractions of the uterus throughout their physiological effects and value in the diagnosis of (J. B. Hicks) . . xiii, 216
„ on intermittent contractions of uterine fibromata and in, in relation to diagnosis (J. B. Hicks) . . . xxxvi, 188
„ cornual, at full term, removed six months after the death of the child (C. H. Roberts) . . . . xlviii, 309
„ in a rudimentary horn (L. Remfry) . . . xxxvi, 263
„ — of uterus (A. L. Galabin) . . . xxxvii, 225
„ in a rudimentary uterine cornu (A. H. N. Lewers) . . xlvii, 111
„ of right horn in a complete uterus bicornis (E. H. M. Sell) . xv 180
„ in one horn of a uterus bicornis unicollis (H. C. Pope) xxviii, 70, 72

PREGNANCY (*continued*)—
„ dermoid ovarian cyst impacted in the pelvis which was removed by abdominal section during the ninth month of (T. H. Morse) . . . . . xxxviii, 221
„ diabetes insipidus in (J. Matthews Duncan) . . xxix, 308
„ difficulties encountered in determining the existence of, and the value of auscultation as a means of diagnosis (E. Copeman) x, 62
„ discoloration of the skin of the forearms and hands during (J. G. Swayne) . . . . . iv, 18
„ eclampsia of, with observations on the state of the renal function (G. E. Herman) . . . . xxix, 517
„ notes of a case of puerperal eclampsia, with a description of a five weeks' ovum removed in a subsequent (W. S. A. Griffith and T. W. Eden) . . . . . xli, 151
„ hypertrophic elongation of the cervix uteri at the full term of (G. Roper) . . . . . xv, 167
„ strong mental emotion affecting women during, as a cause of idiocy in the offspring (A. Mitchell) . . . xxvi, 124
„ complicated by epithelioma of the cervix uteri (A. W. Edis) . xvii, 344
„ epithelioma of cervix with (A. W. Edis) . . . xxiii, 264
„ — complicated with (C. T. Savory) . . . xvii, 82
„ — removed by écraseur wire during, without causing abortion (C. Godson) . . . . . xxv, 18
„ — complicating, Cæsarean section (A. W. Edis) . . xxiv, 304
„ extensions or retroflexions of the fœtus, especially of the trunk, during (J. Matthews Duncan and J. B. Hurry) . . xxvi, 206
„ fracture of the pelvis with injury to the uterus in the sixth month of (T. Fairbank) . . . . ix, 1
„ fibro-enchrondromatous tumour complicating; safe delivery (A. Wiltshire) . . . . . xii, 376
„ complicated with multiple fibroids, rapidly fatal cerebral hæmorrhage in a case of (W. Duncan) . . . xxxii, 2
„ uterine fibroid removed during; premature labour (J. Knowsley Thornton) . . . . . xxi, 163
„ uterine fibroids complicating (H. M. Madge) . . xiv, 227
„ œdematous fibroid tumour of uterus associated with (A. L. Galabin) . . . . . xxxvii, 286
„ early, attended by fibrous tumour of the uterus (J. H. Davis) viii, 11
„ diseased fœtal membranes in early (John Phillips) . xxxi, 52, 161
„ five months' fœtus and placenta from a case of twin, in which the second child was delivered alive at or near full term along with the dead fœtus (G. G. Genge) . . xxxviii, 5
„ fibro-myoma removed by abdominal myomectomy in the second month of (A. Doran) . . . . . xlvii, 426
„ necrobiotic uterine fibro-myoma occurring in (F. E. Taylor) . xlvii, 333
„ case of galactorrhœa during a first (W. S. A. Griffith) . xxxiv, 491
„ gangrene of the thigh during the seventh month of (J. G. Swayne) . . . . . xxv, 215
„ three cases of glycosuria of (W. H. B. Brook) . . xlviii, 192
„ fatal case of concealed accidental hæmorrhage, occurring at the eighth month of (R. Dunn) . . . . viii, 285
„ concealed accidental hæmorrhage at the latter end of, and during labour (J. B. Hicks) . . . . ii, 53
„ hæmorrhage from the Fallopian tube without evidence of tubal (Alban Doran) . . . . . xl, 180
„ abdominal hysterectomy for cancer of the cervix associated with (D. Drew) . . . . . xlviii, 202

PREGNANCY (*continued*)—
„ complicating two cases of abdominal hysterectomy for fibroids (F. N. Boyd) . . . . . xlvi, 106
„ uterus removed at eight and a half months of, by abdominal hysterectomy for fibroid obstructing labour (A. Routh) . xliv, 41
„ of four and a half months, combined vaginal and abdominal hysterectomy for, complicated by cancer of the cervix (R. Sanderson) . . . . . xliii, 312
„ increase during, in fibroma of the abdominal wall (Alban Doran) . . . . . xxxix, 42
„ influence of purpura hæmorrhagica upon menstruation and (John Phillips) . . . . . xxxiii, 390
„ ingravescent hemiplegia during (P. Horrocks) . . xxxiii, 201
„ co-existent intra- and extra-uterine (E. W. Hey Groves) . xlvii, 428
„ on the administration of iron during, as a preventive of post-partum hæmorrhage (J. Bassett) . . . xvi, 111
„ iron salts in anæmia complicated with (W. B. Woodman) . xii, 33
„ and labour, unsuspected (T. H. Tanner) . . . iv, 113
„ — at term, myomectomy during, in an elderly primipara, with notes on similar cases (A. Doran) . . . xlviii, 303
„ — with Bright's disease, six more cases of (G. E. Herman) . xxxvi, 9
„ — fibroid tumours complicating (A. Donald) . . xliii, 180
„ leukæmia and (G. E. Herman) . . . . xliii, 234
„ the longings of women during (A. E. Giles) . . xxxv, 242
„ two cases of, complicated by extensive malignant disease of the cervix (A. L. Galabin) . . . . xviii, 239
„ malignant disease of uterus complicating (W. S. Playfair) . x, 58
„ complicated with malignant growths in the vagina and rectum (J. B. Potter) . . . . . xx, 110
„ membranes of a twin ovum of ten weeks (J. H. Davis) . x, 57
„ menstruation during (W. G. Hewitt) . . . viii, 221
„ mole or blighted ovum from supposed three months' (A. W. Williams) . . . . . xiii, 95
„ seventh month of, œdema of the lower half of the body after a fall in (A. Rasch) . . . . . vii, 80
„ orbital tumour in a hydrocephalic female fœtus, with tumour of cheek, mal-development of neck, associated with hydramnios, necessitating interference with, at the seventh month (H. S. Stannus) . . . . . xliii, 304
„ ovarian cyst co-existing with, which ruptured spontaneously ten days after labour (C. Clay) . . . . i, 226
„ associated with ovarian cystic disease (J. B. Hicks) . . xi, 263
„ complicated by ovarian cystoma (H. Macnaughton-Jones) . xlii, 140
„ incarcerated ovarian (dermoid) cyst, removed during (Amand Routh) . . . . . xl, 217
„ — — in the middle of (H. R. Spencer) . . . xl, 259
„ — — removed at the fourth month of; delivery of a living child at term (H. R. Spencer) . . . . xl, 329
„ complicated by ovarian disease (T. Spencer Wells) . . xi, 251
„ — — tumour at about two months (J. W. Taylor) . . xliv, 297
„ uterine appendages of the left side showing evidences of the rupture of the sac of an ovarian (H. Gilford) . . xliii, 24
„ primary ovarian, with rupture fourteen days after last menstruation (G. P. Anning and H. Littlewood) . . xliii, 14
„ ovarian (H. Briggs) . . . . . xlix, 222
„ ovariotomy performed during, additional cases of (T. Spencer Wells) . . . . . xix, 185

PREGNANCY (*continued*)—
„ ovariotomy during, with remarks on the treatment of ovarian tumours complicating (E. Goddard) . . . xiii, 275
„ — double, during (J. Knowsley Thornton) . xxvii, 46; xxviii, 41
„ — — two cases of (W. A. Meredith) . . . xxxiv, 239
„ after removal of both ovaries for cystic tumour (A. Doran) . xliv, 231
„ paraplegia occurring during (P. Boulton) . . . ix, 12
„ pelvic cellulitis after second, followed by suppuration in left groin and left antero-superior femoral region (N. C. Hatherley) . . . . . iii, 286
„ — — first, followed by suppuration at back and front parts of vagina (G. D. Gibb) . . . . . ii, 324
„ complicated by acute peritonitis (without discovered cause) (John Phillips) . . . . . xli, 389
„ in cases of phthisis, should it be terminated prematurely? (W. Duncan) . . . . . xxxii, 7
„ the value of pilocarpine in (John Phillips) . . xxx, 354
„ the diagnosis of placenta prævia by palpation of the abdomen (H. R. Spencer) . . . . . xxxi, 203
„ three and a half months, with placenta prævia and fibroids extensively developed in the walls of the dissected uterus (J. B. Hicks) . . . . . xvii, 298
„ *post-mortem* examination of a woman at the full period of (F. J. Gant) . . . . . vi, 214
„ protracted, case of (A. Thomson) . . . . xxvii, 308
„ — (C. Paget Blake) . . . . . xxxiv, 28
„ pyelonephritis of (W. A. Milligan) . . . xlviii, 1
„ pyosalpinx complicating (W. C. Grigg) . . . xxxiii, 75
„ risk to life of first and subsequent (R. Barnes) . . i, 311
„ rupture of the uterus, occurring at the eight month of (R. Dunn) . . . . . ix, 65
„ ruptured uterus in about the seventh month of, death from peritonitis (J. T. Mitchell) . . . . xi, 204
„ salivation of, successfully treated (T. Skinner) . . ix, 117
„ spontaneous salivation associated with (A. Farr) . xv, 222
„ scarlatina during, and in the puerperal state (R. Boxall) xxx, 11, 126, 167
„ frozen sections of a uterus at the tenth week of, showing hæmorrhages into the placenta, decidua reflexa, and decidua vera, from a patient who died of heart disease (G. F. Blacker) , ... xlii, 235
„ complicated with smallpox (R. Barnes) . . ix, 102
„ — (C. W. Milne) . . . . . ix, 110
„ spurious, simulating ectopic gestation (E. S. Stevenson) . xxxii, 216
„ tetany in (W. R. Dakin) . . . . xxxiii, 163
„ triplets at eighth month of (W. Martyn) . . . xi, 208
„ twin (J. Way) . . . . . vii, 209
„ — complicated by multiple fibro-myomata (John Phillips) . xxviii, 138
„ double uterus with simultaneous (H. Grace) . . iv, 138
„ with double uterus, and vagina (J. B. Hicks) . . xxiii, 23
„ complicated by tumour of the uterus (J. L. Worship) . xiv, 305
„ of a uterus bicornis (J. R. Ratcliffe) . . . xxxiv, 469
„ unsuspected, and awkward delivery (J. Shortt) . . iv, 202
„ necrobiotic uterus associated with recent (A. Doran and H. Williamson) . . . . . xlvi, 274
„ in a uterus, with fibroids; pan-hysterectomy during labour in the seventh month (J. Bland-Sutton) . . . xlvi, 238

PREGNANCY (*continued*)—
„ specimen preserved in formalin of an early, in both horns of the uterus of a bitch, displaying the allantoid vessels in their natural colour (Amand Routh) . . . xli, 5
„ early, excessive vomiting in, depending on the irritation of the gravid uterus (W. T. Smith) . . . . i, 335
„ vomiting of, its causes and treatment (W. G. Hewitt) . xiii, 103
„ — observations on the ætiology of (A. E. Giles) . . xxxv, 303
„ the uncontrollable vomiting of (Graily Hewitt) . xxvi, 273, 331
„ sickness of, observations on the ætiology of (A. E. Giles) . xxxv, 303
„ two fatal cases of pernicious vomiting in (J. L. Maxwell) . xliii, 288
„ full-term, in a rudimentary horn of uterus; missed labour (five months); abdominal section and removal of sac; recovery (J. H. Targett) . . . . xlii, 276
„ uterine and extra-uterine, progressing simultaneously to the full period of gestation (L. R. Cooke) . . . v, 143
„ EXTRA-UTERINE (C. Waller) . . . . i, 99
„ — (C. Drage) . . . . . ii, 254
„ — (W. Playfair) . . . . . vii, 1
„ — (E. B. Truman) . . . . . vii, 164
„ — (E. Malins) . . . . . xxxiv, 181
„ — (A. L. Galabin) . . . . xxxviii, 88
„ — (P. Horrocks) . . . . . xliv, 228
„ — rare form of (J. B. Hicks) . . . . vii, 95
„ — two cases of (D. C. MacCallum) . . . xv, 248
„ — — (Dr. Fulcher) . . . . . xxii, 153
„ — with operation (J. Scott) . . . . xv, 140
„ — cyst from (J. Scott) . . . . . xv, 124
„ — diagnosis of (L. Tait) . . . . xv, 135
„ — the treatment of (A. L. Galabin) . . . xxxi, 90
„ — two specimens of . . . . . xlvi, 88
„ — bilateral (H. R. Andrews) . . . . xlv, 461
„ — unusual (H. Williamson) . . . . xliv, 225
„ — two cases of which went to term (J. Bland-Sutton) . xliv, 316
„ — anomalous case, probably ovarian (E. O. Croft) . . xlii, 316
„ — associated with sloughing of the abdominal wall and attempted extrusion of a matured and putrid fœtus near the umbilicus (A. M. Shield) . . . . xxxiii, 148
„ — cast from the uterus having all the characters of the decidual membrane found in connection with, together with a small ovarian cyst from the same case, with microscopic sections of each (W. R. Dakin) . . xxxviii, 385
„ — decidual cast of the uterus from a case in which there was no evidence of (T. W. Eden) . . . . xxxix, 132
„ — in which the fœtus seems to have been developed to the full time in the peritoneal cavity, still retaining its amniotic covering (L. Tait) . . . . . xxxiv, 192
„ — ectopic, going nearly to term in the peritoneal cavity, the placenta being attached to the top of the uterus (G. E. Herman) . . . . . xxxix, 135
„ — note on the importance of a decidual cast as evidence of (W. S. A. Griffith) . . . . . xxxvi, 335
„ — at full term; removal of child and placenta by abdominal section; recovery (J. W. Taylor) . . . xxxiii, 115
„ — the sac being situated in the right broad ligament; pregnancy advanced to the early part of the fourth month (W. S. A. Griffith) . . . . . xxxiii, 126

PREGNANCY (*continued*)—
„ extra-uterine, on primary laparotomy in cases of (F. H. Champneys) . . . . . xxix, 456
„ — on delivery by the vagina in (G. E. Herman) . . xxix, 429
„ — double pyo-salpinx simulating; removal; recovery xxxvii, 291
„ — gastrotomy successfully performed (W. R. Jordan) . xv, 130
„ — — for (A. Meadows) . . . . xv, 145
„ — mode of dealing with placenta in gastrotomy for (R. Barnes) xiv, 325
„ — fœtus and placenta in (W. R. Jordan) . . . . xv, 124
„ — fœtus and placenta removed by laparotomy from a case of (W. Duncan) . . . . . xxxvi, 146
„ — gestation sac ruptured in the fifth month of (R. Boxall) . xlvii, 297
„ — placenta from a case of; the child at full term and removed five months after death (John Phillips) . . . xl, 3
„ — growth of the placenta after death of the fœtus in (Lawson Tait and C. Martin) . . . . . xxxiv, 206
„ — death of fœtus at the end of the eighth month, and operation a month later (A. E. Giles) . . . . xlvii, 114
„ — operation during the sixth month of pregnancy (H. J. Paterson) . . . . . xlvii, 326
„ — not primarily tubal (A. L. Galabin) . . xxxviii, 91
„ — partially macerated fœtus from, retained in the body about a year after its death (J. D. Malcolm) . . . xli, 222
„ — macerated bones of a fœtus from, retained seven years (J. D. Malcolm) . . . . . xli, 223
„ — death after operation from septicæmia; remarks on the significance of adhesions of the wall of the gestation sac to the dead fœtus (J. D. Malcolm) . . . . xlv, 421
„ — simulating a retro-flexed gravid uterus (J. M. Munro Kerr) xlii, 146
„ — in which fœtal death occurred at term after spurious labour and abdominal section was performed four to five months later (John Phillips) . . . . xlii, 121
„ — in which fœtal death occurred at the eighth month after spurious labour; abdominal section two months later (A. Doran) xlii, 213
„ — treated by abdominal section (J. B. Hicks) . . ix, 93
„ — abdominal, removal of living fœtus by abdominal section (T. R. Jessop) . . . . . xviii, 261
„ — — delivery of living child *per vaginam*; removal of placenta; recovery (J. H. Mathieson) . . . xxvi, 132
„ — — in which abdominal section was performed during the life of the fœtus at the thirty-fifth week of gestation (J. Williams) xxix, 482
„ — — case of, in which a communication existed between the cyst and the uterus (A. L. Galabin) . . xvii, 170, 384
„ — — fœtal bones from a case which had undergone spontaneous cure (W. O. Priestley) . . . . xxi, 24
„ — — about the seventh month, removal of fœtus by abdominal section (J. B. Hicks) . . . . xxii, 141
„ — — two cases of, with results (C. H. Carter) . . xxii, 160
„ — — fœtus and placenta from (G. E. Herman) . . xxviii, 141
„ — — — — from a case of (C. J. Cullingworth) . . xxxii, 135
„ — — — sac, and pelvic viscera from a case of, removed by abdominal section (A. Doran) . . . . xxix, 491
„ — — four months' fœtus from (A. Lawrence) . xxx, 122, 302
„ — — abdominal section eight months after death of fœtus (C. J. Cullingworth) . . . . . xxx, 480
„ — — gastrotomy for, in which the placenta never came away (J. Braithwaite) . . . . . xxviii, 33

PREGNANCY (*continued*)—
„ extra-uterine, abdominal, associated with intra-uterine, in which abdominal section was performed (A. L. Galabin) . xxiii, 141
„ — — simulating so-called missed labour (A. Rasch) . xxv, 113
„ — — parts illustrating (Heywood Smith) . . . xx, 5
„ — — removed by vaginal incision (C. Godson) . . xxix, 499
„ — — case of, in which the fœtal movements ceased at the end of the eighth month, and abdominal section was performed four weeks later (C. J. Cullingworth) . . xxxv, 155
„ — — spurious labour at term; fœtus and placenta removed six months later (E. J. Maclean) . . . . xlviii, 129
„ — — successfully treated by removal of child and placenta three months after death of child at term (J. W. Taylor) . xxxix, 178
„ — — in which fœtal death probably occurred at the end of the sixth month, and abdominal section was performed two and a half months later (John Phillips) . . . xxxv, 162
„ — — two cases of (E. S. Stevenson) . . . xxxv, 175
„ — — question of, in specimen of fœtus in peritoneal cavity (A. Doran) . . . . . xxxv, 222
„ — — and ovarian, summary of reported cases of primary (A. Doran) . . . . . xxxv, 222
„ — — secondary to partial rupture of tubal gestation sac; abdominal section fifteen months after conception and eight months after death of fœtus (J. B. Hellier) . . xlv, 366
„ — — (A. J. Sturmer) . . . . . xlvi, 381
„ — — section on each occasion (C. E. Purslow) . . xlvii, 185
„ — secondary abdominal; septic peritonitis; evacuation *per rectum*; recovery (H. A. Lediard) . . . xli, 276
„ — primary ovarian (A. W. Mayo Robson) . . . . xliv, 215
„ — probably ovarian, *report* of committee on E. O. Croft's specimen of an anomalous case of . . . xliii, 24
„ — ovarian (J. H. Davis) . . . . i, 241
„ — — (E. Child) . . . . xviii, 119
„ — — (J. Chalmers) . . . . xviii, 67, 82
„ — interstitial (R. Greenhalgh) . . . . v, 154
„ — — ruptured (H. R. Andrews) . . . . xlvii, 259
„ — intermural (J. B. Hicks) . . . . ix, 57
„ — intra-ligamentous, retained for twenty-one years (A. L. Galabin) . . . . . xxxviii, 38
„ — (intra-ligamentous), at the seventh month, in which the fœtus was extracted by vaginal incision (A. Donald) . xli, 7
„ — Fallopian (H. Grace) . . . . ii, 49
„ — the left ovary and the fimbriæ of left Fallopian tube formed the cyst, which had ruptured, discharging the eight months' fœtus into abdominal cavity (J. H. Davis) . . xii, 331
„ — *report* on H. Davis's specimen of . . . xii, 367
„ — tubal, with fibrous tumours of the uterus (G. Harley) . i, 101
„ — — (J. L. Worship) . . . . . xi, 211
„ — tubal, fœtus and placenta successfully removed in a case of (G. E. Herman) . . . . . xxx, 123
„ — — Fallopian tube and ovary from a case of (W. Duncan) . xxxi, 165
„ — — (J. S. Turner) . . . . . xvi, 30
„ — — (P. Boulton) . . . . . xxi, 117
„ — — (W. Burton) . . . . . xxiii, 34
„ — — (Clement Godson) . . . . xxiii, 109
„ — — (J. Matthews Duncan) . . . . xxiii, 263
„ — — (F. H. Daly) . . . . . xxiv, 155

PREGNANCY (*continued*)—
„ extra-uterine, tubal, (W. S. A. Griffith) . . . xxvii, 304
„ — — (Leonard Remfry) . . . xxxvii, 287
„ — — (J. Bland-Sutton) . . . xxxiii, 70; xl, 313
„ — — incomplete tubal abortion; hæmorrhage; operation; recovery (A. C. Butler-Smythe) . . . . xl, 298
„ — — (W. G. Hewitt) . . . . v, 154
„ — — ruptured at the sixth week (A. L. Galabin) . xxxviii, 39
„ — — of nine weeks' duration successfully removed three hours after rupture (W. Duncan) . . . . xxxvi, 66
„ — — of three months operated on before rupture (A. H. N. Lewers) . . . . xxxvii, 151
„ — — two unusual cases of: the one causing chronic intestinal obstruction, and accompanied by a hæmatosalpinx of the non-gravid tube; the other simulating retroversion of the gravid uterus (A. E. Giles and E. J. Maclean) . . xxxix, 232
„ — — case of, with notices of other cases (C. H. F. Routh) . xxi, 93
„ — — and the effects of chronic retro-uterine hæmorrhage (A. Doran) . . . . . xxi, 169
„ — — microscopical section of tube from (A. L. Galabin) . xxx, 195
„ — — (molar) complicated by suppurating ovarian cyst of the opposite side (John Phillips) . . . . xli, 384
„ — — with acute salpingitis (T. W. Eden) . . . xlviii, 272
„ — — sections showing muscular tissue in the pseudo-reflexa (H. R. Andrews) . . . . xlv, 335
„ — — in which the ovum continued to grow for about four weeks after rupture, the gestation sac becoming implanted on the omentum (C .Lockyer) . . . . xlv, 400
„ — ruptured tubal (W. Duncan) . . xxxvi, 114; xxxvii, 244
„ — — (W. A. Stott) . . . . xxxvi, 343
„ — — (W. S. Playfair) . . . . xxxviii, 34
„ — — (at fourth or fifth week); operation; recovery (Amand Routh) . . . . . xl, 220
„ — — with hæmatosalpinx of opposite side (A. H. N. Lewers) xxxix, 189
„ — — (J. H. Dauber) . . . . xliv, 321
„ — — and death about the fifth month (A. Meadows) . xviii, 258
„ — — Cæsarean section and total abdominal hysterectomy for fibroids complicating labour near term in a patient who had recovered without operation from (H. R. Spencer) . xlviii, 240
„ — — uterus and appendages showing (C. Godson) . xxii, 186, 242
„ — — fœtus from (A. H. N. Lewers) . . . xxviii, 207
„ — — fœtus, placenta, membranes, and Fallopian tube from a case of, complicated by a large hæmatosalpinx on the other side (C. J. Cullingworth) . . . . xxxii, 273
„ — — (Sidney Harvey) . . . xxx, 2, 166
„ — — (C. J. Cullingworth) . . . xxxiv, 134
„ — — (A. E. A. Lawrence) . . . xxxiv, 439
„ — — — four cases of ruptured, occurring in two women; removal by abdominal section; recovery (A. J. Sturmer) . xlv, 144
„ — which apparently ruptured twice (J. C. H. Leicester) . xlvii, 321
„ — ruptured, in an imperfect uterine horn (J. H. Targett) . xxxix, 46
„ — rupture of an early tubal (fifteenth day), complicated by fibro-myomata of the uterus (E. R. Dawson) . . xl, 155
„ — — removed by abdominal section (J. Knowsley Thornton) xxiv, 51, 81
„ — — — (Sydney Jones) . . . . xxvi, 268
„ — — abortion (J. Bland-Sutton) . . . xxxii, 342

PREGNANCY (*continued*)—
„ extra-uterine, rupture of an early tubal, rupture into broad ligament (J. Bland-Sutton) . . . . xxxiv, 217
„ — — removed before rupture (G. E. Herman) . . xxxii, 307
„ — — diagnosed before rupture, and a case of tubal abortion (J. Bland-Sutton) . . . . . xliv, 44
„ — unruptured tubal, with apoplexy of the ovum (C. J. Cullingworth) . . . . . xxxiv, 155, 182
„ — supposed unruptured tubal (W. S. Playfair) . xxxiv, 28, 465
„ — removal of unruptured tube; recovery (W. G. Nash) . xlvii, 408
„ — unruptured tubal (T. W. Eden) . . . xxxvi, 5
„ — — removed by abominal section (W. Duncan) . xxxvii, 197
„ — — (W. Duncan) . . . . xxxviii, 36
„ — — (M. A. D. Scharlieb) . . . . xlvi, 54
„ — sections showing muscular tissue in the pseudo-reflexa in (H. R. Andrews) . . . . . xlv, 333
„ — suspected early tubal, on both sides double hæmato-salpinx (A. Doran) . . . . . xxxiii, 112
„ — early tubal, with hæmatoma and hæmatocele (A. Doran) . xlvi, 206
„ — operation for, between the third and fourth months of gestation, with removal of a living fœtus and much trouble from hæmorrhage during convalescence (J. D. Malcolm) . xlv, 382
„ — repeated, in the same patient; laparotomy on each occasion (A. H. N. Lewers) . . . . xlii, 324; xlv, 418
„ — repeated tubal (A. Doran) . . . . xlvii, 235
„ — tubo-abdominal, at three months (F. G. Penrose). xxx, 124, 303
„ — — at the fourth month of pregnancy removed by abdominal section (G. F. Blacker). . . . . xlviii, 137
„ — — in which a living fœtus was extracted by cœliotomy after term, and the mother's life preserved (J. Bland-Sutton) . . . . . xl, 308
„ — tubo-ovarian (J. A. M. Moullin) . . . xxv, 103
„ — — (E. J. Maclean) . . . . . xxxv, 106
„ — interstitial or tubo-uterine, with notes on similar cases in the museums of London hospitals (A. Doran) . . xxiv, 227
„ — early ectopic (? tubo-uterine) complicated by fibro-myomata of the uterus (C. J. Cullingworth) . . xxxix, 284; xl, 285
„ — tubo-uterine; primary intra-peritoneal rupture; recovery (J. Bland-Sutton) . . . . . xxxvii, 296
„ — tubular, with twins (N. J. Haydon) . . . v, 75
„ — case of spurious pregnancy simulating (E. S. Stevenson) . xxxii, 216
„ — supposed, with birth through uterus (E. F. Grün) xxvii, 226, 306
„ — followed by intra-uterine (E. E. Day) . . . vi, 3
„ — in which two fœtuses were found in connection with the same tube (N. J. Haydon) . . . . v, 280
„ — rupture of the cyst and death . . . . xi, 7
„ — terminating in sudden death (W. Martyn) . . xi, 57
„ — *report* on . . . . . xi, 62
„ — treatment of some forms of (A. Meadows) . . xiv, 309
„ — with remarks on its treatment (A. Meadows) . . xiii, 268

PREGNANT HORN from the uterus of a cat (Robert Wise) . xxxix, 260

PRESENTATIONS, breech, blunt hook and sling for assisting delivery in cases of (J. G. Swayne) . . . xvii, 313
„ breech, the forceps in . . . . . xix, 217
„ — with extended legs (W. S. A. Griffith and Arnold W. W. Lea) . . . . . xxxix, 13

PRESENTATION, face (R. Barnes) . . . . v, 173
„ — delivery by forceps; subsequent sloughing and separation of the mucous lining of the bladder and expulsion of the same (W. Martyn) . . . . . v, 186
„ — in the mento-posterior position (J. B. Hicks) . . vii, 57
„ — in which delivery was effected by the cephalotribe (J. B. Hicks) . . . . . x, 144
„ — mento-anterior, cast of the head of a child born under, showing distortions of face and cranium (G. Roper) . xx, 124
„ delivery by the forceps in face, in the mento-lateral position (J. B. Hicks) . . . . . xv, 39
„ natural and placental, in a case of twins (J. Brunton) . xii, 167
„ of the right arm and shoulder; delivery by the natural powers, or spontaneous evolution (R. Hodges) . . . iv, 140
„ of right breast, followed by prolapsus of the cord and right arm; delivery by version (J. Brunton) . . . x, 145
„ of right shoulder and arm; spontaneous evolution (C. Mayo) . iii, 105
„ funis (H. G. Trend) . . . . . x, 1
„ head-last, on traction by the lower jaw in (J. Matthews Duncan) . . . . . xx, 61
„ of the upper extremity, on the choice of leg which shall be seized in version for (A. L. Galabin) . . . xix, 239

PRESSURE of the femora, and its influence on the shape of the pelvis (F. H. Champneys) . . . . xxv, 70

PREVÔT (OSCAR), thermo-cautery, invented by Paquelin . xviii, 180

PRIESTLEY (W. O.), curious intra-uterine injury on the head of a new-born child . . . . . i, 60
„ labour complicated with a fibrous tumour of the uterus; delivery by long forceps, and subsequent removal of tumour i, 217
„ sloughing of the fœtal scalp as the result of tedious labour . i, 323
„ treatment of cases of abortion in which the placenta and membranes are retained . . . . . iii, 146
„ medicated pessaries . . . . . vii, 208
„ inaugural address as President . . . . xvii, 36
„ annual address as President . . . xviii, 29; xix, 17
„ summary of discussion on puerperal fever (vol xvii) . . xviii, 29
„ bones from an extra-uterine fœtation which had undergone spontaneous cure . . . . . xxi, 24
„ on the induction of abortion as a therapeutic measure . xxii, 271
„ chronic papillary inflammation of the vulva . . xxvi, 156
„ notes of a visit to some of the lying-in hospitals in the North of Europe; and particularly on the advantages of the antiseptic system in obstetric practice . . . xxvii, 197
„ election as Honorary Fellow . . . . xlii, 40
„ letter acknowledging election as Honorary Fellow . . xlii, 131

PRITCHARD (W. E.), abortion procured by tents of common seatangle . . . . . v, 198

PROBYN-WILLIAMS (R. J.), malformed heart . . . xxxvi, 3
„ hydrocephalus with spina bifida . . . . xxxvi, 4
„ abscess in abdominal wall . . . . xxxvi, 62
„ and LENNARD CUTLER, some observations on the temperature, pulse, and respiration during labour and the lying-in xxxvii, 19
„ adjourned discussion . . . . xxxvii, 152
„ see *A. E. Giles.*

PROCIDENTIA UTERI, see *Prolapsus uteri.*

PROLAPSUS of the female genital organs (M. Konrád) . . xiii, 251
„ of the cord and right arm following presentation of the right breast; delivery by version (J. Brunton) . . . x, 145
„ of the funis during labour (G. Roper) . . . xvii, 318
„ of ovaries, adherent (W. S. A. Griffith) . . . xxvi, 270
„ ovarian, treated by shortening the ovarian ligament (V. Bonney) . . . . . xlviii, 339
„ of the pelvic floor and uterus, the changes which accompany the slighter degrees of (G. E. Herman) . . xxxi, 276
„ of Meckel's diverticulum in an infant, forming an umbilical tumour (S. W. Wheaton) . . . . xxxiv, 184
„ of the vagina, the relation of, to hernia (G. E. Herman) . xxvi, 88

PROLAPSUS UTERI (J. M. Sims) . . . vii, 213, 238
„ cases of (A. Cordes) . . . . . xvii, 63
„ complete, caused by fibroid tumour springing from the posterior lip of uterus (R. Barnes) . . . . iii, 211
„ congenital and imperforate rectum (H. R. Andrews) . xlii, 169
„ congenital, of uterus associated with spina bifida (H. R. Andrews) . . . . . xliv, 137
„ complete, of an inverted uterus (H. R. Andrews) . . xlviii, 284
„ and inversion of vagina, with hypertrophic elongation of cervix (R. Barnes) . . . . . xv, 124
„ in which the neck of the uterus was partially severed by a ligature of hair (N. Coates) . . . . xv, 9
„ extirpation of uterus for (E. Malins) . . . xxvi, 148
„ pessary for (R. Barnes) . . . . . xix, 119
„ (A. L. Galabin) . . . . . xx, 169
„ new treatment in (J. H. Aveling) . . . xi, 215
„ vesical calculi from a case of (A. Lawrence) . . xxx, 227
„ ending fatally by dilatation of the ureters and wasting of the kidneys (J. J. Phillips) . . . . xii, 276
„ vesical calculi, the sequel of (A. L. Galabin) . . xxii, 106

PROPAGATION, power and act of, in females of the industrial classes in the metropolis; derived from eleven years' experience of two lying-in institutions (A. B. Granville) . . ii, 139

PROPERT (Mr.), fibro-sarcoma of the right ovary . . xii, 1

PROPERTY of the Society, alteration of laws respecting the . xxxii, 106

PROTRUDER, rectal (J. H. Aveling) . . . xviii, 83

PROVIS (F. LIONEL), see *Eden, T. W.*

PSEUDO-HERMAPHRODITISM, pelvic viscera showing (C. H. Roberts) . . . . . xliii, 298

PUDENDUM, inflammations of lupus of the (J. Matthews Duncan) xxvii, 310

PUERPERAL CONVULSIONS; illustrated by cases (J. H. Davis) . xi, 268

PUERPERAL DIABETES (J. Matthews Duncan) . . xxiv, 256

PUERPERAL DISEASES, short report of eighty-nine cases, with remarks (J. B. Hicks) . . . . . xii, 44
„ (J. B. Hicks) adjourned discussion on . . . xii, 123
„ further contribution to the clinical knowledge of (J. B. Hicks) . . . . . xxxv, 412

PUERPERAL ECLAMPSIA, cases of, especially illustrating the temperature and urine in this disease (G. E. Herman) . . xxxii, 17

PUERPERAL ECLAMPSIA (*continued*)—
„ five more cases of, especially illustrating the temperature and urine in this disease (G. E. Herman) . . . xxxiii, 315
„ with autopsy and remarks (R. H. Bell) . . . xliv, 253
„ see *Eclampsia.*

PUERPERAL FEVER (W. T. Fox) . . . . iii, 368
„ (T. Snow Beck) . . . . vii, 31
„ discussion on the relation of, to the infective diseases and pyæmia . . . . xvii, 90, 131, 178, 217
„ summary of discussion (W. O. Priestley) . . . xviii, 32
„ and septic poisoning, inaugural address (J. Watt Black) . xxxiii, 76
„ complicated with diphtheria, in which life was saved by the sesquichloride of iron (R. Druitt) . . . iii, 30
„ or puerperal pyæmia, after an abortion (T. S. Beck) . . ix, 275
„ in the British Lying-in Hospital; with remarks on the treatment of (W. G. Hewitt) . . . . x, 69
„ treated by the injection of ammonia into the veins followed by recovery (W. T. Smith) . . . . xi, 247
„ in England and Wales, undiminished mortality from, inaugural address (C. J. Cullingworth) . . . . xxxix, 91
„ uterus of patient after (R. Barnes) . . . ix, 241
„ see also *Fever.*

PUERPERAL HÆMORRHAGE, secondary (C. S. Redmond) . xix, 258

PUERPERAL HYPERPYREXIA, bed for cases of, requiring continuous application of cold (W. S. Playfair) . . xx, 171

PUERPERAL INSANITY, cases of, in the Montreal University Lying-in Hospital (D. C. McCallum) . . . xx, 46
„ (Robert Jones) . . . . xlv, 2
„ bromide of potassium in (J. B. Curgenven) . . ix, 155

PUERPERAL PERITONITIS (J. T. Mitchell) . . . iv, 96
„ complicated with ovarian disease, followed by febrile diseases of the puerperal state, the probable consequences of infection (R. U. West) . . . . . i, 187

PUERPERAL SEPTICÆMIA, case of (H. Gervis) . . xviii, 160
„ with abscesses, phlegmasia dolens, etc. (A. Wiltshire) . xviii, 181
„ the clinical relation of scarlatina to (R. Boxall) . . xxx, 126
„ uterus, heart, and brain from a case of (W. Duncan) . xxxi, 202

PUERPERAL TEMPERATURES, some observations on (E. S. Tait) xxvi, 8

PUERPERAL THROMBOSIS (W. S. Playfair) . . xvi, 42, 89

PUERPERIUM, abscess of uterus developing during; rupture into the peritoneal cavity; abdominal section; recovery (A. W. W. Lea). . . . . xlvi, 7
„ sudden apoplectiform seizure, terminating fatally in thirty-five hours, on the sixth day of the (R. U. West) . . ii, 276
„ the change in size of the chest and abdomen during, and the effect of the binder upon them (G. E. Herman) . . xxxii, 108
„ epileptiform convulsions in the third week of (R. U. West) . iii, 35
„ fatal influence of grief during (G. D. Gibb) . . i, 75
„ febrile diseases of, following puerperal peritonitis complicated with ovarian disease (R. U. West) . . . i, 187
„ fever during the. Part II.—The relation of internal meteorological conditions to the incidence of febrile illness in childbed (R. Boxall) . . . . . xxxv, 340

PUERPERIUM (*continued*)—
„ vaginal hysterectomy in, for sepsis due to suppuration of myoma (A. W. W. Lea) . . . . xlvii, 1
„ destructive inflammation of hip-joint in (T. W. Nunn) . vi, 116
„ lymphangitis mammæ: an affection of the breast arising about the tenth day of (R. H. Vincent) . . . xliv, 158
„ the conditions which favour mercurialism during the, with suggestions for its prevention (R. Boxall). . . xxx, 304
„ mortality in, both in hospital and in general practice (R. Boxall) . . . . . xlvii, 196
„ the value of pilocarpine during the (John Phillips) . . xxx, 354
„ acute non-septic pulmonary disorders as complications of (John Phillips) . . . . xxxi, 171
„ scarlatina during pregnancy and in the (R. Boxall) xxx, 11, 126, 167
„ effect of the scarlatinal poison on the (R. Boxall) . . xxx, 70
„ the occurrence of sugar in the urine during the (F. J. McCann and W. A. Turner) . . . . . xxxiv, 473
„ the indications afforded by the sphygmograph during the (F. Barnes) . . . . . xvi, 263
„ observations on the temperature, pulse, and respiration during labour (R. J. Probyn-Williams and L. Cutler) . xxxvii, 19, 152
„ absorption of thrombosis of the pulmonary artery during the (W. S. Playfair) . . . . . xxvi, 162
„ sections of uterus at different periods of the, showing complete absence of the alleged fatty changes (W. S. A. Griffith) . xxxi, 308
„ variation in height of the fundus uteri above the symphysis during, the conditions which influence this, and the practical conclusions which may be drawn from such observations (T. G. Stevens and W. S. A. Griffith) . . xxxvii, 245
„ see also *Childbed*.

PULMONARY ARTERY, absorption of thrombosis of, in the puerperal state (W. S. Playfair) . . . . xxvi, 162
„ fatal embolism of the right heart and, nineteen days after delivery (G. Roper) . . . . . xxi, 74

PULMONARY DISORDERS, acute, non-septic, as complications of the puerperium (John Phillips) . . . . xxxi, 171

PULSE and respiration during labour and the lying-in, some observations on the temperature and (R. J. Probyn-Williams and L. Cutler) . . . . xxxvii, 19, 152
„ and temperature in relation to menstruation, observations on the variations in (A. E. Giles) . . . . xxxix, 115

Purcell (F. A.), vaginal hysterectomy for malignant disease . xxvii, 5

PURPURA HÆMORRHAGICA, influence of, upon menstruation and pregnancy (John Phillips) . . . xxxiii, 2, 390

PURSE-STRING SUTURE, its use in complete rupture of the perineum (P. Boulton) . . . . . xxxii, 380

Purslow (C. E.), fœtus enclosed in amniotic sac only . . xli, 168
„ cyst of the broad ligament . . . . xli, 169
„ cystic tumour of uterus . . . . . xlvi, 269
„ tubal mole . . . . . xlvi, 271
„ repeated tubal pregnancy, abdominal section on each occasion xlvii, 181

PUS, offensive, in sarcoma of ovary showing necrosis of central portion lying in an abscess cavity (W. W. H. Tate) . xli, 373

PYÆMIA in a case of cancer of the cervix uteri complicating pregnancy (A. L. Galabin) . . . . xxiii, 186
„ causing death in an early pregnancy, attended by fibrous tumour of the uterus (J. H. Davis) . . . viii, 11
„ death of mother from, after parturition, in a case of epithelioma of the cervix (A. W. Edis) . . . xvii, 344
„ discussion on the relation of puerperal fever to the infective diseases and . . . xvii, 90, 131, 178, 217; xviii, 32
„ puerperal, or puerperal fever, after an abortion (T. S. Beck) . ix, 275
„ produced by phlebitis of the umbilical vein, two cases of death in new-born infants from (G. Roper) . . . xix, 8
„ with extensive purulent deposits in a new-born infant (A. W. Edis) . . . . . xix, 12

PYELONEPHRITIS of pregnancy (W. A. Milligan) . . xlviii, 1

PYOMETRA (W. S. A. Griffith) . . . . xxix, 398
„ two specimens of (J. Matthews Duncan) . . . xxi, 54
„ microscopic sections of uterine wall from a case of (A. L. Galabin) . . . . . xxii, 239
„ cancerous uterus with (A. H. N. Lewers) . . xxxviii, 14
„ complicating cancer of the cervix uteri (W. W. H. Tate) . xxxix, 323

PYOSALPINX, cases of (Lawson Tait) . . xxv, 111, 138, 234
„ — (J. Knowsley Thornton) . . . xxv, 139
„ ovaries and tubes from a case of (E. Malins) . . xxvi, 228
„ removal of the uterine appendages for (Lawson Tait) . xxiv, 157
„ double (E. Malins) . . . . . xxvii, 137
„ — (C. H. Carter) . . . . xxxii, 64
„ — with rupture of the tubes (A. H. N. Lewers) . . xxvii, 298
„ — associated with fibro-myoma of uterus (W. S. Playfair) . xxxiii, 497
„ — (A. C. Butler-Smythe) . . . . xxxiv, 24
„ — (W. Duncan) . . . xxxvii, 245; xxxix, 89
„ — simulating extra-uterine pregnancy; removal; recovery (W. Duncan) . . . . xxxvii, 291
„ — in which the tubal sacs communicated (J. D. Malcolm) xlii, 10
„ — in which the tubes were enormously distended (C. H. Roberts) . . . . . xl, 121
„ — tuberculous, with inter-communication of the tubes (A. L. Galabin) . . . . . xlii, 173
„ — with enlarged bladder and secondary renal complication (H. Macnaughton-Jones) . . . . xxxix, 319
„ — tuberculous (J. H. Targett) . . . . xli, 341
„ with tubo-ovarian cysts (W. C. Grigg) . . . xxxiii, 75
„ two cases of double tuberculous (J. H. Targett) . . xli, 163
„ unsuspected tuberculous salpingitis and (J. H. Targett) . xlvi, 20
„ a series of seven cases of (C. J. Cullingworth) . xxxiii, 447
„ two cases of (C. J. Cullingworth) . . . xxxiv, 219
„ complicating pregnancy (W. C. Grigg) . . . xxxiii, 75
„ simulating tubo-ovarian abscess (C. J. Cullingworth) xxxiv, 437; xxxvii, 2
„ with multiple abscesses of the ovary (C. J. Cullingworth) . xxxix, 47
„ with twisted pedicle (A. H. N. Lewers) . . . xliv, 362
„ and hæmatosalpinx (W. Duncan) . . . xxxi, 332
„ see *Uterine appendages.*

QUEEN VICTORIA, loyal address submitted to the King on the death of . . . . . xliii, 21
„ — reply . . . . . xliii, 143

RABBIT, five fœtal sacs from the peritoneal cavity of (M. S. Pembrey) . . . . . xl, 253
„ sacs containing fœtuses and lying free in the peritoneal cavity of (M. S. Pembrey and G. Bellingham Smith) . . xlvi, 283

RADIOGRAPH of fœtus *in utero* (Heywood Smith) . . xlviii, 44

RADFORD (THOMAS), laceration of the uterus, with remarks . viii, 150

RASCH (ADOLPH), simple instrument for vaginal injections . vi, 224
„ œdema of the lower half of the body, after a fall in the seventh month of pregnancy in premature labour; recovery . vii, 80
„ vaginal drainer . . . . . x, 94
„ fœtus and placenta; funis obliterated by twisting . . x, 94
„ air in the vagina . . . . . xii, 281
„ novel way of using the uterine sound in flexions of the uterus xiii, 247
„ case of extra-uterine gestation simulating so-called missed labour . . . . . xxv, 113
„ gangrene of the bladder from retroversion of the gravid uterus xxxi, 129
„ case of large chylous cyst of the mesentery . . xxxi, 311
„ ovaries removed from a case of osteomalacia . . xxxiv, 462
„ osteomalacia cured by excision of the ovaries . . xxxv, 39

RATCLIFFE (J. R.), pregnant uterus bicornis . . . xxxiv, 469

RAYNES (H.), difficult labour from locked heads . . iv, 19

RECTUM, adhesions between the uterus and, dragging down the fundus uteri (E. E. Day) . . . . vi, 10
„ cancer of ovary extending to (J. W. J. Oswald) . . xviii, 122
„ cancerous disease of, in a patient in whom abortion was induced (F. W. Mackenzie) . . . . i, 11
„ and the genito-urinary tract, pelvic viscera showing congenital communication between (A. Doran) . . . xxii, 79
„ imperforate; attempt at relief by operation; death (W. T. Fox) iv, 195
„ — two cases of (P. Horrocks) . . . . xxvii, 135
„ — imperforate, and congenital prolapse of the uterus (H. R. Andrews) . . . . . xlii, 169
„ instrument for protruding the, by pressure on the posterior wall of the vagina (J. H. Aveling) . . . xviii, 83
„ malformation of (A. E. Giles) . . . . xxxiv, 129
„ malignant growth in the, complicating pregnancy (J. B. Potter) . . . . . xx, 110
„ tumour protruded from, during labour (R. Barnes) . . xxi, 28
„ uterus, and left kidney from a woman who died of uræmia (W. Duncan) . . . . . xxxi, 255

REDMOND (C. STENNETT), secondary puerperal hæmorrhage . xix, 258

REFEREES, alteration of the laws respecting the . . xxvii, 59

REGISTER, obstetrical (D. Mackinder) . . . ix, 268

REGULATOR, Leiter's temperature (C. Godson) . . xxiii, 131
„ to be used with Paquelin's cautery (J. H. Aveling) . . xx, 293

RELATIONS of organic affections of the heart to fibro-myoma of the uterus (T. Wilson) . . . . xlii, 176

REMFRY (L.), blighted embryo . . . . xxxv, 153
„ two cirrhotic and cystic ovaries, with microscopical section of same . . . . . xxxvi, 184
„ ligature and division of the upper part of both broad ligaments, and the result as compared with that following removal of the uterine appendages . . . . xxxvi, 202

REMFRY (L.) (*continued*)—
„ remarks on fœtal retroflexion; report of a specimen showing origin of gluteus maximus from occipital bone . . xxxvi, 227
„ incomplete tubal abortion . . . . xxxvi, 261
„ gestation in a rudimentary horn . . . . xxxvi, 263
„ case of absence of uterus and breasts . . . xxxvii, 12
„ list of ovariotomies in women over 80. A case, aged 83, complicated by epithelioma of the vulva . . xxxvii, 155
„ tubal gestation . . . . xxxvii, 287
„ effects of lactation on menstruation and impregnation xxxviii, 22
„ microscopical sections of uterus showing chorionic villi and doubtful sarcoma . . . . xxxviii, 223
„ hydrocele of the canal of Nück containing a portion of the left Fallopian tube . . . . . xl, 6
„ death of . . . . . xl, 174

RENAL FUNCTION, see *Kidneys*.

REPORT of the University Lying-in Hospital, Montreal (D. C. McCallum) . . . . . xx, 35

REPORTS OF COMMITTEES, see *Committees*, reports of.

REPOSITOR for inversion of the uterus (J. H. Aveling) . . xx, 126

REPOSITORS, failure of elastic pressure with, in a case of complete inversion of uterus of seven months' duration; operation of anterior vaginal cœliotomy, anterior hysterotomy, and replacement; recovery (J. W. Taylor) . . . xliv, 299

RESPIRATION during labour and the lying-in, some observations on the temperature, pulse and (R. J. Probyn-Williams and L. Cutler) . . . . . xxxvii, 19, 152

RETENTION OF MEMBRANES, some causes of (F. H. Champneys) xxix, 337

RETINITIS, see *Choroido-retinitis*.

RETRACTION of the uterus (J. Matthews Duncan) . . xxviii, 115
„ tonic uterine contraction without completeness of (J. Matthews Duncan) . . . . . xxix, 369
„ of uterus, a case showing (*a*) uterine contraction without, and (*b*) prolonged high temperature of nervous origin (G. E. Herman) . . . . . xlviii, 204

RETRACTORS, self-retaining glass (H. Macnaughton-Jones) xxxviii, 345

RETROFLEXION of an early human embryo, with absence of the spinal medulla and imperfection of the vertebral column (C. B. Lockwood) . . . . . xxix, 234
„ of the fœtus during pregnancy (J. Matthews Duncan and J. B. Hurry) . . . . . xxvi, 206
„ — and ectopia viscerum (W. R. Dakin) . xxxi, 308; xxxii, 200
„ — — (Amand Routh) . . . . . xxxv, 102
„ — at seven months, illustrating celosoma with (Leith Napier) xxxvi, 116
„ fœtal, report of a specimen showing origin of gluteus maximus from occipital bone (L. Remfry) . . . xxxvi, 227
„ of the gravid uterus during labour at term (H. Oldham) . i, 317
„ of uterus as a frequent cause of abortion (J. J. Phillips) . xiv, 45
„ — in a new-born child (H. R. Spencer) . . xxxiv, 25

RETROVERSION OF UTERUS, see *Uterus*, displacements of (retroversion).

REVOLUTIONS, fœtal (J. Matthews Duncan) . . . xxvi, 171

RICHARDS (D.), spina bifida, followed by hydrocephalus . iv, 191
RICHARDSON (BENJAMIN), remarks in the discussion on puerperal fever . . . . . xvii, 122
RICHARDSON (J. C.), double placenta, with remarks by G. Hewitt viii, 337
RICKETS, influence of the mother's health in the production of (W. T. FOX) . . . . . iv, 260
„ oblique rhachitic pelvis (W. S. A. Griffith). . . xxv, 232
RIGBY (EDWARD), address at first meeting of the Society . i, 1
„ address as President . . . . i, 1; ii, 1
„ cranial blood swelling; with remarks on the nature of these tumours . . . . . i, 231
„ address at first anniversary meeting of the Society, January 4th, 1859 . . . . . ii, 1
RIGDEN (GEORGE), statistics of midwifery in private practice . xxiii, 151
RIGDEN (W.), age at which menstruation commences . . xi, 243
RITCHIE (C. J.), cephalotripsy as performed at Vienna by Professor Braun . . . . . vi, 75
„ dermoid cyst in Fallopian tube . . . . vii, 254
RITCHIE (JAMES), embryoma of anterior mediastinum in a male adult . . . . . xlv, 250
ROBERTS (C. H.), curious congenital deformity . . xxxvi, 341
„ on the common form of "white leg" after confinement xxxvii, 163
„ notes of a case of primary epithelioma of vagina . xxxviii, 381
„ fibroma of the ovary undergoing calcareous degeneration . xxxix, 8
„ a case of double pyosalpinx, in which the tubes were enormously distended . . . . . xl, 121
„ a case of primary carcinoma of the Fallopian tube . . xl, 189
„ second case of primary carcinoma of the Fallopian tube . xli, 129
„ notes of a case of a large retro-peritoneal fibroid undergoing suppuration . . . . . xli, 213
„ myxoma of chorion not discharged till the seventh month . xlii, 168
„ cystic fibro-myoma of the cervix uteri . . . xlii, 211
„ cancer of the cervix associated with an adenomatous growth in the fundus. . . . . xlii, 267
„ pelvic viscera showing pseudo-hermaphroditism . . xliii, 298
„ adenoma malignum of the body of the uterus . . xlv, 86
„ microscopical sections of a case of tuberculosis of the ovary and Fallopian tube . . . . . xlv, 92
„ cornual pregnancy at full term removed six months after the death of the child . . . . . xlviii, 309
„ curious case of cancer of the uterus . . . xlviii, 311
„ supposed recurrence after vaginal hysterectomy for cancer of the cervix . . . . . xlix, 114
ROBERTS (D. LLOYD), report of a case of Cæsarean section, with remarks . . . . . ix, 250
„ two cases of monstrosity . . . . . x, 269
„ fibroid polypus attached to the fundus uteri removed by écraseur; recovery . . . . . xi, 244
„ spina bifida . . . . . xi, 313
„ two cases of spina bifida and one of extroversion of bladder . xii, 361
„ notes of cases of submucous fibroid of the uterus, etc. . xiii, 309
„ drawing of bicorned uterus with double vagina . . xiii, 312
ROBINSON (A. H.), see *Cullingworth, C. J.*

ROBINSON (G. D.), on certain micro-organisms of obstetrical and gynæcological interest . . . . xxxvii, 263
„ cystic ovaries . . . . . xxxix, 130
„ vulval discharges in children . . . . xli, 14
ROBSON (A. W. MAYO), primary ovarian gestation . . xliv, 215
ROGERS (J. F.), double monstrosity . . . . xi, 128
ROGERS (W. R.), polypoid tumours of uterus . . . x, 94
„ unusual and interesting appearance of an ovum thrown off at the second month . . . . . xi, 80
„ elephantine development of the clitoris . . . xi, 84
„ vagina and uterus divided by septum . . . xii, 297
„ hæmatocele of doubtful origin . . . . xvi, 177
„ — *report* on ditto by committee (Heywood Smith and W. R. Rogers) . . . . . xvi, 274
„ case of chronic complete inversion of the uterus, successfully treated by sustained elastic pressure . . . xxiii, 19
ROPER (G.), labour in primiparous women late in the reproductive period of life . . . . . vii, 51
„ difficult case of labour connected with a non-evoluted and hypertrophied state of the cervix uteri . . . vii, 233
„ remarkable case of placenta prævia . . . viii, 340
„ hypertrophic elongation of the cervix uteri at the full term of pregnancy . . . . . xv, 167
„ on prolapse of the funis during labour . . . xvii, 318
„ deformed fœtus . . . . . xviii, 295
„ reports of two cases of death in new-born infants from pyæmia, produced by phlebitis of the umbilical vein . . xix, 8
„ new craniotomy forceps . . . . . xix, 136
„ alteration of Hicks' cephalotribe . . . . xix, 137
„ a difficult case of labour in a primiparous woman, who, having been barren for thirteen years, became pregnant after bilateral division of a deformed cervix uteri . . . xix, 169
„ fibrous tumour of the uterus in a state of calcareous degeneration . . . . . xix, 255
„ placental tumour from a primipara . . . xix, 256
„ extensively ruptured uterus . . . . xx, 2
„ small intestine taken from an infant . . . xx, 35
„ case of protracted labour, in which the use of the forceps was typically indicated; child still-born . . . xx, 75
„ cast of the head of a child born under face presentation, showing distortion of face and cranium . . . xx, 124
„ some clinical remarks on a certain class of cases of anteflexion of the uterus, with certain correlated conditions . xx, 304, 324
„ report of a case of fatal embolism of the right heart and pulmonary artery nineteen days after delivery, with a few clinical remarks . . . . . xxi, 74
„ remarks in the discussion on the use of forceps . . xxi, 201
„ supplementary placenta, the size of the palm of the hand . xxii, 45
„ cast of fœtal head showing furrowing due to pressure against the sacrum . . . . . xxii, 84
„ malignant disease of the cervix uteri . . . xxii, 85
„ specimen of missed abortion . . . . xxii, 108
„ *report* on A. L. Galabin's case of occluded cervical canal with retention of pus in the uterine cavity . . . xix, 177
„ note on some difficult cases of fronto-anterior positions of the fœtal head . . . . . xl, 271

Rose (H. Cooper), new description of nipple-shield and treatment of sore nipples . . . . . iv, 135
„ disease of both ovaries, the right ovary forming a communication with the cæcum and externally the left tumour emptying itself into the rectum; death, and *post-mortem* results . ix, 44
„ child with malformed genital organs . . xv, 85, 125
„ contribution to the statistics of midwifery in general practice xviii, 146
„ case of extreme hypospadias in a child who had been baptised, brought up, and educated at a large girls' school as a female xviii, 256

Ross (W.), curious monster which lived for some time after birth ix, 31

ROTATION, axial, of ovarian tumours, leading to strangulation and gangrene (Lawson Tait) . . . . xxii, 86
„ — of a right-sided parovarian cyst (Leith Napier) . . xxxiv, 124
„ chronic axial, of an ovarian cyst giving rise to extreme twisting of the elongated uterus (T. Wilson) . . . xxxix, 167
„ acute axial, of parovarian cyst (A. W. W. Lea) . . xxxix, 8
„ — of a calcified fibroid of the uterus (J. Bland-Sutton) . xlvi, 149
„ of uterine tumours (W. A. Meredith) . . . xxx, 80
„ and impaction of a myomatous uterus (J. Bland-Sutton) . xli, 296

ROTATORY ACTION in the use of the forceps (W. Stephenson) . xxii, 217

Rouse (John), recovery of a still-born child; unusual marking of the skin, simulating the effects of injury . . . . vii, 45

Roussel (J.), on the transfusion of blood . . . xviii, 280

Routh (Amand), urethral calculus . . . . xxvii, 3
„ case of serous perimetritis . . . . xxviii, 131
„ fibroid of one-horned uterus . . . . xxix, 2
„ — *report* on, ditto by committee (Alban Doran, W. S. A. Griffith, and Amand Routh) . . . . xxix, 57
„ primary cancer of the Fallopian tube; recurrence . . xxxi, 200
„ urethral diverticula . . . . . xxxii, 69
„ apoplectic ovum . . . . . xxxii, 194
„ case of acephalous acardiac twin . . . . xxxii, 347
„ — *report* on, by committee (J. Bland-Sutton, Amand Routh, and Alban Doran) . . . . . xxxiii, 26
„ cancerous uterus removed by vaginal hysterectomy . . xxxiv, 87
„ ruptured uterus and vagina . . . . xxxiv, 252
„ malformed fœtus . . . . . xxxiv, 463
„ fœtus with hernia umbilicalis congenita and spina bifida lumbo-sacralis ('Transactions,' vol. xxxiv, p. 463 . . xxxv, 102
„ anencephalic fœtus . . . . . xxxv, 241
„ — *report* of committee . . . . . xxxv, 294
„ phosphatic calculus and bodkin nucleus . . . xxxv, 240
„ fibroma spontaneously enucleated . xxxv, 409; xxxvi, 2
„ on cases of associated parovarian and vaginal cysts, formed from a distended Gärtner's duct . . . . xxxvi, 152
„ cancerous uterus and parovarian cyst removed *per vaginam* xxxvii, 8
„ anencephalic di-prosopia fœtus . . . . xxxvii, 162
„ skull of an anencephalic fœtus . . . . xxxvii, 219
„ fibroid tumour and cancer of the uterus . . . xxxviii, 99
„ independent cancer of the body and of the cervix uteri xxxviii, 100
„ hydrosalpinx and small ovarian cyst removed by anterior colpotomy . . . . . xxxviii, 185
„ entirely detached uterine fibroid . . . . xxxviii, 388
„ malignant papilloma of uterus . . . . . xxxix, 5

ROUTH (AMAND) (*continued*)—
„ parturition during paraplegia, with cases . . . xxxix, 191
„ incarcerated ovarian (dermoid) cyst, removed during pregnancy *per vaginam* . . . . . xl, 217
„ ruptured tubal gestation (at fourth or fifth week); operation; recovery . . . . . xl, 220
„ uterine appendages showing a hæmatosalpinx . . xl, 306
„ specimen preserved in formalin of an early gestation in both horns of the uterus of a bitch, displaying the allantoid vessels in their natural colour . . . . xli, 5
„ myxo-sarcoma of the uterus removed by pan-hysterectomy . xli, 139
„ supposed myxo-sarcoma of the uterus removed by abdomino-vaginal method . . . . . xli, 367
„ fœtus thoracopagus . . . . . xlii, 29
„ Porro-Cæsarean hysterectomy with retro-peritoneal treatment of the stump in a case of fibroids obstructing labour; with remarks upon the relative advantages of the modern Porro operation over the Sänger-Cæsarean in most other cases requiring abdominal section . . . . xlii, 244
„ tubal abortion with rupture of tube . . . xliii, 294
„ dermoid cyst of ovary removed by posterior colpotomy . xliv, 38
„ uterus removed at eight and a half months of gestation by abdominal hysterectomy for fibroid obstructing labour . xliv, 41
„ Fallopian tube ruptured towards its fimbriated end in two places . . . . . xliv, 131
„ fibroma of the ovary . . . . . xlviii, 133
„ fibroid of uterus with a sarcomatous nodule in the centre . xlix, 1
„ pelvic organs of a case where inoperable papilloma of the left ovary had been found seven years previously . . xlix, 216
ROUTH (C. H. F.), menorrhagia treated by injection, or the removal of the uterine mucous membrane by the gouge, or both means combined . . . . . ii, 117
„ hydatidiform degeneration of the ovum . . . ii, 242
„ fibro-cystic disease of uterus . . . . vii, 253
„ — of the uterus mistaken for ovarian disease; attempted extirpation; failure; death by rupture of a vessel within the cyst viii, 122
„ new mode of treating epithelial cancer of the cervix uteri and its cavity . . . . . viii, 290
„ samples of infants' food . . . . . ix, 29
„ triplets . . . . . ix, 156
„ new intra-uterine pessary . . . . xi, 53
„ — vesico-vaginal speculum-holder . . . xi, 125
„ remarkable case of absence of vagina, with retained menses *in utero* and Fallopian tubes . . . . xii, 34
„ fundal endometritis . . . . . xii, 136
„ bilocular uterus . . . . . xii, 295
„ viability in a child born at five and a half months . . xiii, 132
„ écraseur . . . . . xv, 38
„ use of intra-uterine stems in uterine disease . . xv, 252
„ remarks in the discussion on puerperal fever . . xvii, 257
„ on a case of extra-uterine fibroid successfully removed by gastrotomy . . . . . xvii, 216; xviii, 5
„ addendum to ditto . . . . . xviii, 145
„ case of excessive prolongation of anterior lip of cervix . xviii, 144
„ on a case of extra-uterine pregnancy, with notices of other cases . . . . . xxi, 93
„ for *J. W. J. Oswald*, fœtal monstrosity . . . xxiv, 75

ROWLING (C. C.), the history of the Florence Nightingale Lying-in Ward, King's College Hospital . . . x, 50

RUPTURE of Fallopian tubes (C. Godson) . . xxii, 2, 82
„ — in a case of double pyosalpinx (A. H. N. Lewers) . xxvii, 298
„ — and tubal abortion (A. Routh) . . . xliii, 294
„ of the heart in a still-born infant (C. N. Longridge) . . xlix, 214
„ intra-peritoneal, of the bladder occurring during labour (C. R. Porter) . . . . . xlix, 170
„ partial, of tubal gestation sac in a case of secondary abdominal pregnancy; abdominal section fifteen months after conception, and eight months after death of fœtus (J. B. Hellier) . xlv, 366
„ tubal gestation in which the ovum continued to grow for about four weeks after, the gestation sac becoming implanted on the omentum (C. Lockyer) . . . xlv, 400
„ of an ovarian abscess twelve hours after labour (C. Berkeley) xliv, 73
„ — cyst in an infant (A. Doran) . . . . xxxiv, 24
„ of the sac of an ovarian pregnancy, evidences of, in uterine appendages of the left side (H. Gilford) . . . xliii, 24
„ in primary ovarian pregnancy fourteen days after last menstruation (G. P. Anning and H. Littlewood) . . xliii, 14
„ of perineum, complete (C. R. Thompson) . . . xix, 265
„ — note on the operation for restoring the perineal body in (A. Lawrence) . . . . . xxxii, 377
„ — the use of the purse-string suture in (Percy Boulton) . xxxii, 380
„ prevention of (H. E. Trestrail) . . . . xvii, 61
„ of the uterus, occurring at the eighth month of pregnancy (R. Dunn) . . . . . ix, 65
„ — (G. Roper) . . . . . xx, 2
„ — (John Williams) . . . . . xx, 86
„ — (J. Hickinbotham) . . . . . xx, 96
„ — (F. H. Champneys) . . . . . xxvi, 329
„ — (Robert Harvey) . . . . xxvii, 191, 228
„ — (Lovell Drage) . . . . . xxviii, 2
„ — (J. G. Swayne) . . . . . xxviii, 213
„ — (R. Cox) . . . . . xxviii, 225
„ — (P. Horrocks) . . . . . xxxi, 228
„ — (R. Boxall) . . . . . xxxiv, 11
„ — occurring during labour and after external violence (John Phillips) . . . . . xxxii, 375
„ — and vagina (A. Wiltshire) . . xviii, 220; xxiii, 163
„ — — (P. Horrocks) . . . . xxvi, 119, 260
„ — — (Amand Routh) . . . . . xxxiv, 252
„ of the uterus, four cases successfully treated by packing the tear *per vaginam* with iodoform gauze (H. R. Spencer) . xlii, 14
„ spontaneous, of the uterus in placenta prævia (J. P. Maxwell) xliii, 217
„ of vagina during labour, two cases of (A. L. Galabin) . xx, 295
„ — with recovery (Heywood Smith) . . . xvii, 359
„ — spontaneous, with recovery (A. Wiltshire) . . xvii, 362
„ — incomplete, death from septicæmia (F. H. Champneys) . xxiii, 10

RUSSELL (W. A.), hydatidiform degeneration of the ovum . vii, 228

RUTHERFOORD (HENRY T.), cancerous uterus removed by vaginal hysterectomy; no recurrence nine months after operation . xxxiii, 28
„ cysts of the vagina; their ætiology, pathology, and treatment xxxiii, 354
„ sections of fibroma of the ovary . . . . xxxiv, 88
„ pelvis of a cat, with bladder, uterus, and rectum *in situ* . xxxiv, 251

SABOIA (V.), ovarian disease . . . . . xii, 312
„ notice of a new operation performed on a lady who presented a considerable atresia of the vaginal orifice of the neck of the uterus . . . . . xvi, 116

SACRUM, fœtal head showing furrowing from pressure against (G. Roper) . . . . . xxii, 84
„ cutaneous sinus over (A. Doran) . . . . xxxiii, 199

SACS, double pyosalpinx in which the tubal sacs communicated (J. D. Malcolm) . . . . . xlii, 10
„ five fœtal, from the peritoneal cavity of a rabbit (M. S. Pembrey) . . . . . xl, 253
„ containing fœtuses and lying free in the peritoneal cavity of a rabbit (M. S. Pembrey and G. Bellingham Smith) . . xlvi, 283
„ translucent, microscopical preparations from, in a case of blighted and atrophied embryo (G. E. Herman) . . xxiii, 259
„ of an ovarian pregnancy, uterine appendages of the left side showing evidences of the rupture of (H. Gilford) . . xliii, 24

SALICYLIC ACID, cream of, for keeping sponges and instruments aseptic in the vagina (J. Matthews Duncan) . . xxiv, 5

SALINE SOLUTION in cases of severe hæmorrhage (P. Horrocks) . xxxv, 430
„ injection of, transfusion bottle, etc., for (H. R. Spencer) . xxxv, 428

SALIVATION of pregnancy successfully treated (T. Skinner) . ix, 117
„ spontaneous, associated with pregnancy (A. Farr) . . xv, 222

SALPINGITIS, acute, in tubal pregnancy (T. W. Eden) . . xlviii, 272
„ bilateral primary tuberculous, with secondary infection of the perivascular lymphatics of the uterine wall (C. Lockyer) . xlix, 141
„ on closure of the ostium in (A. Doran) . . . xxxi, 344
„ double, and carcinoma of cervix, fibro-myoma of uterus complicated with (W. W. H. Tate) . . . . xliii, 270
„ double hydrosalpinx without (A. Doran) . . . xli, 379
„ tuberculous (F. J. McCann) . . . . xxxiii, 496
„ unsuspected tuberculous, and pyosalpinx (J. H. Targett) . xlvi, 20
„ see *Fallopian tubes.*

SANDERSON (R.), combined vaginal and abdominal hysterectomy for a pregnancy of four and a half months, complicated by cancer of the cervix . . . . . xliii, 312

SÄENGER-CÆSAREAN SECTION, relative advantages of the modern Porro operation in most cases requiring abdominal section over (A. Routh) . . . . . xlii, 244

SANKEY (W.), knot on funis in a case in which the fœtus was born dead . . . . . iii, 413

SANSOM (A. E.), anæsthetic properties of the bichloride of carbon viii, 49
„ uterine and vaginal douche . . . . . viii, 219
„ pain of parturition and anæsthetics in obstetric practice . x, 121
„ pessaries containing fluids . . . . . x, 245
„ sulpho-carbolates in the treatment of certain diseases of children . . . . . xii, 6

SARCOMA of the body of the uterus removed by vaginal extirpation (W. S. Playfair) . . . . xxxvii, 200
„ — — primary, ("deciduoma malignum") in a patient, aged 24, treated by vaginal hysterectomy (A. H. N. Lewers) . xxxix, 246
„ — — — (A. H. N. Lewers) . . . . xl, 225
„ — — with complete inversion (W. C. Swayne) . . xliv, 366
„ of cervix uteri (A. L. Galabin) . . . xxxviii, 120

SARCOMA (*continued*)—
„ of cervix uteri, "grape-like," fungating into and infiltrating the walls of the vagina, in a child, aged 12 months; extirpation of the uterus and vagina (H. J. Curtis) . . xlv, 320
„ — — — (H. Williamson) . . . . xlvii, 119
„ of the cervix, medullary (A. L. Galabin) . . . xx, 323
„ — supposed (H. R. Andrews) . . . . xlix, 137
„ congenital, in a new-born infant (John Phillips) . xxx, 301, 334
„ malignant, of the right broad ligament (W. S. Playfair) . xv, 217
„ cystic, of omentum, simulating ovarian tumour; removal; recovery (W. Duncan) . . . . . xxxvi, 264
„ doubtful, microscopical sections of uterus showing chorionic villi and (Leonard Remfry) . . . xxxviii, 223
„ of endometrium, small round-celled (A. L. Galabin) . . xlv, 184
„ of the femur, endosteal, showing syncytial structures (F. W. Andrewes) . . . . . xlv, 237
„ of the stomach (G. E. Herman) . . . . xliii, 2
„ of the ovary (G. Elder) . . . . . xxv, 130
„ ovarian, anterior serous perimetritis simulating (A. Doran) xxxi, 217; xxxiii, 185
„ primary, of both ovaries (J. A. Shaw-Mackenzie) . . xxxiv, 2
„ (?) large, of the ovary (P. Horrocks) . . . xxxvi, 192
„ of ovary (W. R. Dakin) . . . . xxxvi, 313
„ of both ovaries (A. Doran) . . . xl, 296
„ of ovary (P. Horrocks) . . . . . xliv, 94
„ — showing necrosis of central portion lying in an abscess cavity containing offensive pus (W. Tate) . . xli, 373
„ — primary melanotic (H. R. Andrews) . . . xliii, 228
„ of the ovary, unusual (J. Inglis Parsons) . . . xlv, 48
„ — of the same side as a tubal mole (A. L. Galabin) . xlviii, 19
„ uterine fibroid clinically resembling (W. R. Dakin) . . xl, 32
„ fibro-myoma of the uterus undergoing change like (W. S. A. Griffith and H. Williamson) . . . . xlviii, 22
„ and degenerating fibro-myoma of uterus (W. Tate) . . xlvii, 358
„ of uterus, further history of a case of degenerating fibro-myoma and (R. Hamilton Bell) . . . . xlviii, 199
„ of the uterus (W. Duncan) . . . . xxxi, 2
„ — removed by vaginal hysterectomy (W. J. Gow) . . xxxii, 374
„ — spindle-celled, removed by vaginal hysterectomy (W. R. Dakin) . . . . . xxxii, 139
„ — with inversion (J. H. Targett) . . . xxxix, 285
„ - (W. S. A. Griffith) . . . . . xli, 232
„ — with a microscopic section (H. R. Andrews) . . xlii, 210
„ — (A. W. W. Lea) . . . . . xliii, 73
„ — (A. L. Galabin) . . . . . xliii, 226
„ — (W. Duncan) . . . . . xliii, 228
„ gangrenous, of uterus, removed by abdominal hysterectomy from a patient suffering from glycosuria (W. Tate) . xliv, 165
„ small fibroma uteri showing evidence of (J. M. Munro Kerr) . xliv, 129
„ of the vagina and uterus, circumscribed (A. H. N. Lewers) . xxviii, 78
„ — secondary deposits in lungs (W. S. A. Griffith) . . xxviii, 38
„ see *Fibro-sarcoma.*

SARCOMATOUS DERMOID CYST of the ovary (J. Knowsley Thornton) . . . . . xxvii, 194

SASS (Mr.), anencephalous fœtus . . . . xi, 31

SAVAGE (HENRY), remarks in the discussion on puerperal fever . xvii, 189
„ — on the use of forceps . . . . xxi, 196

SAVORY (CHARLES T.), case of epithelioma of the cervix uteri complicated with pregnancy; removal of diseased portion; subsequent delivery of a healthy child; recurring pregnancy . xvii, 82

SAVORY (HORACE), notes on a case of puerperal eclampsia . xli, 284

SCALE for calculating onset of labour (W. S. Playfair) . . xxviii, 68

SCARLATINA, the relation of, to menstruation (R. Boxall) . xxx, 55
„ during pregnancy and in the puerperal state (R. Boxall) xxx, 11, 126, 167
„ in the room during a case of persistent sickness and labour (A. W. Williams) . . . . . xii, 164
„ the clinical relation of, to puerperal septicæmia (R. Boxall) . xxx, 126

SCHÄFER (E. A.), *report* of experimental inquiry instituted to determine with what fluids and by what methods the operation of blood transfusion may best be performed, and to ascertain the effects, immediate or remote, which result from the operation in animals . . . . xxi, 316

SCHARLIEB (MARY A. D.), unruptured tubal gestation . . xlvi, 54
„ endothelioma of uterus . . . . . xlvii, 281
„ a case of unusual malignant disease of the uterus . . xlviii, 73
„ myxomatous fibroid . . . . . xlix, 273

SCHNEGIERIEF (W.), on vaginismus (dyspareunia of Barnes) . xvi, 187

SCHOFIELD (R. H. A.), the delivery of a monster . . xxi, 71

SCHROEDER'S OPERATION, cancerous uterus removed by (W. Duncan) . . . . . xxvi, 27
„ uterus removed by, for procidentia (G. Malins) . . xxvi, 148

SCISSORS, angular (H. Smith) . . . . xiv, 68
„ serrated, for making smooth and definite incisions in any tissue (Protheroe Smith) . . . . xvi, 180

SCOOP for removing superficial portions of malignant disease of the cervix (Professor Simon) . . . . xiv, 209

SCOTT (JOHN), specimen illustrating an operation for double ovariotomy . . . . . xiii, 168
„ — *report* on ditto . . . . xiii, 264
„ cyst from case of extra-uterine fœtation . . . xv, 124
„ extra-uterine fœtation, with operation . . . xv, 140

SCOUGAL (E. F.), hemiplegia occurring nine days after parturition; death; partial *post-mortem* examination . . xxx, 214

SECRETION OF MILK in a new-born male child (W. Duncan) . xxx, 226

SECRETIONS, a note on vaginal (W. J. Gow) . . . xxxvi, 52
„ poured into the vagina, the effect of glycerine on the quantity of (G. E. Herman) . . . . . xxx, 452

SECTION OF OBSTETRICS AND GYNÆCOLOGY OF THE ROYAL SOCIETY OF MEDICINE: nomination of first Council . xlix, 136

SECTIONS of an adeno-myomatous polypus of the cervix (F. E. Taylor) . . . . . xlviii, 12
„ illustrating the structure of three different types of urethral caruncles (H. Williamson) . . . . xlvii, 6

SEDGWICK (W.), malformation of the fœtus . . . i, 239

Sell (E. H. M.), ossification of muscles . . . xv, 125
„ complete uterus bicornis, the septum extending into the one common cervix; pregnancy of the right horn; turning and extraction on account of pelvic contraction, the conjugate diameter measuring only two and a half inches . . xv, 180

Semnopithecus entellus, menstruation of (W. Heape) . xxxvi, 213

Sepsis, vaginal hysterectomy in the puerperium for, due to suppuration of myoma (A. W. W. Lea) . . . xlvii, 1

Septicæmia in a case of fibro-cystic myoma of uterus (H. A. Lediard) . . . . . xxvi, 193
„ sloughing of fundus uteri in a case of acute, following abdominal section (C. J. Cullingworth) . . . xxx, 406
„ puerperal, case of (H. Gervis) . . . xviii, 160, 184
„ — with abscesses, phlegmasia dolens, etc. (A. Wiltshire) . xviii, 181
„ — treated by anti-streptococcic serum (J. Walters and A. R. Walters) . . . . . xl, 277
„ — death from, in a case of incomplete rupture of the vagina (F. H. Champneys) . . . . . xxiii, 10
„ — the clinical relation of scarlatina to (R. Boxall) . . xxx, 126
„ — and fatal cardiac thrombosis following a case of abortion (J. T. Musgrave) . . . . . xxi, 81
„ — uterus, heart, and brain from a case of (W. Duncan) . xxxi, 202
„ death after operation from, in a case of extra-uterine gestation (J. D. Malcolm) . . . . . xlv, 421

Septum, case of transverse, in the vagina (H. Gervis) . . xxiv, 210
„ vertical, in lower part of vagina, impeding labour (J. B. Hicks) xxiii, 24
„ several large thick septa in a cyst of the broad ligament (W. S. A. Griffith) . . . . . xxvii, 251

Sequeira (H. L.), face monstrosity . . . . v, 195

Serous peritonitis, see *Peritonitis.*

Serum, anti-streptococcic, appeared to have saved life in two cases (G. E. Herman) . . . . . xli, 346

Severn (Walter D.), *report* on Heywood Smith's specimen shown March 3rd, 1897 . . . . xl, 135

Sex, the essential factor in the causation of; a new theory of sex (E. R. Dawson) . . . . . xlii, 356
„ uncertain; person, aged 26 (W. S. A. Griffith) . . xliii, 298

Seydewitz (Baron P. von), chloral treatment of eclampsia . xii, 117

Sharpin (H. W.), ovarian dropsy; ovariotomy; recovery . vii, 105

Shattock (S. G.) and Graily Hewitt, specimen of spondylolisthesis . . . . . xxvi, 149, 151

Shaw (H. S.), inversion of the uterus; spontaneous reduction . x, 35

Shaw (John), the constant current in the therapeutics of gynæcology . . . . . xxx, 243, 265
„ douche can . . . . . xxxi, 262
„ case of Cæsarean section . . . . xxxiv, 98
„ peritonitis, its nature and treatment . . xxxvii, 10

Shaw (William F.), the pathology of chronic metritis . xlix, 19

Shaw-Mackenzie (J.), dermoid cyst of ovary . . . xxxiii, 461
„ primary sarcoma of both ovaries . . . xxxiv, 2

SHIELD (A. MARMADUKE), extra-uterine gestation associated with sloughing of the abdominal wall, and attempted extrusion of a matured and putrid fœtus near the umbilicus . . xxxiii, 148

SHERATON (G. R.), steel fillet . . . . viii, 259
„ tire-tête, or combined perforator and extractor . . ix, 111

SHORTT (JOHN), singular case of unsuspected pregnancy and awkward delivery . . . . iv, 202
„ sudden and unconscious delivery . . . . iv, 210
„ medical history of women in southern India . . v, 103
„ deformity of arm and hands . . . . vi, 205
„ criminal abortion . . . . ix, 6

SICKNESS, persistent; labour induced after full period had elapsed, scarlatina in the room (A. W. Williams) . . xii, 164
„ of pregnancy, observations on the ætiology of (A. E. Giles) . xxxv, 303
„ treatment of, in uterine inflammation and diseases of menstruation (E. J. Tilt) . . . . iii, 15

SIKES (A. W.), icterus neonatorum . . . . xliv, 369
„ diffuse meningeal hæmorrhage in infant after normal labour . xlv, 44
„ method of taking intra-uterine bacteriological cultures . xlv, 380
„ unusual form of succenturiate placenta . . . xlv, 381
„ three cases of variation of the posterior fontanelle in children xlvi, 272
„ infantile interstitial pneumonia . . . . xlvii, 74

SILCOCK (A. Q.) and GRAILY HEWITT, general and considerable congestive hypertrophy of the uterus with acute anteflexion and presence of an ovarian cyst . . . . xxv, 131

SIMON (MAX F.), case of retroversion of the gravid womb . xvi, 254

SIMON (Professor), scoop for removing superficial portions of malignant disease of the cervix . . . . xiv, 209

SIMS (J. Marion), vaginismus . . . . iii, 356
„ new form of curette for the removal of uterine fungoid granulations . . . . . vii, 72
„ abstract of a paper on procidentia uteri . . . vii, 213
„ procidentia uteri . . . . vii, 213, 238

SIMS' modification of Chassaignac's écraseur . . . vi, 254

SINCLAIR (WILLIAM J.), contribution to the diagnosis and treatment of retroflexio-versio uteri gravidi . . . xlii, 338
„ the use of laminaria tents . . . . xlviii, 185

SINGER (CHARLES), anatomy of an infant presenting some rare deformities . . . . . xlvii, 250

SKELETON of extra-uterine fœtus (L. B. Aldrich-Blake). . xlix, 269

SKENE (WILLIAM), see *Doran, Alban.*

SKIAGRAM of sireniform monster (Herbert Spencer) . xxxviii, 118

SKIN, defective formation of, round the umbilicus (A. Napper) . iii, 65

SKIN DISEASES, common, of children (A. Wiltshire) . . xv, 223

SKINNER (T.), anæsthesia in midwifery . . . iv, 116
„ galactagogue properties of Faradisation, with eight cases . v, 94
„ salivation of pregnancy successfully treated, with a case . ix, 117

SKULL of an anencephalic fœtus (Amand Routh) . .xxxvii, 219
„ monstrosity resulting from amniotic adhesion to (John Phillips) . . . . .xxxviii, 388; xl, 130

SLOAN (SAMUEL), graduated metallic uterine dilators . . xxviii, 114

SLOUGH forming a complete cast of the vagina, from a case of enteric fever (W. S. Playfair) . . . xxxviii, 33

SLOUGHING of the abdominal wall and attempted extrusion of a matured and putrid fœtus near the umbilicus in a case of extra-uterine gestation (A. M. Sheild) . . . xxxiii, 148

„ of the central part of a uterine fibro-myoma shortly after delivery (J. D. Malcolm) . . . . xlvi, 15

„ of the fœtal scalp as the result of tedious labour (W. O. Priestley) . . . . . i, 323

„ of fundus uteri, localised, in a case of acute septicæmia following abdominal section (C. J. Cullingworth) . . xxx, 406

Slyman (William D.), see *Slyman, Woodley.*

Slyman (Woodley), for *W. D. Slyman*, an acephalous acardiac monster of six months' gestation, with rudimentary heart . xxxi, 258

SMALLPOX, complicating pregnancy (R. Barnes) . . ix, 102

„ in the fifth month, with consequent delivery at full term of a dead child (C. W. Milne) . . . . ix, 110

„ in twin fœtuses (H. Madge) . . . . iii, 173

Smith (A. Lionel), diffused subcutaneous induration in an infant xli, 103

Smith (Fly), see *Champneys, F. H.*

Smith (G. F. Darwall), perithelioma of the uterus . . xlix, 97

Smith (Heywood), encephalocele . . . . ix, 243

„ fœtus with rent near the anus, through which the intestines protruded . . . . . x, 198

„ malformed heart . . . . . xii, 116

„ cast of head after cephalotripsy . . . xii, 134; xiii, 37

„ ovum containing fœtus three eighths of an inch long . xii, 163

„ marine vaginal irrigator . . . . xiii, 190

„ fœtus at fourth month enclosed in a perfect sac . . xiv, 66

„ uterus after delivery at five months; death from secondary post-partum hæmorrhage from carcinoma of cervix . . xiv, 67

„ angular scissors . . . . . xiv, 68

„ modification of angular scissors . . . . xiv, 103

„ treatment of post-partum hæmorrhage by the intra-uterine injection of the perchloride of iron . . . xv, 44, 65

„ instrument for dividing funis . . . . xv, 86

„ improvement in single-wire écraseur . . . xv, 86

„ fœtus with diaphragmatic hernia . . . . xv, 162

„ three months' fœtus flattened and curved laterally, and double placenta atrophied and flattened . . . xvi, 2

„ new "rat-trap" forceps to aid in the removal of uterine growths, or to be used as vulsella during ovariotomy . xvi, 229

„ uterus and ovaries of a woman who had died of hæmorrhage into the pelvis . . . . . xvii, 56

„ notes of a case of ruptured vagina during labour, with recovery . . . . . xvii, 359

„ three new points for Paquelin's petroleum cautery . . xix, 41

„ Bailey's new patent abdominal belt . . . xix, 41

„ new portable pelvimeter imported from Russia . . xix, 41

„ on a case of inversion of the uterus . . . xix, 57

„ uterus, the body of which was the seat of malignant disease . xx, 4

„ parts illustrating extra-uterine fœtation . . . xx, 5

„ forceps bent as a sound, for the introduction of laminaria tents, designed by Mr. Coley . . . . xx, 170

„ modification of ovum forceps . . . . xx, 170

SMITH (HEYWOOD) (*continued*)—
„ uterus and appendages removed by hysterectomy . . xxi, 313
„ *report* on ditto by committee (A. L. Galabin and John Williams) . . . . . xxii, 3
„ belt for use after ovariotomy . . . . xxii, 45
„ grappling iron for use in hysterotomy or removal of large solid ovarian tumours . . . . . xxii, 45
„ improvement in the joint of his ovum forceps . . xxii, 46
„ improved duck-bill speculum . . . . xxii, 46
„ two photographs of a young woman whose mother was frightened by a monkey . . . . xxii, 242
„ case of delivery through an imperforate vagina . . xxiii, 117
„ removal of a large fibrous polypus . . . xxiii, 233
„ fibroma of the uterus . . . . . xxiii, 262
„ fœtus with outgrowth from end of coccyx . . . xxv, 2
„ dermoid cyst of the ovary . . . . xxvi, 57
„ fibro-cystic disease of the uterus; hysterectomy . . xxvi, 58
„ new electric light . . . . . xxvii, 3
„ abscess of ovary . . . . . xxxiv, 3
„ radiograph of fœtus *in utero* . . . . xlviii, 44
„ uterus removed by Porro's operation . . . xxv, 2

SMITH (PROTHEROE), extraction of a hairpin from the bladder of a female by means of an instrument . . . x, 59
„ pelvic band . . . . . xi, 169
„ exploring needle trocars . . . . xii, 271
„ carcinoma of cavity of uterus . . . . xii, 299
„ pelvic viscera after death from spontaneous rupture of ovarian cyst, complicated with fibroid tumour of uterus . . xiii, 39
„ ovarian tumour . . . . . xiii, 98
„ uterus and appendages from above case . . . xiii, 126
„ new expanding cylindrical speculum uteri . . . xiii, 187
„ pneumatic india-rubber tube for introduction of cylindrical specula . . . . . xv, 165
„ newly invented serrated scissors to insure a clean cut through any tissue . . . . . xvi, 180
„ case of abortion at six and a half months with general dropsy of the fœtus . . . . . xvii, 303

SMITH (W. TYLER), abolition of craniotomy from obstetric practice, in all cases where the fœtus is living and viable . . i, 21
„ excessive vomiting in early pregnancy, depending on the irritation of the gravid uterus . . . . i, 335
„ inquiry into the correctness of the doctrine of William Hunter in regard to retroversion and retroflexion of the gravid uterus . . . . . ii, 286
„ inaugural address as President . . . iii, 3; iv, 6; v, 18
„ ovariotomy, with cases and remarks on the different steps of the operation and the causes of its mortality . . iii, 41
„ four additional cases of ovariotomy . . iii, 215; iv, 141
„ instrument for removal of polypi of the uterus . . iii, 413
„ eight additional cases of ovariotomy . . . vi, 66
„ dermoid cyst . . . . . vii, 45
„ new speculum uteri . . . . . viii, 101
„ two cases of inversion of the uterus after delivery, with remarks . . . . . x, 30
„ puerperal fever treated by the injection of ammonia into the veins, followed by recovery . . . . xi, 247

SMITH (W. TYLER) (*continued*)—
„ and J. B. HICKS, *report* on N. J. Haydon's specimen of extra-uterine fœtation . . . . . v, 281
SMUTS (C.), curious case of prolapsed placenta . . viii, 280
SMYLY (W. J.), three myomatous uteri removed *per vaginam* by Doyen's method . . . . . xli, 96
SOCIETIES, amalgamation of medical, special general meeting on xi, 151
SOUFFLE, see *Bruit*.
SOUND, uterine, aseptic (P. Horrocks) . . . xxxiv, 460
„ — flexible vertebrated (G. C. P. Murray) . . . xviii, 140
„ — in flexions of the uterus (A. Rasch) . . . xiii, 247
„ — with metroscope (A. Meadows) . . . ix, 242
SPAULE (B.), hydrocephalic head of a child . . . xiii, 214
SPECULUM, pneumatic india-rubber tube for introduction of cylindrical (P. Smith) . . . . . xv, 165
„ expanding, for operations on the cervix uteri (R. Ellis) . ix, 86
„ modification of Neugebauer's (R. Barnes) . . . xiv, 309
„ self-retaining (Leith-Napier) . . . . xxxv, 3
„ (H. R. Spencer) . . . . xxxviii, 117
„ holder, vesico-vaginal (C. H. F. Routh) . . . xi, 125
„ uteri (W. T. Smith) . . . . viii, 101
„ — new expanding cylindrical (P. Smith) . . . xiii, 187
„ vaginal (A. Meadows) . . . . xi, 3; xii, 134
„ — of Dr. Neugebauer . . . . xiii, 51
„ — (J. Hall Davis) . . . . xvi, 98
„ — ordinary cylindrical, set of pocket instruments contained within (C. Godson) . . . . xxi, 90
„ — improved duck-bill (Heywood Smith) . . . xxii, 46
„ — toughened glass (A. Wiltshire) . . . xix, 137
„ a glissières, Delbastaille's (Alban Doran) . . . xxxii, 307
„ for introducing pledgets of wool into vagina (R. Barnes) . xiii, 96
„ trough, india-rubber (A. W. Edis) . . . xvii, 49
SPENCER (HERBERT R.), uterus with sloughing fibroid . . xxx, 408
„ an eight month anencephalic monster . . . xxx, 408
„ the diagnosis of placenta prævia by palpation of the abdomen xxxi, 203
„ three cases of congenital diaphragmatic hernia, two being on the right side . . . . . xxxii, 132
„ congenital diaphragmatic hernia . . . . xxxiii, 34
„ visceral hæmorrhages in still-born children; an analysis of 130 autopsies; being a contribution to the study of the causation of stillbirth . . . . . xxxiii, 203
„ retroflexion of the uterus in a new-born child . . xxxiv, 25
„ case of triplets and complete placenta prævia in which the children were delivered alive through a perforation in the first placenta . . . . . xxxv, 107
„ transfusion bottle, etc., for injection of saline fluid . . xxxv, 428
„ speculum . . . . . xxxviii, 117
„ skiagram of sireniform monster . . . xxxviii, 118
„ case of deciduoma malignum . . . xxxviii, 135
„ three cases of Porro's operation, with intra-peritoneal treatment of the stump . . . . . xxxviii, 389
„ incarcerated ovarian dermoid obstructing labour; ovariotomy during labour . . . . . xl, 14
„ — — — manual elevation; removal seven months later . xl, 22
„ — — in the middle of pregnancy; manual elevation; removal a fortnight after delivery at term . . . xl, 259

SPENCER (HERBERT R.) (*continued*)—
„ incarcerated ovarian dermoid, removed at the fourth month of pregnancy; delivery of a living child at term . . xl, 329
„ for *James Jackson*, incarcerated ovarian dermoid ruptured during delivery by forceps and version, with fatal result . xl, 331
„ two cases of fibro-myoma of the uterus removed by operation from women under twenty-five years of age . . xl, 228
„ three cases of congenital tumour at the internal os uteri causing hydrometra in new-born children . . . xl, 332
„ adenoma of the meatus urinarius externus . . . xli, 383
„ peculiar cervical mucous polypus . . . . xli, 383
„ four cases of rupture of the uterus successfully treated by packing the tear *per vaginam* with iodoform gauze . . xlii, 14
„ two cases of parovarian cyst with twisted pedicle, in which the ovary only (and not the cyst) was congested and inflamed . . . . . xlii, 333
„ large uterus, with cervical fibroid, removed by abdominal hysterectomy by Doyen's method . . . xliii, 5
„ cystic fibro-myoma of the uterus removed by posterior colpotomy . . . . . xliii, 110
„ large ovarian tumour ruptured on the third day after labour . xliii, 224
„ Porro medal and report on Porro-Cæsarean section . . xliv, 298
„ Kurz needle-holder . . . . . xlv, 51
„ deciduoma malignum . . . . . xlv, 250
„ degenerated uterine fibroid threatening to rupture, removed by total abdominal hysterectomy . . . xlv, 378
„ fibro-myoma of the intra-abdominal portion of the round ligament of the uterus . . . . . xlvi, 26
„ degenerated fibro-myoma weighing over 17 lb. enucleated from the broad ligament nine hours before delivery at term . xlvi, 122
„ cancer of the body of the uterus simulating fibroid in a woman, aged 36 . . . . . xlvi, 235
„ galvano-cautery knife . . . . . xlvi, 353
„ three cases of cancer of the cervix complicating labour in advanced pregnancy, the patients remaining well eleven, eight and a half, and eight years after high amputation of the cervix . . . . . xlvi, 355
„ carcino-sarcoma uteri . . . . . xlvii, 338
„ a second case of abdominal ovariotomy during labour . xlviii, 37
„ Cæsarean section and total abdominal hysterectomy for fibroids complicating labour near term in a patient who had recovered without operation from ruptured tubal pregnancy . xlviii, 240
„ three cases of myomatous uteri bleeding after the menopause . xlviii, 333
„ inaugural address . . . . . xlix, 117
„ myomatous uterus weighing over 7 lb. removed from a woman, aged 22 . . . . . xlix, 219
„ calcified uterine fibro-myoma removed piecemeal for hæmorrhage fourteen years after oöphorectomy . . . xlix, 271

SPHYGMOGRAPH in the puerperal state, the indications afforded by the (Fancourt Barnes) . . . . xvi, 263

SPINA BIFIDA (W. G. Hewitt) . . . . iv, 5
„ (D. L. Roberts) . . . . xi, 313
„ two cases of (D. L. Roberts) . . . xii, 361
„ dissection of a case of (T. W. Eden) . . . xxxv, 336
„ associated with hydrocephalus (R. Barnes) . . v, 172
„ — — (W. Leishman) . . . . v, 198
„ followed by hydrocephalus (D. Richards) . . . iv, 191

SPINA BIFIDA (*continued*)—
„ hydrocephalus with (R. J. Probyn-Williams) . . xxxvi, 4
„ in an anencephalous fœtus (F. Wallace) . . . xxiii, 204
„ fœtus anencephalus with (E. Jones) . . . xi, 209
„ lumbo-sacralis, and hernia umbilicalis congenita (Amand Routh) . . . . . xxxv, 102
„ in association with congenital prolapse of uterus (H. R. Andrews) . . . . . xliv, 137
„ with talipes varus of both feet (H. Madge) . . ix, 158
„ supposed (P. Horrocks) . . . . . xxix, 57
SPINAL COLUMN exhibiting want of ossification in the inter-articular portion of the lumbar vertebræ (G. F. Blacker) . xlii, 90
SPINAL CORD, obliteration of the central canal of, in an early human embryo (C. B. Lockwood) . . . xxx, 470
SPINE, completely cleft, associated with an unusual visceral malformation in an anencephalic fœtus (T. G. Stevens) xxxviii, 346
„ large tumour at the end of, supposed spina bifida (P. Horrocks) . . . . . xxix, 57
SPLEEN, fatal rupture of an aneurysm of the artery of, immediately after labour (J. D. S. Nodes and Frank Hinds) . xlii, 305
„ hypertrophy of, in a child aged 9 (J. W. J. Oswald) . . xviii, 191
„ enlarged wandering, forming pelvic tumours (F. E. Taylor) . xlvi, 179
„ wandering, simulating an ovarian tumour and causing retroversion of the uterus (F. E. Taylor) . . . xlvii, 70
SPONDYLOLISTHESIS, with an account of a case of pelvic contraction from this affection (R. Barnes) . . . vi, 78
„ appendix to above . . . . . vi, 98
„ specimen of, in University College Museum, with anatomical description (Graily Hewitt and S. G. Shattock) . xxvi, 149, 151
„ specimens illustrating (F. L. Neugebauer) . . xxvi, 84, 186
„ in a girl aged 16 (J. H. Targett) . . . . xxxiii, 108
„ redescription of the specimen in the Museum of University College (T. W. P. Lawrence) . . . . xlii, 75
SPONGE TENTS, aseptic (A. Lawrence) . . . xxxi, 333
„ plan for deodorising (J. H. Aveling) . . . ix, 264
SPONGES in the vagina, means of keeping, aseptic (J. Matthews Duncan) . . . . . xxiv, 5
SPURIOUS LABOUR, case of (H. R. Fuller) . . . xxvii, 326
„ macerated fœtus removed from the abdominal cavity two months after (A. Doran) . . . . xlii, 8
„ extra-uterine, occurred at term after, and in which abdominal section was performed four to five months later (John Phillips) . . . . . xlii, 121
„ — gestation in which fœtal death occurred at the eighth month after, abdominal section two months later (A. Doran) xlii, 213
SQUAREY (C. E.), short account of a case of three sisters in whom the uterus and ovaries were absent . . . xiv, 212
„ causation of acquired flexions of the uterus and their pathology . . . . . xiv, 344
„ flexible stems for flexions of the uterus . . . xv, 221
SQUIRE (W.), glandular cystic tumour of mamma . . iii, 213
„ puerperal temperatures . . . . ix, 129, 145
„ infantile temperature in health and disease . . x, 273
„ temperature variations in the diseases of children . . xii, 171
„ earthenware bed-pan and linen breast supporter . . xv, 163

SQUIRE (W.) (*continued*)—
„ remarks in the discussion on puerperal fever . . xvii, 143
„ cancer of the uterus, where degeneration had proceeded to its most extreme degree without marked pain . . xx, 85
„ see *Buckell, Edward.*

STABB (A. F.), for *W. S. A. Griffith*, placenta velamentosa and an abnormally large placenta . . . xxxviii, 4
„ uterus with interstitial fibroid removed from a patient aged 26 xxxix, 89
„ pedunculated subserous fibro-myoma of uterus which had undergone myxomatous and cystic degeneration . . xlii, 133

STANNUS (HUGH S.), orbital tumour in a hydrocephalic female fœtus, with tumour of cheek, maldevelopment of neck, associated with hydramnios, necessitating interference with the pregnancy at the seventh month . . . xliii, 304
„ teratoma of the fœtal head . . . xliv, 78

Staphylococcus albus, peritonitis and (J. D. Malcolm) . . xlviii, 97

STATISTICS of midwifery practice, see *Midwifery.*

STEAMING and curetting of uterus followed by vaginal hysterectomy fourteen days after (G. F. Blacker) . . . xlv, 80

STEAVENSON (W. E.), electrical instruments in use in obstetric medicine . . . . . xxix, 298
„ note on the use of electrolysis in gynæcological practice xxx, 229, 260, 265

STEELE (A. B.), on the management of difficult labour with a minor degree of contraction of brim . . . xvi, 32

STEMS, flexible, for flexions of the uterus (C. E. Squarey) . xv, 221
„ intra-uterine, use of, in uterine disease (C. H. F. Routh) . xv, 252
„ see *Pessaries*, stem.

STENOSIS, mitral, case of labour in a primipara suffering from (G. Coates) . . . . . xxviii, 108

STEPHENSON (SYDNEY), ophthalmia neonatorum, its ætiology and prevention . . . . . xlv, 337

STEPHENSON (WILLIAM), remarks in the discussion on the use of forceps . . . . . xxi, 150
„ on rotatory action in using the forceps . . . xxii, 217
„ on the relation between chlorosis and menstruation, an analysis of two hundred and thirty-two cases . . . xxxi, 104
„ see *McKerron, Robert G.*

STERILITY and spasmodic dysmenorrhœa, the treatment of, by dilatation of the cervical canal with graduated metallic bougies (C. Godson) . . . xxiii, 277; xxiv, 6
„ dysmenorrhœa, metrorrhagia, ovaritis and, depending upon a peculiar formation of the cervix uteri (R. Barnes) . . vii, 120
„ treatment of mechanical dysmenorrhœa and (R. Greenhalgh) v, 164

STERILITY AND ABORTION, on the relation between backward displacement of the uterus and (G. E. Herman) . . xxxiii, 499

STEVENS (THOMAS G.), fœtus with absence of urethra and ascites obstructing delivery . . . . xxxvii, 5
„ and GRIFFITH (W. S. A.), notes on the variation in height of the fundus uteri above the symphysis during the puerperium, the conditions which influence this, and the practical conclusions which may be drawn from such observations . xxxvii, 246
„ case of completely cleft spine associated with an unusual visceral malformation in an anencephalic fœtus . xxxviii, 346

STEVENS (THOMAS G.) (*continued*)—
„ for *Peter Horrocks*, uterine fibroid undergoing colloid degeneration . . . . . xxxvi, 225
„ membranous vaginitis in which the *Bacillus coli communis* was found . . . . . xli, 228
„ fate of the ovum and Graafian follicle in pre-menstrual life . xlv, 465
„ see *Galabin, A. L.*
STEVENSON (E. SINCLAIR), case of spurious pregnancy simulating ectopic gestation . . . . . xxxii, 216
„ two cases of ectopic gestation . . . . xxxv, 175
STEWART (—), legging for varicose veins . . . xvi, 88
„ nightdress for ladies during and after childbirth . . xvi, 87
STILLBIRTHS, statistics of (F. W. Lowndes) . . . xiv, 283
„ visceral hæmorrhages at (H. R. Spencer) . . . xxxiii, 203
STILLBORN CHILD, recovery of, unusual marking of the skin, simulating the effects of injury (J. Rouse) . . vii, 45
STILLBORN CHILDREN, registration of . . . xvi, 22
STOMACH, sarcoma of (G. E. Herman) . . . xliii, 2
STOTHARD (JAMES), see *Edis, A. W.*
STOTT (W. ATKINSON), ruptured tubal pregnancy . . xxxvi, 343
STRANGULATION and gangrene of ovarian tumours from their axial rotation, successful ovariotomy in (Lawson Tait) . xxii, 86
STRICTURE of the urethra in women (G. E. Herman) . . xxix, 27
„ — lupous (G. E. Herman) . . . xxviii, 267
STUDIES in obstetrics (C. F. Ponder) . . . xl, 339
STURMER (A. J.), (?) hydatidiform cysts growing in the vulva . xliii, 148
„ (?) parasitic cyst of the vulva . . . . xliv, 2
„ four cases of ruptured extra-uterine gestation occurring in two women; removal by abdominal section; recovery . xlv, 144
„ deciduoma malignum . . . . . xlv, 251
„ fibro-myoma of ovary . . . . xlv, 335, 370
„ forty-one cases of puerperal eclampsia treated by thyroid extract . . . . . xlvi, 126
„ abdominal gestation . . . . . xlvi, 385
STYPTIC COLLOID, cure of inveterate case of ulceration of the cervix uteri by (J. Wynne) . . . . xi, 86
SUGAR in the urine during the puerperal state, the occurrence of (F. J. McCann and W. A. Turner) . . . xxxiv, 473
SULPHO-CARBOLATES in the treatment of certain diseases of children (A. E. Sansom) . . . . xii, 6
SUPERFŒTATION, probable (W. S. Playfair) . . . xxxiii, 496
„ — (W. F. V. Bonney) . . . . xliv, 163
„ supposed (W. S. Playfair) . . . . xxii, 3
SUPPORT, mechanical, during labour (W. Woodward) . . xi, 192
SUPPRESSION of urine after labour (R. G. McKerron) . . xliv, 97
SUPPURATION and discharge into mucous cavities of dermoid cysts of the pelvis (G. E. Herman) . . . xxvii, 254
„ in fibro-myoma uteri following premature delivery, treated by abdominal hysterectomy (W. Tate) . . . xlix, 54
„ in a large retro-peritoneal fibroid (C. H. Roberts) . . xli, 213
„ in an ovarian cyst caused by the *Bacillus typhosus* (F. E. Taylor) . . . . . xlix, 256

SURGERY, inaugural address on gynæcology in relation to (A. Doran) . . . . . xli, 107

SUSPENDER, ladies' garment, of elastic webbing (E. J. Tilt) . xvi, 202

SUSURRUS, muscular, in relation to fœtal heart sounds (J. B. Hicks) . . . . . xv, 187

Sutton (J. Bland), the glands of the Fallopian tubes and their function . . . . . xxx, 207
„ ovarian cysts with mucous membrane . . . xxx, 339
„ some specimens of ovarian tumours . . . xxxi, 333
„ uterus showing the effects of a gangrenous fibroid . . xxxii, 171
„ the glands of the Fallopian tube . . . . xxxii, 189
„ case of tubal abortion . . . . . xxxii, 342
„ a case of tubal pregnancy . . . . xxxiii, 70
„ on an early tubal ovum . . . . xxxvi, 195
„ see also *Bland-Sutton, J.*

SUTURE for closing the uterine wound in Cæsarean section and for uniting uterine wound to the abdominal wall (R. Barnes) xii, 364
„ the purse-string, its use in complete rupture of the perineum (P. Boulton) . . . . . xxxii, 380

Swayne (J. G.), discoloration of the skin of the forearms and hands during pregnancy . . . . iv, 18
„ Cæsarean section . . . . . v, 84
„ double monstrosity . . . . ii, 320; viii, 1
„ remarks in the discussion on puerperal fever . . xvii, 154
„ on a new form of blunt hook and sling for assisting delivery in cases of breech presentation . . . . xvii, 313
„ remarks in the discussion on the use of forceps . . xxi, 233
„ on a new form of stem pessary . . . . xxiv, 220
„ gangrene of the thigh during the seventh month of pregnancy xxv, 215
„ cases of ruptured uterus . . . . xxviii, 213
„ hydrocephalus as a complication of labour . . . xxix, 405

Swayne (W. C.), sarcoma of the body of the uterus with complete inversion . . . . . xliv, 366
„ cystic fibroid of uterus . . . . . xliv, 369
„ uterine fibroid removed by pan-hysterectomy . . xlv, 140
„ fibroid of the vagina . . . . . xlv, 142

SYMPHYSIOTOMY, case of (A. H. N. Lewers) . . . xxxv, 408
„ patient after (W. S. A. Griffith) . . . xxxvii, 13
„ a plea for the practice of, based upon its record for the past eight years (R. P. Harris) . . . . xxxvi, 117
„ subcutaneous (G. E. Herman) . . . . xlii, 282

SYNCYTIOMA from the body of a woman who died in St. Bartholomew's Hospital thirty-one years ago (H. Williamson) . xlv, 253

SYNCYTIUM derived from chorionic epithelium partially differentiated into cells shown in a vesicular mole (A. L. Galabin) . xlv, 240
„ deciduoma malignum *without*; secondary deposits in vagina, lymphatic glands (iliac and lumbar), and lungs, after hydatidiform degeneration of the chorion (P. Horrocks) . xlv, 243
„ forming reticulating processes, carneous mole retained *in utero*, five months after death of embryo, showing proliferation of epithelium of villi as (A. L. Galabin) . . . xlv, 240
„ structures of, in endosteal sarcoma of the femur (F. W. Andrewes) . . . . . xlv, 237

SYNOSTOSIS, left sacro-iliac, in a case of obliquely contracted pelvis, with remarks on the pelvis of Naegele (F. H. Champneys) . . . . . xxiv, 191

SYPHILIS after vaccination (R. Druitt) . . . v, 196
„ chancre on the cervix uteri (G. E. Herman) . . xxvii, 252
„ infantile (T. H. Tanner) . . . . i, 132
„ fatty placenta and a still-born fœtus from a patient suffering with (T. C. Hayes) . . . . . xvii, 275
„ of placenta (B. Godfrey) . . . xiv, 137, 211

SYRINGE, the alpha constant current (P. Boulton) . . xxx, 198

TAIT (E. S.), some observations on puerperal temperatures . xxvi, 8
TAIT (LAWSON), reduction of chronic inversion of the uterus by sustained pressure . . . . . xi, 174
„ instruments for the application of medicated tents to the interior of the cervix . . . . . xiv, 323
„ diagnosis of extra-uterine pregnancy . . . xv, 135
„ case of general dropsy in a fœtus . . . . xvii, 307
„ note on a diseased placenta . . . . xvii, 326
„ case of vesico-vaginal fistula left fourteen years after lithotomy, cured by a series of plastic operations . . . xviii, 209
„ four cases of removal of large uterine myomata by abdominal section . . . . . xix, 274
„ two cases of repair of the female bladder and urethra . xx, 88
„ apparatus for dilating the uterine canal by continuous elastic pressure . . . . . xxi, 291
„ on new methods of operation for repair of the female perineum xxi, 292
„ on axial rotation of ovarian tumours, leading to their strangulation and gangrene; three cases successfully treated by immediate ovariotomy . . . . . xxii, 86
„ removal of the uterine appendages, fifteen specimens of hydro- and pyosalpinx . . . . . xxiv, 157
„ hydrosalpinx and pyosalpinx . . . . xxv, 111
„ parovarian cyst . . . . . xxv, 112
„ four cases of pyosalpinx . . . . . xxv, 138
„ note on uterine myoma, its pathology and treatment . xxv, 194
„ three cases of pyosalpinx . . . . xxv, 234
„ case of idiopathic gangrene of the uterus . . . xxv, 248
„ an undescribed disease of the Fallopian tubes . . xxv, 249
„ removal of appendages on account of chronic inflammatory disease . . . . . xxix, 184
„ case of ectopic pregnancy in which the fœtus seems to have been developed to the full time in the peritoneal cavity, still retaining its amniotic covering . . . . xxxiv, 192
„ two cases of hysterectomy . . . . xxxiv, 199
„ see *Jones, Sydney.*
„ and CHRISTOPHER MARTIN, note on the growth of the placenta after death of the fœtus in ectopic gestation . . xxxiv, 206

TALIPES VARUS of both feet and spina bifida (H. Madge) . ix, 158
„ see *Malformations.*

TANNER (T. H.), infantile syphilis, with remarks . . i, 132
„ two fœtal monsters . . . . . ii, 247
„ fibrous tumour of the uterus . . . . iii, 11
„ unsuspected pregnancy and labour . . . iv, 113

TANNER (T. H.) (*continued*)—
„ use of medicated pessaries in the treatment of uterine disease iv, 205
„ multiple medullary cancer complicated with pregnancy . iv, 243
„ hernia cerebri and hernia umbilicalis, with attachment of the fœtal membranes to the scalp . . . . vii, 109
„ excision of the clitoris as a cure for hysteria, etc. . . viii, 360
„ see *Harley, G.*

TAPSON (J. A.), placenta and knotted cord . . . xi, 242
„ removal of intra-uterine tumours . . . . xv, 247

TARGETT (J. H.), spondylolisthesis in a girl aged 16 . . xxxiii, 108
„ — *report* on ditto by committee (J. H. Targett, Alfred L. Galabin, G. E. Herman, and F. H. Champneys) . . xxxiii, 463
„ two cases of pseudo-hermaphroditism . . . xxxvi, 272
„ hydatids in the bony pelvis . . . . xxxvi, 344
„ acute suppuration and sloughing of ovaries after parturition . xxxvii, 216
„ epidermic casts from the vagina . . . . xxxvii, 218
„ ruptured gestation in an imperfect uterine horn (*Uterus bicornis unicollis*) . . . . xxxix, 46
„ encysted tuberculous peritonitis and its effects upon the female pelvic viscera . . . . . xxxix, 126
„ accessory adrenal bodies in the broad ligaments . . xxxix, 157
„ sarcoma of the uterus with inversion . . . xxxix, 285
„ for *J. B. Hellier*, case of deciduoma malignum . . xl, 113
„ double intestinal obstruction following ovariotomy . . xl, 175
„ *report* on Amand Routh's specimen of ruptured tubal gestation xl, 222
„ fibro-myoma of vagina (anterior wall) . . . xli, 100
„ two cases of double tuberculous pyosalpinx . . xli, 163
„ Naegele pelvis . . . . . xli, 231
„ tuberculous pyosalpinx . . . . . xli, 341
„ perimetric cystoma . . . . . xli, 343
„ ruptured uterus at term through scar of old Cæsarean section; abdominal hysterectomy . . . . xlii, 242
„ full-term pregnancy in a rudimentary horn of uterus; missed labour (five months); abdominal section and removal of sac; recovery . . . . . xlii, 276
„ carcinoma of the body of the uterus . . . xlii, 281
„ unsuspected tuberculous salpingitis and pyosalpinx . . xlvi, 20
„ abdominal hysterectomy for severe concealed accidental hæmorrhage . . . . . xlvii, 147
„ and H. T. HICKS, two cases of malignant embryoma of the ovary . . . . . xlvii, 287
„ hæmorrhage in uterine fibroid . . . . xlix, 268

TARNIER'S FORCEPS, description of modification in (A. Wiltshire) xix, 223
„ modification of (A. W. Edis) . . . . xx, 163

TATE (WALTER), tubo-ovarian abscess . . xxxviii, 319, 380

TATE (WALTER W. H.), three cases of pyometra complicating cancer of the cervix uteri . . . . . xxxix, 323
„ fibro-myoma of uterus projecting into vagina, removed by abdominal hysterectomy . . . . xl, 159
„ carcinoma of cervix uteri in which the disease extended upwards into the body . . . . . xl, 258
„ case of sloughing fibro-myoma of uterus occurring in a patient twenty years after the menopause . . . xl, 303
„ calcareous fibroid of the cervix . . . . xli, 372

Tate (Walter W. H.) (*continued*)—
„ sarcoma of ovary showing necrosis of central portion lying in an abscess cavity containing offensive pus . . xli, 373
„ large fibro-myoma of the cervix removed by enucleation, followed by vaginal hysterectomy . . . xlii, 161
„ suppurating ovarian cyst obstructing labour, removed by abdominal section eighteen months later . . . xlii, 164
„ fibro-myoma of uterus showing marked cystic degeneration, removed from a patient aged 63, from whom both ovaries had been removed eleven years before . . . xliii, 26
„ fibro-myoma of uterus complicated with double salpingitis and carcinoma of cervix . . . . . xliii, 270
„ lithopædion retained in patient for sixteen years . . xliv, 95
„ gangrenous sarcoma of uterus removed by abdominal hysterectomy from a patient suffering from glycosuria . . xliv, 165
„ two cases of fibro-myoma of cervix treated by abdominal hysterectomy . . . . . xlv, 173
„ tuberculous disease of cervix and Fallopian tubes . . xlvi, 138
„ fibro-myoma of uterus, with extensive carcinoma of body of uterus, and fibroma of ovary . . . . xlvi, 139
„ two cases of diffuse adeno-myoma of uterus . . xlvi, 141
„ fibro-myoma and cystic disease co-existing in the same ovary . xlvi, 273
„ dermoid cyst of the ovary removed by abdominal section five years after causing obstruction to labour. . . xlvi, 344
„ three cases of intestinal obstruction following operations for fibroid tumour of uterus, with special reference to the choice of operation . . . . . xlvi, 391
„ degenerating fibro-myoma and sarcoma of uterus . . xlvii, 358
„ fibro-myoma of uterus, associated with large cavity containing retained menses communicating with uterine canal . xlvii, 360
„ carcinoma of the ovary . . . . . xlviii, 96
„ large fibro-myoma of uterus removed by operation . , xlviii, 183
„ co-existing tubal and uterine pregnancy; abdominal section; subsequent delivery at term . . . . xlix, 51
„ suppuration in fibro-myoma uteri, following premature delivery, treated by abdominal hysterectomy . . xlix, 54

Taylor (F.), nipple shield . . . . iv, 228

Taylor (F. E.), two cases of enlarged wandering spleen forming pelvic tumours . . . . . xlvi, 179
„ adeno-myoma of the uterus . . . . xlvi, 188
„ fibroma of the ovary . . . . . xlvi, 280
„ wandering spleen simulating an ovarian tumour and causing retroversion of the uterus . . . . xlvii, 70
„ necrobiotic uterine fibro-myoma occurring in pregnancy . xlvii, 333
„ presence of sarcomatous tissue in the walls of ovarian cysts . xlvii, 411
„ sections of an adeno-myomatous polypus of the cervix . xlviii, 12
„ suppuration in an ovarian cyst caused by the *Bacillus typhosus* xlix, 256
„ two uteri with "fundal ligament" after hysteropexy . xlix, 265

Taylor (John W.), extra-uterine pregnancy at full term; removal of child and placenta by abdominal section; recovery . xxxiii, 115
„ a second case of "abdominal" pregnancy successfully treated by removal of child and placenta three months after death of child at term . . . . . xxxix, 178
„ ovarian tumour obstructing delivery; posterior vaginal section and ovariotomy during labour; operation and delivery at one sitting; recovery . . . . . xliv, 275

TAYLOR (JOHN W.) (*continued*)—
„ small ovarian tumour removed by vaginal section from a patient who was about two months pregnant . . xliv, 297
„ complete inversion of uterus of seven months' duration; failure of elastic pressure with repositors; operation of anterior vaginal cœliotomy, anterior hysterotomy, and replacement; recovery . . . . . xliv, 299

TEACHER (J. H.), chorion-epithelioma malignum; primary tumour in uterus . . . . . xlv, 252
„ for *Professor Sutherland* and *Dr. Buist*), chorion-epithelioma malignum with secondary growths in liver . . xlv, 252
„ chorion-epithelioma malignum, two photographs of pelvic organs with primary tumour and a glass tube containing a secondary nodule from the lungs . . . xlv, 253
„ — (the so-called deciduoma malignum) and the occurrence of chorion-epitheliomatous and hydatidiform mole-like structures in tumours of the testis . . . . xlv, 256
„ — and the occurrence of chorion-epitheliomatous and hydatidiform mole-like structures in teratomata, adjourned discussion . . . . . xlv, 303

TEETHING (S. Norton) . . . . . xi, 183

TEMPERATURE and urine in puerperal eclampsia (G. E. Herman) xxxii, 17; xxxiii, 315
„ in a case of pelvic cellulitis (C. J. Cullingworth) . . xii, 370
„ infantile, in health and disease (W. Squire) . . x, 273
„ immediately after delivery in relation to the duration and other characteristics of labour (A. E. Giles) . . xxxvi, 238
„ prolonged high, of nervous origin, in a case showing uterine contraction without retraction (G. E. Herman) . . xlviii, 204
„ observations in relation to menstruation, on the variations in pulse and (A. E. Giles). . . . . xxxix, 115
„ pulse, and respiration during labour and the lying-in, some observations on (R. J. Probyn-Williams and L. Cutler) xxxvii, 19, 152
„ puerperal (W. Squire) . . . . ix, 129, 145
„ — some observations on (E. S. Tait) . . . xxvi, 8
„ regulator, Leiter's (C. Godson) . . . xxiii, 131
„ variations in the diseases of children (W. Squire) . . xii, 171

TENACULUM, self-retaining, for operations on the cervix uteri (R. Ellis) . . . . . ix, 88

TENTS, carbolised and defects of ordinary sponge (R. Ellis) . ix, 121
„ intra-uterine spring (J. H. Aveling) . . . vii, 155
„ medicated, instruments for the application to the interior of the cervix of (L. Tait) . . . . . xiv, 323
„ sponge (A. Lawrence) . . . . xxxi, 333
„ of common sea-tangle, abortion procured by (W. E. Pritchard) v, 198
„ uterine, new form of laminaria (R. Greenhalgh) . . vii, 72
„ the use of laminaria (W. Sinclair) . . . xlviii, 185
„ introducer, laminaria (R. Barnes) . . . vii, 207
„ uterine (A. Wiltshire) . . . . . viii, 149

TERATOMA of the fœtal head (H. S. Stannus) . . xliv, 78
„ see also *Monsters*.

TESTIS, chorion-epithelioma (the so-called deciduoma malignum) and the occurrence of chorion-epitheliomatous and hydatidiform mole-like structures in tumours of (J. H. Teacher) . xlv, 256

TENANUS after abortion (A. Wiltshire) . . . xiii, 133
„ *see Trismus.*
TETANY in pregnancy (W. R. Dakin) . . . xxxiii, 163
THANE (G. D.), monster . . . . . vii, 227
THERAPEUTICS of gynæcology, the constant current in (J. Shaw) . . . . . xxx, 243, 265
„ uterine (H. E. Eastlake) . . . . viii, 6
THIN (GEORGE), histological observations and remarks on lupus . xxvii, 315
THOMAS (GAILLARD), see *Playfair, W. S.*
THOMPSON (CHAS. ROBERT), complete rupture of perineum . xix, 265
THOMPSON (JOSEPH), umbilical hernia . . . x, 9
THOMPSON (J. A.), wax model of successful vaccination with lymph from a secondary vaccination . . . xiii, 94
„ description of a cyclopean monster . . . xv, 35
„ complication in the delivery of an ascitic fœtus . . xvii, 4
„ — *report* on ditto by committee (John Williams and J. A. Thompson) . . . . . xvii, 66
„ note on the treatment of chlorosis and anæmia with the phosphide of zinc . . . . . xvii, 57
„ congenital deformity in two children, and the maternal impressions to which the deformities were attributed . . xix, 94
THOMSON (ARNOLD), case of protracted pregnancy . . xxvii, 308
„ see *Godson, Clement.*
THOMSON (ARTHUR), sexual differences of the fœtal pelvis . xli, 279
THORACOPAGUS, see *Monsters.*
THORAX, transposition of the greater part of the abdominal viscera into the left cavity of (H. W. Bailey) . . . x, 6
THORBURN (JOHN), remarks in the discussion on the use of forceps xxi, 146
„ midwifery forceps with simple method of increasing its compressive power . . . . . xxi, 162
THORNE (MAY), uterus showing malignant villous tumour and a fibroid which has undergone sarcomatous change . . xlix, 181
THORNTON (J. KNOWSLEY), unilocular cyst involving both ovaries and with both Fallopian tubes attached . . . xxi, 119
„ uterine outgrowth removed during pregnancy; premature labour; death from obstruction of intestine . . xxi, 163
„ removal of uterine fibroids by laparotomy . . . xxii, 114
„ dermoid cyst of the left ovary . . . . xxiii, 104
„ ovarian tumour with the Fallopian tube adherent to the opposite ovary . . . . . xxiii, 258
„ case of extra-uterine fœtation removed by abdominal section xxiv, 51, 81
„ dermoid ovarian tumour . . . . xxiv, 80
„ ovaries and Fallopian tubes removed by oöphorectomy . xxiv, 137
„ case of extirpation of uterus and appendages for epithelioma of the cavity . . . . . xxv, 9
„ uterine fibro-myoma, removed by supra-vaginal hysterectomy xxv, 67
„ pyosalpinx . . . . . xxv, 139
„ hysterectomy for fibroid uterus . . . . xxv, 163
„ ovarian cyst highly congested from twisting of pedicle . xxv, 164
„ uterine fibroids and fibro-cystic tumour; hysterectomy . xxvi, 3
„ hæmatosalpinx, papillomatous ovarian cyst, abdominal section xxvi, 4
„ fibro-cystic myoma of the uterus . . . . xxvi, 54

THORNTON (J. KNOWSLEY) (*continued*)—
„ uterine fibroids with multilocular ovarian cysts and broad ligament cyst . . . . . xxvi, 55
„ vascular fibro-myoma of the uterus . . . xxvi, 269
„ case of removal of both ovaries for dermoid cysts during pregnancy . . . . xxvii, 46; xxviii, 41
„ malignant dermoid ovarian cyst . . . . xxvii, 194
„ fungating papillomata of both ovaries . . xxviii, 38
„ for *James Craig*, ruptured Fallopian tube . . . xxxi, 198
„ two uterine fibro-cysts . . . . . xxxi, 199
„ see *Malcolm, John D.*

THROMBOSIS, fatal cardiac, and septicæmia following a case of abortion (J. T. Musgrave) . . . . . xxi, 81
„ in the cerebral veins in a case of ingravescent hemiplegia during pregnancy and parturition (P. Horrocks) . . xxxiii, 201
„ and embolia of lying-in women (R. Barnes) . . iv, 30
„ of right heart and pulmonary arteries, death from, in a case of tedious labour (W. Martyn) . . . . x, 263
„ puerperal (W. S. Playfair) . . . xvi, 42, 89
„ of the pulmonary artery in the puerperal state, note on the absorption of (W. S. Playfair) . . . . xxvi, 162

THROMBUS, vaginal (R. Jalland) . . . . xiv, 43

THYROID EXTRACT, forty-one cases of puerperal eclampsia treated by (A. J. Sturmer) . . . . . xlvi, 126

TILT (E. J.), treatment of sickness in uterine inflammation and diseases of menstruation . . . . iii, 15
„ ready-made plasters . . . . . v, 41
„ extreme surgical tendencies of uterine pathologists, and on the division of the cervix uteri . . . . viii, 262
„ irritable uterus . . . . . x, 199
„ diagnosis of the least known varieties of uterine inflammation xiii, 197
„ inaugural address as President . . . . xv, 30
„ progress of pelvic pathology during the last twenty-five years xv, 87
„ diagnosis of subacute ovaritis . . . . xv, 202
„ annual address as President . . . xvi, 13; xvii, 24
„ for *Campbell Maclean*, fœtus with placenta attached to the head xvi, 124
„ lymphangitis in pelvic pathology . . . . xvi, 130
„ ladies' garment suspender . . . . xvi, 202
„ remarks in the discussion on puerperal fever . . xvii, 204

TIMES (H. G.), large fibrous tumour of the womb . . ii, 33
„ fœtus with encephalocele . . . . xiii, 51

TIRE-TÊTE, or combined perforator and extractor (G. R. Sheraton) ix, 111

TISSUE, fibroid, formed around a needle and removed from the left labium majus (H. Briggs) . . . . xlix, 223

TOMLINSON (R. S.), tuberculosis of the uterus . . . v, 174

TORSION, acute, of an ovarian pedicle, from a case where there was chronic torsion of the pedicle of a tumour of the opposite ovary (A. Doran) . . . . . xliii, 12
„ of the pedicle in hydrosalpinx, and other morbid conditions of the Fallopian tube (R. H. Bell) . . . . xlvi, 152
„ of the pedicle of a hydrosalpinx (H. Williamson) . . xlvii, 5

TOWELS, ladies' sanitary (A. L. Galabin) . . . xxii, 188
„ improved sanitary (A. L. Galabin) . . xxxvii, 227

TRACHÉLO-RAPHÉ, or Emmet's operation, notes on (W. S. Playfair) . . . . . xxiv, 54
TRACHEOTOMY in croup (F. C. Cory) . . . xi, 78
TRACTION by the lower jaw in head-last cases (J. Matthews Duncan) . . . . . xx, 61
TRACY (R. T.), short history and description of the Lying-in Hospital and Infirmary at Melbourne, with some account of what has been done in it . . . . . xii, 349
TRANSFUSION apparatus, Münchmeyer's (J. Matthews Duncan) . xxxii, 5
„ — (P. Horrocks) . . . . . xxxiv, 460
„ — (C. E. Jennings) . . . . . xliii, 146
„ — presented (Professor Casella) . . . . xvii, 45
„ — for the performance of (G. Hewitt) . . . vi, 136
„ — portable (W. Walter) . . . . xxvi, 182
„ — for immediate (J. H. Aveling) . . . . xiv, 101
„ immediate (J. H. Aveling) . . . . vi, 126
„ bottle, etc., for injection of saline fluid (H. R. Spencer) . xxxv, 428
„ of blood (J. Roussel) . . . . . xviii, 280
„ — its history, and application in cases of severe hæmorrhage (C. Waller) . . . . . i, 61
„ best mode of opening the vein in (J. H. Aveling) . . xv, 164
„ *report* of experimental inquiry instituted to determine with what fluids, and by what methods, the operation of, may best be performed, and to ascertain the effects, immediate or remote, of the operation in animals (E. A. Schäfer) . xxi, 316
„ use of saline, in treatment of puerperal eclampsia (E. W. Hey Groves) . . . . . xliii, 117, 148
„ of milk, the effects of, in animals (E. A. Schäfer) . . xxi, 320
TRANSPOSITION of the greater part of the abdominal viscera into the left cavity of the thorax (H. W. Bailey) . . x, 6
TREATMENT of ovarian prolapse by shortening the ovarian ligament (V. Bonney) . . . . . xlviii, 339
TREND (H. G.), funis presentations . . . . x, 1
TRENHOLME (E. H.), irregular uterine contraction . . xiv, 231
TRESTRAIL (H. ERNEST), the treatment of rigid perineum, and the avoidance of its rupture . . . . xvii, 61
„ case of mylacephalous acardiac twin . . xxxi, 2, 4
TRIPLET FŒTUSES (J. G. Westmacott) . . . xiii, 95
TRIPLETS (C. H. F. Routh) . . . . ix, 156
„ placenta from a case of (A. L. Galabin) . . . xxiii, 129
„ placentæ and membranes from a case of (P. Horrocks) . xxvi, 160
„ case of, and complete placenta prævia in which the children were delivered alive through a perforation in the first placenta (H. R. Spencer) . . . . xxxv, 107
„ at upwards of eight months of pregnancy (W. Martyn) . xi, 208
TRISMUS NASCENTIUM, case of (Leith Napier) . . xix, 5
TROCAR AND CANNULA for tapping and withdrawing cysts in ovariotomy (G. C. P. Murray) . . . . viii, 313
„ exploring needle (P. Smith) . . . . xii, 271
TROUGH, india-rubber speculum (A. W. Edis) . . . xvii, 49
TROUNCER (J. H.), induction of premature labour in a case of distorted pelvis . . . . . i, 236

TRUMAN (E. B.), extra-uterine fœtation . . . vii, 164

TRUSS, uterine (Mr. de Berdt Hovell's), for post-partum hæmorrhage (R. Barnes) . . . . . xiii, 129

TRUSTEES, alteration of laws respecting the duties of the xix, 16; xxxii, 106

TUBAL DISEASE, the relation of hydroperitoneum to (Alban Doran) . . . . . xxviii, 229, 243

„ see *Fallopian tubes.*

TUBAL GESTATION, see *Pregnancy*, extra-uterine (tubal).

TUBE, glass injection (R. Barnes) . . . . . xxvi, 232

„ new form of, for injecting the uterus after labour or abortion (T. C. Hayes) . . . . . xx, 58

„ vulcanite, to facilitate the injection of perchloride of iron or iodine into the uterus (F. Barnes) . . . xx, 60

„ see *Fallopian tubes.*

TUBERCULAR DEPOSITS, uterine appendages the subject of (W. Duncan) . . . . . xxxii, 306

TUBERCULAR DISEASE of the Fallopian tubes and ovaries (A. W. W. Lea) . . . . . xlv, 133

„ of uterus (S. W. Wheaton) . . . . xxxiii, 29

TUBERCLE, great distension of the Fallopian tubes from, in fibroid tumours of the uterus (P. Horrocks) . . . xlii, 166

„ of uterus (P. Horrocks) . . . . . xliv, 141

„ — (H. Williamson) . . . . . xliv, 141

„ uterus and appendages affected with (W. R. Dakin). . xxxiii, 3

TUBERCULOSIS (probably primary) of the body of the uterus in an adult (J. Bland-Sutton) . . . . xlvii, 72

„ of cervix (E. O. Croft) . . . . . xliv, 142

„ — primary, of the cervix simulating cancer, and treated by vaginal hysterectomy (A. H. N. Lewers) . . . xliv, 144

„ — — further note (W. H. B. Brook) . . . xlvi, 265

„ primary, of the cervix uteri (E. E. Young) . . xlviii, 286

„ — — for which vaginal hysterectomy was performed (W. H. B. Brook) . . . . . xlv, 185

„ of cervix and Fallopian tubes (W. W. H. Tate) . . xlvi, 138

„ of Fallopian tube (W. S. A. Griffith) . . . xxviii, 66

„ of the Fallopian tubes and uterus in cases of phthisis (P. D. Turner) . . . . . xli, 359

„ of the ovary and Fallopian tube, microscopical sections of (C. H. Roberts) . . . . . xlv, 92

„ of the uterus (R. S. Tomlinson) . . . . v, 174

„ — and appendages (P. D. Turner) . . . xli, 344

TUBO-OVARIAN ABSCESS, see *Abscess*, tubo-ovarian.

TUBO-OVARIAN CYSTS, see *Cysts*, tubo-ovarian.

TUBO-OVARIAN GESTATION (E. J. Maclean) . . . xxxv, 106

TUMOURS, adenoma of the labium (H. Williamson) . . xlviii, 235

„ — of the uterus (T. W. Eden) . . . . xlii, 2

„ — cystic, of the cervix (W. S. A. Griffith) . . xxx, 4

„ adrenal, of the kidney, malignant vaginal polypus secondary to (A. Doran). . . . . xlix, 182

„ angioma of labium (J. Matthews Duncan) . . . xxvi, 118

„ calcified, of uncertain origin removed by laparotomy from Douglas' pouch (A. H. N. Lewers) . . . xlvii, 151

„ cancerous, commencing in the outer cellular tissue of the broad ligament (T. C. Hayes) . . . xvi, 101, 102, 127

TUMOURS (*continued*)—
„ cephalhæmatomata, bilateral (S. W. Wheaton) . . xxxv, 6
„ — double, infant suffering from (J. Brunton) . . xx, 293
„ chorio-endothelioma of uterus; intra-peritoneal hæmorrhage; hysterectomy; death (A. Doran, for the late *Dr. G. Bagot Ferguson*) . . . . . xlix, 57
„ chorion-epithelioma of the uterus, with secondary growths in the vagina, lungs, and the liver (G. F. Blacker) . . xlvi, 55
„ colloid, a large conglomerate of, grown from the omentum (R. Barnes) . . . . . xvii, 216; xviii, 193
„ congenital, at the internal os uteri, causing hydrometra in new-born children (H. R. Spencer) . . . xl, 332
„ — encephaloid, not impeding delivery (S. Wells) . . ii, 27
„ cranial blood-swelling (E. Rigby) . . . i, 231
„ cystic, in connection with the right Fallopian tube, arising probably from an accessory Fallopian tube (R. H. Bell) . xlvi, 21
„ — of both ovaries (J. Knowsley Thornton) . . xxvi, 269
„ — pregnancy after removal of both ovaries for (A. Doran) xliv, 231
„ — of neck of uterus (A. H. N. Lewers) . . xxxviii, 106
„ embryoma of anterior mediastinum in a male adult (J. Ritchie) . . . . . xlv, 250
„ — malignant, of the ovary (H. T. Hicks and J. H. Targett) . . . . . xlvii, 287
„ endothelioma of uterus (M. A. D. Scharlieb) . . xlvii, 281
„ large fibro-cellular (Wm. Duncan) . . . xxv, 212
„ fibro-enchondromatous complicating pregnancy; safe delivery (A. Wiltshire) . . . . . xii, 376
„ fibro-cystic, of uterus (A. C. Butler-Smythe) . . xxix, 350
„ — — (J. Knowsley Thornton) . . . . xxvi, 3
„ — — (W. C. Swayne) . . . . . xliv, 369
„ — — removed by abdominal section (A. H. N. Lewers) . xxxvi, 270
„ — with carcinoma of left ovary and right Fallopian tube (R. Boxall) . . . . . xliii, 71
„ — — — after-history of (R. Boxall) . . . xlviii, 136
„ — — intra-ligamentous, weighing about 30 lb., removed by enucleation and subtotal hysterectomy (T. W. Eden and F. L. Provis) . . . . . xlviii, 264
„ — — laceration on its surface; free intra-peritoneal hæmorrhage (A. H. N. Lewers) . . . . xlvii, 261
„ FIBROID, a large cystic (H. R. Andrews) . . . xlviii, 249
„ — showing cystic degeneration removed three weeks after labour (H. R. Andrews) . . . . xlviii, 247
„ — (R. Barnes) . . . . . vi, 101
„ — extra-uterine, successfully removed by gastrotomy (C. H. F. Routh) . . . . xvii, 216; xviii, 5, 145
„ — expelled spontaneously (R. Barnes) . . . vii, 113
„ — removed by enucleation and excision (R. Barnes) . vii, 55
„ — two cases of abdominal hysterectomy for, complicated by pregnancy; with specimens (F. N. Boyd) . . . xlvi, 106
„ — micrococci, in the substance of a decomposing (S. W. Wheaton) . . . . . xxxiv, 187
„ — solitary interstitial, removed by abdominal myomectomy (W. S. Handley and C. Lockyer) . . . xlv, 51
„ — two cases illustrating changes in, after the menopause (J. Bland-Sutton) . . . . . xlv, 105
„ — which filled the pelvic cavity, Cæsarean section followed by removal of (H. R. Andrews) . . . . xlviii, 313

TUMOURS (*continued*)—
„ FIBROID (*continued*)—
„ — unusual thickening of the endometrium in (A. W. Addinsell) . . . . . xli, 231
„ — complicating labour near term in a patient who had recovered without operation from ruptured tubal pregnancy (H. R. Spencer) . . . . . xlviii, 240
„ — necrobiotic (F. N. Boyd) . . . . . xlvi, 198
„ — — removed from a recently delivered patient aged 22 (J. S. Fairbairn) . . . . . xlvi, 194
„ — large retro-peritoneal, undergoing suppuration (C. H. Roberts) xli, 213
„ — in undeveloped cornu of an uterus unicornis; from a parous subject (A. Doran) . . . . . xli, 295
„ — sloughing, removed by hysterectomy (W. Duncan) xxxvii, 197
„ — complicating pregnancy and labour (A. Donald) . . xliii, 180
„ — rapidly growing in a patient aged 63 (A. L. Galabin) . xxxix, 229
„ — supposed myxomatous degeneration of (M. Handfield-Jones) . . . . . xxxiii, 461
„ — of broad ligament (F. N. Boyd) . . . xlvi, 348
„ — — weighing 4½ lb., with twisted pedicle (A. H. N. Lewers) . xliv, 364
„ — — weighing 44½ lb. (20 kilogrammes) removed by enucleation (A. Doran) . . . . . xli, 173
„ — — associated with an ovarian cyst (A. Doran) . . xliii, 260
„ — — after-history of, associated with an ovarian cyst reported in the forty-third volume of the Society's 'Transactions' (A. Doran) . . . . . xlix, 94
„ — of the cervix, calcareous (W. W. H. Tate) . . xli, 372
„ — calcified, lying free in the cavity of a fibro-myomatous uterus (J. H. Dauber) . . . . . xlix, 139
„ — two specimens of, associated with bleeding after the menopause (A. H. N. Lewers) . . . . xlix, 270
„ — cervical (F. J. McCann) . . . . xlviii, 178
„ — polypus of cervix (W. Duncan) . . . xxxvi, 114
„ — of uterus, wholly cervical, and characterised by profuse hæmorrhage (J. S. Fairbairn) . . . . xlv, 178
„ — — (A. L. Galabin) . . . . . xlv, 175
„ — — removed by abdominal hysterectomy by Doyen's method (H. R. Spencer) . . . . . xliii, 5
„ — of the ovary (C. H. Carter) . . . . xxiv, 139
„ — — removed by abdominal section (John Williams) . xxv, 35
„ — — with a papilliferous cyst (John Williams) . xxix, 247, 513
„ — — with observations on their pathological anatomy (J. S. Fairbairn) . . . . . xliv, 177
„ — of uterus (T. Chambers) . . . . xi, 31
„ — — (W. B. Woodman) . . . . vii, 26
„ — — (C. M. Carter) . . . . xiii, 167
„ — — (T. Chambers) . . xviii, 177; xxii, 159, 187
„ — — (F. H. Daly) . . . . . xviii, 65
„ — — (A. Wiltshire) . . . . . xix, 119
„ — — (F. H. Champneys) . . . . xxii, 185
„ — — (A. L. Galabin) . . . . . xxiv, 4
„ — — (G. E. Herman) . . . . . xxiv, 52
„ — — (W. A. Meredith) . . . . xxiv, 79
„ — — (Wynn Williams) . . . xxv, 46, 70
„ — — (A. Meadows) . . . . . xxv, 161
„ — — (J. D. Malcolm) . . . . . xxxvi, 200
„ — — (J. H. Galton) . . . . . xxxvi, 318

TUMOURS (*continued*)—
„ FIBROID (*continued*)—
„ — of uterus, large (P. Horrocks) . . . xxxvi, 193
„ — — removed from a patient aged 20 (H. R. Andrews) . xlvii, 154
„ — — absorption of (W. S. Playfair) . . . x, 102
„ — — — with a report of a suspected case (A. Doran) . xxxv, 250
„ — — in a state of calcareous degeneration (G. Roper) . xix, 255
„ — — calcified (John Williams) . . . . xvi, 125
„ — — — (M. Handfield-Jones) . . . . xxxv, 2
„ — — — with acute axial rotation (J. Bland-Sutton) . xlvi, 149
„ — — — in elderly women, removed by abdominal section (W. S. A. Griffith) . . . . xlviii, 17
„ — — with cancer (A. L. Galabin) . . . xlv, 102
„ — — — (Amand Routh) . . . xxxviii, 99
„ — — — of the body in a woman, aged 36, simulating (H. R. Spencer) . . . . xlvi, 235
„ — — — in the same (M. Handfield-Jones) . . xlvii, 337
„ — — (multiple), with carcinoma of the body (A. H. N. Lewers) . . . . xlvi, 266
„ — — complicated by cancer of the corporeal endometrium (J. Bland-Sutton) . . . . xlviii, 140
„ — — associated with carcinoma (A. L. Galabin) . xxxviii, 102
„ — — — of the cervix removed *post-mortem* from a patient on whom eight years previously the operation of oöphorectomy had been performed (G. F. Blacker) . . . xxxvii, 213
„ — — undergoing colloid degeneration (T. G. Stevens) . xxxvi, 225
„ — — cystic degeneration of (C. H. Carter) . . xxv, 108
„ — — — of the surrounding tissues (M. Handfield-Jones) . xlvi, 307
„ — — degenerated, threatening to rupture, removed by total abdominal hysterectomy (H. R. Spencer) . . . xlv, 378
„ — — myxomatous degeneration of (C. Godson) . . xxv, 140
„ — — entirely detached (Amand Routh) . . xxxviii, 388
„ — — with great distension of the Fallopian tubes from tubercle (P. Horrocks) . . . . xlii, 166
„ — — removed by enucleation fifteen days after delivery (R. Boxall) . . . . . xxxvi, 64
„ — — extirpation of uterus and both ovaries for (T. Chambers) . . . . . xxiii, 12
„ — — and fibro-cystic tumour (J. Knowsley Thornton) . xxvi, 3
„ — — gangrenous (J. Bland-Sutton) . . . xxxii, 171
„ — — — inversion of uterus caused by (G. E. Herman) . xxx, 226
„ — — — removed by abdominal hysterectomy (W. Duncan) . xxxvi, 181
„ — — myxomatous (M. A. D. Scharlieb) . . . xlix, 273
„ — — with a sarcomatous nodule in the centre (Amand Routh) xlix, 1
„ — — interstitial, causing retroflexion (C. Godson) . . xxiii, 63
„ — — — removed from a patient aged 26 (A. F. Stabb) . xxxix, 89
„ — — — from a case of placenta prævia centralis (R. Boxall). xl, 338
„ — — three cases of intestinal obstruction following operations for, with special reference to the choice of operation (W. W. H. Tate) . . . . xlvi, 391
„ — — with, undergoing mucoid change, successfully removed by abdominal hysterectomy with intra-peritoneal treatment of the stump (A. H. N. Lewers) . . . . xlii, 94
„ — — removed by intra-peritoneal hysterectomy (W. Duncan) xliii, 76
„ — — intra-uterine, intra-mural, and subperitoneal (G. G. Bantock) . . . xxiv, 47, 91, 301; xxv, 38; xxvi, 119
„ — — — removed by single-wire écraseur (G. C. P. Murray) . xi, 78

TUMOURS (*continued*)—
„ FIBROID (*continued*)—
„ — of uterus, intra-uterine, partly removed by écraseur, the remainder thrown off by disintegration (J. H. Davis) . x, 227
„ — — fibro-plastic, extensively adherent, removed by enucleation (J. H. Davis) . . . . . ii, 17
„ — — removal of, and subsequent pregnancy (Wynn Williams) xvi, 183
„ — — removed by hysterectomy (J. Knowsley Thornton) . xxv, 163
„ — — — by laparotomy (J. Knowsley Thornton) . . xxii, 114
„ — — suppurating (G. F. Blacker) . . . xlix, 100
„ — — case of locked, treated by supra-vaginal hysterectomy (W. A. Meredith) . . . . . xxx, 442
„ — — on locking, retroversion, and strangulation of, in the pelvic excavation (J. Matthews Duncan) . . . xxx, 435
„ — — with multilocular ovarian cysts and broad-ligament cyst (J. Knowsley Thornton) . . . . xxvi, 55
„ — — undergoing necrobiosis or red degeneration (A. H. N. Lewers) . . . . . xlviii, 173
„ — — obstructing labour in which Porro-Cæsarean hysterectomy with retro-peritoneal treatment of the stump was performed; with remarks upon the relative advantages of the modern Porro operation over the Sänger-Cæsarean in most other cases requiring abdominal section (A. Routh) . xlii, 244
„ — — uterus removed at eight and a half months of gestation by abdominal hysterectomy for (A. Routh) . . xliv, 41
„ — — which developed after both ovaries and tubes had been removed for independent disease (E. W. Hey Groves) . xlv, 136
„ — — removed by pan-hysterectomy (W. C. Swayne) . xlv, 140
„ — — complicating pregnancy (H. M. Madge) . . xiv, 227
„ — — — — treated by enucleation (W. Hankes Day) . xxvii, 158
„ — — — — multiple, fatal cerebral hæmorrhage in a case of (W. Duncan) . . . . . xxxii, 2
„ — — — — pan-hysterectomy during labour in the seventh month (J. Bland-Sutton) . . . . xlvi, 238
„ — — — delivery (W. S. Playfair) . . xix, 101; xxiii, 25
„ — — pregnant about three and a half months, with placenta prævia (J. Braxton Hicks) . . . . xvii, 298
„ — — — removed by operation (A. Doran) . . xlvi, 119
„ — — removed during pregnancy; premature labour; death from obstruction of intestine (J. Knowsley Thornton) . xxi, 163
„ — — expelled after delivery (F. H. Daly) . . xxviii, 170
„ — and pregnant uterus, removed by abdominal hysterectomy (P. Horrocks) . . . . . xlii, 242
„ — — œdematous, associated with pregnancy (A. L. Galabin) xxxvii, 286
„ — — — removed by abdominal hysterectomy (C. J. Cullingworth) . . . . . xxxv, 38
„ — — multiple, with deformed fœtus (A. Wiltshire) . xxiii, 163
„ — — non-capsulated, resembling retained placenta (J. Braithwaite) . . . . . xxiii, 182
„ — — of one-horned (A. Routh) . . . xxix, 2, 57
„ — — outgrowth from the fundus uteri (T. S. Wells) . xi, 73
„ — — with attached ovarian cyst (F. H. Daly) . xvi, 122, 202
„ — — with double ovarian cysts and ascitic fluid from peritonitis (A. W. Edis) . . . . . xx, 164
„ — — pedunculated (W. Duncan) . . . xxvi, 186
„ — — sloughing (W. Duncan) . . . . xxix, 250
„ — — — (H. R. Spencer) . . . xxx, 408

TUMOURS (*continued*)—
„ FIBROID (*continued*)—
„ — of uterus, sloughing, submucous (H. Gervis) . . xxv, 161
„ — — — of the left uterine cornu; abnormal relations (A. Doran and C. Lockyer) . . . . . xliii, 272
„ — — spontaneous extrusion of a large (W. S. A. Griffith) . xxxv, 38
„ — — submucous, presenting at the os uteri ten days after delivery: labour normal (G. Ernest Herman) . . xxxiii, 30
„ — — subperitoneal pedunculated (T. C. Hayes) . . xxxiii, 74
„ — — subperitoneal (A. Meadows) . . . xxv, 232
„ — — — (F. Wallace) . . . . xvii, 177, 276
„ — — showing the three forms of the disease, subperitoneal, interstitial, and submucous (G. C. P. Murray) . . xvi, 482
„ — — suppurating (S. Boyd) . . . . xliii, 172
„ — — soft, removed by hysterectomy (T. C. Hayes) . . xxxv, 186
„ — — voluminous (R. Barnes) . . . . vii, 228
„ — — situated in the anterior wall, which obstructed labour (R. Barnes) . . . . . v, 171
„ — — springing from the posterior lip (R. Barnes) . . iii, 211
„ — — clinically resembling sarcoma (W. R. Dakin) . . xl, 32
„ — of the vagina (G. E. Herman) . . . . xxii, 44
„ — — (A. H. N. Lewers) . . . . xxix, 299
„ — — (W. C. Swayne) . . . . xlv, 142
„ FIBROMA of the abdominal wall; increase during pregnancy (A. Doran) . . . . . xxxix, 42
„ — of broad ligament weighing 44 lb. 8 oz. successfully removed from a woman aged 28 (A. Doran) . . . xl, 295
„ — of the ovarian ligament (A. Doran) . . . xxxi, 200
„ — spontaneously enucleated (Amand Routh) . . xxxv, 409
„ — of the ovary (H. T. Rutherfoord) . . . xxxiv, 88
„ — (?) of the ovary (P. Horrocks) . . . xxxvi, 192
„ — of ovary (M. Handfield-Jones) . . . xxxvi, 343
„ — — (J. Crawford) . . . . xxxvi, 190
„ — — impaction, ascites, removal (A Doran) . . xxxix, 37
„ — — (C. J. Cullingworth) . . . . xxxix, 279
„ — — (F. N. Boyd) . . . . xliv, 176
„ — — (A. E. Giles) . . . . xliv, 360
„ — — (F. E. Taylor) . . . . xlvi, 280
„ — — pure (A. Doran) . . . . xliv, 172
„ — — one third of an inch in diameter (A. Doran) . xliv, 173
„ — — weighing 17 lb.; under observation for ten years (A. Doran) . . . . . xlvii, 421
„ — — undergoing calcareous degeneration (C. Hubert Roberts) xxxix, 8
„ — of the uterus (Heywood Smith) . . . xxiii, 262
„ — — on intermittent contractions of, and in pregnancy, in relation to diagnosis (J. B. Hicks) . . . xxxvi, 188
„ — — multiple, with carcinoma of body, removed by abdominal pan-hysterectomy (J. H. Dauber) . . . xxxix, 321
„ — — two, removed by intra-peritoneal hysterectomy (H. Macnaughton-Jones) . . . . . xxxix, 321
„ FIBRO-MYOMA and abscess (W. Duncan) . . . xxxi, 332
„ — removed by abdominal myomectomy in second month of pregnancy; labour at term (A. Doran) . . . xlvii, 426
„ — necrobiotic uterine, occurring in pregnancy (F. E. Taylor) xlvii, 333
„ — of broad ligament (W. A. Meredith) . . xxix, 249, 514
„ — — (M. Handfield-Jones) . . . . xxxv, 239
„ — soft, in the left broad ligament (R. Boxall) . . xxxv, 410

TUMOURS (*continued*)—
„ FIBRO-MYOMA (*continued*)—
„ — of the intra-abdominal portion of the round ligament of the uterus (H. R. Spencer) . . . . xlvi, 26
„ — of the cervix uteri, removed by abdominal pan-hysterectomy (W. A. Meredith) . . . . xlvi, 12
„ — — which had obstructed labour (W. Duncan) . . xxxv, 296
„ — cystic, of the uterus removed by posterior colpotomy (H. R. Spencer) . . . . xliii, 110
„ — solid, mesenteric, weighing 30 lb. (A. Doran) . . xlvi, 145
„ — of right ovary removed by abdominal section (C. H. Carter) xxix, 190
„ — of ovary (A. J. Sturmer) . . . xlv, 335, 370
„ — of uterus (R. Barnes) . . . . xxv, 68
„ — — (W. Walter) . . . . xxvi, 326
„ — — two specimens of, with axial rotation (W. A. Meredith) xxx, 80
„ — — from a case of Cæsarean section (P. Horrocks) . xxix, 98
„ — — degenerating, associated with a case of hæmatometra, treated by supra-vaginal hysterectomy (W. A. Meredith) . xxix, 422
„ — — attached to fundus of an irreducible inverted uterus (P. Horrocks) . . . . xxx, 196, 228
„ — — removed by hysterectomy (J. Knowsley Thornton) xxv, 67; xxvi, 269
„ — — on the advisability of removing the cervix in performing hysterectomy for (J. D. Malcolm) . . . xlix, 148
„ — — suppuration in, following premature delivery, treated by abdominal hysterectomy (W. Tate) . . . xlix, 54
„ — — causing intestinal obstruction and death two years after the menopause (C. J. Cullingworth) . . . xxxix, 282
„ — — complicating early ectopic gestation (? tubo-uterine) (C. J. Cullingworth) . . . . xxxix, 284; xl, 285
„ — — multiple, complicating a twin pregnancy (John Phillips) xxviii, 138
„ — — — (Leith Napier) . . . . xxxv 3
„ — — — large, removed by hysterectomy (Leith Napier) . xxxiv, 159
„ — — spontaneously enucleated during labour (W. R. Dakin) xli, 105
„ — — gangrene of an interstitial (C. J. Cullingworth) . xxxix, 281
„ — — œdematous subperitoneal, in right broad ligament removed by abdominal hysterectomy (C. J. Cullingworth) . xl, 302
„ — — pedunculated, of the broad ligament, with twisted pedicle (C. J. Cullingworth) . . . xxxvii, 222
„ — — double pyosalpinx associated with (W. S. Playfair) . xxxiii, 497
„ — — sloughing, occurring in a patient twenty years after the menopause (W. W. H. Tate) . . . xl, 303
„ — — — of the central part shortly after delivery (J. D. Malcolm) . . . . . xlvi, 15
„ — — undergoing sarcomatous degeneration (P. Horrocks) . xlvi, 184
„ — — — — change (W. S. A. Griffith and H. Williamson) . xlviii, 22
„ — of the vagina (J. Bland-Sutton) . . . xli, 100
„ — — (J. M. Munro Kerr) . . . . xliv, 130
„ — of the vestibule (J. Inglis Parsons) . . . xlviii, 184
„ fibro-sarcoma of chorion (A. L. Galabin) . . . xxvii, 107
„ — of the right ovary (M. Handfield-Jones) . . xxxi, 126
„ large fibrotic, with calcification of the arteries (J. S. Fairbairn) xlvii, 299
„ FIBROUS, impeding delivery (H. M. Madge) . . iv, 129
„ — of the cervix uteri (G. C. P. Murray) . . . vi, 184
„ — — obstructing labour, removed by enucleation . . xii, 273
„ — of the ovary, removed by ovariotomy (L. J. Martin) . xii, 302
„ — of both ovaries (C. J. Cullingworth) . . . xxi, 276

TUMOURS (*continued*)—
„ FIBROUS (*continued*)—
„ — of the uterus (C. H. Carter) . . . . xxiv, 2
„ — — (H. G. Times) . . . . . ii, 33
„ — — (T. H. Tanner) . . . . . iii, 11
„ — — illustrating a surgical operation for the cure of this affection (I. Baker Brown) . . . . i, 329
„ — — tubal pregnancy with (G. Harley) . . . i, 101
„ — — (W. G. Hewitt) . . . . . ii, 240
„ — — spontaneous sloughing; death from peritonitis (J. B. Hicks) . . . . . vii, 110
„ — — treated by surgical means (I. B. Brown) . iii, 67; vi, 21
„ — removal of, from fundus uteri (C. Godson) . . xxii, 111
„ — from anterior wall of vagina (R. Barnes) . . xiv, 309
„ "grape-like" sarcoma of the cervix uteri (H. Williamson) . xlvii, 119
„ intra-mural calcareous, impeding labour (Wynn Williams) . xvii, 172
„ intra-uterine, case of (F. H. Daly) . . . xviii, 222
„ — removal of (J. A. Tapson) . . . . xv, 247
„ of labium (J. B. Potter) . . . . xxvi, 228
„ expelled from the uterus during natural labour, along with microscopic sections (A. W. W. Lea) . . . xli, 2
„ lipoma removed from left labium majus (C. H. Carter) . xxxii, 6
„ — of the lumbar region, 4 lb. in weight, and of twenty years' growth (A. Doran) . . . . xxxix, 40
„ — retro-peritoneal, weighing 13 lb. 12 oz. (A. Doran) . xliv, 265
„ malignant, of omentum (G. D. Brown) . . . xviii, 24
„ — growths in the vagina and rectum, pregnancy complicated by (J. B. Potter) . . . . . xx, 110
„ of fœtal membranes (G. M. Bluett and G. E. Herman) xxix, 243, 512
„ of the mesometrium weighing 22 lb. (J. Bland-Sutton) . xli, 298
„ molluscum fibrosum of the labium majus (A. E. Giles) . xxxix, 231
„ multilocular ovarian (John Williams) . . . xxiv, 77
„ — (W. Duncan) . . . . . xxvi, 229
„ — ruptured secondary cyst in (A. Doran) . . . xxvi, 118
„ myo-fibroma, three specimens of (H. Gervis) . . xxv, 108
„ MYOMA of left broad ligament (W. Duncan) . . xxxi, 309
„ — of the uterus, its pathology and treatment (Lawson Tait) . xxv, 194
„ — — four cases of removal of, by abdominal section (Lawson Tait) . . . . . xix, 274
„ — — (F. J. McCann) . . . . . xl, 3
„ — — degenerating (W. Duncan) . . xxxvii, 147
„ — — soft, showing early cystic degeneration (J. H. Aveling) xxvi, 270
„ — — diffuse, non-capsulated (C. J. Cullingworth) . xxxvii, 143
„ — of cervix uteri (J. Bland-Sutton) . . . xxxix, 160
„ — — — (C. J. Cullingworth) . . . . xxxiv, 223
„ — — necrotic change in, occurring in a young subject (C. J. Cullingworth) . . . . xxxvii, 284
„ — — œdematous (W. Duncan) . . . xxxvii, 148
„ — — (R. H. O'Callaghan) . . . xxxvii, 201
„ — — in case of placenta prævia (J. Hickinbotham) . xxiii, 166
„ — — fibro-cystic (J. Knowsley Thornton) . . xxvi, 54
„ — — — septicæmia (H. A. Lediard) . . . xxvi, 193
„ — — undergoing red degeneration (W. F. V. Bonney) . xlv, 464
„ — and fibro-myoma of the uterus and allied tumours of the ovary (A. Doran) . . . . . xxx, 410
„ — invaded by carcinoma of the corpus uteri; hysterectomy (J. M. Munro Kerr) . . . . . xlvii, 191

TUMOURS (*continued*)—
„ MYOMA (*continued*)—
„ — polypoid, of the uterus (A. Lawrence) . . . xxxii, 366
„ — — — (W. R. Rogers) . . . . x, 94
„ — pure, of the ovary, with a microscopic section (A. Doran) . xliv, 168
„ myxo-fibroma of cervix uteri (A. L. Galabin) . . xxviii, 178
„ myxoma of the labium majus (M. Handfield-Jones) . . xlvii, 362
„ — of fundus uteri following vesicular mole (?) a myxoma of chorionic villi engrafted upon uterus (A. L. Galabin) . xlv, 241
„ showing the impossibility, in some cases, to diagnose between uterine and ovarian neoplasms (J. D. Malcolm) . . xxix, 249
„ orbital, in a hydrocephalic female fœtus with tumour of cheek, maldevelopment of neck, associated with hydramnios, necessitating interference with the pregnancy at the seventh month (H. S. Stannus). . . . . xliii, 304
„ OVARIAN (H. Oldham) . . . . . vi, 75
„ — (A. W. Williams) . . . . . x, 197
„ — (P. Smith) . . . . . xiii, 98
„ — (W. H. Harris) . . . . . xv, 58
„ — (A. Meadows) . . . . . xxv, 161
„ — axial rotation of, leading to strangulation and gangrene (L. Tait) . . . . . xxii, 86
„ — biloculated, complicated by a hæmatosalpinx (John Phillips) . . . . . xxviii, 89
„ — weighing 76½ oz., in a girl, aged 12½, terminating life suddenly by asphyxia . . . . . ii, 280
„ — with the Fallopian tube adherent to the opposite ovary (J. Knowsley Thornton) . . . . . xxiii, 258
„ — hydatids in omentum simulating (W. Newman) . . iv, 169
„ — treatment of labour complicated by (W. S. Playfair) . ix, 69
„ — obstruction of labour by (R. G. McKerron) . . xxxix, 334
„ — adjourned discussion on R. G. McKerron's paper on the obstruction of labour by . . . . xl, 8
„ — removed by ovariotomy (T. Spencer Wells) . . iii, 214
„ — appearance of thyroid-like structures in (R. Hamilton Bell) xlvii, 242
„ — with twisted pedicle (R. Barnes) . . . xxvi, 59
„ — suppurating (J. W. J. Oswald) . . . xvii, 168
„ — and uterus, non-malignant, sections of (W. S. A. Griffith) xxx, 302, 409
„ — adenoma, unusual example of rupture of (J. Bland-Sutton) xli, 98
„ — anomalous, associated with uterine fibroid (H. Macnaughton-Jones) . . . . . xl, 154
„ — bilateral, in a patient with chorio-epithelioma following hydatidiform mole (J. D. Malcolm, R. H. Bell, and C. Lockyer) . . . . . xlv, 483
„ — carcinomatous (J. S. Fairbairn) . . . . xliii, 208
„ — complicating pregnancy, cyst ruptured during examination; immediate laparotomy; recovery (W. Duncan) . xxxvi, 312
„ — containing corpus luteum (A. L. Galabin) . xxxviii, 101
„ — with greatly enlarged Fallopian tube (P. Horrocks) . xxxvi, 185
„ — hydrocele containing papillomata (J. Bland-Sutton) . xxxiv, 215
„ — papillomatous cyst (A. H. N. Lewers) . . . xxxiv, 462
„ — — cyst of, causing profuse ascitic effusion (A. Doran) . xxxiv, 149
„ — — cystoma, removed after double ovariotomy fifteen years previously (J. D. Malcolm) . . . . xxxv, 36
„ — — closely simulating a cystoma attached to the front of the bladder and quite separate from both ovaries (J. D. Malcolm) . . . . . xli, 226

TUMOURS (*continued*)—
„ OVARIAN (*continued*)—
„ — large, ruptured on the third day after labour (H. R. Spencer) . . . . . xliii, 224
„ — which had made its way between the layers of the meso-sigmoid, both broad ligaments, and the meso-cæcum (W. H. B. Brook) . . . . . xlv, 415
„ — obstructing delivery; posterior vaginal section and ovariotomy during labour; operation and delivery at one sitting; recovery (J. W. Taylor) . . . xliv, 275
„ — sarcoma of (P. Horrocks) . . xxxvi, 192; xliv, 94
„ — — (W. R. Dakin) . . . . xxxvi, 313
„ — — showing necrosis of central portion lying in an abscess cavity containing offensive pus (W. W. H. Tate) . . xli, 373
„ — — primary (J. A. Shaw Mackenzie) . . . xxxiv, 2
„ — cystic, of omentum simulating ovarian; removal; recovery (W. Duncan) . . . . . xxxvi, 264
„ — presence of sarcomatous tissue in the walls of (F. E. Taylor) . . . . . xlvii, 411
„ — simulated by a wandering spleen, which caused retroversion of the uterus (F. E. Taylor) . . . xlvii, 70
„ — large solid (J. D. Malcolm) . . . xxxviii, 166, 167
„ — solid (Leith Napier) . . . . xxxviii, 29, 32
„ — — with an attached cyst communicating with the left Fallopian tube (W. F. V. Bonney) . . . xliv, 92
„ — — removed from a woman, aged 36 (A. W. Addinsell) . xlii, 139
„ — small, removed by vaginal section from a patient who was about two months pregnant (J. W. Taylor) . . xliv, 297
„ DERMOID OVARIAN (J. Knowsley Thornton) . . xxiv, 80
„ — — (W. Duncan) . . . . . xxxi, 255
„ — — some specimens of (J. Bland-Sutton) xxxi, 333; xxxiv, 5
„ — — dentigerous bony plates from (A. Doran) . . xxxi, 86
„ — — with very long ovarian ligament on the left side (W. Rivers Pollock) . . . . . xl, 119
„ — — twisted pedicle (R. Boxall) . . xli, 5
„ — — bony girdle from (S. W. Wheaton) . . . xxxv, 4
„ — — cyst (A. L. Galabin) . . . xxxiv, 441
„ — — incarcerated, removed at the fourth month of pregnancy; delivery of a living child at term (H. R. Spencer) xl, 329
„ — — ruptured during delivery by forceps and version, with fatal result (H. R. Spencer) . . . . xl, 331
„ — — Cæsarean section, and removal of tumour at the end of the first stage of of labour (R. Boxall) . . . xl, 25
„ — — in the middle of pregnancy; manual elevation; removal a fortnight after delivery at term (H. R. Spencer) . . xl, 259
„ — — obstructing labour; manual elevation; removal seven months later (H. R. Spencer) . . . . xl, 22
„ — — — ovariotomy during labour (H. R. Spencer) xl, 14
„ — — obstructing labour; displacement of the tumour from the true pelvis and extraction of the child with forceps; removal of tumour five weeks later; recovery (J. M. Munro Kerr) . . . . . xliii, 145
„ — — infiltration of broad ligament with fat (J. Bland-Sutton) xxxiv, 7
„ — — with a twisted pedicle six inches in length (J. Bland-Sutton) . . . . . xlvi, 147
„ — — section of the wall showing giant cells (H. Williamson) xlvi, 299
„ malignant papilloma of uterus (Amand Routh) . . xxxix, 5

TUMOURS (*continued*)—
„ multilobular papilloma of the urethra (C. Lockyer) . . xlvii, 122
„ parovarian cyst, axial rotation of (Leith Napier) . . xxxiv, 124
„ solid pelvic (W. A. Meredith) . . . . xxix, 249
„ pelvic, case of labour complicated by, and convulsions (H. M. Madge) . . . . . xvii, 20
„ — obstructing delivery (E. Copeman) . . xii, 313
„ — two cases of enlarged wandering spleen forming (F. E. Taylor) . . . . . xlvi, 179
„ large pendulous uterine (R. Wise) . . . xli, 302
„ of the placenta (A. L. Galabin) . . xxiv, 241; xxvii, 107
„ — from a primipara (G. Roper) . . . . xix, 256
„ which had been protruded from the rectum during labour (R. Barnes) . . . . . xxi, 28
„ sarcoma of the uterus with inversion (J. H. Targett) . xxxix, 285
„ serous, in the occipital region (W. B. Woodman) . . vii, 158
„ solid (Leith Napier) . . . . xxxvii, 283
„ large, at the end of the spine, supposed spina bifida (P. Horrocks) . . . . . xxix, 57
„ of the testis, chorion-epithelioma (the so-called deciduoma malignum), and the occurrence of chorion-epitheliomatous and hydatidiform mole-like structure in (J. H. Teacher) . xlv, 256
„ tubo-ovarian cyst (M. Handfield-Jones) . . . xxxiv, 85
„ umbilical, formed by prolapse of Meckel's diverticulum (S. W. Wheaton) . . . . . xxxiv, 184
„ sections illustrating the structure of three different types of urethral caruncles (H. Williamson) . . . xlvii, 6
„ of the uterus (C. Carter) . . . . xxiv, 161
„ — complicating pregnancy (J. L. Worship) . . xiv, 305
„ — (C. E. Purslow) . . . . . xlvi, 269
„ from anterior wall of vagina (A. Meadows) . . x, 141
„ vaginal cystocele, new operation for (E. W. Hey Groves) . xlvii, 65
„ vascular (erectile), in the sheath of the funis in a new-born infant (F. Lawton) . . . . . vii, 210
„ villous, of the body of the uterus, in a woman aged 84; vaginal hysterectomy; recovery (J. Bland-Sutton) . xlix, 46
„ — malignant, uterus showing, and a fibroid which has undergone sarcomatous change (May Thorne) . . xlix, 181
„ see *Carcinoma, Cysts, Encephalocele, Epithelioma, Fibro-myoma, Hæmatoma, Meningocele, Myoma, Myxoma, Papilloma, Polypus, Sarcoma, etc.*

TURNER (J. S.), two specimens of ovarian dropsy . . x, 39
„ tubal pregnancy . . . . xvi, 30
„ hydronephrosis of the left kidney . . xxxviii, 103

TURNER (P. D.), tuberculosis of uterus and appendages . xli, 344
„ notes on tuberculosis of the Fallopian tubes and uterus in cases of phthisis . . . . . xli, 359

TURNER (W. A.), see *McCann, F. J.*

TURNING in cases of contracted brim (P. L. Burchell) . . xxv, 61
„ in cases of disproportion (A. H. M'Clintock) . . iv, 175
„ one of the causes of difficulty in, with remarks on the practice of amputating the procident arm (G. E. Herman) . . xxviii, 150

TWINS, ABORTION (J. C. Langmore) . . . iv, 133
„ abortion of, one emaciated and one acephalous (C. Godson) xvi, 100, 121

TWINS (*continued*)—
„ arrested development of one (A. W. Edis) . . . xxv, 213
„ one blighted, the other anencephalous (A. Meadows) . i, 51
„ case of, in which one died at an early period of pregnancy (A. W. Edis) . . . . . xvii, 211
„ conjoined, case of (Percy Boulton) . . . xxiii, 260
„ — double monster (C. Godson) . . . xx, 171; xxi, 88
„ — Marie-Rosa Drouin, description of (D. C. MacCallum) . xx, 120
„ — Rozalie and Josepha Blazet (W. S. Playfair) . . xxii, 265
„ — (Amand Routh) . . . . . xlii, 29
„ — (thoracopagus) (W. Duncan) . . . xxxvii, 198
„ entire full-time ovum in (R. Wise) . . . xlix, 147
„ tubular fœtation with (N. J. Haydon) . . . v, 75
„ short funis in both (J. B. Hicks) . . . . xxiii, 253
„ monster (P. Horrocks) . . . . xlvi, 183
„ mylacephalous acardiac (H. Page) . . . xxxiii, 302
„ observations and remarks on cases of (J. Brunton) . . xi, 67
„ placenta from, two cases of, prematurely expelled (A. W. Edis) . . . . . xx, 321, 322
„ two cases; the first child presented naturally, with the second there was placental presentation (J. Brunton) . . xii, 167
„ together with secundines, from a case of hydrops amnii (W. G. Hewitt) . . . . . xi, 37
„ uniovular (C. Lockyer) . . . . . xlvi, 191
„ hydramnion in cases of uniovial or homologous (T. Wilson) . xli, 235

TWIN-BEARING FAMILY, hereditary (J. B. Curgenven) . xi, 106

TWIN-FŒTUSES, smallpox in (H. Madge) . . . iii, 173

TWIN-LABOUR, difficult position of the heads during (T. Pollock) iii, 103

TWISTING of the funis (M. Handfield-Jones) . . . xxxi, 164
„ of pedicle in an incipient dermoid ovarian cyst (A. Doran) . xxiv, 133
„ — in an ovarian cyst (R. Barnes) . . . xxvi, 59
„ — — (J. Knowsley Thornton) . . xxv, 164; xxvii, 64
„ — — caused by hæmorrhagic effusion into (R. Barnes) . xxv, 160
„ see *Rotation*.

ULCERATION of the cervix uteri, cured by the application of styptic colloid (J. Wynne) . . . . . xi, 86
„ of lupus of the female degenerative organs, including perforations, pits, and excavations (J. Matthews Duncan) . . xxvii, 139
„ of wall of vagina caused by a pessary (T. C. Hayes) . . xvi, 30

ULCERATION (AND ULCERS), corroding, of the os uteri (John Williams) . . . . . xxvi, 60
„ — — further note on (John Williams) . . . xxvii, 300

UMBILICAL CORD in a state of cystic degeneration (C. Godson) xxiii, 180
„ double battledore placenta with a single, connected with one child (J. H. Davis) . . . . . ii, 273
„ two placentæ in which the blood-vessels ran along the membranes for some distance from the edge of the placenta, and then united to form the (W. H. Maberly). . . xix, 65
„ knotted (J. Brunton) . . . . xi, 54
„ peculiar knotted (G. C. P. Murray) . . . xi, 54
„ knot in, fœtus with placenta attached showing (C. Godson) . xxv, 66
„ placenta, fœtus, and membranes (R. Wise) . xxxviii, 166

UMBILICAL VEIN, phlebitis of, producing pyæmia and death, two cases of (G. Roper) . . . . . xix, 8

UMBILICUS, note on a condition observed in the navel cord of a young infant (John Williams) . . . . . xxvi, 199

URÆMIA, uterus, rectum, and left kidney from a woman who died from (W. Duncan) . . . . . xxxi, 255

URETERS, dilated in stillborn infants (C. N. Longridge) . xlix, 215
„ fatal dilatation of, in case of prolapsus uteri (J. J. Phillips) . xii, 276
„ pelvis of kidney, etc., in an infant, distension of (H. Gervis) . vi, 221
„ and bladder, dilatation of, from pressure, in an infant (W. McAdam Eccles) . . . . . xxxiv, 250
„ and kidney, with uterus, from a case of Cæsarean section (W. Duncan) . . . . . xxxiv, 127
„ and kidneys, congenital absence of (A. E. Giles) . . xxxiv, 129

URETHRA, female, abscess of (F. C. Cory) . . . xi, 65
„ chronic abscess of the female (G. E. Herman) . . xxviii, 181
„ calculi embedded in the female (J. Matthews Duncan) . xxiii, 109
„ in a child, myxo-sarcoma of (A. L. Galabin) . xxxviii, 120
„ diverticula of (A. Routh) . . . . xxxii, 69
„ absence of, in a fœtus with ascites (T. G. Stevens) . .xxxvii, 5
„ lupous stricture and atresia of (G. E. Herman) . . xxviii, 267
„ multilobular papilloma of (C. Lockyer) . . . xlvii, 122
„ stricture of, in women (G. E. Herman) . . . xxix, 27
„ and bladder, female, two cases of repair of (Lawson Tait) . xx, 88

URINE, blue; cyanuria (John Phillips) . . . xxxi, 256
„ complete incontinence of, cured by ventro-fixation of the uterus (H. Macnaughton-Jones) . . . . xl, 226
„ retention of, caused by pressure of a dermoid ovarian cyst (W. S. A. Griffith) . . . . . xxxi, 135
„ the occurrence of sugar in the, during the puerperal state (F. J. McCann and W. A. Turner) . . . xxxiv, 473
„ suppression of, after labour (R. G. McKerron) . . xliv, 97
„ and temperature in puerperal eclampsia (G. E. Herman) xxxii, 17; xxxiii, 315

UTERINE APPENDAGES, removal of, for chronic inflammatory disease (Lawson Tait) . . . . . xxix, 184
„ — for hydro- and pyosalpinx (Lawson Tait) . . xxiv, 157
„ — in cases of functional neurosis (W. S. Playfair) . . xxxiii, 7
„ right, and uterus unicornis removed from an epileptic subject (G. F. Blacker) . . . . . xlviii, 82
„ fibroid tumour which had developed subsequently to removal of both (E. W. Hey Groves) . . . . xlv, 136
„ showing cystic growths and tubal dilatation (T. C. Hayes) xxxiii, 4, 107
„ showing a hæmatosalpinx (Amand Routh) . . . xl, 306
„ the subject of tubercular deposits (W. Duncan) . . xxxii, 306
„ malignant growth involving the right (C. J. Cullingworth) . xl, 6
„ matted (W. C. Grigg) . . . . . xxxiii, 75
„ and uterus from a single woman (W. Duncan) . . xxx, 408
„ of the left side showing evidences of the rupture of the sac of an ovarian pregnancy (H. Gilford) . . . xliii, 24
„ see *Fallopian tubes, Hæmatosalpinx, Hydrosalpinx, Pyosalpinx.*

UTERINE APPLICATOR, Beck's (R. Barnes) . . . xix, 136

UTERINE BRUIT, observations on the (F. H. Champneys) . xxviii, 188

UTERINE CANAL, apparatus for dilating by continuous elastic pressure (Lawson Tait) . . . . . xxi, 291
UTERUS, congenital abnormality of, simulating retention of menses (J. Braxton Hicks) . . . . . xxii, 260
„ case of missed abortion, in which an early embryo in its amniotic sac was retained for eight months in the (W. Duncan) . . . . . xxxvii, 196
„ abscess in (W. F. Victor Bonney). . . . xlvi, 2
„ — of, developing during the puerperium; rupture into the peritoneal cavity; abdominal section; recovery (A. W. W. Lea) . . . . . xlvi, 7
„ absence of, and occlusion of the vagina (F. Bousquet) . xxvii, 123
„ case of apparent absence of (G. Mowat) . . . xx, 289
„ adeno-carcinoma of, and left ovary removed by abdominal section (W. Duncan) . . . . . xxxix, 289
„ affected with adeno-carcinoma of the body in an early stage, with microscopical sections (E. W. Hey Groves) . . xlv, 138
„ adenoma of (T. W. Eden) . . . . xlii, 2
„ adenoma malignum of the body of (C. H. Roberts) . . xlv, 86
„ adeno-myoma of (F. E. Taylor) . . . . xlvi, 188
„ — two cases of diffuse (W. W. H. Tate) . . . xlvi, 141
„ — (C. Lockyer) . . . . . xlviii, 84
„ affections of, especially those accompanied with leucorrhœal discharge in their relations to phthisis pulmonalis (R. F. Battye) . . . . . viii, 237
„ amputation of forearm in (W. G. Hewitt) . . . xiii, 94
„ traumatic aneurysm of the artery of (W. G. Hewitt) . ix, 246
„ atrophy of, with large fibroid (F. H. Champneys) . . xxii, 185
„ avulsion of, post-partum (J. H. Walters) . . xxiv, 136; xxvi, 233
„ of a bitch, early gestation in both horns of (A. Routh) . xli, 5
„ of a bonnet monkey, sections from (A. W. Addinsell) . xli, 141
„ after Cæsarean section (R. Greenhalgh) . . . ix, 241
„ — segment of (W. S. A. Griffith). . . . xxix, 298
„ cancer of, successfully treated by bromine (A. W. Williams) . xii, 249
„ — curious case of (C. H. Roberts) . . . xlviii, 311
„ — the body of the, histology of (A. L. Galabin) . . xxiii, 161
„ — — (A. H. N. Lewers) . . . . xxxiv, 213
„ — — (M. Handfield-Jones) . . . . xl, 34
„ — — simulating fibroid in a woman aged 36 (H. R. Spencer). xlvi, 235
„ — the body, illustrating the difficulty of diagnosis between this disease and senile endometritis (G. E. Herman) . xxxiii, 31
„ cancerous disease of, in a patient in whom abortion was induced (F. W. Mackenzie) . . . . i, 11
„ extirpation of, for cancer (W. Duncan) . . . xxxiii, 157
„ independent cancer of the body and of the cervix (Amand Routh) . . . . . xxxviii, 100
„ cancerous (Amand Routh) . . . . xxxiv, 87
„ — (J. D. Malcolm) . . . . . xlvii, 10
„ — and gravid, removed *per vaginam* (W. S. Playfair) . xxxvii, 198
„ cancerous, and parovarian cyst removed *per vaginam* (A. Routh) xxxvii, 8
„ — removed by vaginal hysterectomy (P. Horrocks) . . xxxiv, 85
„ — — (H. T. Rutherfoord) . . . . xxxiii, 28
„ — with pyometra (A. H. N. Lewers) . . xxxviii, 14
„ appendages of, ligature and division of the upper part of both broad ligaments, and the result as compared with that following removal of (L. Remfry) . . . . xxxvi, 202
„ and appendages with ruptured pregnant tube (A. W. Addinsell) xli, 172

UTERUS (*continued*)—
„ cancer and fibro-myoma co-existing in the body of (M. Handfield-Jones) . . . . . xlvi, 305
„ uteri, two, removed by abdominal pan-hysterectomy for cancer of the body (A. H. N. Lewers) . . . xliv, 10
„ see also *Cancer*.
„ carcinoma of (W. S. Playfair) . . . . xxxix, 288
„ — the body of (W. S. Playfair) . . . . xii, 116
„ — — (J. H. Targett) . . . . . xlii, 281
„ — — with secondary growth in both ovaries (H. T. Hicks) xlviii, 196
„ body of, carcinoma of, invading a myoma; hysterectomy (J. M. Munro Kerr) . . . . . xlvii, 191
„ primary carcinoma of the body of (A. H. N. Lewers). . xxxvi, 374
„ removed by abdominal pan-hysterectomy for primary carcinoma of the body (A. H. N. Lewers) . . . xliv, 290
„ carcinoma of the cavity of (P. Smith) . . . xii, 299
„ — *report* on P. Smith's case . . . . xiv, 324
„ — in the muscular wall of, secondary to cancer of both ovaries (C. Lockyer) . . . . . xlvi, 302
„ carcinoma, body and multiple fibromata of, removed by abdominal pan-hysterectomy (J. H. Dauber) . . . xxxix, 321
„ with carcinoma of the body and multiple fibroids (A. H. N. Lewers) . . . . . xlvi, 266
„ keratinising carcinoma of the body (A. H. N. Lewers) . xlv, 97
„ carcinomatous, removed eighteen and a half years subsequent to double ovariotomy (A. C. Butler-Smythe) . . xliii, 214
„ carcino-sarcoma of (H. R. Spencer) . . . xlvii, 338
„ carcinoma of, see also *Carcinoma*.
„ cast of (T. W. Eden) . . . . . xlii, 5
„ decidual cast of, from a case in which there was no evidence of extra-uterine gestation; with microscopic sections (T. W. Eden) . . . . . xxxix, 132
„ — expelled after eight weeks' amenorrhœa, together with an ovum of about five days' growth (W. E. Fothergill) . xliii, 162
„ cast from, having all the characters of the decidual membrane found in connection with ectopic gestation, together with a small ovarian cyst from the same case, with microscopic sections of each (W. R. Dakin) . . . xxxviii, 385
„ of a cat, pregnant horn from (R. Wise) . . . xxxix, 260
„ the anatomical changes in, at the onset of labour and after delivery, sections of, demonstrating (A. H. F. Barbour) . xxviii, 73
„ on some changes in the, resulting from gestation (John Williams) . . . . . xx, 172
„ chorion-epithelioma of; lutein cysts in both ovaries (G. F. Blacker) . . . . . xlix, 104
„ chorion-epithelioma malignum, primary tumour in (J. H. Teacher) . . . . . xlv, 252
„ chorion-epithelioma of, with secondary growths in the vagina, the lungs, and the liver (G. F. Blacker) . . . xlvi, 55
„ removed by vaginal hysterectomy, showing nodule of chorio-epithelioma (F. W. N. Haultain) . . . xlv, 242
„ the circulation in the, with some of its anatomical and pathological bearings (John Williams) . . . xxvii, 112
„ condition of, in obstructed labour (J. B. Hicks) . . ix, 207
„ — at various periods after labour, description of a series of casts showing (A. Farre) . . . . xviii, 84
„ congestion of, relation between flexion and (John Williams) . xvi, 202

UTERUS (*continued*)—
„ contraction, inhibition, and expansion of (J. Matthews Duncan) xxviii, 91
„ contractions of, throughout pregnancy; their physiological effects and value in the diagnosis of pregnancy (J. B. Hicks) xiii, 216
„ irregular contraction of (E. H. Trenholme) . . xiv, 231
„ contraction, tonic, without completeness of retraction (J. Matthews Duncan) . . . . xxix, 369
„ — without retraction, accompanied by prolonged high temperature of nervous origin (G. E. Herman) . . xlviii, 204
„ cysts of, see also *Cysts*.
„ cystic tumour of (C. E. Purslow) . . . . xlvi, 269
„ removed by vaginal hysterectomy fourteen days after the operation of curetting and steaming had been performed (G. F. Blacker) . . . . xlv, 80
„ after death from a simple tapping (R. Barnes) . . vii, 207
„ deciduoma malignum of (J. R. Morison) . . . xlv, 249
„ deficient development of, atresia of the os externum, atrophy of the ovaries, insanity (A. Doran) . . . xxi, 253
„ after delivery at five months (H. Smith) . . . xiv, 67
„ diseases of, use of intra-uterine stems in (C. H. F. Routh) . xv, 252
„ — medicated pessaries in the treatment of (T. H. Tanner) . iv, 205
„ — use of nitrate of silver in (R. Ellis) . . . iv, 116
„ DISPLACEMENT, anteflexion of (T. C. Hayes) . xxii, 82; xxiii, 109
„ — — notes of a specimen of (W. S. A. Griffith) . . xxv, 3
„ — — and version of, pessary for (W. G. Hewitt) . . ix, 63
„ — — clinical remarks on a certain class of cases of (G. Roper) . . . . . xx, 304, 324
„ — — the relation of, to dysmenorrhœa (G. E. Herman) . xxiii, 209
„ — — treatment without intra-uterine stem (J. H. Galton) . xvi, 171
„ — — pessary for (W. S. Playfair) . . . xv, 124
„ — — shield for supporting a vulcanite stem pessary (A. W. Williams) . . . . . xv, 246
„ — — with hypertrophy and presence of an ovarian cyst (Graily Hewitt and A. Q. Silcock) . . . xxv, 131
„ — anteflexion of, gravid (W. G. Hewitt) . . . vii, 170
„ — anteversion of, new form of pessary for (A. L. Galabin) . xviii, 176
„ — by the distension of the bladder (J. B. Hicks and J. F. Goodhart) . . . . . xviii, 194
„ — or distortion of, report on sixty-seven cases treated at All Saints' Institution for Ladies (Graily Hewitt) . xxii, 173, 188
„ — on the relation between backward and painful menstruation (G. E. Herman) . . . . . xxiv, 161
„ — backward, menstruation in cases of (G. E. Herman) . xxxiv, 225
„ — — relation between, sterility and abortion (G. E. Herman) xxxiii, 499
„ — — — and prolonged hæmorrhage after delivery and abortion (G. E. Herman) . . . . . xxxiv, 14
„ — — on the frequency of the local symptoms associated with (G. E. Herman) . . . . . xxxv, 8
„ — flexions of (A. Meadows) . . . . x, 204
„ — — novel way of using the uterine sound in (A. Rasch) . xiii, 247
„ — — acquired, their causation and pathology (C. E. Squarey) . . . . . xiv, 344
„ — — relation between congestion and (John Williams) . xvi, 202
„ — — instrument to measure the amount of (Fancourt Barnes) xxiii, 177
„ — — new pessary and intra-uterine stem for the relief of (W. R. Jordan) . . . . . xvi, 125
„ — pessaries for (W. G. Hewitt) . . . . . x, 223

UTERUS (*continued*)—
„ DISPLACEMENT (*continued*)—
„ — use of wire loops, horseshoe wires, etc., for correcting (C. Clay) v, 177
„ — prolapse, cases of (A. Cordes) . . . . xvii, 63
„ — — the changes in the pelvic floor which accompany the slighter degrees of (G. E. Herman) . . . xxxi, 276
„ — — pessary for (R. Barnes) . . . . xix, 119
„ — — — (A. L. Galabin) . . . . xx, 169
„ — — multiple vesical calculi, the sequel of (A. L. Galabin) . xxii, 106
„ — — vesical calculi from a case of (A. Lawrence) . . xxx, 227
„ — retro-displaced gravid, three cases of incarceration of (J. M. Munro Kerr) . . . . xlii, 146
„ — retroflexion of (F. H. Champneys) . . . xxii, 156
„ — — as a frequent cause of abortion (J. J. Phillips) . xiv, 45
„ — — the gravid, during labour at term (H. Oldham) . i, 317
„ — — — diagnosis and treatment of (W. J. Sinclair) . xlii, 338
„ — — from a woman who died from the bursting of an aneurysm of a branch of the pulmonary artery (F. H. Champneys) . . . . xx, 124
„ — — caused by an interstitial fibroid (C. Godson) . . xxiii, 63
„ — — the unimpregnated, a new mode of treating certain cases of (J. Braithwaite) . . . . xix, 122
„ — — and ectopia viscerum (John Phillips) . . xxxiii, 490
„ — — of, in a new-born child (H. R. Spencer) . . xxxiv, 25
„ — retroversion (J. H. Davis) . . . . viii, 11
„ — — three cases of (R. Hardey) . . . . v, 267
„ — — elastic spring pessary for (R. Greenhalgh) . . x, 93
„ — — and prolapse of, pessary for (C. Godson) . . xxvi, 272
„ — — or retroflexion of the gravid (W. T. Smith) . . ii, 286
„ — — of the gravid (T. Chambers) . . . xvi, 181
„ — — (Max F. Simon) . . . . . xvi, 254
„ — — of the gravid, caused by gangrene of the bladder (A. Rasch) . . . . . xxxi, 129
„ — — — (H. Gervis) . . . . xvi, 232, 255
„ — — — tubal gestation simulating (A. E. Giles and E. J. Maclean) . . . . . xxxix, 232
„ — — caused by a wandering spleen simulating an ovarian tumour (F. E. Taylor) . . . . xlvii, 70
„ — displacement of unimpregnated, as a cause of displacement of the gravid organ (J. H. Aveling) . . . iii, 288
„ INVERSION of (J. W. S. Coward) . . . . ✓xii, 344
„ — (H. M. Madge) . . . . ✓xii, 347
„ — (T. Chambers) . . . . xvi, 180
„ — simulated by fibroid tumour (R. Barnes) . . iii, 211
„ — two cases of (W. Hickman) . . . ✓xix, 49
„ — after delivery, two cases, with remarks (W. T. Smith) . ✓x, 30
„ — after childbirth in a primipara, amputation by écraseur on account of hæmorrhage (J. H. Davis) . . . ✓xiv, 104
„ — chronic, reduction by sustained pressure (L. Tait) . xi, 174
„ — — which had existed for more than five years, without serious symptoms (W. B. Woodman) . . . ix, 52
„ — — successfully treated by sustained elastic pressure (W. R. Rogers) . . . . . xxiii, 19
„ — complete, occurring immediately after labour (F. H. Gervis) xvii, 278
„ — by a gangrenous fibroid (G. E. Herman) . . xxx, 226
„ — irreducible, with a fibro-myoma removed by amputation (P. Horrocks) . . . . xxx, 196, 228

UTERUS (*continued*)—
„ INVERSION (*continued*)—
„ — reduction (J. Braxton Hicks) . . . . xxxi, 340
„ — sixteen months' standing, replacement (W. Newman) . xxxi, 166
„ — repositor for (J. H. Aveling) . . . . xx, 126
„ — removal for (J. A. M. Moullin) . . . xxvi, 158
„ — spontaneous reduction (H. G. Shaw) . . . x, 35
„ — — (F. Ellington) . . . . . xix, 50
„ — (C. Godson) . . . . . xix, 51
„ — (Heywood Smith) . . . . . xix, 57
„ — (G. E. Herman) . . . . . xxvii, 83
„ — the puerperal, in the absence of the ovaries (John Williams) xxvi, 203
„ — spontaneous reposition of inverted (R. Boxall) . . xlvi, 292
„ — complete, of seven months' duration; failure of elastic pressure with repositors; operation of anterior vaginal cœliotomy, anterior hysterotomy, and replacement; recovery (J. W. Taylor) . . . . . xliv, 299
„ — acute of; spontaneous reposition (R. Boxall) . . xlvi, 292
„ — complete prolapse of (H. R. Andrews) . . . xlviii, 284
„ — complete, sarcoma of the body of (W. C. Swayne) . xliv, 366
„ — unusual (S. Boyd) . . . . . xlv, 170
„ distension of, in a fœtus impeding labour (H. Gervis) . v, 284
„ — by retained menstrual fluid, in a case of absence of vagina (C. H. Carter) . . . . . xxii, 251
„ dissection of, pregnant three and a half months, with placenta prævia and fibroids extensively developed in the walls of (J. Braxton Hicks) . . . . . xvii, 298
„ in puerperal eclampsia, the behaviour of (J. Braxton Hicks) . . . . . xxv, 118
„ from a patient aged 45, married, subject to eczema for three years (R. Barnes) . . . . . xvii, 216
„ elasticity, retraction, and polarity of (J. Matthews Duncan) . xxviii, 115
„ chronic axial rotation of an ovarian cyst giving rise to extreme twisting of the elongated (T. Wilson) . . . xxxix, 167
„ endothelioma of (M. A. D. Scharlieb) . . . xlvii, 281
„ removed for (?) malignant overgrowth of the endometrium (V. Bonney) . . . . . xlvii, 191
„ primary squamous-celled epithelioma of the body of (A. Doran) . . . . . xlv, 374
„ enlargements of, which follow abortions, premature, or natural confinements (S. Beck) . . . . viii, 54
„ epithelioma of, see also *Epithelioma*.
„ spontaneous evolution of the fœtus in, the head changed for the feet (R. Hodges) . . . . . ii, 303
„ cauliflower excrescence of (E. F. Fussell) . . . vi, 102
„ — of posterior lip of (A. Meadows) . . . viii, 258
„ in a case of extra-uterine pregnancy, communication between the cyst and the (A. L. Galabin) . . xvii, 170, 384
„ — of puerperal fever (S. Beck) . . . . vi, 186
„ — — (R. Barnes) . . . . . ix, 241
„ fibro-cystic disease of (C. H. F. Routh) . . . vii, 253
„ — — (J. B. Hicks) . . . . . xiv, 66
„ — — extirpation; recovery (T. Bryant) . . . xiv, 79
„ — — (T. Chambers) . . . xx, 32, 54; xxii, 159, 187
„ — — (Heywood Smith) . . . . xxvi, 58
„ — — mistaken for ovarian disease (C. H. F. Routh) . viii, 122
„ — tumour of (A. H. N. Lewers) . . . . xlvii, 261

UTERUS (*continued*)—
„ fibro-cystic tumour of, intra-ligamentous, weighing about 30 lb., removed by enucleation and subtotal hysterectomy (T. W. Eden and F. L. Provis) . . . . xlviii, 264
„ fibro-cysts of, see *Fibro-cysts.*
„ cystic fibroid of (W. C. Swayne) . . . . xliv, 369
„ fibroid of, undergoing cystic degeneration (P. Horrocks) . xl, 227
„ — showing the three forms of the disease, subperitoneal, interstitial, and submucous (G. C. P. Murray) . . . xvi, 248
„ — degeneration of, with subperitoneal and interstitial fibrous tumours (A. W. Edis) . . . . . xi, 34
„ — outgrowth from the fundus of (T. Spencer Wells) . xi. 73
„ — tumour springing from posterior lip of (R. Barnes) . iii, 211
„ — — situated in the anterior wall of (R. Barnes) . . v, 171
„ — — numerous (W. B. Woodman) . . . vii, 26
„ — — expelled spontaneously (J. B. Hicks) . . vii, 113
„ — — (T. Chambers) . . . . . xi, 31
„ — — absorption of (W. S. Playfair) . . . x, 102
„ — — complicating spontaneous rupture of ovarian cyst (P. Smith) . . . . . xiii, 39
„ — — (C. M. Carter) . . . . . xiii, 167
„ — — complicating pregnancy (H. M. Madge) . . xiv, 227
„ — pregnancy in the right cornu of (F. N. Boyd) . . xlix, 49
„ — submucous (D. L. Roberts) . . . . xiii, 309
„ — tumour with great distension of the Fallopian tubes from tubercle (P. Horrocks) . . . . xlii, 166
„ — associated with anomalous ovarian tumour (H. Macnaughton-Jones) . . . . . xl, 154
„ — undergoing mucoid change, successfully removed by abdominal hysterectomy with intra-peritoneal treatment of the stump (A. H. N. Lewers) . . . . xlii, 94
„ removed at eight and a half months of gestation by abdominal hysterectomy for fibroid obstructing labour (A. Routh) . . . . . xliv, 41
„ fibroid tumour and cancer of (Amand Routh) . xxxviii, 99
„ — — — in the same (M. Handfield-Jones) . . xlvii, 337
„ — — — (A. L. Galabin) . . . . xlv, 102
„ — — and carcinoma of the cervix removed *post-mortem* from a patient on whom eight years previously the operation of oöphorectomy had been performed (G. F. Blacker) xxxvii, 213
„ — calcified, with acute axial rotation (J. Bland-Sutton) . xlvi, 149
„ — with cystic degeneration of the surrounding tissues (M. Handfield-Jones) . . . . . xlvi, 307
„ — complicated by cancer of the corporeal endometrium (J. Bland-Sutton) . . . . . xlviii, 140
„ — degenerated, threatening to rupture, removed by total abdominal hysterectomy (H. R. Spencer) . . . xlv, 378
„ — tumour removed by pan-hysterectomy (W. C. Swayne) . xlv, 140
„ — — which developed after both ovaries and tubes had been removed for independent disease (E. W. Hey Groves) . xlv, 136
„ — — wholly cervical, forming an abdominal tumour, and characterised by profuse hæmorrhage (J. S. Fairbairn) . xlv, 178
„ — — intestinal obstruction following operations for (W. W. H. Tate) . . . . . xlvi, 391
„ with intestinal fibroid removed from a patient aged 26 (A. F. Stabb) . . . . . xxxix, 89
„ — from a case of placenta prævia centralis (R. Boxall) . xl, 338

UTERUS (*continued*)—
„ large fibroid tumour of, undergoing necrobiosis or red degeneration (A. H. N. Lewers) . . . . xlviii, 137
„ œdematous fibroid tumour of, associated with pregnancy (A. L. Galabin) . . . . . xxxvii, 286
„ with fibroids, pregnancy in; pan-hysterectomy during labour in the seventh month (J. Bland-Sutton) . . . xlvi, 238
„ — — removed at the fifth month (A. Doran) . . xliii, 178
„ — — — removed by operation (A. Doran) . . xlvi, 119
„ — with sarcomatous degeneration (P. Horrocks) . . xl, 178
„ — large solitary subperitoneal tumour of, with multiple fibroids (A. H. N. Lewers) . . . . xl, 327
„ — — suppurating (S. Boyd) . . . . xliii, 172
„ — — — (G. F. Blacker) . . . . xlix, 100
„ — with a sarcomatous nodule in the centre (Amand Routh) . xlix, 1
„ — see *Tumours* (fibroid).
„ fibroma and other morbid conditions of, treated by Apostoli's method (J. Inglis Parsons) . . . . xxxiv, 22
„ — small, showing sarcomatous changes(J. M. Munro Kerr) . xliv, 129
„ — see *Fibroma, Tumours* (fibroma).
„ — causing intestinal obstruction and death two years after the menopause (C. J. Cullingworth) . . . xxxix, 282
„ — of the intra-abdominal portion of the round ligament of (H. R. Spencer) . . . . . xlvi, 26
„ — relations of organic affections of the heart to (T. Wilson) . xlii, 176
„ — in a patient aged 23, with remarks on enucleation and myomectomy (A. E. Giles) . . . . xlii, 299
„ — incarcerated, in an unusually young subject (C. J. Cullingworth) . . . . . xlii, 132
„ — multiple (C. J. Cullingworth) . . . xxxviii, 6
„ — pedunculated subserous, which had undergone myxomatous and cystic degeneration (A. F. Stabb) . . . xlii, 133
„ — undergoing sarcomatous degeneration (P. Horrocks) . xlvi, 184
„ — undergoing sarcomatous change (W. S. A. Griffith and H. Williamson) . . . . . xlviii, 22
„ — with a calcified fibroid lying free in its cavity (J. H. Dauber) . . . . . xlix, 139
„ — sloughing of the central part of a, shortly after delivery (J. D. Malcolm) . . . . . xlvi, 15
„ — — occurring in a patient twenty years after the menopause (W. W. H. Tate) . . . . xl, 303
„ — two cases of, removed by operation (H. R. Spencer) . xl, 228
„ — with extensive carcinoma of body of, and fibroma of ovary (W. W. H. Tate) . . . . xlvi, 139
„ — degenerating, and sarcoma of (W. W. H. Tate) . . xlvii, 358
„ — — — further history of a case of (R. Hamilton Bell) . xlviii, 199
„ — large, removed by operation (W. W. H. Tate) . . xlviii, 183
„ — projecting into vagina, removed by abdominal hysterectomy (W. W. H. Tate) . . . . xl, 159
„ — associated with large cavity containing retained menses communicating with uterine canal (W. W. H. Tate) . xlvii, 360
„ — complicated with double salpingitis and carcinoma of cervix (W. W. H. Tate) . . . . xliii, 270
„ — showing marked cystic degeneration, removed from a patient aged 63, from whom both ovaries had been removed eleven years before (W. W. H. Tate) . . . xliii, 26
„ — cystic, removed by posterior colpotomy (H. R. Spencer) . xliii, 110

UTERUS (*continued*)—
„ fibro-myoma, cystic, complicating pregnancy; removal at four and a half months (J. Dysart McCaw) . . . xl, 256
„ — complicating early ectopic gestation (? tubo-uterine) (C. J. Cullingworth) . . . . . xl, 285
„ — — rupture of an early (fifteenth day) tubal gestation (E. Rumley Dawson) . . . . . xl, 155
„ — œdematous subperitoneal, in right broad ligament, removed by abdominal hysterectomy (C. J. Cullingworth) . . xl, 302
„ gangrene of an interstitial fibro-myoma of (C. J. Cullingworth) xxxix, 281
„ early ectopic gestation (? tubo-uterine) complicated by fibro-myomata of (C. J. Cullingworth) . . . xxxix, 284
„ fibro-myoma, see *Fibro-myoma, Tumours* (fibro-myoma).
„ large fibrotic, with calcification of the arteries (J. S. Fairbairn) xlvii, 299
„ four years after Cæsarean section (J. Bland-Sutton) . . xlix, 174
„ ventral fixation of, and its alternatives (G. E. Herman) . xlvii, 429
„ notes on the variation in height of the fundus of, above the symphysis during the puerperium, the conditions which influence this, and the practical conclusions which may be drawn from such observations (T. G. Stevens and W. S. A. Griffith) . . . . . xxxvii, 246
„ fibrous enlargement of, successfully treated by ergot of rye (J. Brunton) . . . . . xiii, 282
„ — polypus of (W. G. Hewitt) . . . . v, 123
„ — tumour of (H. G. Times) . . . . ii, 33
„ — — (H. M. Madge) . . . . viii, 105
„ — — enormous, connected with (W. G. Hewitt) . . ii, 240
„ — — (T. H. Tanner) . . . . . iii, 11
„ — — treated by surgical means (I. B. Brown) . iii, 67; vi, 21
„ — — complicating labour (W. O. Priestley) . . i, 271
„ — — spontaneous sloughing; death from peritonitis (J. B. Hicks) . . . . . vii, 110
„ — — attended by early pregnancy; retroversion of the uterus and retention of urine; death and decay of the fœtus and subsequently death of the mother from pyæmia (J. H. Davis) viii, 11
„ idiopathic gangrene of (Lawson Tait) . . . xxv, 248
„ fungoid granulations of, curette for removal of (J. M. Sims) . vii, 72
„ gravid, at full term (— Fitzpatrick) . . . xxi, 37
„ — peritoneal adhesions as a cause of post-partum hæmorrhage (W. G. Hewitt) . . . . . xi, 108
„ — excessive vomiting in early pregnancy, depending on the irritation of (W. T. Smith) . . . . i, 335
„ — forming exomphalos (G. C. P. Murray) . . . i, 77
„ from a case of severe uterine hæmorrhage and injection of perchloride of iron (R. Cory) . . . . xxi, 51
„ apparatus for injecting the, in cases of post-partum hæmorrhage (J. B. Potter) . . . . . xxi, 29
„ on plugging the, in severe cases of post-partum hæmorrhage (A. H. N. Lewers) . . . . . xxxii, 356
„ of a woman who died from post-partum hæmorrhage (G. E. Herman) . . . . . xx, 2
„ hydatids expelled from (W. G. Hewitt) . . . xii, 135
„ — (W. G. Hewitt) . . . . . xii, 237
„ congestive hypertrophy of, with anteflexion and presence of an ovarian cyst (Grailly Hewitt and A. Q. Silcock) . . xxv, 131
„ inflammation of, treatment of sickness in (E. J. Tilt) . iii, 15
„ injection of, after labour, apparatus for facilitating (R. Barnes) xix, 118

UTERUS (*continued*)—
„ injection of, after labour or abortion, tube for (T. C. Hayes) . xx, 58
„ tubes of vulcanite for the injection of perchloride of iron or iodine into the (F. Barnes) . . . . xx, 63
„ injury to, in the sixth month of pregnancy (T. Fairbank) . ix, 1
„ instrument for local applications to (F. E. Junker) . . xii, 244
„ internal surface of, after delivery (J. Matthews Duncan) . iv, 107
„ irritable (E. J. Tilt) . . . . . x, 199
„ — discussion on . . . . . x, 231
„ involution of, the effect of ergot on (G. E. Herman and C. O. Fowler) . . . . . xxx, 85
„ with kidneys and ureters, from a case of Cæsarean section (W. Duncan) . . . . . xxxiv, 127
„ laceration of (T. Radford) . . . . . viii, 150
„ lymphatics of, the comparative anatomy of (G. Hoggan) . xxiii, 4
„ MALFORMATIONS of, uterus bicornis (H. J. Paterson) . xlvii, 248
„ — bicornis unicollis, case of gestation in one horn of (H. C. Pope) . . . . . xxviii, 70, 72
„ — — — (W. F. V. Bonney) . . . . xliii, 77
„ — — bicornis, complete, with pregnancy of the right horn; turning and extraction on account of pelvic contraction (E. H. M. Sell) . . . . . xv, 180
„ — — — unicollis, pregnant (J. R. Ratcliffe) . . xxxiv, 469
„ — — — and double vagina (G. E. Herman) . . xx, 123
„ — bilocular (C. H. F. Routh) . . . . xii, 295
„ — didelphys, with observations on the clinical importance of this malformation (A. Giles) . . . xxxvii, 301
„ — — case of (M. Handfield-Jones) . . . xxix, 146
„ — — with double hæmatometra and complete absence of the vagina (A. H. N. Lewers) . . . xxxviii, 327
„ — — with cystic intra-ligamentous myoma (W. J. Gow) . xl, 134
„ — — with simultaneous gestation (H. Grace) . . iv, 138
„ — — delivery in a case of (Matthews Duncan) . . xxiii, 21
„ — — decidua or fleshy substance discharged from the unimpregnated side of (W. F. Cleveland) xxiii, 132, 181; xxiv, 297; xxvi, 117, 184, 331
„ — — retention of menstrual fluid in one half of (A. L. Galabin) . . . . . xxiv, 21
„ — — and double vagina, case of (H. Gervis) . . xix, 271
„ — — case of pregnancy with (J. Braxton Hicks) . xxiii, 23
„ — unicorned (G. E. Herman) . . . . xx, 60
„ — unilateral, and solitary kidney with two ureters (J. Braxton Hicks) . . . . . xxi, 57
„ unicornis and right appendages removed from an epileptic subject (G. F. Blacker) . . . . xlviii, 82
„ — fibroid in undeveloped cornu of (A. Doran) . . xli, 295
„ one-horned, malignant disease of cervix in (L. B. Aldrich-Blake) xlix, 269
„ malignant disease of, complicated with pregnancy (W. S. Playfair) . . . . . x, 58
„ — with numerous deposits in the lungs, and death following an abortion (J. D. Malcolm) . . . xxxviii, 125
„ — the body (H. Smith) . . . . xx, 4
„ — — diffuse (S. W. Wheaton for *W. Duncan*) . . xxxiii, 113
„ — unusual (M. A. D. Scharlieb) . . . . xlviii, 73
„ — see *Malignant disease.*
„ chronic infective metritis (A. W. Addinsell) . . xlviii, 144
„ fragment of membrane passed from (A. Doran) . xxxi, 229, 310

UTERUS (*continued*)—
„ mucous membrane of, in endometritis (A. L. Galabin) . xxii, 47
„ — in an infant suffering from uterine hæmorrhage (S. W. Wheaton) . . . . . xxxiv, 190
„ membrane expelled from, a few days before delivery at full term (A. Harris) . . . . . vii, 47
„ during menstruation (W. G. Hewitt) . . . viii, 220
„ from a subject who died the day menstruation commenced, microscopical sections of (R. Cory) . . . xx, 104
„ just before menstruation, with microscopic sections (W. S. A. Griffith) . . . . . xxiv, 138
„ of a woman, aged 55, who had had two miscarriages at the age of 39 (F. Wallace) . . . . xvii, 177, 276
„ carneous mole retained in, five months after death of embryo, showing proliferations of epithelium of villi as a syncytium forming reticulating processes (A. L. Galabin) . . xlv, 240
„ hydatid mole expelled from, immediately after a living fœtus and its placenta, at about six months' gestation (J. H. Davis) iii, 177
„ myoma of, its pathology and treatment (Lawson Tait) . xxv, 194
„ — abdominal hysterectomy for; with brief notes of twenty-eight cases (J. Bland-Sutton) . . . . xxxix, 292
„ — cystic, weighing over 15 lb. (A. Doran) . . xxxviii, 164
„ — diffuse (non-capsulated) (C. J. Cullingworth) . xxxvii, 143
„ — large interstitial gangrenous (C. J. Cullingworth) . xxxvi, 268
„ — submucous and interstitial, removed by hysterectomy (W. Duncan) . . . . . xxxix, 290
„ — small, necrotic change in, occurring in a young subject (C. J. Cullingworth) . . . . xxxvii, 284
„ — œdematous (W. Duncan) . . . xxxvii, 148
„ — undergoing red degeneration (W. F. V. Bonney) . xlv, 464
„ — three removed *per vaginam* by Doyen's method (W. J. Smyly) xli, 96
„ — three cases of, with bleeding after the menopause (H. R. Spencer) . . . . . xlviii, 333
„ — weighing 26 lb., successfully removed from a woman aged 74 (J. Bland-Sutton) . . . . . xli, 300
„ — weighing over 7 lb., removed from a woman, aged 22 (H. R. Spencer) . . . . . xlix, 219
„ — rotation and impaction of (J. Bland-Sutton) . . xli, 296
„ — see also *Myoma, Tumours.*
„ myxoma of fundus uteri following vesicular mole (?), a myxoma of chorionic villi engrafted upon (A. L. Galabin) . xlv, 241
„ removed by pan-hysterectomy for myxo-sarcoma (Amand Routh) xli, 139
„ supposed myxo-sarcoma of, removed by abdomino-vaginal method (Amand Routh) . . . . xli, 367
„ necrobiotic, associated with recent pregnancy (A. Doran and H. Williamson) . . . . . xlvi, 274
„ nulliparous, note on the *post-mortem* diagnosis of (A. Meadows) . . . . . xvii, 355; xviii, 69
„ — and multiparous, specimens and tables of measurement of (J. Braxton Hicks and A. W. Edis) . . xviii, 70, 74
„ instruments for operations on (Messrs. Weiss and Son) . vii, 157
„ three, removed by pan-hysterectomy (A. H. N. Lewers) . xli, 275
„ removed by pan-hysterectomy (A. H. N. Lewers) . . xxxix, 131
„ malignant papilloma of (Amand Routh) . . . xxxix, 5
„ removed at full term by intra-peritoneal hysterectomy in a case of contracted pelvis (W. Duncan) . . . xliii, 9
„ perithelioma of (G. F. Darwall-Smith) . . . xlix, 97

UTERUS (*continued*)—
„ showing placenta prævia (C. J. Cullingworth) . xxxii, 67, 107
„ with placenta prævia marginalis *in situ* (G. F. Blacker) . xxxvi, 194
„ polypus of (F. Elkington) . . . . i, 112
„ — (J. H. Davis) . . . . . i, 247
„ — (J. B. Hicks) . . . . . iii, 346
„ — (W. G. Hewitt) . . . . . iii, 350
„ — (H. Gervis) . . . . . xi, 4
„ polypi of, instrument for the removal of (W. T. Smith) . iii, 413
„ polypoid tumour of (W. R. Rogers) . . . x, 94
„ — see *Polypus.*
„ removed by Porro's operation (C. Godson) . . . xxiv, 299
„ from a case of Porro's operation with intra-peritoneal treatment of the stump (W. J. Gow) . . . xxxix, 7
„ portio vaginalis uteri, adenoma of, see *Tumours.*
„ ectopic pregnancy going nearly to term in the peritoneal cavity, the placenta being attached to the top of (G. E. Herman) . . . . . xxxix, 135
„ pregnancy in a rudimentary horn of (H. R. Andrews) . xlix, 209
„ pregnant, showing the behaviour of the, in chorea (J. Braxton Hicks) . . . . . xxxiii, 486
„ — and fibroid tumour removed by abdominal hysterectomy (P. Horrocks) . . . . . xlii, 242
„ fœtation in a rudimentary horn of (A. L. Galabin) . xxxvii, 225
„ full-term pregnancy in a rudimentary horn of; missed labour (five months); abdominal section and removal of sac; recovery (J. H. Targett) . . . . xlii, 276
„ congenital prolapse of, and imperforate rectum (H. R. Andrews) . . . . . xlii, 169
„ — associated with spina bifida (H. R. Andrews) . . xliv, 137
„ puerperal, primary infection by *Diplococcus pneumoniæ* of (A. G. R. Foulerton and W. F. Victor Bonney) . . xlv, 128
„ at different periods of the puerperium, showing complete absence of the alleged fatty changes, sections of (W. S. A. Griffith) . . . . . xxxi, 308
„ puncture of, *per rectum,* in a case of retained menses (I. B. Brown) . . . . . v, 162
„ punctured by rectum, in case of retained menses (I. B. Brown) iv, 21
„ see *Pyometra.*
„ double pyosalpinx associated with fibro-myoma of (W. S. Playfair) . . . . . xxxiii, 497
„ radiograph of fœtus in (Heywood Smith) . . . xlviii, 44
„ removed of, see *Abdominal section, Extirpation, Hysterectomy, Porro's operation.*
„ retention in, of the greater portion of a dead fœtus for four years (A. Halley) . . . . . ix, 90
„ retention of ovum within, in a case of abortion (W. G. Hewitt) iii, 411
„ RUPTURE of (H. Madge) . . . . . x, 97
„ — (G. Roper) . . . . . xx, 2
„ — (John Williams) . . . . . xx, 86
„ — (J. Hickinbotham) . . . . . xx, 96
„ — (F. H. Champneys) . . . . xxvi, 329
„ — (R. Cox) . . . . . xxviii, 225
„ — (J. G Swayne) . . . . . xxviii, 213
„ — (Robert Harvey) . . . . xxvii, 191, 228
„ — (Lovell Drage) . . . . . xxviii, 2
„ — (P. Horrocks) . . . . . xxxi, 228

UTERUS (*continued*)—
„ RUPTURE (*continued*)—
„ — after external violence (John Phillips) . . . xxxii, 375
„ — (R. Boxall). . . . . xxxiv, 11
„ — fatal case, occurring at the eighth month of pregnancy (R. Dunn) . . . . . ix, 65
„ — in about the seventh month of pregnancy, death from peritonitis (J. T. Mitchell). . . . . xi, 204
„ — (?) death and decomposition of the fœtus; blood poisoning; puncture of the membranes; recovery of the patient (R. Greenhalgh) . . . . . xi, 9
„ — occurring during labour (E. J. Asbury). . . x, 40
„ — (G. E. Herman) . . . . . xxxiii, 491
„ — (G. F. Blacker) . . . . . xxxvi, 316
„ — treated by abdominal hysterectomy (John Phillips) . xxxix, 260
„ — during unobstructed labour (with a microscopic section) (W. R. Dakin) . . . . . xl, 29
„ — with dermoid ovarian cyst the size of a child's head (A. H. N. Lewers) . . . . . xlii, 95
„ — at term through scar of old Cæsarean section; abdominal hysterectomy (J. H. Targett) . . . . . xlii, 242
„ spontaneous rupture of, in placenta prævia (J. P. Maxwell) . xliii, 217
„ four cases of rupture of, successfully treated by packing the tear *per vaginam* with iodoform gauze (H. R. Spencer) . xlii, 14
„ sarcoma of (W. S. A. Griffith) . . . . xli, 232
„ — (A. W. W. Lea) . . . . . xliii, 73
„ — (A. L. Galabin) . . . . . xliii, 226
„ — with inversion (J. H. Targett) . . . xxxix, 285
„ — with a microscopic section (H. R. Andrews) . . xlii, 210
„ primary sarcoma ("deciduoma malignum") in a patient, aged 24, treated by vaginal hysterectomy (A. H. N. Lewers) . xxxix, 246
„ — — of the body of (A. H. N. Lewers) . . . xl, 225
„ sarcoma of the body, with complete inversion (W. C. Swayne) xliv, 366
„ — — removed by vaginal extirpation (W. S. Playfair) . xxxvii, 200
„ — see also *Sarcoma*.
„ gangrenous sarcoma of, removed by abdominal hysterectomy from a patient suffering from glycosuria (W. W. H. Tate) . xliv, 165
„ showing malignant villous tumour and a fibroid which has undergone sarcomatous change (May Thorne) . . xlix, 181
„ frozen sections of, at the tenth week of pregnancy, showing hæmorrhages into the placenta, decidua reflexa, and decidua vera, from a patient who died of heart disease (G. F. Blacker) xlii, 235
„ microscopic sections of mucous membrane of (A. W. W. Lea) . xxxix, 322
„ — tissue removed from (A. L. Galabin) . . xxxviii, 121
„ microscopic sections, showing chorionic villi and doubtful sarcoma (L. Remfry) . . . . xxxviii, 223
„ from a septic case (C. Chepmell) . . . . xxxvi, 3
„ from a case of puerperal septicæmia (W. Duncan) . . xxxi, 202
„ septicæmic, with bacteriological investigation (C. Lockyer) . xliii, 304
„ structure of, and the changes the tissues undergo during pregnancy and after parturition . . . . xiii, 290
„ suppuration of the cavity of, resulting from occlusion of the cervix (A. L. Galabin) . . . . . xix, 176
„ suture for closing wound of, in Cæsarean section and for uniting wound to the abdominal wall (R. Barnes) . . xii, 364
„ tubal pregnancy with fibrous tumours of (G. Harley) . i, 101
„ tuberculosis of (R. S. Tomlinson) . . . v, 174

UTERUS (*continued*)—
„ tuberculosis of, in cases of phthisis (P. D. Turner) . . xli, 359
„ tubercle of (P. Horrocks) . . . . xliv, 141
„ — (H. Williamson) . . . . . xliv, 141
„ tubercular (A. W. Addinsell) . . . xlvii, 336
„ early tubercular disease of (S. W. Wheaton) . . xxxiii, 29
„ tuberculosis (probably primary) of the body of, in an adult (J. Bland-Sutton) . . . . . xlvii, 72
„ tumour of, complicating pregnancy (J. L. Worship) . . xiv, 305
„ tumours, see also *Tumours*.
„ — removed by new constrictor (J. Lazarewitch) . . xv, 63
„ tumour expelled from, during natural labour (A. W. W. Lea) xli, 2
„ body of, villous tumour of, in a woman, aged 84; vaginal hysterectomy (J. Bland-Sutton) . . . xlix, 46
„ wall of, secondary infection of the perivascular lymphatics of, to bilateral primary tuberculous salpingitis (C. Lockyer) . xlix, 141
„ with "fundal ligament" after hysteropexy (F. E. Taylor) . xlix, 265
„ with its contents at full term (J. Fitzpatrick) . . xxi, 37
„ removed by vaginal operation (S. W. Wheaton for *William Duncan*) . . . . . xxxiii, 113
„ and vessels concerned in phlegmasia dolens (R. Barnes) . x, 113
„ complete incontinence of urine cured by ventro-fixation of (H. Macnaughton-Jones) . . . . xl, 226
„ CERVIX UTERI, malignant adenoma (carcinoma) of (F. J. McCann) . . . . . xl, 2
„ — on the advisability of removing, in performing hysterectomy for fibro-myomatous uterine tumours (J. D. Malcolm) . xlix, 148
„ — amputation of (R. Greenhalgh) . . . vi, 102
„ — — (A. Meadows) . . . . viii, 39; xi, 102
„ — — supra-vaginal amputation for cancer (A. H. N. Lewers) xxxiii, 301; xxxvii, 201
„ — atresia of, with distension of uterus, and escape of menses between the walls of the vagina (G. Lowe) . . xxix, 401
„ — — of the vaginal orifice of, new operation for (V. de Saboia) xvi, 116
„ — use of fused anhydrous sulphate of zinc to the canal of (J. B. Hicks) . . . . . viii, 220
„ — two uteri removed by vaginal hysterectomy for cancer of, the disease being apparently at the same stage in each (A. H. N. Lewers) . . . . xxxviii, 164
„ — three cases of pyometra complicating cancer of (W. W. H. Tate) . . . . . xxxix, 323
„ — cancer of, associated with an adenomatous growth in the fundus (C. Hubert Roberts) . . . . xlii, 267
„ — — from eight cases treated by the supra-vaginal amputation, in which from four to fifteen years had elapsed without recurrence (A. H. N. Lewers) . . . . xliv, 221
„ — uterus and iliac glands removed by abdominal hysterectomy for cancer of (T. V. Dickinson) . . . xlviii, 15
„ — cancer of, complicating a case of combined vaginal and abdominal hysterectomy for a pregnancy of four and a half months (R. Sanderson) . . . . xliii, 312
„ — two cases of, the patients remaining free from recurrence twenty and eleven years respectively after operation (A. H. N. Lewers) . . . . . xlix, 179
„ — — supposed recurrence after vaginal hysterectomy for (C. Hubert Roberts) . . . . xlix, 114
„ — — pregnant, removed by pan-hysterectomy (F. N. Boyd) . xlvi, 345

UTERUS (*continued*)—
„ CERVIX UTERI (*continued*)—
„ — cancer of, complicating labour in advanced pregnancy, the patients remaining well eleven, eight and a half, and eight years after high amputation of (H. R. Spencer) . . xlvi, 355
„ — — treatment of epithelial (C, H. F. Routh) . . viii, 290
„ — — see also *Cancer*.
„ — carcinoma of, complicating labour at term; Cæsarean section, followed by vaginal hysterectomy (J. M. Munro Kerr) . xlvii, 194
„ — — in which the disease extended upwards into the body (W. W. H. Tate) . . . . . xl, 258
„ — squamous-celled, in which the disease had extended in an upward and not in a downward direction (C. J. Cullingworth) xxxiv, 136
„ — — squamous (F. J. McCann) . . . . xliv, 136
„ — — see also *Carcinoma*.
„ — chancre on (G. E. Herman) . . . . xxvii, 252
„ — on the change in size of the canal during menstruation (G. E. Herman) . . . . xxxvi, 250
„ — cystic degeneration of (H. Gervis) . . . xxvi, 144
„ — deformed, pregnancy after bilateral division of (G. Roper) xix, 169
„ — relative value of substances used in dilating (J. H. Aveling) ix, 264
„ — the dilatation of the canal of, for spasmodic dysmenorrhœa and sterility (C. Godson) . . xxiii, 277; xxiv, 6
„ — diseased (R. Greenhalgh) . . . . v, 199
„ — malignant disease of (G. Roper) . . . xxii, 85
„ — — complicating pregnancy (A. L. Galabin) . . xviii, 239
„ — — extensive, in which Cæsarean section was performed (A. L. Galabin) . . . . . xviii, 286
„ — — scoop for removing superficial portions of (Professor Simon) . . . . . xiv, 209
„ — — removal of (A. H. N. Lewers) . . . xxxii, 136
„ — — disease of, in one-horned (L. B. Aldrich-Blake) . xlix, 269
„ — — growth of, in a girl aged 18 (F. N. Boyd) . . xlvii, 313
„ — division of (E. J. Tilt) . . . . viii, 262
„ — extreme elongation of, in a case of labour (R. Barnes) . xviii, 293
„ — hypertrophic elongation of, at the full term of pregnancy (G. Roper) . . . . . xv, 167
„ — supposed endothelioma of (H. Russell Andrews) . . xlviii, 283
„ — epithelioma, removed by the écraseur where local anæsthesia by the ether spray was employed (E. Parson) . ix, 47
„ — squamous-celled epithelioma of, in a very early stage (W. S. A. Griffith) . . . . . xlii, 210
„ — with squamous epithelioma, removed in 1895; no recurrence in 1901 (A. H. N. Lewers) . . . . xliii, 266
„ — showing rapidly growing epithelioma of; death from recurrence five months after removal (C. Lockyer) . . xliv, 284
„ — three months' gravid, removed by vaginal hysterectomy of cervix for squamous epithelioma (W. Duncan) . . xliv, 297
„ — epithelioma of, see *Epithelioma*.
„ — erosions of, pathological anatomy of (A. L. Galabin) . xxii, 156
„ — fibro-adenoma removed from (G. F. Blacker) . . xli, 374
„ — calcareous fibroid of (W. W. H. Tate) . . . xli, 372
„ — three fibroid tumours of (A. L. Galabin) . . xlv, 175
„ — large, with cervical fibroid, removed by abdominal hysterectomy by Doyen's method (H. R. Spencer) . . xliii, 5
„ — fibro-myoma of, treated by abdominal hysterectomy (W. H. H. Tate) . . . . . xlv, 173

UTERUS (*continued*)—
„ CERVIX UTERI (*continued*)—
„ — fibro-myoma of, removed by abdominal pan-hysterectomy (W. A. Meredith) . . . . . xlvi, 12
„ — — removed by enucleation, followed by vaginal hysterectomy (W. W. H. Tate) . . . . . xlii, 161
„ — cystic fibro-myoma of (C. H. Roberts) . . . xlii, 211
„ — fibrous tumour of (G. C. P. Murray) . . . vi, 184
„ — — obstructing labour, removed by enucleation (J. B. Hicks) . . . . . xii, 273
„ — peculiar formation of (R. Barnes) . . . vii, 120
„ — ganglion cervicale uteri, the normal and pathological anatomy of (N. W. Jastreboff) . . . . xxiii, 266
„ — gangrene of vaginal portion of (G. E. Herman) . . xxix, 244
„ — growth removed from (R. Greenhalgh) . . . vii, 255
„ — hypertrophy removed by the wire-rope écraseur (R. Greenhalgh) . . . . . vi, 75
„ — non-evoluted and hypertrophied (G. Roper) . . vii. 233
„ — follicular hypertrophy of (G. E. Herman) . . xxii, 270
„ — instrument for dividing (R. Barnes) . . . vii, 72
„ — annular laceration of (T. H. Barker) . . . ii, 329
„ — laceration of, histological results of (A. L. Galabin) . xxiv, 53
„ — — bilateral, with ectropion, section from the anterior lip of (A. L. Galabin) . . . . . xxi, 312
„ — tubal mole complicating carcinoma of (A. H. N. Lewers) . xlv, 335
„ — myoma of (C. J. Cullingworth) . . . xxxiv, 223
„ — — (J. Bland-Sutton) . . . . xxxix, 160
„ — — large fibro-cystic of (C. J. Cullingworth) . xxxviii, 8
„ — myxo-fibroma of (A. L. Galabin) . . . xxviii, 178
„ — partial obstruction of, by distension (A. L. Galabin) . xxvii, 81
„ — occlusion of, with resulting suppuration of the uterine cavity (A. L. Galabin) . . . . . xix, 176
„ — new expanding speculum for operations on (R. Ellis) . ix, 86
„ — self-retaining tenaculum for operations on (R. Ellis) . ix, 88
„ — plan for cauterising (R. Barnes) . . . viii, 102
„ — sections of an adeno-myomatous polypus of (F. E. Taylor) . xlviii, 12
„ — peculiar mucous polypus of (R. G. McKerron) . . xxxix, 314
„ — — — (H. R. Spencer) . . . . xli, 383
„ — multiple myxomatous polypi from (W. Duncan) . xlii, 243; xliii, 75
„ — prolongation, excessive, of anterior lip (C. H. F. Routh) . xviii, 144
„ — rupture of, at the vaginal junction (A. Wiltshire) . xviii, 220
„ — sarcoma of (A. L. Galabin) . . . xxxviii, 120
„ — "grape-like" sarcoma fungating into, and infiltrating the walls of the vagina, in a child aged 12 months; extirpation of uterus and vagina (H. J. Curtis) . . xlv, 320
„ — — of (H. Williamson) . . . . xlvii, 119
„ — supposed sarcoma of (H. R. Andrews) . . . xlix, 137
„ — separation of the greater portion of, during labour (R. Gray) xvi, 128
„ — trachélo-raphé or Emmet's operation, notes on (W. S. Playfair) . . . . . xxiv, 54
„ — tuberculous disease of, and Fallopian tubes (W. W. H. Tate) xlvi, 138
„ — — primary (E. E. Young) . . . . xlviii, 268
„ — tuberculosis of (E. O. Croft) . . . . xliv, 142
„ — — primary, simulating cancer, and treated by vaginal hysterectomy (A. H. N. Lewers) . . . . xliv, 144
„ — — for which vaginal hysterectomy was performed (W. H. B. Brook) . . . . . xlv, 185; xlvi, 265

UTERUS (*continued*)—
„ CERVIX UTERI (*continued*)
„ — cystic tumour of (A. H. N. Lewers) . . xxxviii, 106
„ — ulceration of, cured by the application of styptic colloid (J. Wynne) . . . . . xi, 86
„ — volsella forceps for the soft dilated (R. Wise) . . xliii, 233
„ fundus uteri, fibroid polypus attached to (D. L. Roberts) . xi, 244
„ — removal of fibrous outgrowth from (C. Godson) . . xxii, 111
„ — injection to, for induction of premature labour (J. Lazarewitch) . . . . . ix, 161
„ — localised sloughing of, in a case of acute septicæmia following abdominal section (C. J. Cullingworth) . . xxx, 406
„ OS UTERI, chancre on (W. B. Woodman) . . . vii, 26
„ — submucous fibroid presenting at, ten days after delivery (G. E. Herman) . . . . . xxxiii, 30
„ — three cases of congenital tumour at the internal, causing hydrometra in new-born children (H. R. Spencer) . . xl, 332
„ — a new and speedy method of dilating a rigid os in parturition (J. Farrar) . . . . . xxxvi, 321
„ — corroding ulcer of (John Williams) . . xxvi, 60, xxvii, 300
„ — dilatation of, for chorea in pregnancy (W. F. Wade) . xxii, 244
„ — — digital, in labour (J. Braithwaite) . . . xxi, 38
„ — fibroid polypus pediculated to posterior margin of (J. H. Davis) . . . . . ix, 152
„ — internum, its anatomy, physiology, and pathology (J. H. Bennet) . . . . . xxv, 219
„ — ulceration of, with allongement of cervix uteri (G. C. P. Murray) . . . . . ix, 30
„ AND APPENDAGES, chronic septic infection of (A. Donald) . xlix, 6
„ — connected by adhesions to the large intestine (T. C. Hayes) . . . . . xvii, 45
„ — enveloped in a large amount of blood-clot and false membrane (T. C. Hayes) . . . . . xx, 119
„ — from a case of Cæsarean section (C. J. Cullingworth) . xxxi, 308
„ — epithelioma of (Heywood Smith) . . xxi, 313; xxii, 3
„ — of a woman who died from rupture of the right Fallopian tube (Aust Lawrence) . . . . . xx, 292
„ — showing rupture of tubal fœtation (C. Godson) . xxii, 186, 242
„ — from a fatal case of hæmorrhage in the pelvis (Heywood Smith) . . . . . xvii, 56
„ — from a case of hæmorrhage from the uterine mucous membrane in an infant (C. H. James) . . . xxxii, 66
„ — from a patient who died of heart disease (T. C. Hayes) . xvi, 174
„ — removed by hysterectomy (H. Smith) . . . xxi, 313
„ — from patient with ovarian cyst (P. Smith) . . xiii, 126
„ — from a patient dying during menstruation from purpura hæmorrhagica (Werlhof) (John Phillips) . . . xxxiii, 2
„ — entire removal of (C. Clay) . . . . v, 58
„ — affected with tubercle (W. R. Dakin) . . . xxxiii, 3
„ — tuberculosis of (P. D. Turner) . . . xli, 344
„ — of pregnant woman who died from convulsions during typhus fever (S. Beck) . . . . . xiii, 239
„ — from a single woman (W. Duncan) . . . xxx, 408
„ and breasts, case of absence of (L. Remfry) . . xxxvii, 12
„ and iliac glands removed by abdominal hysterectomy for cancer of cervix (T. V. Dickinson) . . . xlviii, 15
„ and ovaries (T. Spencer Wells) . . . . xi, 97

UTERUS (*continued*)—
„ and ovaries, extirpation of, with large fibrous tumours (I. B. Brown) . . . . . vi, 249
„ — absent in three sisters (C. E. Squarey) . . . xiv, 212
„ — of child who died of tubercular meningitis (F. Beach) . xv, 57
„ and placenta, adherent, from patient dying of post-partum hæmorrhage (John Phillips) . . . . xxxii, 195
„ with its contained placenta, removed from a rachitic woman, aged 30, by Porro's operation (W. Duncan) . . xxx, 408
„ placenta retained two months in (J. B. Walker) . . xii, 338
„ and vagina with the child *in situ* in the second stage of labour (W. F. Victor Bonney) . . . . . xliv, 292
„ — distension of, with muco-puriform fluid, in a child aged 7 weeks (W. McAdam Eccles) . . . . xxxiv, 250
„ — divided by a septum (W. R. Rogers) . . . xii, 297
„ — rupture of (P. Horrocks) . . . xxvi, 119, 260
„ — — (A. Wiltshire) . . . . . xxiii, 163
„ — — (Amand Routh) . . . . . xxxiv, 252
„ and rectum, adhesions between, dragging down the fundus uteri (E. E. Day) . . . . . vi, 10
„ rectum, and left kidney from a woman who died of uræmia (W. Duncan) . . . . . xxxi, 255

VACCINATION, reckless (R. Druitt) . . . . ii, 305
„ with lymph from a secondary (J. A. Thompson) . . xiii, 94
„ syphilis after (R. Druitt) . . . . v, 196
„ two instruments for performing (J. Whitehead) . . xiii, 188

VAGINA, absence of, uterus distended by retained menstrual fluid (C. H. Carter) . . . . . xxii, 251
„ — with retained menses *in utero* and Fallopian tubes (C. H. F. Routh) . . . . . xii, 34
„ complete absence of, in a case of double uterus with double hæmatometra (A. H. N. Lewers). . . . xxxviii, 327
„ air expelled from (G. Harley) . . . . iv, 173
„ air in (A. Rasch) . . . . . xii, 281
„ atresia of, case of labour with (Fancourt Barnes) . . xxv, 99
„ — instruments for (N. Bozeman) . . . xix, 96
„ primary carcinoma of (F. J. McCann) . . . xlviii, 181
„ epidermic casts from (J. H. Targett) . . xxxvii, 218
„ chorion-epithelioma of uterus with secondary growths in (G. F. Blacker) . . . . . xlvi, 55
„ — with secondary growths in (C. Lockyer) . . xlv, 245
„ closure of (J. B. Hicks) . . . . . iv, 228
„ cysts of (M. Handfield-Jones) . . . . xxxi, 129
„ — their ætiology, pathology, and treatment (H. T. Rutherfoord) . . . . . xxxiii, 354
„ polypiform cyst, growing from anterior wall of (J. H. Davis) . ix, 32
„ deciduoma malignum with secondary deposit in, lungs showing secondary deposits (F. J. McCann) . . . xlv, 248
„ secondary deposits of deciduoma malignum *without* syncytium in, after hydatidiform degeneration of the chorion (P. Horrocks) . . . . . xlv, 243
„ secondary growth of deciduoma malignum from (J. R. Morison) xlv, 249
„ on delivery by the, in extra-uterine gestation (G. E. Herman) xxix, 429
„ double, doubtful case of (A. L. Galabin) . . . xxiv, 20
„ — and bicorned uterus (G. E. Herman) . . . xx, 123
„ — and double uterus (H. Gervis) . . . . xix, 271

VAGINA (*continued*)—
„ double, and double uterus, case of pregnancy with (J. B. Hicks) . . . . . xxiii, 23
„ primary epithelioma of (C. H. Roberts) . . xxxviii, 381
„ fibroid tumour of (W. C. Swayne) . . . xlv, 142
„ — see also *Tumours*, fibroid.
„ fibro-myoma of (J. Bland-Sutton). . . . xli, 100
„ — (J. M. Munro Kerr) . . . . . xliv, 130
„ — wall of (with microscopical slide) (John Phillips) . xl, 130
„ fibrous tumour from anterior wall of (R. Barnes) . . xiv, 309
„ foreign body in, removal after four years, and after-results (C. H. Carter and F. H. Daly) . . . . xxii, 34
„ — for two years, perforating wall of bladder, its removal and closure of fistulous opening (C. H. Carter) . . xxii, 38
„ spontaneous gangrene of upper part of (G. E. Herman) . xxix, 244
„ the effect of glycerine on the quantity of secretions poured into the (G. E. Herman) . . . . xxx, 452
„ hæmorrhage from, during parturition, a diagnostic sign of (P. Budin) . . . . . xix, 232
„ imperforate, case of (P. Boulton) . . . . xxiii, 125
„ — parturition through (Heywood Smith) . . . xxiii, 117
„ incision of, for removal of extra-uterine fœtation (C. Godson) xxix, 499
„ of infant with medullary growths (N. Heckford) . . x, 224
„ inversion of, with hypertrophic elongation of the cervix uteri (R. Barnes) . . . . . xv, 124
„ laceration of, in labour (J. Matthews Duncan) . . xxxi, 236
„ malignant growth in the, complicating pregnancy (J. B. Potter) . . . . . xx, 110
„ three myomatous uteri removed *per vaginam* by Doyen's method (W. J. Smyly) . . . . . xli, 96
„ myoma of (F. J. McCann) . . . . xlviii, 182
„ myxo-sarcoma of, in a child, aged 2½ (A. W. W. Lea) . xlii, 143
„ obliteration of, cicatricial, Cæsarean section on account of (A. L. Galabin) . . . . . xviii, 252
„ os vaginæ and arms, ruptured perinæum and birth of child between (I. Baker Brown) . . . . ii, 197
„ occlusion of, after delivery, with subsequent retention of menses (S. Craddock) . . . . . xiii, 101
„ occlusion of, in a case of absence of the uterus (F. Bousquet). xxvii, 123
„ pessary (Greenhalgh's) removed with difficulty from (A. L. Galabin) . . . . . xxi, 49
„ polypus adherent to (J. B. Potter) . . . . xxv, 138
„ primary embolic chorion-epithelioma of (H. T. Hicks) . xlix, 224
„ prolapse of the, the relation of, to hernia (G. E. Herman) . xxvi, 88
„ RUPTURE OF, during labour; child in abdomen three and a half hours; pelvic cellulitis; recovery (J. H. Bell) . . iv, 197
„ — — (T. J. Walker) . . . . viii, 109
„ — two cases (A. L. Galabin) . . . . xx, 295
„ — death from septicæmia (F. H. Champneys) . . xxiii, 10
„ — with recovery (Heywood Smith) . . . xvii, 359
„ — spontaneous, with recovery (A. Wiltshire) . . xvii, 362
„ AND UTERUS, RUPTURE OF (A. Wiltshire) . . . xxiii, 163
„ — — (P. Horrocks) . . . . xxvi, 119, 260
„ — — (Amand Routh) . . . . . xxxiv, 252
„ — distension of, with muco-puriform fluid, in a child aged 7 weeks (W. McAdam Eccles) . . . . xxxiv, 250
„ — divided by a septum (W. R. Rogers) . . . xii, 297

VAGINA (*continued*)—
„ "grape-like" sarcoma of the cervix uteri fungating into and infiltrating the walls of, in a child aged 12 months; extirpation of uterus and (H. J. Curtis) . . . xlv, 320
„ sarcoma of, see also *Sarcoma*.
„ secretion from (W. J. Gow) . . . . xxxvi, 52
„ septum in, case of transverse (H. Gervis) . . . xxiv, 210
„ — vertical, impeding labour (J. B. Hicks) . . . xxiii, 24
„ slough from a case of enteric fever, forming a complete cast of (W. S. Playfair) . . . . xxxviii, 33
„ sponges in, means of keeping aseptic (J. Matthews Duncan) . xxiv, 5
„ suppuration at the back and front parts of, following pelvic cellulitis after a first pregnancy (G. D. Gibb) . . ii, 324
„ tumour from anterior wall of (A. Meadows) . . x, 141
„ ulceration of wall of, caused by a pessary (T. C. Hayes) . xvi, 30

VAGINAL DRAINER (A. Rasch) . . . . x, 94

VAGINAL INJECTION of acid nitrate of mercury, death following (John Phillips) . . . . . xxxiii, 180

VAGINAL SPECULUM, see *Speculum*.

VAGINISMUS (J. M. Sims) . . . . . iii, 356
„ [dyspareunia of Barnes] (W. Schnegierief) . . xvi, 187

VAGINITIS, membranous, in which the *Bacillus coli communis* was found (T. G. Stevens) . . . . xli, 228

VALVES, mitral stenosis in a primipara (G. Coates) . . xxviii, 108

VARIOLA, see *Smallpox*.

VASELINE, a new lubricant, specimens of (A. Wiltshire) . xviii, 176

VEINS, puerperal thrombosis (W. S. Playfair) . xvi, 42, 89
„ umbilical, phlebitis of, producing pyæmia (G. Roper) . xix. 8
„ varicose, legging for (— Stewart) . . . xvi, 88

VENTRO-FIXATION of uterus for complete incontinence of urine (H. Macnaughton-Jones) . . . . xl, 226

VERSION, cases of, in the Montreal University Lying-in Hospital (D. C. MacCallum) . . . . . xx, 40
„ combined external and internal (J. B. Hicks) . . v, 219
„ external, present position of, in obstetrics, with a suggestion of a new method of performing it (W. R. Pollock) . . xlviii, 319
„ in cases of contracted brim (P. L. Burchell) . . xxv, 61
„ one of the causes of difficulty in, with remarks on the practice of amputating the procident arm (G. E. Herman) . . xxviii, 150
„ for presentation of the upper extremity, on the choice of leg which should be seized in (A. L. Galabin) . . xix, 239
„ spontaneous, in a case of obstructed labour, following an unsuccessful attempt to deliver by the crotchet after craniotomy (S. D. Hine) . . . . . xxvii, 293
„ incarcerated ovarian dermoid ruptured during delivery by forceps and (H. R. Spencer) . . . . xl, 331

VERTEBRÆ, imperfection of, and absence of spinal medulla in an early embryo (C. B. Lockwood) . . . . xxix, 234
„ spinal column exhibiting want of ossification in the interarticular portion of the lumbar (G. F. Blacker) . . xlii, 90
„ see *Spondylolisthesis*.

VESICO-VAGINAL FISTULA, see *Fistula*, vesico-vaginal.

VIABILITY in a child born at five and a half months (C. H. F. Routh) . . . . . xiii, 132

VILLI, proliferation of epithelium of, as a syncytium forming reticulating processes, shown in a carneous mole retained *in utero* five months after death of embryo (A. L. Galabin) . xlv, 240

„ chorionic, myxoma of, engrafted upon uterus; myxoma of fundus uteri following vesicular mole? (A. L. Galabin) . xlv, 241

VINCENT (RALPH HENRY), lymphangitis mammæ: an affection of the breast arising about the tenth day of the puerperium with well-marked clinical features . . . xliv, 158

VISCERA, abdominal, transposition of greater part of, into the left cavity of the thorax (H. W. Bailey) . . . x, 6

„ hæmorrhages from, in stillborn children (H. R. Spencer) . xxxiii, 203

„ pelvic, after death from spontaneous rupture of ovarian cyst, complicated with fibroid tumour of uterus (P. Smith) . xiii, 39

„ — showing congenital communication between the rectum and the genito-urinary tract (A. Doran) . . . xxii, 79

„ — showing pseudo-hermaphroditism (C. H. Roberts) . xliii, 298

„ — female, encysted tuberculous peritonitis and its effects upon (J. H. Targett) . . . . . xxxix, 126

„ transposed, from a pregnant woman, *post-mortem* Cæsarean section (E. Buckell) . . . . . xix, 179

VOLSELLA FORCEPS for the soft dilated cervix (R. Wise) . xliii, 233

VOLVULUS in a fœtus (R. D. Maxwell) . . . xlviii, 277

VOMITING, excessive, in early pregnancy, depending on the irritation of the gravid uterus (W. T. Smith) . . . i, 335

„ of pregnancy: its causes and treatment (W. G. Hewitt) . xiii, 103

„ — on the so-called uncontrollable (Graily Hewitt) . xxvi, 273, 331

„ — observations on the ætiology of (A. E. Giles) . . xxxv, 303

„ in pregnancy, two fatal cases of pernicious (J. L. Maxwell) . xliii, 288

VOTE OF CONDOLENCE on the death of Dr. W. M. Graily Hewitt . xxxv, 336

VULSELLUM FORCEPS, new axis-traction (R. Barnes) . . xxv, 68

VULVA, cyst removed from (A. L. Galabin) . . . xxvi, 56

„ discharges from, in children (G. D. Robinson) . . xli, 14

„ elephantiasis of (W. S. Playfair) . . . . xix, 184

„ epithelioma of, with after-histories (A. H. N. Lewers) . xlviii, 163

„ fibro-myoma of the vestibule (J. Inglis Parsons) . . xlviii, 184

„ case of acute gangrene of, in an adult (G. E. Herman) . xxv, 141

„ hydatidiform cysts growing in (A. J. Sturmer) . . xliii, 148

„ list of ovariotomies in women over eighty. A case, aged 83, complicated by epithelioma of the (L. Remfry) . xxxvii, 155

„ case of lupus of (A. H. N. Lewers) . . . xxxi, 326

„ papillary inflammation of, chronic (W. O. Priestley) . xxvi, 156

„ (?) parasitic cyst of (A. J. Sturmer) . . . xliv, 2

„ see also *Labium, Pudendum.*

WADE (W. F.), puerperal embolism . . . . vi, 255

„ case of chorea in pregnancy successfully treated by dilatation of the os uteri . . . . . xxii, 244

WAITS (J.), serous tumour in the occipital region . . vii, 158

WALKER (G. S.), see *Cleveland, W. F.*

WALKER (J. B.), placenta retained *in utero* two months . xii, 338

WALKER (T. J.), ruptured vagina during labour . . viii, 109

WALLACE (FREDERICK), case of monstrosity . . . xvii, 176
„ — *report* on ditto by committee (T. C. Hayes and J. H. Aveling) xvii, 277
„ uterus of a woman, aged 55, who had had two miscarriages at the age of thirty-nine . . . . . xvii, 177
„ — *report* on ditto by committee (T. C. Hayes and J. H. Aveling) xvii, 276
„ remarks in the discussion on puerperal fever . . xvii, 260
„ anencephalous fœtus with spina bifida . . . xxiii, 204
WALLER (C.), transfusion of blood, its history and application in cases of severe hæmorrhage . . . . i, 61
„ extra-uterine fœtation . . . . . i, 99
„ case in which the delivery of a very large living child was effected by means of the long forceps . . . i, 309
WALTER (WILLIAM), portable transfusion apparatus . . xxvi, 182
„ multilocular ovarian cyst . . . . xxvi, 148
„ fibro-myoma of uterus . . . . . xxvi, 326
WALTERS (J. HOPKINS), uterus torn out after delivery . xxiv, 136; xxvi, 233
WALTERS (J.), and A. R. WALTERS, case of puerperal septicæmia treated by anti-streptococcic serum . . . xl, 277
WARN (R. T.), labour complicated with ovarian disease. . xi, 198
WATKINS (R. W.), retention of a fœtus in the abdomen forty-three years . . . . . viii, 106
WAY (J.), twin pregnancy . . . . . vii, 209
WEBB (F.), hydatid degeneration of the ovum . . ix, 85
WEIR (G.), spring intra-uterine stem . . . viii, 218
WEISS (MESSRS.), case of instruments for uterine operations . vii, 157
WELLS (T. SPENCER), large congenital encephaloid tumour, not impeding delivery . . . . . ii, 27
„ ovarian tumour removed by ovariotomy . . . iii, 214
„ stone from female bladder . . . . iii, 285
„ two ovarian cysts removed by ovariotomy . . . iii, 285
„ female bladder, showing the results of retention of urine after delivery . . . . . iii, 354
„ cast of female bladder . . . . . iii, 417
„ ovariotomy, and reply to a statement respecting it made by Mr. Baker Brown . . . . . iv, 89
„ multilocular cyst of left ovary, removed six years after removal of right ovary . . . . . x, 19
„ fibroid outgrowth from fundus uteri . . . xi, 73
„ — *report* on ditto by J. B. Hicks . . . . xi, 76
„ uterus and ovaries from above case . . . xi, 97
„ complication of pregnancy with ovarian disease . . xi, 251
„ opening remarks and reply in the discussion on puerperal fever . . . . . xvii, 90, 265
„ additional cases of ovariotomy performed during pregnancy . xix, 185
„ list of published writings, arranged chronologically (C. J. Cullingworth) . . . . . xl, 91
WENYON (CHARLES), double monster . . . xxxiii, 384
WEST (CHARLES), remarks in the discussion on puerperal fever . xvii, 235
„ inaugural address as President . . . . xix, 42
„ annual address as President . . . xx, 10; xxi, 5
„ death of . . . . . xl, 174
WEST (R. UVEDALE), membranous croup . . . i, 53
„ description of an anencephalian monster . . . i, 105

WEST (R. UVEDALE) (*continued*)—
„ fatal case of puerperal peritonitis complicated with ovarian disease, followed by febrile diseases of the puerperal state, the probable consequences of infection . . . i, 187
„ sudden apoplectiform seizure, terminating fatally in thirty-five hours, on the sixth day of lying-in . . . ii, 276
„ epileptiform convulsions in the third week of the puerperal state . . . . . iii, 35
„ is the ergot of rye, when administered to the mother during labour, dangerous or not to the life of the child? . . iii, 222
„ protracted retention of blighted ovum . . . iv, 17
„ abnormal variety of the battledore placenta . . vii, 257

WEST (W. J.), first ovariotomist in England, portrait of . xviii, 177

WESTMACOTT (J. G.), use of the whale-bone loop . . xi, 177
„ corkscrew funis . . . . . xiii, 51
„ triplet fœtuses . . . . . xiii, 95
„ note on J. Palfrey's specimen of monster . . . xix, 100

WHEATON (S. W.), ovary containing three dermoid cysts . xxxiii, 28
„ early tubercular disease of uterus . . . xxxiii, 29
„ for *William Duncan*, diffuse malignant disease of the body of the uterus . . . . . xxxiii, 113, 161
„ prolapse of Meckel's diverticulum in an infant forming an umbilical tumour . . . . . xxxiv, 184
„ micrococci in the substance of a decomposing fibroid tumour removed by hysterectomy . . . . xxxiv, 187
„ microscopic section of the uterine mucous membrane of an infant suffering from uterine hæmorrhage . xxxiv, 190
„ bony girdle from a dermoid tumour . . . xxxv, 4
„ — *report* of Committee . . . . xxxv, 41
„ bilateral cephalhæmatomata, cast of . . . xxxv, 6

WHITE (B.), see *Hayes, T. C.*

"WHITE LEG," see *Phlegmasia alba dolens.*

WHITEHEAD (J.), two instruments for performing vaccination . xiii, 188

WHITMARSH (W. M.), ovum of seven months expelled entire . vi, 105

WILLIAMS (JOHN), calcified fibroids of uterus . . . xvi, 125
„ on the relation between congestion of the uterus and flexion of the organ . . . . . xvi, 202
„ case of hydatidiform mole . . . . xvii, 2
„ the mechanical action of pessaries . . . xviii, 126
„ the pathology and treatment of membranous dysmenorrhœa . xix, 138
„ for *W. E. Marshall*, ruptured uterus . . . xx, 86
„ on some of the changes in the uterus resulting from gestation, and on their value in the diagnosis of parity . xx, 172
„ ovarian tumour . . . . . xxiv, 77
„ dermoid cyst of the ovary: myxomatous growth of the peritoneum . . . . . xxiv, 93
„ on the natural history of dysmenorrhœa . . xxiv, 103, 141
„ fibroid tumour of the ovary removed by abdominal section . xxv, 35
„ placenta with cyst on the fœtal surface . . . xxv, 69
„ on the corroding ulcer of the os uteri . . . xxvi, 60
„ — further note on . . . . xxvii, 300
„ note on a condition observed in the navel cord of a young infant . . . . . xxvi, 199

Williams (John) (*continued*)—
„ note on the involution of the puerperal uterus in the absence of the ovaries . . . . . xxvi 203
„ the circulation in the uterus, with some of its anatomical and pathological bearings . . . . . xxvii, 112
„ on serous perimetritis . . . . . xxvii, 169
„ inaugural address as President . . . . xxix, 99
„ fibroid tumour of the ovary, with a papilliferous cyst . xxix, 247
„ — *report* on ditto by committee (A. L. Galabin, G. E. Herman, and Alban Doran) . . . . xxix, 513
„ case of extra-uterine pregnancy in which abdominal section was performed during the life of the fœtus at the thirty-fifth week of gestation . . . . . xxix, 482
„ annual address as President . . . xxx, 104; xxxi, 73
Williams (A. Wynn), missed labour . . . vi, 208
„ large abdominal cyst . . . . . viii, 218
„ — *report* on ditto, by Drs. G. Hewitt and Williams . viii, 278
„ hæmorrhage due to retained placenta, supposed to be the placenta of a previous abortion . . . . viii, 317
„ diphtheria . . . . . ix, 35
„ hydatidiform vesicles attached to placenta . . . x, 93
„ large ovarian tumour . . . . . x, 197
„ heart and lungs of an infant aged 14 days . . . xi, 242
„ persistent sickness; labour induced after full period had elapsed; scarlatina in the room . . . . xii, 164
„ cancer of the womb successfully treated by bromine . xii, 249
„ mole from case of supposed three months' pregnancy . xiii, 95
„ epithelioma of lip treated by injection of bromine . . xiii, 97
„ large-sized mucous polypus . . . . xiv, 135
„ pessary for treatment of flexions of the uterus . . xiv, 308
„ shield for supporting vulcanite-stem pessary . . xv, 246
„ intra-uterine tumour; removal; subsequent pregnancy; delivery by turning; post-partum hæmorrhage; recovery . xvi, 183
„ intra-mural calcareous tumour impeding labour . . xvii, 172
„ remarks in the discussion on puerperal fever . . xvii, 196
„ adherent placenta . . . . . xxiv, 300
„ two specimens of fibroid tumour of the uterus . . xxv, 46
„ — *report* on ditto by committee (A. Doran, C. Godson, and F. H. Champneys) . . . . . xxv, 70
„ dysmenorrhœal membrane . . . . xxv, 233
„ see *Meadows, A.*
Williamson (Herbert), pathology and symptoms of hydatidiform degeneration of the chorion . . . xli, 303
„ abnormal umbilical cord . . . . . xliv, 141
„ tubercle of uterus . . . . . xliv, 141
„ unusual case of ectopic gestation . . . . xliv, 225
„ pulmonary embolism occurring twenty-four days after delivery xlv, 189
„ syncytioma from the body of a woman who died in St. Bartholomew's Hospital thirty-one years ago . . xlv, 253
„ and Harrison Cripps, two cases involving the question of the site of impregnation . . . . . xlvi, 89
„ section of the wall of an ovarian dermoid showing giant-cells xlvi, 299
„ sections illustrating the structure of three different types of urethral caruncles . . . . . xlvii, 6
„ "grape-like" sarcoma of the cervix uteri . . . xlvii, 119
„ and Griffith (W. S. A.), a case of fibro-myoma of the uterus undergoing sarcomatous change . . . . xlviii, 22

WILLIAMSON (HERBERT) (*continued*)—
„ a note on adenoma of the labium . . . . xlviii, 235
„ see *Doran, Alban.*
„ see *Griffith, W. S. A.*

WILLING (G. F. BUTLER), five and half months' fœtus . . xvi, 85
„ — *report* on ditto by committee (H. Savage and C. H. F. Routh) . . . . . xvi, 97

WILLOUGHBY (E. F.), cicatrices from burn requiring division during labour. . . . . xii, 31

WILLS (W.), double monstrosity, with account of the delivery . vii, 6

WILMOT (R. E.), fillet or loop as an obstetric aid, with especial reference to a new modification of the instrument . . xv, 172

WILSON (H. S.), *per G. E. Herman*, notes on a fœtus . . xxi, 58

WILSON (THOMAS), chronic axial rotation of an ovarian cyst giving rise to extreme twisting of the elongated uterus . . xxxix, 167
„ hydramnion in cases of unioval or homologous twins . xli, 235
„ relations of organic affections of the heart to fibro-myoma of the uterus . . . . . xlii, 176
„ primary pneumococcus meningitis simulating puerperal eclampsia . . . . . xliv, 5

WILTSHIRE (ALFRED), new form of uterine tent . . viii, 149
„ observations on puerperal temperatures . . . ix, 146
„ new utero-vaginal douche . . . . x, 20
„ ovarian tumour and treatment of pedicle by acu-pressure needle . . . . . xii, 31
„ univentricular heart, by Dr. Elliot, of Carlisle . . xii, 164
„ infant with marks and boy with webbed fingers . . xii, 329
„ fibro-enchondromatous tumour complicating pregnancy ; safe delivery . . . . . xii, 376
„ tetanus after abortion . . . . . xiii, 133
„ common skin diseases of children . . . . xv, 223
„ protected perforators, modifications of Oldham's and Simpson's perforators . . . . . xvi, 88
„ case of spontaneous rupture of the vagina, with recovery . xvii, 362
„ liquid extract of ergot (Martindale's) . . . xviii, 2
„ specimens of vaseline, a new lubricant, and vulcanite jars for carrying it . . . . . xviii, 176
„ notes of a case of puerperal septicæmia with abscesses, disorganisation of the left wrist-joint, and phlegmasia dolens, in which recovery took place . . . . xviii, 181
„ specimen of utero-vaginal rupture . . . xviii, 220
„ two cases of idiocy . . . . . xviii, 280
„ for *John Hadden*, specimen of fibroid tumour of the uterus . xix, 119
„ toughened glass specula . . . . xix, 137
„ modifications in Tarnier's forceps, with extract from his letter describing the changes . . . . xix, 223
„ in normal asymmetry of the fœtal head, and colour of eyes in newly-born infants . . . . . xx, 78
„ photograph of an infant with enormous enlargement of the shoulder, hip, and knee-joints . . . . xx, 84
„ specimen of utero-vaginal rupture, placenta prævia, multiple fibroids with deformed fœtus . . . . xxiii, 163
„ cysts from the labia minora . . . . xxiii, 206

WISE (ROBERT), placenta, cord, fœtus, and membranes . xxxviii, 166
„ aborted ovum . . . . . xxxix, 259

Wise (Robert) (*continued*)—
„ pregnant horn from the uterus of a cat . . . xxxix, 260
„ abortion showing recent placental hæmorrhage . . xl, 257
„ entire full-time ovum in twins . . . . xlix, 147
„ volsella forceps for the soft dilated cervix . . . xliii, 233
WOMEN in Southern India, medical history of (J. Shortt) . v, 103
„ power and act of propagation in (R. Druitt) . . ii, 139
„ special meeting relative to the admission of, to the Fellowship of the Society . . . . . xvi, 65
„ admission of, as Fellows of the Society . . . xliv, 56
Woodman (W. Bathurst), chancre on os uteri . . vii, 26
„ numerous fibroids in a uterus . . . . vii, 26
„ combination of chorea with pregnancy . . . vii, 102
„ dermoid cyst of right ovary; *post-mortem* . . . vii, 158
„ three cases of a third nipple in the human subject, one case hereditary . . . . . ix, 50
„ chronic inversion of the uterus which had existed for more than five years without serious symptoms . . . ix, 52
„ iron salts in anæmia complicated with pregnancy . . xii, 33
„ two forms of apparatus for use in empyema of children . xv, 2
„ on the prevention of mammary abscesses by the application of the principle of rest . . . . . xvii, 9
„ carneous or fleshy mole, with history of the case by R. Hughes xviii, 3
„ — *report* on ditto by committee (John Williams and W. Bathurst Woodman) . . . . . xviii, 311
Woodward (W.), mechanical support during labour . . xi, 192
Worship (J. L.), ovarian disease . . . . xi, 76
„ extra-uterine tubal fœtation, with specimen . . xi, 211
„ deformed fœtus . . . . . xiv, 139
„ tumour of the uterus complicating pregnancy . . xiv, 305
„ case of supposed cancer of both ovaries . . . xix, 235
„ remarks in the discussion on the use of forceps . . xxi, 159
Wynne (James), inveterate case of ulceration of the cervix uteri cured by the application of styptic colloid, with remarks . xi, 86

XYLONITE, pessaries of (A. Meadows) . . . xxiii, 131

Yarrow (G. E.), see *Godson, Clement,* and *Eve, F. S.*
Young (Eric Ernest), primary tuberculous disease of the cervix uteri . . . . . xlviii, 286

ZINC, fused anhydrous sulphate of, use of, to the canal of the cervix uteri (J. B. Hicks) . . . . viii, 220
„ phosphide of, treatment of chlorosis and anæmia with (J. A. Thompson) . . . . . xvii, 57

PRINTED BY ADLARD AND SON, LONDON AND DORKING.